

# The Lectin Pathway-A Dominant Pattern of the Complement System Activation in Primary Focal Segmental Glomerulosclerosis?

---

Zagorec, Nikola; Horvatić, Ivica; Šenjug, Petar; Sović, Slavica; Galešić, Krešimir; Galešić Ljubanović, Danica

Source / Izvornik: **Kidney International Reports, 2024, 9, 1925 - 1926**

Journal article, Published version

Rad u časopisu, Objavljena verzija rada (izdavačev PDF)

<https://doi.org/10.1016/j.ekir.2024.02.1441>

Permanent link / Trajna poveznica: <https://um.nsk.hr/um:nbn:hr:105:633324>

Rights / Prava: [Attribution-NonCommercial-NoDerivatives 4.0 International/Imenovanje-Nekomercijalno-Bez prerada 4.0 međunarodna](#)

Download date / Datum preuzimanja: **2025-03-22**



Repository / Repozitorij:

[Dr Med - University of Zagreb School of Medicine Digital Repository](#)

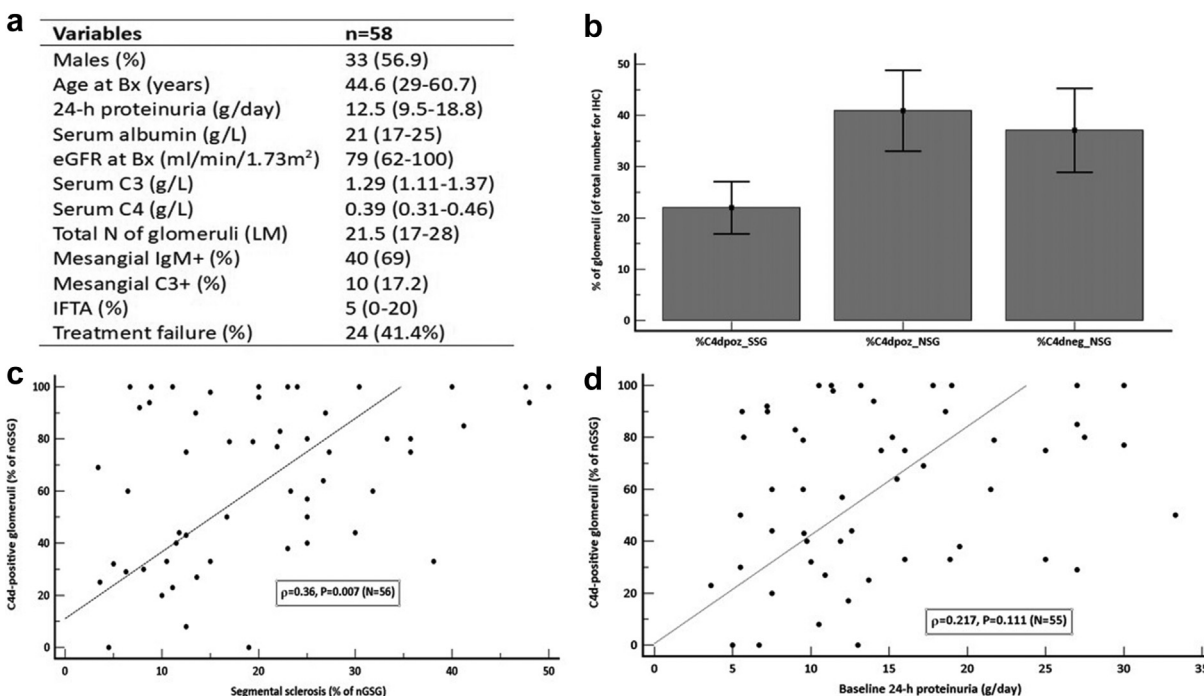


# The Lectin Pathway—A Dominant Pattern of the Complement System Activation in Primary Focal Segmental Glomerulosclerosis?



**To the Editor:** We read with a big interest article by Cambier *et al.*<sup>1</sup> reporting significantly elevated urine levels of C5b-C9 and C5a in individuals with focal segmental glomerulosclerosis (FSGS), indicating the role of the complement system activation in disease pathogenesis. We can not only confirm the role of complement system activation in pathogenesis of primary FSGS, but also show prognostic significance of C4d, long-term tissue “fingerprint” of complement activation, and the role of lectin pathway activation.

In our cohort of 58 strictly selected patients with primary FSGS treated with immunosuppressive therapy (Figure 1a), additional immunohistochemistry for C4d on paraffin-embedded biopsy samples was performed. At least 1 nonglobally sclerosed glomerulus was C4d-positive (C4d+) in segmental distribution in 55 immunohistochemistry samples. All segmental scleroses were C4d+ and about 40% of all glomeruli were C4d+ nonsclerotic glomeruli (NSG) (Figure 1b). C1q was negative in all biopsy samples. Percentage of segmentally sclerosed glomeruli (SSG) was positively correlated with percentage of C4d+ nonglobally sclerosed glomeruli ( $\rho = 0.36, P = 0.007$ ) (Figure 1c). Contrary to the study above in which there was positive correlation between proteinuria and complement components level; in our study, there was no significant correlation between baseline 24-hour proteinuria and percentage of C4d+ nonglobally sclerosed glomeruli ( $\rho = 0.217, P = 0.111$ ) (Figure 1d), which is consistent with previous report.<sup>2</sup> In the univariate logistic regression models, IgM positivity (69% of samples) and C3 positivity



**Figure 1.** (a) Relevant clinical and histologic data of a cohort of 58 individuals with primary FSGS (categorical data shown as numbers and percentages and numeric as medians with interquartile range). (b) Distribution of glomeruli available for immunohistochemistry regarding C4d positivity and segmental sclerosis. (c) Percentage of glomeruli with segmental sclerosis (of the total number of nonglobally sclerosed glomeruli) was positively correlated with percentage of C4d-positive glomeruli (Spearman’s coefficient,  $\rho = 0.36; P = 0.007$ ). (d) 24-hour proteinuria was not correlated with the percentage of C4d-positive glomeruli (of the total number of nonglobally sclerosed glomeruli) (Spearman’s coefficient,  $\rho = 0.217; P = 0.111$ ). %C4dpoz\_SSG; percentage of C4d-positive SSG; %C4dpoz\_NSg, percentage of C4d-positive NSG; Bx, kidney biopsy; eGFR, estimated glomerular filtration rate according to Chronic Kidney Disease-Epidemiology Collaboration; IFTA, interstitial fibrosis and tubular atrophy; IHC, immunohistochemistry; N, number; nGSG, nonglobally sclerosed glomeruli; NSG, nonsclerotic glomeruli; SSG, segmentally sclerosed glomeruli.

(17% of samples) were not associated with treatment failure, which is defined as nonachievement of at least partial remission at the last follow-up, (odds ratio [OR]: 2.35, 95% confidence interval [CI]: 0.71–7.87,  $P = 0.164$  and OR: 1.53, 95% CI: 0.39–5.99,  $P = 0.545$ , respectively), percentage of SSG was marginally significant (OR: 1.03, 95% CI: 0.99–1.07,  $P = 0.088$ ), whereas percentages of interstitial fibrosis and tubular atrophy and percentage of C4d+ nonglobally sclerosed glomeruli were independent predictors of treatment failure, and remain significant after the adjustment to the 24-hour proteinuria and percentage of SSG in the multivariate model (OR per 1% = 1.06, 95% CI: 1.003–1.11,  $P = 0.038$  and OR per 1% = 1.03, 95% CI: 1.007–1.054,  $P = 0.008$ , respectively). C4d positivity in all SSG and the association between percentage of SSG and C4d are consistent with previous reports.<sup>2,3</sup> Although prognostic significance of C4d was not investigated in the pivotal study by de van de Lest *et al.*,<sup>2</sup> it was shown that C4d could precede the development of segmental sclerosis in FSGS. This is the possible explanation of why about 60% of all C4d+ glomeruli in our analysis were without sclerosis. Of note, about 20% of individuals with minimal change disease were also C4d+; thus the role of complement activation cannot be ruled out in the pathogenesis of minimal change disease.<sup>2</sup> Although previous studies indicated possible role of IgM and C3 in pathogenesis of FSGS, apparently they do not influence disease outcome.<sup>4</sup> Taken together, complement components are not only trapped by chance in sclerotic areas, but might play a role in the development of sclerosis and indicate worse renal prognosis. Previous studies speculate on classic or alternative complement pathway activation in FSGS.<sup>2–5</sup> Given that almost all renal samples were C4d+ in the absence of C1q, and C3 deposits were rare, the lectin pathway might play the main role in the pathogenesis of primary FSGS in majority of patients. Further studies are needed to elucidate the role of lectin pathway in primary FSGS as well as the prognostic

significance of C4d deposits and possible treatment implications in the context of therapeutic agents interfering with complement cascade.

1. Cambier A, Patey N, Royal V, et al. A prospective study on complement activation distinguishes focal segmental glomerulosclerosis from minimal change disease. *Kidney Int Rep.* 2024;9:661–670. <https://doi.org/10.1016/j.ekir.2023.12.015>
2. van de Lest NA, Zandbergen M, Wolterbeek R, et al. Glomerular C4d deposition can precede the development of focal segmental glomerulosclerosis. *Kidney Int.* 2019;96:738–749. <https://doi.org/10.1016/j.kint.2019.04.028>
3. Drachenberg CB, Papadimitriou JC, Chandra P, et al. Epidemiology and pathophysiology of glomerular C4d staining in native kidney biopsies. *Kidney Int Rep.* 2019;4:1555–1567. <https://doi.org/10.1016/j.ekir.2019.07.015>
4. Strassheim D, Renner B, Panzer S, et al. IgM contributes to glomerular injury in FSGS. *J Am Soc Nephrol.* 2013;24:393–406. <https://doi.org/10.1681/ASN.2012020187>
5. Chandra P. C4d in native glomerular diseases. *Am J Nephrol.* 2019;49:81–92. <https://doi.org/10.1159/000496059>

Nikola Zagorec<sup>1,2</sup>, Ivica Horvatić<sup>1,2,3</sup>,  
Petar Šenjug<sup>3,4</sup>, Slavica Sović<sup>3,5</sup>,  
Krešimir Galešić<sup>1,3</sup> and Danica Galešić  
Ljubanović<sup>2,3,4</sup>

<sup>1</sup>Department of Nephrology and Dialysis, Dubrava University Hospital, Zagreb, Croatia; <sup>2</sup>Faculty of Pharmacy and Biochemistry, University of Zagreb, Zagreb, Croatia; <sup>3</sup>School of Medicine, University of Zagreb, Zagreb, Croatia; <sup>4</sup>Division of Nephropathology and Electron Microscopy, Department of Pathology and Cytology, Dubrava University Hospital, Zagreb, Croatia; and <sup>5</sup>School of Public Health “Andrija Stampar,” Zagreb, Croatia

**Correspondence:** Nikola Zagorec, Dubrava University Hospital, Avenija Gojka Šuška 6, 10000 Zagreb, Croatia. E-mail: [nikola.zagi@gmail.com](mailto:nikola.zagi@gmail.com)

Received 13 February 2024; accepted 26 February 2024

*Kidney Int Rep* (2024) 9, 1925–1926; <https://doi.org/10.1016/j.ekir.2024.02.1441>

© 2024 International Society of Nephrology. Published by Elsevier Inc. This is an open access article under the CC BY-NC-ND license (<http://creativecommons.org/licenses/by-nc-nd/4.0/>).