

Down syndrome and congenital heart defects

Hinnawi, Nouha

Master's thesis / Diplomski rad

2016

Degree Grantor / Ustanova koja je dodijelila akademski / stručni stupanj: **University of Zagreb, School of Medicine / Sveučilište u Zagrebu, Medicinski fakultet**

Permanent link / Trajna poveznica: <https://um.nsk.hr/um:nbn:hr:105:288277>

Rights / Prava: [In copyright](#)/[Zaštićeno autorskim pravom.](#)

Download date / Datum preuzimanja: **2025-01-03**



Repository / Repozitorij:

[Dr Med - University of Zagreb School of Medicine Digital Repository](#)



UNIVERSITY OF ZAGREB
SCHOOL OF MEDICINE

Nouha Hinnawi

Down syndrome and congenital heart defects

Graduation thesis



Zagreb, 2016

This graduate thesis was made at the Paediatric Cardiology department of University Hospital Centre Zagreb, under supervision of Assistant Professor Dr. sc. Daniel Dilber and was submitted for evaluation in 2015/2016.

Abbreviations

AFP alpha-fetoprotein

ASD atrial septal defect

AV atrioventricular

AVSD atrioventricular septal defect

CD celiac disease

CHD congenital heart defect

CHF chronic heart failure

CNS central nervous system

DS Down syndrome

ECG electrocardiogram

GI gastrointestinal

HANDS hematological abnormalities in newborn Down syndrome

hCG human chorionic gonadotropin

IQ intelligence quotient

LV left ventricle

PDA patent ductus arteriosus

PVR pulmonary vascular resistance

RV right ventricle

SVR systemic vascular resistance

TMD transient myeloproliferative disorder

TOF Tetralogy of Fallot

VSD ventricular septal defect

Content

Summary

1. Introduction	1
1.1 Genetic background	1
1.2 Morphological features	3
1.3 CNS and psychosomatic manifestations	5
1.4 Gastrointestinal abnormalities	6
1.5 Endocrine abnormalities	7
1.6 Hematopoietic disorders	8
1.7 Additional findings	8
2. Congenital heart defects	9
2.1 Normal heart anatomy	9
2.2 Atrioventricular septal defect	11
2.3 Ventricular septal defect	13
2.4 Atrial septal defect	15
2.5 Persistent patent ductus arteriosus	18
3. Antenatal screening for Down's and its importance	21
3.1 Ultrasonography	21
3.2 Maternal serum biochemical markers	22
3.3 Invasive diagnostic tests	22
4. Down syndrome's impact on society	23
5. Advances and future prospects in Down syndrome	24
6. Conclusion	25
Acknowledgement	27
References	28
Biography	31

Summary

Individuals suffering from Down syndrome have widespread body frame abnormalities and impaired brain development and function; the latter leading to impaired intellectual disability. It is caused by having a partial or complete third copy of chromosome 21, and there exists 3 forms: simple trisomy 21, translocation trisomy and mosaic trisomy. Symptoms include intellectual disabilities/mental retardation, early onset Alzheimer's disease and the appearance of various phenotypic features, such as narrow slanted eyes, flat nose and short stature. In addition, cardiac heart defects are very frequent and have significant impact on life expectancy. The most common being from the group of endocardial cushion defects, with forms of common AV canal being the typical and major presentation. Left untreated, it can be complicated with pulmonary hypertension causing symptoms such as tachydyspnea, cyanosis and failure to thrive. There are also other health problems throughout the body, like thyroid function abnormalities along with nutritional disorders¹³. As the many issues listed above that are vital to health and well-being of individuals with DS remain to be studied, this an important and exciting time for chromosome 21 trisomy research.

Today all children with congenital heart defect are treated, including those accompanying Down syndrome. Together with the changing attitude towards children with trisomy 21, there are many issues to be concerned using a multi-systemic approach (medical, educational, environmental), to deal with other organic diseases and also cognitive development, to allow DS patients to extract their maximum potential and increase their chances of living a rich, independent community life.

1. Introduction

Down syndrome is the most common and the most understood chromosomal abnormality in humans occurring at a rate of 1:600-700 newborns. This chromosomal abnormality is primarily caused by over-expression of chromosome 21, where instead of two there are three copies^{13, 18, 21} and is frequently associated with a varied combination of morphological and structural birth defects. These defects include congenital mental disability, hypotonia, characteristic body features, heart defects, and other systemic congenital malformations. However, not all defects occur in each patient; there is a wide range of phenotypic variations. The impact on each patient is individual, with some individuals being severely affected while others are healthy and able to function as independent adults⁹.

It was first described by an English physician John Langdon Down in 1862, who recognized and differentiate this syndrome from mental disability. When karyotype techniques were first discovered in the mid twentieth century, this led to the understanding that three copies of chromosome 21 was the cause of Down syndrome, a finding that was reported by Jerome Lejeune, from Paris in 1959.

1.1 Genetic background

In a normal cell there are 23 pairs of chromosomes, giving a total of 46 chromosomes. Twenty-two of these are called autosomes, which look the same in males and females, where the last pair (23th) is the sex chromosome that indicates the gender, as illustrated in figure 1.

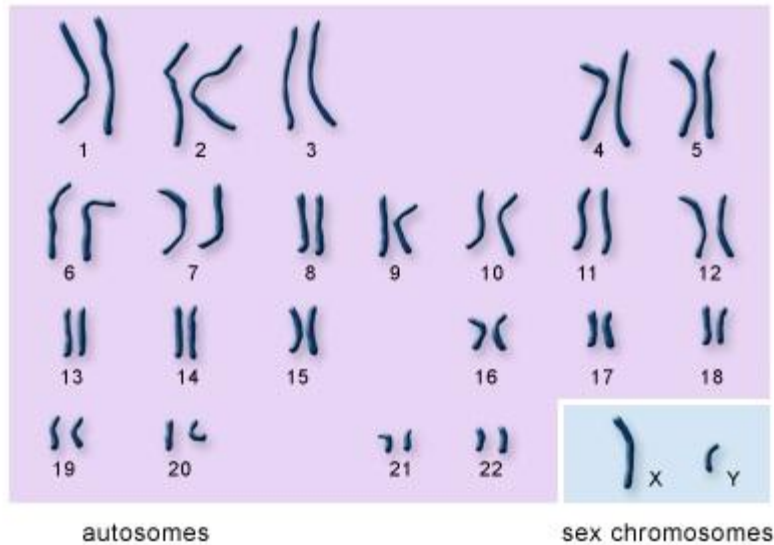


Figure 1 The human chromosomes

In Down syndrome patients this is a bit different, they usually have an additional chromosome 21 making it 3 copies, also known as simple trisomy 21; this extra chromosome affects almost every organ system and results in a wide spectrum, of phenotypic consequences. About 95 percent of affected persons have simple trisomy 21, so that their chromosome count adds up to 47, which is the most common cause of the trisomy, called meiotic nondisjunction. Parents of such children have a normal karyotype and are normal in all respect, this incidence is increasing from 1 in 1,250 at age 25, to 1 in 1,000 at age 30, to 1 in 400 at age 35, to 1 in 100 at age 40, to 1 in 30 at age over 45 years², therefore suggesting that in most cases the meiotic nondisjunction of chromosome 21 occurs in the ovum, during the formation of reproductive cells (oocytes and spermatocytes) and depends on abnormal chromosome separation at the first or second meiotic division leading to a double chromosome 21 in these cells¹³. When the chromosome is shown to be driven from a paternal chromosome it hasn't shown any effect of paternal age to this type of mutation¹⁵. In about 4 percent of all patients with DS, the extra chromosomal material is present not as an extra chromosome but as a translocation (the transfer of a chromosome fragment to another) of long arm of chromosome 21 to, most commonly chromosome 22 or 14. Such cases are frequently familial; the translocated chromosome is inherited from one of the parents, who are most frequently a carrier of a robertsonian translocation. In the remainder 1 percent of Down syndrome patients are mosaic, when the extra chromosome 21 is present in some, but not all cells, of the individual giving a mixture of 46- and 47- chromosome cells. They result from

mitotic nondisjunction of chromosome 21 during early stage of embryogenesis; symptoms in such cases are variable and milder depending on the proportion of abnormal cells to normal cells¹⁵. Three sub-divisions of mosaic trisomy are found; single cell-type (composed of normal and trisomic cells), tissue mosaic trisomy (tissues affected by the chromosome 21 trisomy) and chimerism (where two fertilized eggs are fused together into a whole giving rise to a single organism; where either or both eggs are affected by mosaicism)²³.

Chromosome 21, whether in a Down syndrome individual or not, encodes over 350 genes. Individuals who are trisomic have elevated transcript levels of the more than 350 genes on the chromosome are primarily responsible, it is likely that multiple genetic mechanisms underlie the numerous ways in which development and function diverge in individuals with trisomy 21 compared to euploid individuals²⁰.

1.2 Morphological features

Each DS child possesses a unique set of phenotypic traits, as will be discussed in the section about genetics, however most children have similar morphological features. On physical examination, DS patients have characteristic craniofacial findings (demonstrated in figures 2 a-c), such as: flat occiput and flattened facial appearance, brachycephaly, epicanthal folds, flat nasal bridge, upward-slanting palpebral features, Brushfield spots, small nose and mouth, protruding tongue, small and dysplastic ears, generous nuchal skin, diastasis recti, single transverse palmar crease, short fifth finger with clinodactyly, wide space between the first and second toes (see table 1 for detailed information). In addition to these features, DS individuals may exhibit shortened extremities, short broad hands, with short fifth middle phalanx and single transverse palmar crease (in about 60% of patients), joint hyperextensibility or hyperflexibility, neuromuscular hypotonia, dry skin, premature aging, wide range of intelligences quotients (IQs) and congenital heart defect.

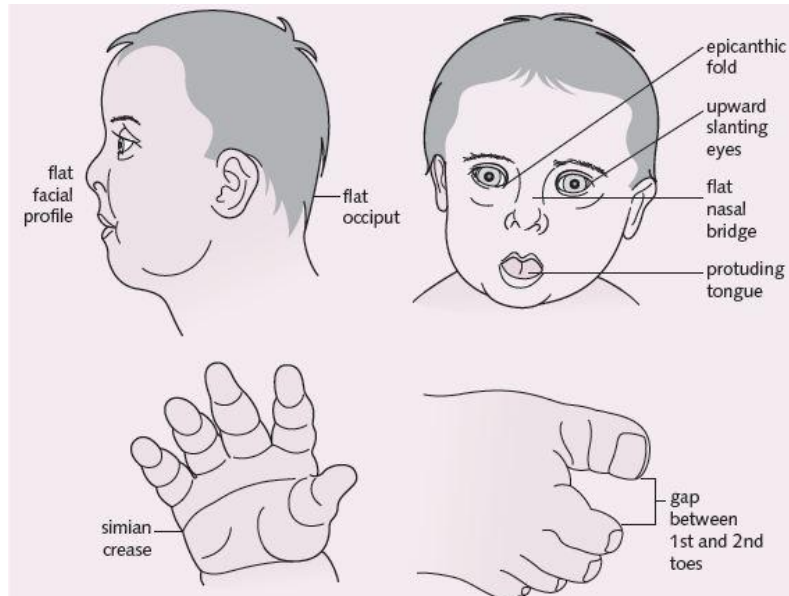


Figure 2a. Sketch of craniofacial findings in Down syndrome.



Figure 2b. Photograph of a girl with Down syndrome [note: slanted palpebral fissures, flat nasal bridge]

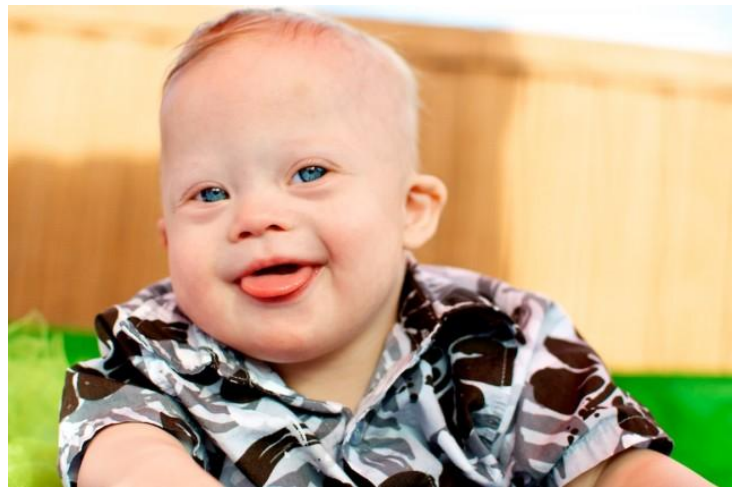

Figure 2c. Photograph of a boy with Down syndrome [note: small dysplastic ears and protruding tongue]

Table 1. Dysmorphic features in *Down* syndrome according to *sadowska* et al.²¹

Body part	Morphological feature
Head	Small sized, anterior-posterior shortened, occipital region flattened and hair that is smooth, sparse and straight.
Face	Flat, round and slightly widened.
Eyes	Narrow and slanted palpebral fissures, epicanthic fold, Brushfield spots on the iris (small white spots), hypertelorism and frequent vision defects (myopia, cataracts)
Nose	Small, flat, short, with a wide thimble and constricted nasal passages
Ears	Small, deformed, low-set, upper part of ear sometimes collapsed and narrowed auditory canals.
Mouth	Thick cracked lips, receding lower lip, protruding tongue, often geographic and flaccid jaw muscles along with the tongue that causes mouth to be open
Palate	Narrow and high-arched; gothic style
Teeth	Misshaped and abnormally apart.
Neck	Short, broad with a skin fold.
Limbs	Wide, short hands and feet, palmar and sandal crease, clinodactyly, syndactyly, short upper and lower limbs in proportion to the body.
Skin	Rough, dry, marbled, bright and irritant sensitive.

1.3 CNS and psychosomatic manifestations

The brain of a child with DS develops differently from a normal one, attaining a form of reduced in size and altered in configuration. Accumulating evidence shows that DS is characterized by numerous neurodevelopmental alterations among which reduction of neurogenesis, dendritic hypotrophy and connectivity alterations appear to play a particularly prominent role.¹⁰ Hypotonia seen in the newborn period is followed by developmental delay and mental retardation. In addition, all individuals with DS demonstrate the neuropathology of Alzheimer disease by age 30–40 years. The unavoidable hallmark of DS, intellectual disability, has heavy impact on families and society. The IQ score usually falls in the moderately to severely retarded range (IQ= 25-55) and mental age is rarely over 8 years. The IQ in DS is not constant during life but

decreases with age and an early deceleration occurs between the age of 6 months and 2 years, with future decline in adolescents. Children with DS exhibit incomplete and delayed acquisition of motor, linguistic, cognitive and adaptive functions, compared with developing children of the same mental age²².

In terms of behavior and psychiatric status, DS individuals have natural spontaneity, genuine warmth, cheerfulness, gentleness, patience, and tolerance. At least half of all children and adults with Down syndrome face a major mental health concern during their life span. The most common mental health concerns include: general anxiety, repetitive and obsessive-compulsive behavior; oppositional, impulsive and inattentive behaviors, such as attention-deficit hyperactive disorder; sleep related difficulties; depression; autism spectrum conditions; and neuropsychological problems characterized by progressive loss of cognitive skills. The pattern of mental health problems in these individuals vary depending on the age and developmental characteristics of the child or adult with Down syndrome.

1.4 Gastrointestinal abnormalities

Children and adults with DS will experience gastrointestinal (GI) symptoms from time to time such as vomiting, diarrhea, constipation, abdominal pain and discomfort that resolves with minimal or no intervention much as in others. However, they may develop structural and functional disorders of the GI tract and related structures more commonly. Structural problems may affect the gastrointestinal tract from the mouth to the anus but many conditions will occur in Down syndrome with similar frequency to other children. In saying that, esophageal, duodenal, and small bowel atresia or stenosis, annular pancreas causing small bowel obstruction, imperforated anus and Hirschsprung disease (affecting about 2% of those with Down syndrome) are more common than in the general population⁴, these may need to be surgically corrected at once in order to have a normal functioning intestinal tract. In addition, gastro-esophageal reflux should be suspected in a child who appears uncomfortable during or after feeding. Down children are prone to this because they spend less time in sitting position and muscle tone in the lower esophageal sphincter may be reduced thus allowing reflux.

Adults with DS are also prone to a wide range of gastrointestinal problems including reflux, obesity, constipation and diarrhea. Celiac disease which has been noted with prevalence of 5% in Down syndrome can present at any age. Symptoms in children and adults are protean and include growth failure, malaise, vomiting, abdominal distention, diarrhea and constipation. Unexplained anemia, iron and calcium deficiency, point to the diagnosis. Because of the strong association some have advocated screening all subjects using human tissue transglutaminase and or endomysial antibodies and if CD is diagnosed gluten free diet should be offered with a referral to a dietician¹¹.

1.5 Endocrine abnormalities

When it comes to hormone-producing organs and Down's syndrome it has been noted over the past 30 years with many publications have suggested an association between DS and thyroid gland disorders by showing altered levels of abnormal thyroxin (T4), triiodothyronine (T3) and/or thyroid stimulating hormone (TSH) levels. An evaluation of reported studies would suggest a life-time prevalence of approximately 25-30%. The prevalence of hypothyroidism, the lack of thyroid hormone, has been found to be greater than that of hyperthyroidism, at a ratio of 9% to 2% was proposed¹¹; as well as an increase in the prevalence of hormonal abnormalities there is also an increased prevalence of autoimmune thyroiditis. As mentioned above, hypothyroidism is the commonest form of thyroid disorder associated with Down syndrome. It may be either congenital (present at birth) or be acquired (occurring at any age after birth) most commonly in teens and early adulthood. Recognition of thyroid disorders (especially hypothyroidism), can be difficult; the person with DS is usually shorter in height, appears less active, has dry skin and fine hair, excess weight, bradycardia and mental impairment. These features are seen in hypothyroidism and therefore, make the early clinical diagnosis of hypothyroidism in individuals with Down syndrome difficult. So, it is recommended by specialists that all infants with Down syndrome be checked at birth, six months of age, one year of age, and once a year for thyroid function. Treatment consists of replacing thyroid hormones with synthetic ones such as thyroxin and treatment is usually needed for life.

1.6 Hematopoietic disorders

Up to 80%, 66%, and 34% of Down syndrome newborns have neutrophilia, thrombocytopenia, and polycythemia, respectively. These findings are usually referred collectively as hematological abnormalities in the newborn DS (HANDS). In general, hematological abnormalities in HANDS are mild, with a benign clinical course, that spontaneously resolves by 2 weeks of age.

Neutrophilia is mild (rarely exceeding $30,000/\mu\text{L}$) and is not associated with infection.

Thrombocytopenia is mild (majority with platelets counts $<150,000/\mu\text{L}$) and not associated with bleeding. Polycythemia is mild in most cases with only some exhibiting duskiess and cyanosis that correct with reduction/partial exchange transfusion.

Transient myeloproliferative Disorder (TMD) is a disease entity unique to DS newborns and is defined as the morphological detection of blasts in DS less than three months of age, occurs at a rate of 10% of all patients with Down syndrome. TMD is usually detected in the first week of life and spontaneously resolves by 3 months of age⁶. It is associated with neonatal death secondary to liver failure, heart failure, sepsis, hemorrhage, hyperviscosity, and disseminated intravascular coagulation in 11 to 52%. After resolution of TMD, approximately 13 to 29% develop acute megakaryocytic leukemia (AMKL) after 6 months of age. In addition Down syndrome is associated with a 10 to 20 times higher incidence of both acute lymphoid leukemia occurring throughout childhood, mainly greater than 4 years of age; and acute myeloid leukemia occurring between 6 months to 5 years.

1.7 Additional findings

Moreover, there are many health problems associated with Down syndrome. Sixty to eighty percent of children with DS have hearing deficits and should be seen by an otolaryngologist to determine the severity of hearing loss. During childhood problems with sight might become visible, for example, 3 percent of those patient have cataracts that need to be removed surgically. Other ocular conditions such as cross-eye, near-sightedness, far-sightedness are also frequently encountered. Conditions that would need special attention are skeletal abnormalities, including patients with kneecap subluxation, hip dislocation and atlanto-axial instability; the latter

condition occurs when C1 and C2 bones of the cervical vertebra are not well aligned because of the presence of loose ligaments. Most of these patients however, do not have any symptoms, except for the one to two percent that require surgical correction.

2. Congenital heart defects (CHD)

Children with Down syndrome have about a 40 to 50% incidence of being born with a structural problem of the heart. The defects can involve the walls of the heart, the valves of the heart, and the veins and arteries coming in and out of the heart, respectively. The blood flow can slow down, go in the wrong direction or to the wrong place, or be blocked completely. Therefore, CHD contribute significantly to the morbidity and mortality of children with Down's syndrome, who as a consequence may develop congestive heart failure, pulmonary vascular disease, pneumonia, or failure to thrive.

In most of the European countries, Sudan, Turkey and the USA, atrioventricular septal defect (AVSD) is the most common cardiac defect with an incidence of 48%, second to that is ventricular septal defect (VSD) at rate of 35%, secundum atrial septal defect (ASD) with 8% occurrence and patent ductus arteriosus (PDA) at a rate of 7%⁹.

2.1 Normal heart anatomy

A human heart, being it a child's heart or adult heart, is a muscular organ about the size of a closed fist that functions as the body's circulatory pump. It is made up of 4 chambers, two atria and two ventricles (as demonstrated in figure 3 below). De-oxygenated blood returns to the right side of the heart via the venous circulation. It is pumped into the right ventricle and then to the lungs where carbon dioxide is released and oxygen is absorbed. The oxygenated blood then flows back to the left side of the heart into the left atria, then into the left ventricle from where it is pumped into the aorta and arterial circulation to provide the body with oxygen. The pressure created in the arteries by the contraction of the left ventricle is the systolic blood pressure. Once the left ventricle has fully contracted it begins to relax and refill with blood from the left atria. The pressure in the arteries falls whilst the ventricle refills. This is the diastolic blood pressure.

The atrioventricular septum completely separates the two sides of the heart (as shown in figure 2 below). Unless there is a septal defect the two sides of the heart never directly communicate. Blood flows from right side to the left side of the heart via the lungs only. However the chambers themselves work together. The two atria contact simultaneously (during diastolic phase), and the two ventricles contract simultaneously (during systolic phase). The atria are separated from the ventricles by atrioventricular valves, allowing blood to flow in one direction that is, from the atria to the ventricles. The AV valve on the right side is called the tricuspid valve because it is made of three cusps that allows blood to pass through and prevent regurgitation. Similarly on the left side the AV valve is called the bicuspid valve because it has two cusps.

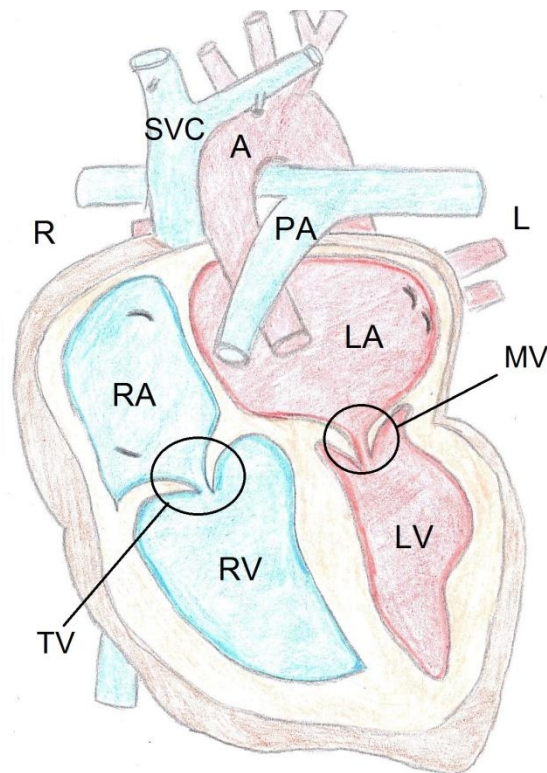


Figure 3. Anatomical heart sketch, coronal plane.

[R: right; L: left; RA: right atria; LA: left atria; RV: right ventricle; LV: left ventricle; A: aorta; PA: pulmonary artery; SVC: superior vena cava; TV: tricuspid valve; MV: mitral valve]

2.2 Atrioventricular septal defect

Atrioventricular septal defect is the most common heart defect, present in 48% of all DS patients. It refers to a broad spectrum of malformations characterized by a deficiency of the atrioventricular septum and abnormalities of the atrioventricular valves. These malformations are presumed to result from failure of fusion of the endocardial cushions in the central portion of the heart, causing a lesion that involves the atrial and ventricular septum, as well as the anterior mitral and septal tricuspid valve leaflets (as shown in figure 4 below). In complete AV canal defect there is a combined deficiency of the atrial and ventricular septum associated with a common AV orifice rather than separate tricuspid and mitral valves. When this common AV valve opens predominantly towards one ventricle or the other, an unbalanced AV canal forms. If the atrioventricular valve predominantly opens into the morphological left ventricle, the defect is termed a left ventricular type (or LV-dominant AV septal defect). If the common AV valve opens predominantly into the morphological right ventricle, the defect is termed a right ventricular type (or RV-dominant AV septal defect). The degree of unbalance varies from mildly unbalanced with 2 nearly normal sized ventricles and therefore termed balanced atrioventricular septal defect, to severely unbalanced leaving one of the ventricles hypoplastic, even rudimentary, and its associated outflow tract with essentially single-ventricle physiology. RV-dominant AV septal defects occur more commonly than the LV-dominant AV septal defects.

Complete AV canal defects produce severe pathophysiological changes, because the large intracardiac communication and significant AV valve regurgitation contribute to ventricular volume loading and pulmonary hypertension. Children with AV canal defect develop signs of chronic heart failure (CHF) within the first few months of life. On physical examination there may be a right ventricular heave and a systolic murmur. Chest radiography will be consistent with CHF, and the electrocardiogram (ECG) will demonstrate right ventricular hypertrophy with prolonged PR interval. A two-dimensional echocardiography with color-flow mapping is confirmatory, but cardiac cauterization should be performed to define the status of the pulmonary vasculature, with a pulmonary vascular resistance (PVR) greater than eight Woods units indicates inoperability.

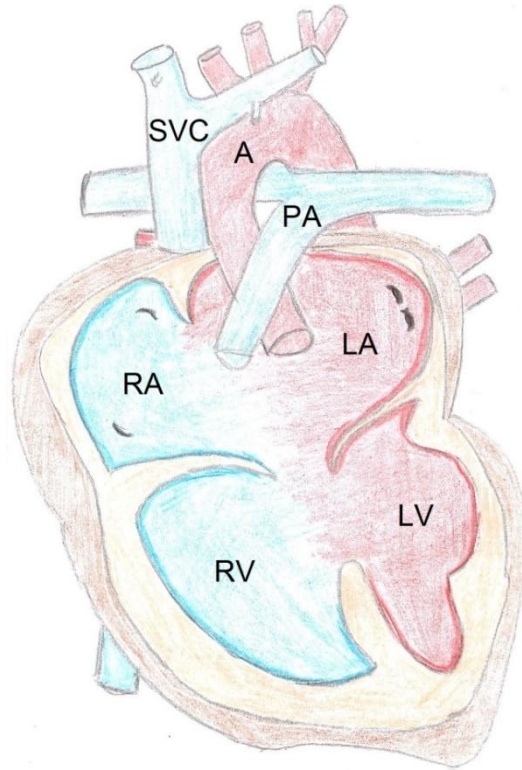


Figure 4. Atrioventricular septal defect sketch, coronal plane.

[R: right; L: left; RA: right atria; LA: left atria; RV: right ventricle; LV: left ventricle; A: aorta; PA: pulmonary artery; SVC: superior vena cava]

The management of patients with AV canal defects can be especially challenging. They should be operated by the first year of life to prevent irreversible changes in the pulmonary circulation. The defect is repaired by patch closure of the VSD, separating the common AV valve into tricuspid and mitral components and suspending the neovalves from the top of the VSD patch, and closing the ASD. With unbalanced defect, the operation should be carried out in philosophy of single ventricle, which means, first by banding of the pulmonary artery, then Glenn and finally total cavopulmonary connection (mostly extracardiac Fontan operation). It is not uncommon to have additional problems with AV canal defect, depending on whether it is left or right ventricle obstruction that might significantly influence hemodynamics. For example, a common AV canal with pulmonary stenosis (so called tetralogy of Fallot); also there are types that have subaortic or other left ventricle obstructive defects. Those with decreased pulmonary artery flow (in terms of TOF type) can benefit from aortopulmonary anastomosis (B-T shunt). Those with unobstructed

blood flow to the lungs, suffering from pulmonary overflow und pulmonary hypertension can benefit from pulmonary artery banding.

Pulmonary artery banding (PAB) is a technique of palliative surgical therapy used by congenital heart surgeons as a staged approach to operative correction of congenital heart defects, it is a surgical intervention for infants born with cardiac defects characterized by left-to-right shunting and pulmonary over circulation. Although the use of pulmonary artery banding has recently significantly decreased, it continues to maintain a therapeutic role in certain subsets of patients with congenital heart disease. The primary objective of performing pulmonary artery banding is to reduce excessive pulmonary blood flow and protect the pulmonary vasculature from hypertrophy and irreversible (fixed) pulmonary hypertension. This is done by putting a band on the main pulmonary artery, making an artificial stenosis that lowers the pulmonary flow and so prevent pulmonary hypertension.

The prognosis of patients with complete AVSD is poor with mortality rate of 3 to 13%. The most common encountered postoperative complications are complete heart block (1 to 2%). Right bundle branch block (22%), arrhythmias (11%), right ventricular obstructive tract (11%) and severe mitral valve regurgitation (13 to 24%).

2.3 Ventricular septal defect

Ventricular septal defect refers to a hole between the left ventricle and the right ventricle, as shown in figure 5 below. These defects occur in 35% of Down syndrome patients. VSDs vary in size from 3 to 4mm to more than 3cm, and are classified into four types based on their location in the ventricular septum: perimembraneous, AV canal (so called – inlet VSD), outlet or supracristal, and muscular.

Large VSDs allow free flow of blood from the left ventricle to the right ventricle, elevating the right ventricular pressures to the same level as systemic pressures. Consequently, the pulmonary-to-systemic flow ratio is inversely dependent on the ratio of PVR to systemic vascular resistance (SVR). Large VSD produce a large increase in pulmonary blood flow, and the afflicted infant will present with symptoms of CHF; left untreated, these defects will cause pulmonary

hypertension with a corresponding increase in pulmonary vascular resistance. This will lead to a reversal of flow (a right-to-left shunt), which is known as Eisenmenger's syndrome; for that pulmonary banding procedure is an excellent option as early palliative surgical therapy to prevent pulmonary hypertension and consequently Eisenmenger's syndrome. In contrast to small VSDs which offer significant resistance to the passage of blood across the defect, and therefore, right ventricular pressure is either normal or only minimally elevated, making these defects generally asymptomatic because of few physiological consequences. However, a long-term risk of endocarditis, because endocardial damage from the jet of blood through the defect may serve as a possible nidus for colonization.

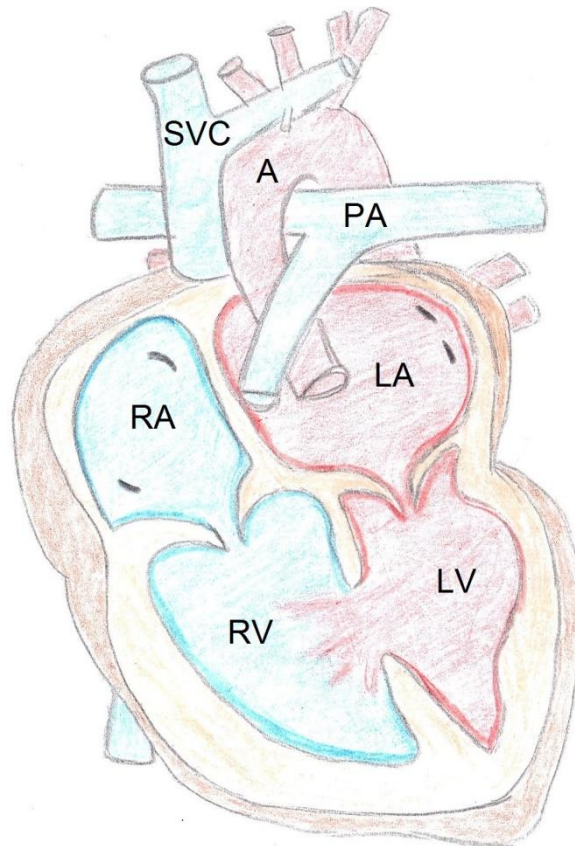


Figure 5. Ventricular septal defect sketch, coronal view.

[R: right; L: left; RA: right atria; LA: left atria; RV: right ventricle; LV: left ventricle; A: aorta; PA: pulmonary artery; SVC: superior vena cava]

As mentioned above, large VSDs will present with severe CHF and frequent respiratory tract infections. Those with Eisenmenger's syndrome may be deceptively asymptomatic until frank cyanosis develops. The chest radiography will show cardiomegaly and pulmonary over-circulation and the ECG will show signs of left ventricular or biventricular hypertrophy. Echocardiography provides definitive diagnosis, and can estimate the degree of shunting as well as pulmonary arterial pressures.

VSDs may close or narrow spontaneously, and the probability of closure is inversely related to the age at which the defect is observed. Thus, infants at 1 month of age have 80% incidence of spontaneous closure, whereas a child at 12 months of age has only a 25% chance of closure³. This has important impact on operative decision making, because a small or moderate-size VSD may be observed for a period of time in the absence of symptoms. Large defects and those in severely symptomatic neonates should be repaired during infancy to relieve the symptoms and because irreversible changes in pulmonary vascular resistance may develop during the first year of life. The used technique to repair a VSD is a patch repair. Even in very small infants, closure of VSD can be safely performed with hospital mortality near 0%.

2.4 Atrial septal defect

Atrial septal defect (ASD) is defined as an opening in the inter-atrial septum that enables the mixing of blood from the systemic venous and pulmonary venous circulations, as shown in figure 6 below. In Down's syndrome this heart defect is seen in 8% of individuals. ASDs result in an increase in pulmonary blood flow secondary to left-to-right shunting through the defect. The direction of the intracardiac shunt is predominantly determined by the compliance of the respective ventricles. In utero, the distensibility of the right and left ventricles is equal, but postnatally the LV becomes less compliant than the RV. This shift occurs because the resistance of the downstream vascular beds changes after birth. The pulmonary vascular resistance (PVR) falls with the infants' first breath, decreasing RV pressure, whereas the systemic vascular resistance rises dramatically, increasing the LV pressure. This increase in pressure creates a thicker muscle mass which offers a greater resistance to diastolic filling than does the RV; thus, the majority of flow through ASD occurs from left to right. The greater the volume of blood

returning to the right atrium causes volume overload in the RV, but because of its lower muscle mass and low-resistance output, it easily distends to accommodate this load.

The long-term consequence of RV volume overload includes hypertrophy with elevated RV end-diastolic pressure and a relative pulmonary stenosis across the pulmonary valve, because it can't accommodate the increase RV flow. This resistance at the level of the pulmonary valve then contributes further pressure load on the RV, which accelerates the RV hypertrophy. The ability of RV to recover normal function is related to the duration of chronic overload, because undergoing ASD closure before age 10 years have a better likelihood of achieving normal RV function in the postoperative period¹⁶.

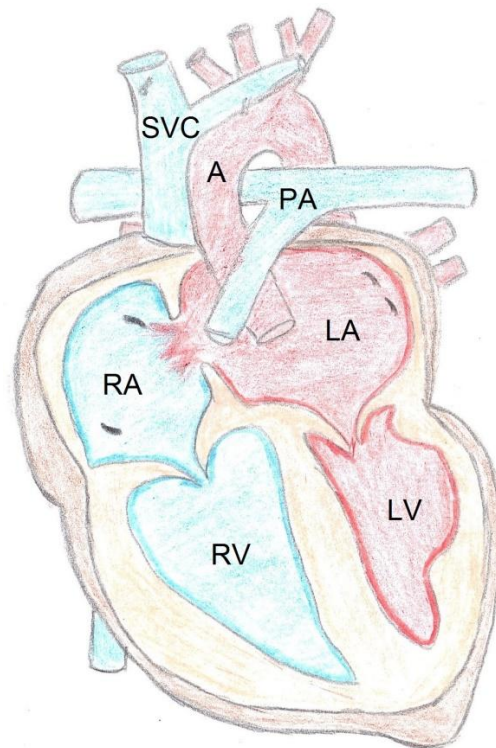


Figure 6. Atrial septal defect sketch, coronal plane.

[R: right; L: left; RA: right atria; LA: left atria; RV: right ventricle; LV: left ventricle; A: aorta; PA: pulmonary artery; SVC: superior vena cava]

Patient with ASD are usually asymptomatic with few physical findings. Auscultation may reveal prominence of the first heart sound with fixed splitting of the second heart sound; resulting from the relatively fixed left-to-right shunt throughout all phases of the cardiac cycle. Chest radiographs in a patient with ASD may show evidence of increase pulmonary vascularity, with

prominent hilar markings and cardiomegaly. The electrocardiogram shows right axis deviation with an incomplete bundle-branch block. Diagnosis is clarified with echocardiogram and the use of color flow mapping facilitated the understanding of the physiologic derangements created by the defect.

In general, ASDs close when patients reach 4 to 5 years of age; if that doesn't happen then surgery is an option, either by primary repair or by insertion of a patch that is sutured to the rim of the defect or by device closure. Mortality rate of surgically repaired ASD is near zero percent. Early repairs in neonates weighing less than 1000 grams have been increasingly reported to with excellent results¹⁹.

Besides ostium secundum atrial septal defect, another DS characteristic is ostium primum ASD is located in the most anterior and inferior aspect of the atrial septum just above the valves and is the simplest form of AV septal defect. Children with smaller ostium primum ASD and little or no mitral regurgitation or left ventricle to right atrium shunting are usually asymptomatic. Those with significant pulmonary over circulation and/or significant mitral regurgitation tend to present in infancy with congestive heart failure. Tachypnea and tachycardia are noted at rest and are exacerbated with crying or exertion. Feeding is accompanied by dyspnea, diaphoresis, and an increased work of breathing. The combination of feeding difficulties and increased metabolic demands results in failure to thrive, which may be severe and/or intractable.

The cardiac examination in isolated ostium primum ASDs or partial AV canal defects with minimal mitral regurgitation is similar to that in other forms of ASDs. Patients typically have an increased right ventricular impulse secondary to volume overload. The first heart sound is normal. The second heart sound is fixed or at least widely split. A systolic ejection murmur is heard loudest at the upper left sternal border, with radiation to both lung fields. A click is not present. A tricuspid mid-diastolic rumble is present in children with larger shunts (pulmonary-to-systemic flow ratio > 2:1) and is appreciated at the lower left sternal border.

Unlike ostium secundum ASD, the ostium primum ASD is not amenable to device closure in the cardiac catheterization laboratory. The device is unable to be adequately seated secondary to an inadequate inferior rim of atrial septal tissue and the proximity of the defect to the AV valves. Therefore, definitive management of hemodynamically significant ASD is operative surgery, it is

done electively between ages 2 and 5 years. Occasionally, repair (done through a right atrial incision) may be recommended at an earlier age because of significant congestive heart failure or failure to thrive, especially if associated with significant mitral valve regurgitation.

2.5 Persistent patent ductus arteriosus

The ductus arteriosus is derived from the sixth aortic arch and normally extends from the main or left pulmonary artery (PA) to the upper descending thoracic aorta, distal to the left subclavian artery. It is the least common structural defect to occur in DS at a rate of only 7%. In normal fetal cardiovascular system, ductal flow is considerable (about 60% of the combined ventricular output), and is directed exclusively from the PA to the aorta¹⁷. During the fetal period the ductus blood flow is maximally maintained by locally produced and circulating prostaglandin E₂ (PGE₂) and PGI₂; they cause relaxation of the ductal musculature. At birth, the increase in pulmonary blood flow metabolizes these prostaglandin products, and absence of the placenta removes an important source of them, resulting in a marked decrease in these ductal-relaxing substances. In addition, release of histamines, catecholamines, bradykinin, and acetylcholine all promote ductal contraction. Despite all of these actions, the rise in oxygen tension in the fetal blood is the main stimulus causing smooth muscle contraction and ductal closure within 24 to 48 hours postnatally. Anatomical closure by fibrosis produces the ligamentum arteriosus connecting the PA to the aorta (as demonstrated in figure 7).

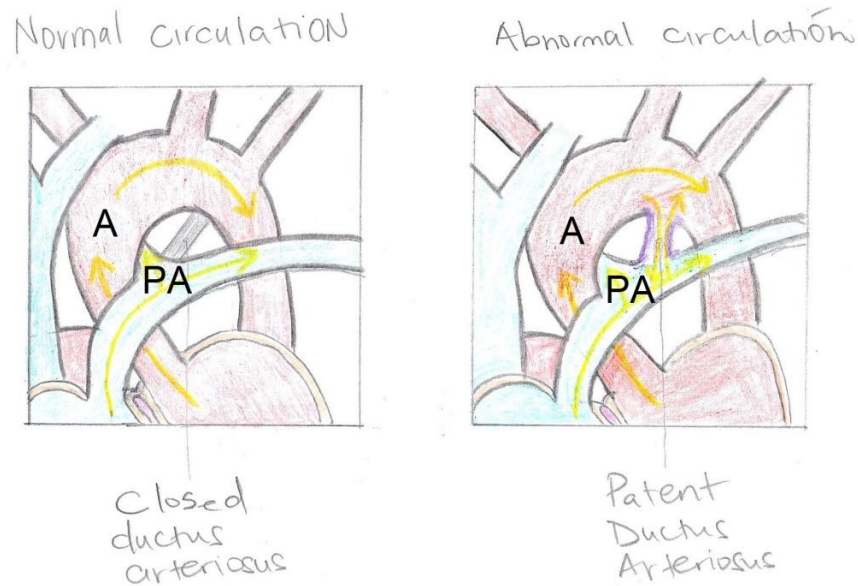


Figure 7. Patent ductus arteriosus, sketch.

[Yellow arrows indicate the direction of blood flow, A: aorta; PA: pulmonary artery]

PDA is not a benign entity, although prolonged survival has been reported. Estimated death rate for infants with isolated untreated PDA is approximately 30%⁵. The leading cause of death is CHF, with respiratory infection as a secondary cause. After birth, in an otherwise normal cardiovascular system, a PDA results in a left-to-right shunt that depends on both the size of the ductal lumen and its total length. As the pulmonary vascular resistance falls 16 to 18 weeks postnatal, the shunt will increase, and its flow will ultimately be determined by the relative resistances of pulmonary and systemic circulations.

The hemodynamic consequences of the ductal shunt are left ventricular overload with increased LA and PA pressures, and right ventricular strain from the augmented afterload. These changes cause hormonal disturbances in the body by increasing the sympathetic discharge, tachycardia, tachypnea, and ventricular hypertrophy. The diastolic shunt results in lower aortic diastolic pressure and increase the potential for myocardial ischemia and under perfusion of other systemic organs, while the increase pulmonary flow leads to increased work of breathing and decreased gas exchange.

Physical examination of the afflicted infant will reveal evidence of a hyperdynamic circulation with a widened pulse pressure and a hyperactive precordium. Auscultation demonstrates a systolic or continuous murmur, most commonly known as machinery murmur. Cyanosis is not present in uncomplicated isolated PDA. Chest radiography may reveal increase pulmonary vascularity or cardiomegaly, and the ECG may show LV strain, LA enlargement, and possibly RV hypertrophy.

The presence of persistent PDA is sufficient indication for closure because of the high mortality and risk of endocarditis. In older patients who already show signs of pulmonary hypertension, closure may not improve symptoms and is associated with much higher mortality. In premature infants, aggressive intervention with indomethacin or ibuprofen to achieve early closure of the PDA is beneficial unless contraindications such as necrotizing enterocolitis or renal insufficiency¹². Term infants, however, are generally unresponsive to pharmacological treatment and therefore, unfortunately need to undergo mechanical closure once the diagnosis has been established. This is accomplished either surgically or with a catheter-based therapy. In premature infants the surgical mortality is very low, although hospital death due to other complications is reportedly high. In older infants and children, mortality is less than 1%.

Other heart defects that can be found in Down syndrome patients is Tetralogy of Fallot, which is classically understood to involve four anatomical abnormalities of the heart (a pulmonary infundibular stenosis- mostly caused by overgrowth of the heart muscle; over-riding aorta- an aortic valve with biventricular connection, situated above the VSD and connected to both the right and left ventricle; VSD and a right ventricular hypertrophy- which increases further due to the right ventricular outflow tract obstruction). It is the most common cyanotic heart defect and the most common cause of blue baby syndrome. TOF is usually right-to-left shunt, in which higher resistance to right ventricle outflow results in more severe cyanosis symptoms. TOF is surgically treated by Blalock-Thomas-Taussig shunt. Patients who have undergone total surgical repair of tetralogy of Fallot have improved hemodynamics and often have good to excellent cardiac function after the operation with some to no exercise intolerance (New York Heart Association Class I-II).

3. Antenatal screening for Down's and its importance

Over the past 20 years, new technology has improved the methods of detection of fetal abnormalities, including Down syndrome. The first prenatal diagnosis of DS was made in 1968, and screening woman on the basis of advanced maternal age with amniocentesis was gradually introduced into the medical practice all around the world. Low maternal serum alpha-fetoprotein levels were associated with Down syndrome in 1983. Later, elevated human chorionic gonadotropin and low unconjugated estriol levels were found to be markers for Down syndrome. By 1988, use of the three biochemical markers together with maternal age, had been accepted as a method of prenatal screening for DS in the general population. Currently in the general population, maternal age, ultrasound findings, and maternal serum markers (in the first or second trimester) are used alone or in combination for risk calculations⁸.

3.1 Ultrasonography

With prenatal ultrasonography, trisomy 21 may be diagnosed in the second and third trimester of pregnancy. Suggestive prenatal ultrasound findings may be followed with amniocentesis and fetal chromosome analysis. Antenatal ultrasonography may reveal the following:

- Soft markers seen in the second trimester for Down syndrome include the absence or hypoplastic nasal bone (observed in 43-62% of trisomy 21 fetuses, compare with 0.5-1.2% of normal fetuses), thickened nuchal fold, echogenic bowel (seen in 15% of the trisomic fetuses in comparison to 0.6% of normal fetuses), shortened long bones (are associated with an increased risk of chromosomal abnormalities), and pyelectasis (in 17%).
- Other ultrasonographic abnormalities include cystic hygroma, duodenal atresia or stenosis (double-bubble sign), cardiac defects (endocardial cushion defect with ASD and VSD defects, abnormal mitral and tricuspid valves).

Even with these changes found while performing and ultrasonographic examination, they should not be relied on as the primary method of diagnosing Down syndrome since these features could be part of other chromosomal abnormalities, other syndromes or even present as isolated anomalies. The diagnosis can even be missed in affected families.

3.2 Maternal serum biochemical markers

Early during pregnancy, all women are offered screening of several blood markers that can indicate increased fetal risk for certain genetic diseases and birth defects. Between 15 and 21 weeks' of gestation, a maternal serum sample is screened for alpha-fetoprotein (AFP), estriol and human chorionic gonadotropin (hCG).

A decreased level of AFP was associated with Down syndrome. AFP level combined with maternal age, along with additional markers found in maternal serum (estriol and hCG), provide a sensitive serum screening test. Low levels of maternal serum AFP and estriol, along with high levels of hCG suggest an increased risk of Down syndrome. Inclusion of a fourth marker, inhibin-A, in the maternal serum screen further improves the accuracy in predicting risk of DS¹.

The baby's risk is then calculated based upon the levels of the three (or four) markers measured plus additional factors such as woman's age, weight, multiple pregnancies, race and whether she had diabetes requiring insulin treatment. Since this is a screening test, abnormal test result only indicates an increased risk and does not diagnose a birth defect or genetic disease. Additional tests would need to be performed to give a definitive diagnosis.

3.3 Invasive diagnostic tests

Invasive procedures are performed on fetus or embryo before it is born. The aim is to detect chromosomal abnormalities, genetic diseases and other conditions, to enable timely medical or surgical treatment of a condition before or after birth, to give parents the option of abortion (not by suggesting abortion but by informing them about the possible consequences that are expected with DS newborns and giving them a way "out"), to give parents the chance to "prepare"

psychologically, socially, financially, and medically for a baby with a health problem or disability, or for the likelihood of stillbirth. Invasive method involves a probe or needles being inserted into the uterus, the following procedures are options to be done to give a definitive diagnosis of Down syndrome:

- Amniocentesis, routinely performed at 14-16 weeks' gestation, remains the criterion standard. Testing for chromosomal disorders is 99.5% accurate; rarely results can be inaccurate if maternal-cell contamination occurs. The associated risk of fetal loss is very small, 1:200-300.
- Chorionic villus sampling is performed at 10-13 weeks' gestation; earlier testing is thought to be associated with a 0.5-1% risk of fetal loss after the procedure. The accuracy of chorionic villus sampling (96-98%) is less than that of mid-trimester amniocentesis, because of confined placental mosaicism and maternal-cell contamination.
- Percutaneous umbilical blood sampling is approximately 95% successful in obtaining blood sample for cytogenetic testing. The fetal loss rate is 3.25%.

4. Down syndrome's impact on society

Surprisingly the main finding of research studies (from Western or European cultures, in the US, Australia and the UK) is normality, the majority of families with children with Down syndrome lead ordinary lives. This does not mean that families do not have additional demands and challenges to cope with. It means that at least 65-70% of families find the resources to meet the additional needs of their child or adult with Down syndrome and lead happy and ordinary family lives themselves⁷. They have reported less stress in the family than families with similar levels of intellectual disability of different cause; there may be several reasons for this, such as early diagnosis and support, information which helps parents to predict the future, the sociable and warm nature of most children and adults with Down syndrome and few behavioral problems than in other comparison groups.

The other 30-35% of families show signs of considerable stress or distress, for variety of reasons. Brothers, sisters and the child with DS are more likely to show behavioral difficulties like with any other family who has a disabled child.

Social network of a family with a Down's child could have a very strong positive source of support, provided that they are positive about the child with Down syndrome and welcome them into their homes or activities. The beliefs that people have about disability and Down syndrome will influence their attitudes and this will apply to family member, friends and contacts in shops and public transport. More often you will notice that parents educate those around them, including some service providers, that's why it is really important to raise awareness about DS.

Many families report the benefit of joining parent support groups for Down syndrome associations and meeting other families with children with DS. It has been reported that the most significant emotional and practical help that they received came from other parents.

In summary the discernible differences concerning the medical condition and the developmental level between Down syndrome children are caused, among other things, by the different medical treatments and the support of each child's environment. Multi-systemic support (medical, educational, environmental) can bring many improvements in the children's function, allowing them to extract their maximum potential and increases their chances to live a rich, independent community life.

5. Advances and future prospects in Down's syndrome

By now it is clear that an additional copy or partial copy of chromosome 21 is the cause of Down syndrome. It is proposed that this trisomy results in the increased expression of many of the genes encoded on this chromosome. The imbalance in expression of chromosome 21 genes and the non-chromosome 21 genes is hypothesized to result in many phenotypes that characterize DS. Thus to understand this syndrome, it is crucial both to understand the genomic content of chromosome 21 and to evaluate how the expression levels of these genes are altered by the presence of the third copy of this chromosome using mice models with the same chromosomal abnormality that causes down syndrome.

Recent interest in therapy for people with DS has focused on pharmacological treatment to enhance cognition. A number of compounds have been shown to improve learning in mouse models with trisomy 21. These compounds reduce gamma-aminobutyric acid-mediated inhibition in the hippocampus and are proposed to improve cognition by releasing normal learning from excess inhibition.

These recent breakthroughs in understanding this trisomy has illustrated that research efforts in this field are making significant strides to understand and to develop treatments for the debilitating aspects of the syndrome.

Therefore, understanding the syndrome goes beyond just knowing its etiology and epidemiology, scientists are trying to prevent the many life threatening complications that could arise from the primary disabilities and defects that are associated with and are the direct consequence of the additional copy of chromosome 21 by testing different hypotheses concerning the underlying genetic and molecular basis of this trisomy and so, to improve quality of life as well as life expectancy in those individuals

6. Conclusion

Down syndrome is a condition in which there is excess genetic material. This genetic addition, which is in fact an excess chromosome 21 (all or part of it, in all or part of the body cells), causes physical and cognitive delays connected with the syndrome. Down syndrome is the most prevalent genetic disorder of all, and its prevalence is the same worldwide, across all races and sexes.

Patients have typical physical and mental characteristics, but only seldom all of them or even most of them are found in one single person. If we study the character of children with the syndrome, we will find they have a pleasant and convenient temperament and a special character. They are friendly, sensitive and have a sharp and developed emotional intelligence. These traits assist them in fitting in as a part of society and the community rather successfully.

Forty to fifty percent of Down syndrome patients are born with a structurally defective heart, (ASD, VSD, AV canal defect, PDA and TOF), ranging from simple asymptomatic heart defects

to complex life threatening defects that have to be managed during the first year of life to prevent irreversible consequences, such as pulmonary hypertension and congestive heart failure. Heart transplantation is reserved as last resort for those who surgery is not pliable and for those with congestive heart failure.

Fifty years after the discovery of the origin of Trisomy 21, people with this disorder continue to suffer the consequences of an extra copy of the chromosome. Compromised well-being and the presence of cardiac disorders and other health problems, including cognitive dysfunction, place these people outside of the mainstream, even in highly advanced cultures. However, recent advances are showing that it may be possible soon to decipher the underlying genetic and molecular bases for their disability and for creating effective treatments. Continued and increasing investments in research on the genetic and molecular basis of Trisomy 21 promise to transform the lives of these individuals and the communities in which they live; but until that goal is reached, we should consider and increase awareness of DS by prenatal screening, educating, and recognizing the inevitable disabling intellectual disability and life threatening conditions like cardiac defects, which when left untreated is the major cause of death by 1 year of age in those patients.

Acknowledgment

Firstly, I would like to express my sincere gratitude to my mentor Assistant Professor Dr. sc. Daniel Dilber for the continuous support of my M.D study and related research, for his patience, motivation, and immense knowledge. His guidance helped me in all the time of research and writing of this thesis. I could not have imagined having a better advisor and mentor for my M.D study.

Besides my mentor, I would like to thank my friends and work colleges, for their insightful comments and encouragement, but also for the hard questions which incited me to widen my knowledge from various perspectives and to all the people who have crossed my path during the past 6 years and have contributed to my expanding knowledge.

Last but not the least, I would like to thank my extended family, especially my mum and dad, my two brothers and sister for supporting me spiritually, mentally and physically throughout the six years of my M.D studies and during the writing of my thesis.

References

1. Akbas S, Özben T, Alper Ö, Ugur A, Yücel G, Lüleci G. Maternal Serum Screening for Down Syndrome, Open Neural Tube Defects and Trisomy 18. *Clinical Chemistry and Laboratory Medicine*. 2001; 39(6).
2. American College of Obstetricians and Gynecologists (ACOG). *Your Pregnancy and Birth*, 4th ed. Washington, DC: ACOG, 2005.
3. Brunicaudi F, Schwartz S. Schwartz's principles of surgery. 9th ed. New York: McGraw-Hill, Health Pub. Division; 2010; 620-621.
4. Buchin PJ, Levy JS, Schullinger JN. Down's syndrome and the gastrointestinal tract. *J Clin Gastroenterol* 1986; 8:111-14.
5. Campbell M. Natural history of persistent ductus arteriosus. *Heart*. 1968; 30(1):4-13.
6. Choi J. Hematopoietic Disorders in Down Syndrome. *Int J Clin Exp Pathol*. 2008; 1:387-395.
7. Cunningham C. Families of children with Down syndrome. *Down Syndrome Research and Practice*. 1996; 4(3):87-95.
8. Dreux S, Olivier C, Dupont J, Leporrier N, Oury J, Muller F. Maternal serum screening in cases of mosaic and translocation Down syndrome. *Prenatal Diagnosis*. 2008; 28(8):699-703.
9. Elmagrpy, Z. et al. "Down Syndrome And Congenital Heart Disease: Why The Regional Difference As Observed In The Libyan Experience?". *Cardiovascular Journal of Africa* 22.6 (2011): 306-309.
10. Guidi S, Bonasoni P, Ceccarelli C, Santini D, Gualtieri F, Ciani E et al. RESEARCH ARTICLE: Neurogenesis Impairment and Increased Cell Death Reduce Total Neuron Number in the Hippocampal Region of Fetuses with Down Syndrome. *Brain Pathology*. 2007; 18(2):180-197.
11. Holmes G. Gastrointestinal disorders in Down syndrome. 2014 ; 7(1):6-8.

12. Itabashi K, Ohno T, Nishida H. Indomethacin responsiveness of patent ductus arteriosus and renal abnormalities in preterm infants treated with indomethacin. *The Journal of Pediatrics*. 2003; 143(2):203-207.
13. J M. Down syndrome--genetic and nutritional aspects of accompanying disorders. - PubMed - NCBI [Internet]. Ncbi.nlm.nih.gov. 2016 [cited 12 April 2016]. Available from: <http://www.ncbi.nlm.nih.gov/pubmed/26400113>
14. Kinnell H, Gibbs N, Teale J, Smith J. Thyroid dysfunction in institutionalized Down's syndrome adults. *Psychological Medicine*. 1987; 17(02):387.
15. Kumar, Vinay, and Stanley L Robbins, 2007. *Genetics and Pediatric Diseases. Robbins Basic Pathology*. Vinay Kumar [et al.]. 8th ed. Philadelphia, PA: Saunders/Elsevier. Print.
16. Liberthson R, Boucher C, Strauss H, Dinsmore R, Mckusick K, Pohost G. Right ventricular function in adult atrial septal defect. *The American Journal of Cardiology*. 1981; 47(1):56-60.
17. McElhinney D, Petrossian E, Tworetzky W, Silverman N, Hanley F. Issues and outcomes in the management of supraaortic stenosis. *The Annals of Thoracic Surgery*. 2000; 69(2):562-567.
18. O'Neill KL., Shults J., Stallings VA., Stettler N.: Child-feeding practices in children with Down syndrome and their siblings. *Pediatr J* 2005; 146:234-238.
19. Reddy V. Cardiac Surgery for Premature and Low Birth Weight Neonates. *Seminars in Thoracic and Cardiovascular Surgery: Pediatric Cardiac Surgery Annual*. 2001; 4(1):271-276.
20. Roper R, Reeves R. Understanding the Basis for Down Syndrome Phenotypes. *PLoS Genetics*. 2006; 2(3):e50.
21. Sadowska L., Myslek-Prucnal M., Choiniska A. M., Mazurek A.: Diagnosis and treatment of children with Down syndrome in the light of their own and review of literature. *Przeg Med Uniw Rzesz* 2009; 1:8-30 (in Polish).

22. Stagni F, Giacomini A, Guidi S, Ciani E, Bartesaghi R. Timing of therapies for Down syndrome: the sooner, the better. *Front Behav Neurosci.* 2015; 9.
23. *Stratford B.:* Down's syndrome. Warszawa, Wyd Lek PZWL, 1993: 150-151.

Biography

Nouha Hinnawi is an M.D graduate from University of Zagreb, School of medicine. Nouha, born in Israel, was raised in a small town called Jaffa; started her medical studies journey in September 2010 and graduated in July 2016. During her medical studies she has immensely expanded her medical knowledge during her practical work in hospitals around Croatia and in various hospitals in her home town, while doing her summer clinical rotations, especially in the pediatric specialty. In the near future Nouha has decided to specialize in pediatric cardiac surgery.

*Obstacles are those frightful things you see
when you take your eyes off the goal
-Henry Ford.*