

# Vitamins in health and disease in children

---

**Tighnavard Mollasarai, Nina Sepideh**

**Master's thesis / Diplomski rad**

**2017**

*Degree Grantor / Ustanova koja je dodijelila akademski / stručni stupanj:* **University of Zagreb, School of Medicine / Sveučilište u Zagrebu, Medicinski fakultet**

*Permanent link / Trajna poveznica:* <https://um.nsk.hr/um:nbn:hr:105:166257>

*Rights / Prava:* [In copyright](#)/[Zaštićeno autorskim pravom.](#)

*Download date / Datum preuzimanja:* **2025-02-28**



*Repository / Repozitorij:*

[Dr Med - University of Zagreb School of Medicine Digital Repository](#)



**UNIVERSITY OF ZAGREB  
SCHOOL OF MEDICINE**

**Nina Sepideh Tighnavard Mollasarai**

**Vitamins in health and disease in children**

**GRADUATE THESIS**



**Zagreb, 2017**

This graduation thesis has been completed at the Department of Pediatrics at the University Hospital Centre Zagreb (KBC Zagreb) mentored by Doc. dr. sc. Mario Čuk and was submitted for evaluation during the academic year 2016/2017.

## LIST OF FIGURES

**Figure 1:** Vitamin D metabolic pathway. *Modified (Lee JY et al. 2013).*

**Figure 2:** Lysine catabolic pathway and its relation to GABA synthesis. *Modified (Jagadeesh S et al. 2013)*

**Figure 3.** Vitamin B<sub>12</sub> cofactor activity. *Modified (Rasmussen SA et al. 2001).*

## LIST OF TABLES

**Table 1:** Vitamin D status in relation to 25-hydroxyvitamin D levels. *Data consistent with Global consensus Recommendations (Moons CF, Shaw N et al. 2016)*

**Table 2:** Vitamin D status based on 25-hydroxyvitamin D levels. *Modified (Carpenter T 2016).*

**Table 3.** Vitamin D dosing scheme in rickets. *Modified (Carpenter T 2016).*

**Table 4.** Clinical findings of vitamin B<sub>12</sub> deficiency in children. *Modified (Rasmussen SA et al. 2001).*

**Table 5.** Interpretation of serum vitamin B<sub>12</sub> levels. *Modified (Schrier SL 2016).*

**Table 6.** Vitamin B<sub>12</sub> treatment regimen. *Modified (Oh RC, Brown DL 2003).*

# LIST OF ABBREVIATIONS

ALP - Alkaline phosphatase

ATP - Adenosine triphosphate

BBB - Blood brain barrier

CBC - complete blood count

CNS - Central nervous system

CoA - Coenzyme A

CSF - Cerebrospinal fluid

GABA - Gamma-aminobutyric acid

IBD - Inflammatory bowel disease

ICU - Intensive care unit

IF - Intrinsic factor

MCV - Mean corpuscular volume

PAS - Polyglandular autoimmune syndrome

PDE - Pyridoxine dependent epilepsy

PNPO - Pyridoxine phosphate oxidase

PTH - Parathyroid hormone

TNF - Tumor necrosis factor

TNSALP - Tissue non-specific alkaline phosphatase

UVR - Ultraviolet radiation

VDR - Vitamin D receptor

WHO - World Health Organization

# TABLE OF CONTENTS

<b>SUMMARY</b>	<b>1</b>
<b>SAŽETAK</b>	<b>3</b>
<b>1.0 VITAMIN D</b>	<b>5</b>
1.1 Source and metabolic pathway	5
1.2 Physiology	5
1.3 Vitamin D deficiency	6
1.3.1 Etiology	6
1.3.2 Clinical manifestations	8
1.3.3 Diagnostic evaluation	8
1.3.4 Prevention and treatment	9
<b>2.0 VITAMIN B6</b>	<b>11</b>
2.1 Source and metabolic pathway	11
2.2 Physiology	11
2.3 Vitamin B6 deficiency	11
2.3.1 Etiology	11
2.3.2 Clinical manifestations	12
2.3.3 Diagnostic evaluation	12
2.3.4 Prevention and treatment	13
2.3.5 Pyridoxine dependent epilepsy	13
<b>3.0 VITAMIN B12</b>	<b>15</b>
3.1 Source and metabolic pathway	15
3.2 Physiology	15
3.3 Vitamin B12 deficiency	16
3.3.1 Etiology	16
3.3.2 Clinical manifestations	17
3.3.3 Diagnostic evaluation	18
3.3.4 Prevention and treatment	19
<b>ACKNOWLEDGEMENTS</b>	<b>21</b>
<b>REFERENCES</b>	<b>22</b>
<b>BIOGRAPHY</b>	<b>25</b>

## SUMMARY

**Title:** Vitamins in health and disease in children

**Author:** Nina Sepideh Tighnavard Mollasarai

This review will discuss vitamin D, B<sub>6</sub> and B<sub>12</sub>, with focus on their source, metabolic pathway, physiology and deficiency. What they have in common is their essential function in normal child development, growth and health.

Vitamin D deficiency is an increasing public health problem in infants and children worldwide, causing rickets and growth failure. Vitamin D deficiency can be of various causes, but the number one factor responsible for this increase is most probably insufficient sun exposure and the excessive use of sunscreen. Exclusively breastfed infants and infants born to vitamin D deficient mothers are at high risk of developing nutritional vitamin D deficiency.

Vitamin B<sub>6</sub> is essential for normal brain function and development. Unlike vitamin D, nutritional vitamin B<sub>6</sub> deficiency is rare, due to its availability in various food products. Deficiency states are most commonly seen in children with malabsorption diseases, in severe malnutrition due to poverty and in inborn errors of vitamin B<sub>6</sub> metabolism. Although the inborn errors of metabolism are extremely rare one such error will be highlighted here, pyridoxine dependent epilepsy. It is an autosomal recessive disease where defective lysine catabolism causes decreased levels of vitamin B<sub>6</sub> in the brain, resulting in seizures and other neurological manifestations.

Vitamin B<sub>12</sub> is involved in the metabolism of every cell in the human body, most importantly in DNA synthesis. As a consequence, vitamin B<sub>12</sub> deficiency mostly affects tissues of high metabolic activity, i.e epithelial, nervous and hematopoietic systems. The clinical manifestations of vitamin B<sub>12</sub> deficiency has a wide spectrum and are usually non specific, thus there is a need for high index of suspicion to find the correlation. Vitamin B<sub>12</sub> is exclusively found in food of animal origin, putting infants of vegan or vegetarian mothers at the highest risk of developing a deficiency. As vegan or vegetarian diets are trending, women planning to get pregnant need to be informed about the crucial function of vitamin B<sub>12</sub> and the need for supplementation during pregnancy and lactation.

Although some deficiencies are rare and some are common, they are all clinically preventable diseases by implementing prevention and screening programs (especially in high risk groups), supplementation and food fortification. Early diagnosis and treatment are of utmost importance in

all vitamin deficiencies since it prevents devastating irreversible consequences and significantly improves outcome in severely deficient children.

**Keywords:** vitamin D deficiency, rickets, vitamin B<sub>6</sub> deficiency, pyridoxine dependent epilepsy, vitamin B<sub>12</sub> deficiency, megaloblastic anemia, pernicious anemia.



# SAŽETAK

**Naslov:** Vitamini u zdravlju i bolestima djece

**Autor:** Nina Sepideh Tighnavard Mollasarai

Ovaj pregled će se osvrnuti na vitamine D, B<sub>6</sub> i B<sub>12</sub>, sa fokusom na njihov izvor, metabolički proces, fiziologiju te nedostatak. Ono što imaju zajedničko je njihova esencijalna funkcija u normalnom rastu, razvoju i zdravlju djeteta.

Nedostatak vitamina D je rastući problem javnog zdravstva kod dojenčadi i djece diljem svijeta, uzrokujući rahitis i zastoj u rastu. Nedostatak vitamina D može biti uzrokovan različitim čimbenicima, ali je glavni uzrok odgovoran za taj porast najvjerojatnije neadekvatna izloženost suncu te pretjerano korištenje krema za sunce. Isključivo dojenčad i novorođenčad čije su majke u nedostatku vitamina D su u visokom riziku razvoja prehranbenog nedostatka vitamina D.

Vitamin B<sub>6</sub> je esencijalan u normalnom razvoju i funkciji mozga. Za razliku od vitamina D, nutritivni manjak vitamina B<sub>6</sub> je rijedak radi njegovog prisutstva u različitim hranidbenim proizvodima. Stadiji nedostatka su najčešće viđeni u djece s bolestima malapsorpcije, u teškoj podhranjenosti radi siromaštva te u urođenim greškama metabolizma B<sub>6</sub>. Makar su urođene greške metabolizma rijetke jednu od njih ćemo naglasiti ovdje, piridoksin ovisnu epilepsiju. To je autosomalna recesivna bolest gdje neispravan katabolizam lizina uzrokuje snižene nivoe vitamina B<sub>6</sub> u mozgu, te prouzrokuje napdaje i ostale neurološke manifestacije.

Vitamin B<sub>12</sub> je umiješan u metabolizam svake stanice u ljudskom tijelu, najvažnije u sintezu DNK. Kao posljedica, nedostatak vitamina B<sub>12</sub> najviše utiče na tkiva visoke metaboličke aktivnosti, npr. epitela, živaca i hematopoetskih sustava. Kliničke manifestacije nedostatka vitamina B<sub>12</sub> imaju širok spektar i obično su nespecifične, dakle postoji potreba za visokim indeksom sumnje kako bi se našla korelacija. Vitamin B<sub>12</sub> isključivo postoji u hrani životinjskog porijekla, činivši dojenčad veganskih ili vegetarijanskih majki najrizičnijom skupinom razvoja nedostatka. Kako su veganski i vegetarijanski tipovi prehrane u trendu, žene koje planiraju trudnoću trebaju biti informirane o presudnoj funkciji vitamina B<sub>12</sub> te potrebom za dopunom tokom trudnoće i dojenja.

Makar su neki nedostaci rijetki a neki učestali, to su klinički spriječive bolesti ako se implementiraju programi prevencije i probira (pogotovo u visoko rizičnim skupinama), suplementacije i fortifikacije hrane. Rana dijagnoza i liječenje su iznimno važni u svim nedostacima vitamina jer sprječavaju razarajuće nepovratne posljedice i značajno poboljšavaju ishod u djece sa velikim deficitom.

**Ključne riječi:** nedostatak vitamina D, rahitis, nedostatak vitamina B<sub>6</sub>, piridoksin ovisna epilepsija, nedostatak vitamina B<sub>12</sub>, megaloblastična anemija, perniciozna anemija.

# 1.0 VITAMIN D

## 1.1 Source and metabolic pathway

Vitamin D is a lipid soluble vitamin existing in different forms in the body. Vitamin D<sub>3</sub> (cholecalciferol) is primarily formed in the skin after exposure to UVR from the sun by conversion of its precursor 7-dehydrocholesterol. Less than 10% is obtained from dietary sources (Norris JM 2001) in the form of either vitamin D<sub>2</sub> (ergocalciferol) or vitamin D<sub>3</sub>. There are very few natural dietary sources containing vitamin D, the main ones being margarine, fatty fish, liver and egg yolk (Misra M et al. 2008). Vitamin D<sub>2</sub> and D<sub>3</sub> are of equivalent potency and in order to become active require further metabolism in the liver and kidney to 25-hydroxyvitamin D (calcidiol) and 1,25-dihydroxyvitamin D (calcitriol), respectively. The former is the storage form of vitamin D whereas the latter is the active form delivered to target organs to express its functions (Marcdante KJ, Kliegman RM 2015).

## 1.2 Physiology

Vitamin D plays an essential role in calcium and phosphate homeostasis in the body, mainly by promoting their absorption in the intestines and decreasing their excretion by the kidneys. The maintenance of adequate concentrations of these minerals enables mineralization of bones. Other functions of Vitamin D include suppression of PTH release from the parathyroid gland, regulation of osteoblast and osteoclast function and bone resorption (*Figure 1*).

Vitamin D has a wide variety of functions in the body, not just involving bone and mineral homeostasis, proven by the presence of its receptor in most organs. Vitamin D is proven to help in modulation of cell growth, neuromuscular and immune function, many genes encoding proteins that regulate cell proliferation, differentiation and apoptosis and the reduction of inflammation (Gupta R et al. 2014). Some studies suggest that it may reduce the risk of autoimmune diseases and protect against diabetes and some cancers (Casey CF et al. 2010).

## 1.3 Vitamin D deficiency

### 1.3.1 Etiology

Low levels of vitamin D results in hypocalcemia and hypophosphatemia, which could over time lead to rickets in infants and children or osteomalacia in adolescence and adults (Misra M 2016). Rickets is defined as decreased or defective bone mineralization in growing children. The skeletal phenotype is partly due the direct effects of vitamin D deficiency on bone and partly due to secondary hyperparathyroidism that develops in the vitamin D deficient state, as PTH causes calcium mobilization and bone resorption.

To my knowledge there is currently no data to show the exact prevalence of rickets, however documentations prove that this problem still exists today (Misra M et al. 2008). Although rickets is rare in developed countries since the introduction of fortified food products and infant formulas, the frequency has been increasing worldwide. Possible factors accounting for this increase include the excessive use of sunscreen and that children are spending more and more time indoors watching TV or playing computer games (Lowdon J 2011).

Children at risk of developing rickets are usually those who are malnourished, exclusively breastfed, not exposed to enough sun or those having chronic illnesses.

Vitamin D deficiency can be due to various causes; factors interfering with the synthesis of vitamin D, decreased nutritional intake, perinatal factors, genetic disorders, malnutrition and various medications.

The primary source of vitamin D synthesis is exposure to UVR from the sun, which has increasingly been limited or blocked by excessive use of sunscreen due to the increased awareness of its strong association with the development of skin cancer. The amount of dermal vitamin D synthesis depends on several factors, skin pigmentation being the most important. Dermal vitamin D synthesis is reduced in dark skinned children due to the blocking action of melanin, hence requiring as much as 3 to 10 times more sun exposure as light-skinned children to reach recommended concentration. Other factors include age, duration of exposure, amount of skin exposed and geographic-related factors.

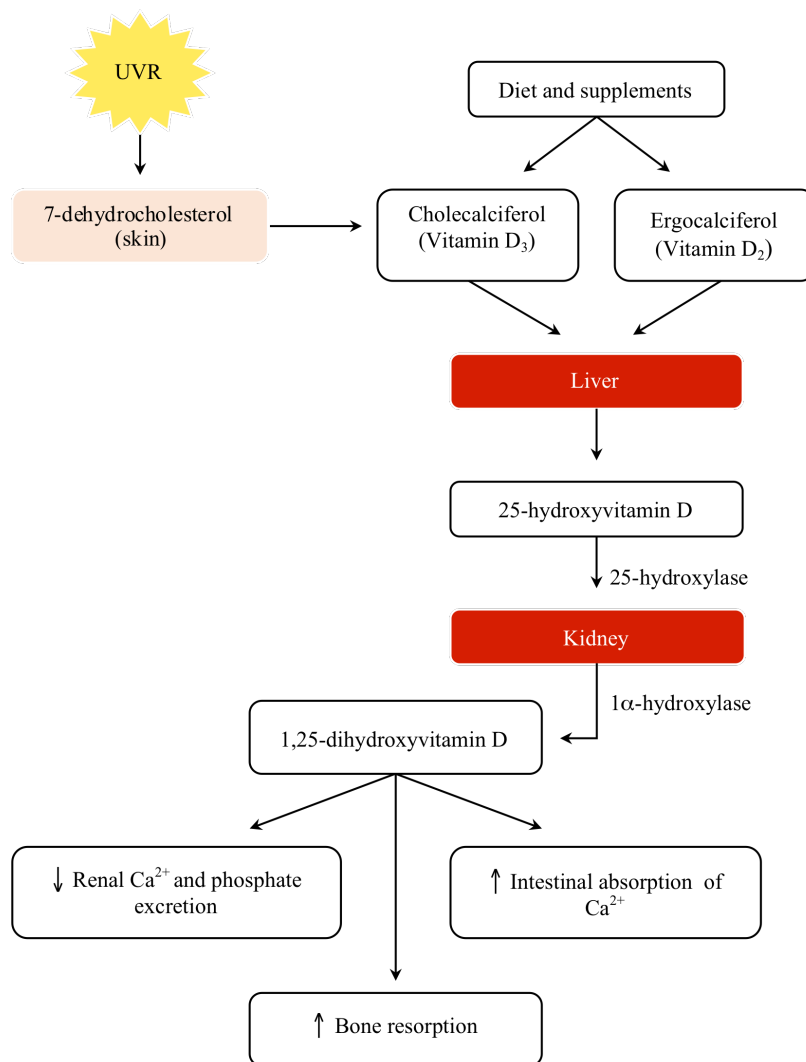
Insufficient intake of vitamin D containing foods or food fortified with vitamin D can cause vitamin D deficiency, particularly in breastfed infants. Exclusive breastfeeding doesn't provide sufficient vitamin D to fetus since the concentration of vitamin D in breastmilk is too low, even in non-deficient mothers.

The only source of vitamin D in the fetus is from the mother across the placenta. During the fetal skeletal calcification which occurs in the third trimester, vitamin D from the mother is critical. A poor maternal vitamin D status during this period can cause fetal vitamin D deficiency, and in severe cases fetal rickets. Premature infants are particularly susceptible (Misra M 2016).

Vitamin D malabsorption from the gut is associated with conditions that impair fat absorption, since vitamin D is fat soluble and therefore chylomicron dependent. Rickets can be found in children with celiac disease (Pazianas M et al. 2005), inflammatory bowel disease, cystic fibrosis and cholestasis (Misra M et al. 2008).

Inherited diseases that cause vitamin D deficiency are rare and are caused by mutations either in genes encoding the enzymes involved in pathway of vitamin d synthesis (1-alpha-hydroxylase and 25-hydroxylase) or the vitamin D receptor (VDR).

Some medications that also can increase the risk of vitamin D deficiency if taken chronically are glucocorticoids, anti-fungals, anticonvulsants and anti-retroviral agents (Lee JY et al. 2013).



**Figure 1.** Vitamin D metabolic pathway.

### 1.3.2 Clinical manifestations

Vitamin D deficient children may present with a range of symptoms and signs, from none to varying degrees of rickets and/or hypocalcemic symptoms, such as seizures, muscle weakness, tetany and hypoplasia of the dental enamel. The clinical manifestations of vitamin D deficient rickets peaks between 6 and 18 months of life, during the period of rapid growth (Wagner CL, Greer FR 2008). The growth plates thicken due to continued normal expansion in the absence of adequate mineralization. As a result these children will have the classical signs of widening of the wrists and ankles (Gupta R et al. 2014). General softening of the bones is responsible for the knock-knees (genu valgum) or bowlegs (genu varum) deformity. Other signs include prominence of costochondral junctions (rachitic rosary), pigeon chest deformity (pectus carinatum), frontal bossing, delayed closure of the fontanelles and craniotables (Marcdante KJ, Kliegman RM 2015). A child with subtle symptoms of irritability, bone pain, delayed motor development such as standing and walking, delayed growth, and a history of frequent falling should raise the suspicion of rickets (Thacher TD, Clarke BL 2011).

### 1.3.3 Diagnostic evaluation

The best indicator for vitamin D status is 25-hydroxyvitamin D, due to its long half-life of 2-3 weeks and its non-susceptibility to changes in PTH concentrations. (Thacher TD, Clarke BL 2011). Standards for defining normal and abnormal serum 25-hydroxyvitamin D levels are not well established because of inconsistent evidence, especially in the pediatric population (Misra M 2016), thus variations are commonly seen. The vitamin D status can be sufficient, insufficient or deficient as shown in *Table 1*.

<b>Vitamin D status</b>	<b>25-hydroxyvitamin D level (ng/mL)</b>
Sufficiency	20-100
Insufficiency	12-20
Deficiency	≤12

When suspecting a child with vitamin D deficient rickets the medical anamnesis should include dietary habits with focus on calcium and vitamin D intake, medication history and history of sun

exposure. Confirmation is mainly done with laboratory and radiographic findings. In addition to 25-hydroxyvitamin D levels, serum measurements in the workup should include calcium, phosphorous, ALP, PTH, and 1,25-dihydroxyvitamin D levels (Gupta R et al. 2014). These measurements are necessary to determine whether the etiology of rickets is due to low calcium levels secondary to vitamin D deficiency or due to phosphorus deficiency. Rickets due to phosphorous deficiency, so called phosphopenic rickets, will not be covered here.

In a vitamin D deficient state, low calcium levels stimulate the parathyroid gland to increase its secretion of PTH, which in turn stimulates calcium reabsorption in renal tubules, bone resorption and 1-alpha-hydroxylase activity (Misra M et al. 2008). This compensatory increase in PTH secretion is responsible for the variations in calcium, phosphorus and 1,25-dihydroxyvitamin D levels occurring in early stages of rickets (*Table 2*). ALP is a product of osteoblasts and is an excellent marker for disease activity, indicating a state of increased bone turnover, thus always elevated in rickets (Van Straalen JP et al. 1991).

The radiographic changes of rickets can best be observed at the growth plate of rapidly growing bones. Thus these changes are most prominent at distal ulna and at the metaphyses above and below the knees, which may show widening, cupping and fraying (Gupta R et al. 2014). Other changes may include osteopenia, cortical thinning of long bones, stress fractures and deformities of the shafts as previously mentioned under clinical presentation (Misra M et al. 2008).

**Table 2.** Biochemical findings in vitamin D deficient rickets

Calcium	Phosphorus	ALP	25-OH D	1,25-(OH) <sub>2</sub> D	PTH
↓/N	↓/N	↑/↑↑	↓	↑/N	↑

↑: increased; ↓: decreased; N: normal.

### 1.3.4 Prevention and treatment

In order to prevent vitamin D deficiency and rickets in infants and children, a daily intake of at least 400 IU is recommended, beginning in the first few days of life (*Table 3*) (Wagner CL, Greer FR 2008). Exclusive breastfeeding of infants does not provide sufficient vitamin D to meet this criteria, thus supplementation is recommended. Supplementation should also be given to infants ingesting less than 1000 ml of fortified formula per day (Carpenter T 2016). Children at risk and those who do not receive enough vitamin D through natural sources, fortified food or sun exposure should also be given supplements. Given the fact that sun exposure is the number one source of

vitamin D and its direct association with skin cancer, a balance of the amount of exposure is necessary (Misra M et al. 2008). Another way of prevention is through screening for vitamin D deficiency, specially in high risk children, i.e those with chronic diseases associated with fat malabsorption, dark pigmented children who live at higher latitudes, children on glucocorticoid or anticonvulsant therapy and children with elevated ALP levels.

Therapy for vitamin D deficiency is indicated in infants and children with clinical manifestations of hypocalcemia and/or rickets and with serum vitamin D levels outside normal range. The most commonly used treatment consists of either vitamin D<sub>2</sub> or vitamin D<sub>3</sub>, the latter being preferred. *Table 3* shows the recommended vitamin D dosing scheme for vitamin D deficient rickets who do not have any underlying defect in intestinal absorptive function. Treatment should also consist of daily calcium supplementation of 30 to 50 mg per kg body weight (Carpenter T 2016). The dosing for vitamin D deficient children without rickets is debatable, some recommend the same dosing scheme as for children with rickets while some suggest lower doses (400 IU/day in children < 1 month, and up to 1000 IU/day for older children; Carpenter T 2016).

<b>Prevention</b>	400 IU/day
<b>Treatment</b>	
Infants < 1 month	1000 IU/day po for 2-3 months*
Infants 1-12 months	1000-2000 IU/day po for 2-3 months*
Children 1-12 years	2000-6000 IU/day po for 3 months**
Children ≥ 12 years	6000 IU/day for 3 months**

*IU: International Units; po: per oral; \* followed by maintenance dose of 400 IU/day; \*\* followed by maintenance dose of 600 IU/day.*



## 2.0 VITAMIN B<sub>6</sub>

### 2.1 Source and metabolic pathway

Vitamin B<sub>6</sub> is a water soluble vitamin present in the body in the form of pyridoxine, pyridoxal, pyridoxamine, and their respective 5'-phosphate derivatives. The main source of vitamin B<sub>6</sub> is from the diet, mainly from meat, cereals, various vegetables, fruits, nuts and beans. A small proportion is synthesized from intestinal bacterial flora. After intestinal absorption they are transported to the liver in order to become phosphorylated by pyridoxal kinase. Pyridoxine phosphate and pyridoxamine phosphate become further oxidized by pyridoxine 5'-phosphate oxidase (PNPO) to the active coenzyme pyridoxal 5'-phosphate (PLP), which is released into the circulation bound to albumin (Surtees R et al. 2006). Since only free vitamin bases can cross the BBB and enter the CNS, the PLP-albumin complex is cleaved by a tissue non-specific alkaline phosphatase to free pyridoxal (TNSALP). Studies on mice lacking this enzyme has been done, where these mice died due to seizures, proving its critical function in transporting vitamin B<sub>6</sub> into the brain (Waymire KG et al. 1995).

### 2.2 Physiology

Pyridoxal phosphate acts as a cofactor for many enzymes involved in metabolism of amino acids, carbohydrates, lipids and brain neurotransmitters (eg. dopamine, serotonin, glycine, glutamate, GABA) as well as the synthesis of neuroprotective compounds (Surtees R et al. 2006). Other functions include immune development, steroid hormone modulation and biosynthesis of hemoglobin and prostaglandins (Marcdante KJ, Kliegman RM 2015). Thus, deficiency of vitamin B<sub>6</sub> can have many diverse consequences.

### 2.3 Vitamin B<sub>6</sub> deficiency

#### 2.3.1 Etiology

Unlike vitamin D, deficiency of vitamin B<sub>6</sub> due to insufficient dietary intake is rare, due to its presence in a wide variety of foods. Nevertheless, it can be seen in severely malnourished children or in children with conditions causing malabsorption, such as IBD and celiac disease.

Vitamin B<sub>6</sub> can be destroyed by cooking and food processing, reducing its availability with up to 50

percent (Pazirandeh S, Burns DL 2017). This has been shown to cause serious consequences, as an outbreak of infants with seizures occurred by the heating of improperly processed formulas (Marcdante KJ, Kliegman RM 2015).

Medications that can interfere with the function of vitamin B<sub>6</sub> are for example isoniazid, penicillamine, hydralazine and cycloserine (Pazirandeh S, Burns DL 2017).

There are currently four recognized inborn errors of metabolism affecting brain PLP, all causing seizures of varying degrees. PNPO deficiency is the only one known to stem from defective vitamin B<sub>6</sub> metabolism and transport. Two inborn errors of other metabolic pathways include pyridoxine dependent epilepsy (PDE) and hyperprolinemia type II. The last one is TNSALP deficiency (hypophosphatasia), an inherited disorder of bone mineralization where affected infants sometimes present with seizures (Surtees R et al. 2006).

### 2.3.2 Clinical manifestations

The classical signs and symptoms of vitamin B<sub>6</sub> deficiency in children include microcytic anemia, dermatitis-like skin eruptions, glossitis, angular cheilitis, immunosuppression, somnolence, confusion, irritability and seizures (Frye RE 2016). As mentioned previously PLP is involved in the metabolism of neurotransmitters, whereas the inhibitory neurotransmitter GABA is one of them. Severe vitamin B<sub>6</sub> deficiency can therefore lead to the development of seizures as a consequence of decreased GABA concentrations in the brain (Kluger G 2008).

### 2.3.3 Diagnostic evaluation

The diagnosis of vitamin B<sub>6</sub> deficiency is usually based on clinical findings and it should always be considered in the differential diagnosis of infantile seizures, specially if the seizures are unresponsive to anticonvulsant treatment (Johnson LE 2016). Although there is currently no single accepted laboratory test in confirming the diagnosis of vitamin B<sub>6</sub> deficiency, the serum PLP level is the best indicator for vitamin B<sub>6</sub> status. Other useful laboratory tests include measurements of erythrocyte transaminase activity and urinary excretion of the vitamin B<sub>6</sub> degradation product pyridoxic acid (Pazirandeh S, Burns DL 2017).

### 2.3.4 Prevention and treatment

In order to achieve optimal body vitamin B<sub>6</sub> levels in otherwise healthy children, a daily intake ranging from 0.1 to 1.3 mg is recommended, depending on the age of the child (Pazirandeh S, Burns DL 2017). Preventive measures include dietary adjustments and vitamin B<sub>6</sub> supplementation in children at risk (i.e with diseases of malabsorption).

The previously mentioned inborn metabolic disorders all respond to treatment with high doses of pyridoxine or PLP.

### 2.3.5 Pyridoxine dependent epilepsy

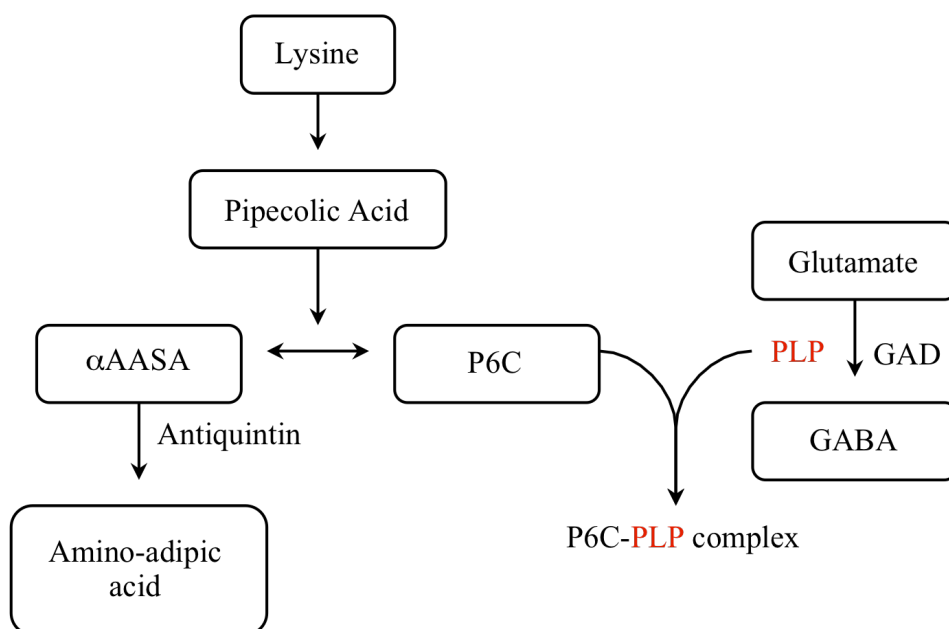
Pyridoxine dependent epilepsy (PDE) is an extremely rare autosomal recessive disease. The exact prevalence is unknown but ranges from approximately 1:20 000 to 1:600 000 births (Stockler S et al. 2011). Recently PDE was proven to result from mutations in the ALDH7A1 gene encoding for antiquitin, an ADH essential for the catabolism of lysine in the brain (Mills PB et al. 2006). As a consequence accumulations of L-pipecolic acid, piperidine-6-carboxylate (P6C) and  $\alpha$ -amino adipic semialdehyde ( $\alpha$ AASA) occurs (*Figure 2*). The accumulated P6C inactivates PLP through the formation of a P6C-PLP complex, thus decreasing free PLP levels in the brain. As a result GABA synthesis decreases, thereby greatly reducing the threshold for seizures.

PDE classically presents with seizures during early infancy, refractory to anticonvulsant treatment but responsive to high doses of pyridoxine. Although multiple types of seizures are reported in these infants, the dramatic presentation of status epilepticus is characteristic (Stockler S et al. 2011). Other clinical manifestations include irritability, abnormal cry, dystonic movements, respiratory distress, abdominal distention, bilious vomiting, hepatomegaly, metabolic acidosis and shock (Mills PB et al. 2010). In one third of cases PDE presents in an atypical manner with late-onset seizures, up to 3 years of age. Other atypical features include prolonged seizure-free interval up to 5 years after pyridoxine withdrawal and initial response to conventional anticonvulsant therapy (Jagadeesh S et al. 2013) (Stockler S et al. 2011).

The diagnosis of PDE is based on clinical and electroencephalographic response to pyridoxine treatment in infants not responding to anticonvulsants, followed by lab- and genetic testing. Elevated urine or plasma  $\alpha$ AASA is a strong indicator for PDE. Plasma P6C and pipecolic acid and CSF pipecolic acid may also be elevated (Stockler S et al. 2011). Additional testing includes EEG

readings, usually being severely abnormal, and brain imaging with possible atrophic or dysplastic changes (Mills PB et al. 2010). Diagnosis is confirmed with mutations in ALDH7A1 gene.

In acute treatment, IV administration of a single dose of 50-100 mg pyridoxine usually results in cessation of seizures within a few minutes (Jagadeesh S et al. 2013). As IV pyridoxine can cause respiratory depression, it should be done in the ICU with close monitoring of vital signs. Seizures recur upon pyridoxine withdrawal, consequently requiring lifelong enteral treatment with either pyridoxine or PLP 15-30 mg/kg/day (Stockler S et al. 2011). Recently a new therapeutic approach consisting of pyridoxine, arginine supplementation and a lysine-restricted diet is shown to be superior to mono-therapy with pyridoxine. Although early diagnosis and treatment significantly improves the outcome, most children will unfortunately still have developmental delay and intellectual disability (Bennet CL 2005).



**Figure 2.** Lysine catabolic pathway and its relation to GABA synthesis.  
*GAD: glutamate decarboxylase*

## 3.0 VITAMIN B<sub>12</sub>

### 3.1 Source and metabolic pathway

Vitamin B<sub>12</sub> (cobalamin, Cbl) is a water soluble vitamin present in the body in the form of hydroxocobalamin, methylcobalamin (methyl-Cbl) and adenosylcobalamin (adenosyl-Cbl) (Smith J, Coman D 2014). The human body is unable to synthesize cobalamin, hence the only source being from dietary products. It's exclusively found in foods of animal origin such as meat and dairy products, thereof the need for supplements in strict vegetarians and vegans. Synthetic vitamin B<sub>12</sub> found in supplements and fortified foods is mainly in the form of cyanocobalamin (cyano-Cbl).

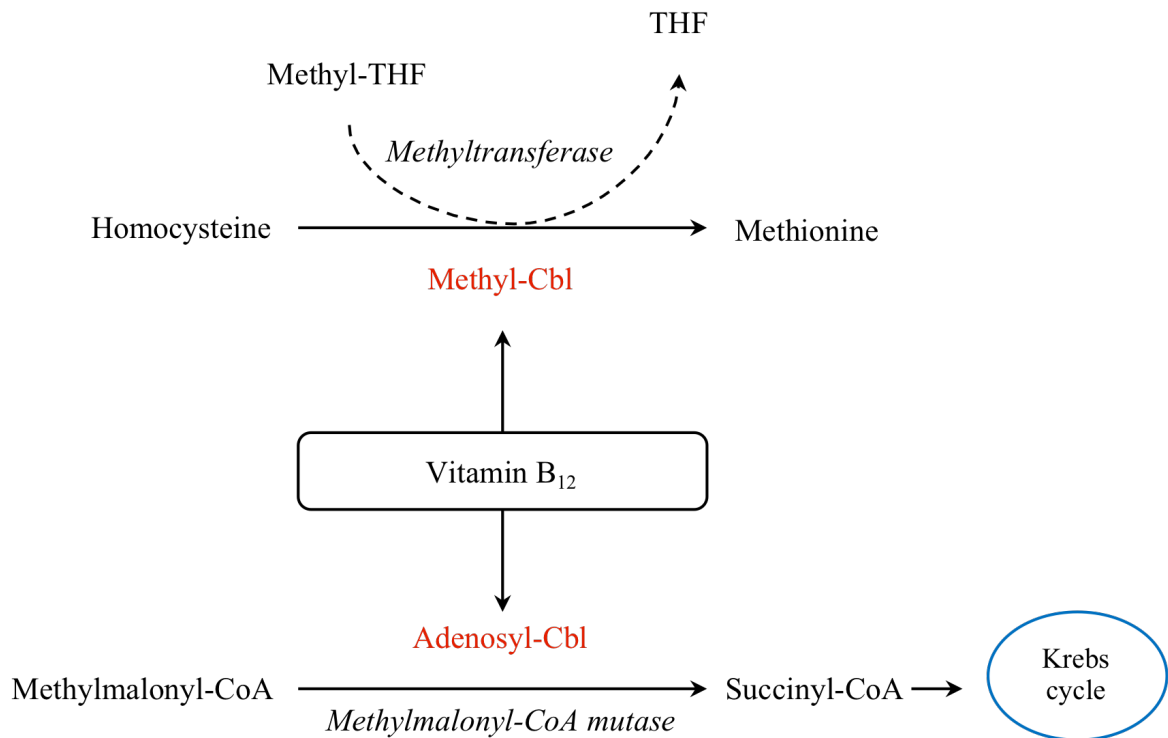
The absorption of cobalamin is a complex process, depending on several factors. In the presence of gastric acid and pepsinogen secretion cobalamin is released from food proteins. It then binds R-binder proteins, only to be released again by the action of pancreatic proteases in the duodenum. The ultimate absorption occurs in the distal ileum, a process requiring the *intrinsic factor* (IF), a binding protein secreted from gastric parietal cells. After absorption into the enterocytes by the means of specific ileal receptors (cubilin-amnionless), the IF-Cbl complex dissociates and free cobalamin is released into the circulation bound to either transcobalamin (TC) or haptocorrin (HC), transporting cobalamin to target tissues (Rasmussen SA et al. 2001).

Unlike other water soluble vitamins cobalamin is stored in the liver in large concentrations, sufficient to last up to several years after cessation of dietary cobalamin intake/absorption. This is mainly possible due to the highly efficient enterohepatic circulation after its secretion in the bile (Smith J, Coman D 2014).

### 3.2 Physiology

Cobalamin is involved in the metabolism of every cell in the human body, most importantly in DNA synthesis and carbohydrate, lipid and protein metabolic pathways (Marcdante KJ, Kliegman RM 2015). Methyl-Cbl and adenosyl-Cbl are essential cofactors for methionine synthase and methylmalonyl-CoA mutase, respectively (*Figure 3*). Methionine synthase is the enzyme catalyzing the conversion of homocysteine to methionine, a reaction coupled with demethylation of methyltetrahydrofolate (methyl-THF) to tetrahydrofolate (THF). These reactions provide two products necessary for DNA synthesis, THF and methionine. Methionine is also a precursor of S-adenosylmethionine, the methyl donor in the formation of phosphatidylcholine from

phosphatidylethanolamine, both of which are major components of myelin. Apart from being a universal methyl group donor in more than 100 reactions in our body, methylmalonyl-CoA mutase catalyzes the conversion of methylmalonyl-CoA to succinyl-CoA (Smith J, Coman D 2014). Methylmalonyl-CoA is formed in the catabolic pathway of cholesterol, branched chain amino acids and odd chain fatty acids and its conversion into Succinyl-CoA is essential in order to enter the citric acid (Krebs) cycle to generate ATP.



**Figure 3.** Vitamin B<sub>12</sub> cofactor activity.

### 3.3 Vitamin B<sub>12</sub> deficiency

#### 3.3.1 Etiology

Cobalamin deficiency in children can be due to decreased nutritional intake, various conditions of malabsorption or inborn errors affecting metabolism, absorption or transport.

The source of fetal cobalamin is from the mother across the placenta, reaching serum levels twice those of maternal levels. The excess is stored in the fetal liver, providing cobalamin sufficient to last approximately 6-12 months postpartum, without taking into account the cobalamin provided through breastmilk. Deficient levels during this period is therefore most likely due to maternal

deficiency (Incecik F et al. 2010), nowadays commonly caused by the increased trend of vegan or vegetarian diets. Other possible maternal causes are poverty and malnutrition, unrecognized pernicious anemia, previous gastric bypass surgery or short gut syndrome (Smith J, Coman D 2014).

Inefficient cobalamin absorption from the gut may occur as a consequence of a defect in any of the mechanisms required for its normal absorption. Secondary causes of defective cobalamin absorption can be due to gastric or ileal resection, decreased gastric acid secretion, pancreatic insufficiency, small bowel bacterial overgrowth, intestinal parasite infections and IBD. Inborn errors of cobalamin absorption includes congenital pernicious anemia and Imerslund-Gräsbeck disease, with a lack of IF and a defect in the cubilin-amnionless receptor, respectively. Although very rare, the classical form of autoimmune pernicious anemia with its onset in adulthood can sometimes present in children as juvenile pernicious anemia. It's important to keep in mind that these children can have additional autoimmune diseases, as part of PAS type 1 and 2.

Other inborn errors of cobalamin deficiency are transcobalamin deficiency, R-binder deficiency as well as defective intracellular metabolism, affecting the synthesis of the coenzymes methyl-Cbl and/or adenosyl-Cbl. Methylmalonic aciduria is a classical type of organic aciduria where methylmalonic acid cannot be converted to succinyl-CoA, due to a deficiency in methylmalonyl-CoA mutase or its cofactor adenosyl-Cbl, resulting in accumulation of high quantities of methylmalonic acid in blood. With the exception of R-binder deficiency, all the above mentioned inborn errors are thought to be inherited in an autosomal recessive manner (Rasmussen SA et al. 2001).

### 3.3.2 Clinical manifestations

Cobalamin deficiency in newborns and infants usually presents with non specific manifestations, such as failure to thrive, vomiting, irritability, weakness, poor feeding and apathy (*Table 4*) (Zengin E et al. 2009). Later on infants may present with the characteristic manifestations of cobalamin deficiency; megaloblastic anemia, varying degrees of pancytopenia, hypersegmented neutrophils and neurological dysfunction. Older children may have additional findings, such as glossitis, depression and personality changes. Abnormal skin pigmentation has also been reported in severe cobalamin deficiency (Smith J, Coman D 2014).

The delayed DNA synthesis in rapidly dividing RBC precursors in the bone marrow results in

ineffective erythropoiesis, producing large and defective erythrocytes with an increase in nucleus to cytoplasm ratio.

The neurological signs and symptoms include irritability, hypotonia, hyporeflexia, tremor, ataxia, seizures, nystagmus, developmental delay, developmental regression, paresthesia and brain atrophy (Incecik F et al. 2010). Still little is known about the underlying mechanisms of the neurological features associated with cobalamin deficiency, but disruptions in myelination of brain and spinal cord is thought to play a major role. As myelination mostly occurs in the first two years of life, cobalamin deficiency in children during this period puts them at particular risk of neurological impairment. The cause of myelin disruption is thought to involve several mechanisms. Firstly, deficiency of adenosyl-CoA leads to accumulation of odd chain fatty acids, which are thought to disrupt the myelin. Secondly, deficiency of methyl-CoA results in decreased formation of the methyl donor, S-adenosylmethionine, important for myelin synthesis. Lastly S-adenosylmethionine is thought to increase production of TNF- $\alpha$ , which also may contribute to defective myelination (Smith J, Coman D 2014).

**Table 4.** Clinical findings of vitamin B<sub>12</sub> deficiency in children

General	Neuropsychological	Hematologic	Other
Weakness, fatigue, anorexia, failure to thrive, irritability,	Developmental delay and regression, paresthesia, hypotonia, hyporeflexia, seizures, ataxia, tremor, personality changes, depression	Megaloblastosis, anemia, pancytopenia	Glossitis, skin hyperpigmentation, vomiting, diarrhea, icterus

### 3.3.3 Diagnostic evaluation

As the clinical manifestations of cobalamin deficiency usually are non specific, delays in diagnosis is common, thus the need for high index of suspicion (Smith J, Coman D 2014).

Cobalamin deficiency often coexists with folate (vitamin B<sub>9</sub>) deficiency, which have a very similar presentation clinically as well as serologically, thereof the need for investigation of both vitamins.

The initial lab tests should include serum cobalamin and folate levels, CBC and red blood cell MCV. Cobalamin values can differ depending on the method used, establishing a normal range is therefor difficult. In general, however, the cobalamin levels can be interpreted as normal, borderline or low (*Table 5*). The inborn errors of cobalamin transport and metabolism can have serum



cobalamin levels in the normal range, but unavailable for utilization in tissues (Rasmussen SA et al. 2001). Both cobalamin and folate deficiency cause megaloblastic anemia with increased MCV, but only cobalamin deficiency causes neurological deficits.

Further diagnostic testing involves serum measurements of the metabolites methylmalonic acid and homocysteine, which accumulate in cobalamin deficiency (Schrier SL 2016). Homocysteine levels can also be elevated in folic acid, whereas elevated methylmalonic acid is specific for cobalamin deficiency (Rasmussen SA et al. 2001). Brain imaging may show atrophy and areas of delayed myelination (Stabler SP 2013).

<b>Vitamin B<sub>12</sub> level (pg/ml)</b>	<b>Interpretation</b>
>300	Normal, deficiency unlikely
200-300	Borderline, deficiency possible
<200	Low, consistent with deficiency

When diagnosis of cobalamin deficiency is established, an investigation of the etiology should be initiated. A proper dietary history of both the mother and the child and testing for cobalamin deficiency in the mother can confirm nutritional cobalamin deficiency. The diagnosis of pernicious anaemia can be confirmed with the presence of antibodies to IF. Other parameters suggestive of pernicious anemia are elevated gastrin levels, low pepsinogen levels and a decrease in pepsinogen I to pepsinogen II ratio (Schrier SL 2016).

### 3.3.4 Prevention and treatment

To augment prevention of cobalamin deficiency in infants, we need to increase awareness and educate pregnant women, especially vegan and vegetarian mothers, about the importance of cobalamin. These women may require supplementation during pregnancy and lactation (Oh RC, Brown DL 2003).

The treatment of cobalamin deficiency depends on the etiology. In mild asymptomatic deficiency diet modifications may be enough to bring serum cobalamin to normal levels. However pharmacological treatment is usually needed in most cases. Cobalamin is usually administered via the parenteral route either in the form of cyanocobalamin or hydroxocobalamin (Schrier SL 2016). As hydroxocobalamin has a longer half-life and thus requires less frequent dosing, it is

recommended as the drug of choice by the WHO (Van Asselt DZB et al. 1998). Oral therapy is shown to be as effective, but many doctors are unaware of this and therefore choose the former. Treatment regimens vary but typically consists of an initial loading dose followed by a maintenance dose (*Table 6*). For patients with pernicious anaemia or other malabsorption conditions with permanent cobalamin deficiency, lifelong therapy is indicated (Oh RC, Brown DL 2003).

**Table 6.** Vitamin B<sub>12</sub> treatment regimen

<b>Route of administration</b>	<b>Initial dose (µg)</b>	<b>Maintenance dose (µg)</b>
Oral	1000-2000/day for 1-2 weeks	1000/day
Intramuscular	100-1000/day for 1-2 weeks	100-1000/1-3 months

Long term prognosis depends on the severity and duration of cobalamin deficiency, thereof the need for early diagnosis and treatment (Rasmussen SA et al. 2001). Effective treatment should correct the anemia and improve neurological symptoms within 2 and 6 months, respectively. Many infants will have a full recovery, while some will unfortunately have persistent neurological damage (Stabler SP 2013).

## ACKNOWLEDGEMENTS

Foremost, I would like to thank my mentor Doc. dr. sc. Mario Ćuk for his time, patience and guidance. He is an inspiring doctor, a great teacher and a role model for many medical students including myself. Also I would like to thank the rest of my thesis committee Prof. dr. sc. Danko Milošević and Prof. dr. sc. Marija Jelušić Dražić.

I am grateful for University of Zagreb School of Medicine, giving me the opportunity to study medicine in the beautiful country of Croatia.

My final gratitudes are directed to my wonderful partner and family who have given me love and support throughout my medical studies.

## REFERENCES

Bennet CL, Huynh HM, Chance PF, Glass IA, Gospe Jr SM (2005) Genetic heterogeneity for autosomal recessive pyridoxine-dependent seizures. *Neurogenetics* 6(3);143-149.

Bordelon P, Ghetu MV, Langan R (2009) Recognition and Management of Vitamin D Deficiency. *Am Fam Physician* 80(8);841-846.

Carpenter T. (2016) Overview of rickets in children. UpToDate [Internet], Waltham, [Accessed on Mars 4, 2017]. Available on: [https://www.uptodate.com/contents/overview-of-rickets-in-children?source=see\\_link](https://www.uptodate.com/contents/overview-of-rickets-in-children?source=see_link)

Casey CF, Slawson DC, Neal LR (2010) Vitamin D Supplementation in Infants, Children, and Adolescents. *Am Fam Physician* 81(6);745-748.

Coughlin CR 2nd, van Karnebeek CD, Al-Hertani W, Shuen AY, Jaggumantri S, Jack RM et al. (2015) Triple therapy with pyridoxine, arginine supplementation and dietary lysine restriction in pyridoxine-dependent epilepsy: Neurodevelopmental outcome. *Mol Genet Metab* 116(1-2);35-43.

Frye RE (2016) Pyridoxine Deficiency. Medscape [Internet]. [Accessed on Mars 8, 2017]. Available on: <http://emedicine.medscape.com/article/124947-overview>

Gupta R, Gupta RK, Saheen A, Malhotra P (2014) Role of vitamin D in children. *JIMSA* 27(4); 229-231.

Incecik F, Herguner ÖM, Altunbasak S, Leblebisatan G (2010) Neurologic findings of nutritional vitamin B12 deficiency in children. *Turkish J Pediatr* 52(1);17-21.

Jagadeesh S, Suresh B, Murugan V, Suresh S, Salomans GS, Struys EA et al. (2013) Pyridoxine-dependent epilepsy owing to antiquitin deficiency - mutation in the ALDH7A1 gene. *Paediatr Int Child Health* 33(2);113-115.

Johnson LE (2016) Vitamin B6 (Pyridoxine). Merck Manuals [Internet]. [Accessed on Mars 10, 2017]. Available on: <http://www.merckmanuals.com/professional/nutritional-disorders/vitamin-deficiency,-dependency,-and-toxicity/vitamin-b-6>

Kluger G, Blank R, Paul K, Paschke E, Jansen E, Jakobs C et al. (2008). Pyridoxine-dependent epilepsy: Normal outcome in a patient with late diagnosis after prolonged status epilepticus causing cortical blindness. *Neuropediatrics* 39(5);276-279

Lee JY, So TY, Thackeray J (2013) A Review on Vitamin D Deficiency Treatment in Pediatric Patients. JPPT 18(4);277-291.

Lowdon J (2011) Rickets: concerns over the worldwide increase. J Fam Health Care 21(2);25-29

Marcdante KJ, Kliegman RM (2015) Nelson Essentials of Pediatrics. 7th edition. Philadelphia: Elsevier/Saunders.

Mills PB, Footitt EJ, Mill KA, Tuschl K, Aylett S, Varadkar S et al. (2010) Genotypic and phenotypic spectrum of pyridoxine-dependent epilepsy (ALDH7A1 deficiency). Brain 133(7); 2148–2159.

Mills PB, Struys E, Jakobs C, Plecko B, Baxter P, Baumgartner M (2006) Mutations in antiquitin in individuals with pyridoxine-dependent seizures. Nat Med 12(3);307-309.

Misra M. (2016) Vitamin D insufficiency and deficiency in children and adolescents. UpToDate, [Internet]. Walthman, [Accessed on February 22, 2017]. Available on: <http://www.uptodate.com>

Misra M, Pacaud D, Petryk A, Solberg PFC, Kappy M (2008) Vitamin D Deficiency in Children and Its Management: Review of Current Knowledge and Recommendations. Pediatrics 122(2); 398-417.

Moons CF, Shaw N, Kiely M, Specker BL, Thacher TD, Ozono K et al. (2016) Global Consensus Recommendations on Prevention and Management of Nutritional Rickets. J Clin Endocrinol Metab 101(2);394-415.

Norris JM (2001) Can the sunshine vitamin shed light on type 1 diabetes? Lancet 358(9292):1476–1478.

Oh RC, Brown DL (2003) Vitamin B12 deficiency. Am Fam Physician 67(5);979-986.

Pazianas M, Butcher GP, Subhani JM, Finch PJ, Ang L, Collins C, et al. (2005) Calcium absorption and bone mineral density in celiacs after long term treatment with gluten-free diet and adequate calcium intake. Osteoporos Int 16(1);56-63.

Pazirandeh S, Burns DL (2017) Overview of water-soluble vitamins. UpToDate [Internet], Walthman, [Accessed on Mars 7, 2017]. Available on: [https://www.uptodate.com/contents/overview-of-water-soluble-vitamins?source=search\\_result&search=vitamin%20b6%20deficiency&selectedTitle=1~38#H39](https://www.uptodate.com/contents/overview-of-water-soluble-vitamins?source=search_result&search=vitamin%20b6%20deficiency&selectedTitle=1~38#H39)

Rasmussen SA, Fernhoff PM, Scanlon KS (2001) Vitamin B12 deficiency in children and adolescents. *J Pediatr* 138(1);10-17.

Schrier SL (2016) Diagnosis and treatment of vitamin B12 and folate deficiency. UpToDate [Internet], Waltham, [Accessed on Mars 24, 2017]. Available on: <https://www.uptodate.com/contents/diagnosis-and-treatment-of-vitamin-b12-and-folate-deficiency#H3619967>

Smith J, Coman D (2014) Vitamin B12 Deficiency: an Update for the General Paediatrician. *Pediatr Therapeut* 4(1)

Stabler SP (2013) Vitamin B12 Deficiency. *N Engl J Med* 368(2);149-160

Stockler S, Plecko B, Gospe SM Jr, Coulter-Mackie M, Connolly M, van Karnebeek C et al. (2011) Pyridoxine dependent epilepsy and antiquitin deficiency: clinical and molecular characteristics and recommendations for diagnosis, treatment and follow-up. *Mol Genet Metab* 104(1-2);48-60.

Surtees R, Mills P, Clayton P (2006) Inborn errors affecting vitamin B<sub>6</sub> metabolism. *Future Neurol* 1(5);615-620.

Thacher TD, Clarke BL (2011) Vitamin D Insufficiency. *Mayo Clinic Proc* 86(1);50-60.

Van Asselt DZB, Merkus FWHM, Russel FGM, Hoefnagels WHL (1998) Nasal absorption of hydroxocobalamin in healthy elderly adults. *Br J Clin Pharmacol* 45(1); 83-86.

Van Straalen JP, Sanders E, Prummel MF, Sanders GT (1991) Bone alkaline phosphatase as an indicator of bone formation. *Clin Chim Acta* 201;27-33.

Wagner CL, Greer FR (2008) Prevention of Rickets and Vitamin D Deficiency in Infants, Children, and Adolescents. *Pediatrics* 122(5);1142-1152.

Waymire KG, Mahuren JD, Jaje JM, Guilarte TR, Coburn SP, MacGregor GR (1995) Mice lacking tissue non-specific alkaline phosphatase die from seizures due to defective metabolism of vitamin B-6. *Nat Genet* 11(1); 45-51.

Zengin E, Sarper N, Caki Kilic S (2009) Clinical manifestations of infants with nutritional vitamin B deficiency due to maternal dietary deficiency. *Acta Paediatr* 98(1);98-102.

## BIOGRAPHY

The author's parents fled to Sweden from Iran during the Iranian revolution with their 3 year old son. The author was born in the north of Sweden in the year of 1991. She was schooled early to become a doctor and the journey started with pre-medical school. She later got accepted to the english medical program at Zagreb University, where she after 6 years fulfilled her dream.

She currently resides in Sundsvall with her boyfriend, waiting to start her internship. She has not decided for specialization yet, however cardiology, neurology and family medicine are all appealing. She wishes to travel the world in the near future.