

Ultrasound in diagnosis of lesions in musculoskeletal system

Paušek, Katarina

Master's thesis / Diplomski rad

2017

Degree Grantor / Ustanova koja je dodijelila akademski / stručni stupanj: **University of Zagreb, School of Medicine / Sveučilište u Zagrebu, Medicinski fakultet**

Permanent link / Trajna poveznica: <https://um.nsk.hr/um:nbn:hr:105:314167>

Rights / Prava: [In copyright](#)/[Zaštićeno autorskim pravom.](#)

Download date / Datum preuzimanja: **2025-03-29**



Repository / Repozitorij:

[Dr Med - University of Zagreb School of Medicine Digital Repository](#)



**UNIVERSITY OF ZAGREB
SCHOOL OF MEDICINE**

Katarina Paušek

**Ultrasound in Diagnosis of Lesions in
Musculoskeletal System**

GRADUATE THESIS



Zagreb, 2017

This graduation paper was made at the Department for Diagnostic and Interventional Radiology at the Clinical Hospital Dubrava under supervision of assist. prof. Gordana Ivanac and it was submitted for evaluation in the academic year 2016/2017.

ACKNOWLEDGEMENTS

I wish to thank my dear mentor doc.dr.sc. Gordana Ivanac for help and guidance, my wonderful colleague and friend dr. Deša Tešanović for support and encouragement in times when I needed it most, and my precious boyfriend Matija, for explaining some concepts in physics and statistics, and for bearing with me through every hardship; for his love and calming disposition.

TABLE OF CONTENTS

- 1. Summary6**
- 2. Sažetak7**
- 3. Basic Physics and Technology of Medical Diagnostic Ultrasound.....8**
- 4. Normal and Pathological Appearance of Structures in the
Musculoskeletal System 11**
- 5. The Shoulder 13**
- 6. The Elbow 15**
- 7. Hand and Wrist.....20**
- 8. The Hip.....28**
- 9. The Knee.....30**
- 10. The Ankle and Foot.....35**
- 11. Pediatric Musculoskeletal Ultrasound36**
- 12. Conclusion40**
- Biography.....42**
- References43**

LIST OF ABBREVIATIONS

AC acromioclavicular

AP anteroposterior

CT computed tomography

CTS carpal tunnel syndrome

DDH developmental dysplasia of the hip

EMG electromyography

GCTTS Giant Cell Tumour of the Tendon Sheath

HNPP hereditary neuropathy with liability to pressure palsies

MCP metacarpophalangeal

ME medial epicondyle

MRI magnetic resonance imaging

NCV nerve conduction velocity

NSAID nonsteroidal anti-inflammatory drug

ROM range of motion

RTS radial tunnel syndrome

UCL ulnar cruciate ligament

US ultrasound

1 Summary

Ultrasound in Diagnosis of Lesions in Musculoskeletal System

Katarina Paušek

Ultrasound has, since its invention, become one of the most widely spread and used diagnostic methods. Almost every child born in the Western part of the world since the 1970s had been examined by ultrasound whilst still in the womb.(42) Ultrasound was used in the musculoskeletal system for the first time in 1958 by K. T. Dussik.(92) Now, almost 60 years later, it has become the first line diagnostic method for imaging the musculoskeletal system in Europe, and its popularity is growing in North America. Ultrasound owes its popularity to being one of the least expensive diagnostic methods, the fact that it doesn't expose patients to harmful ionizing radiation, enables doctor-patient interaction, and the results are available in real time. Diseases of the musculoskeletal system are the main cause of chronic pain and invalidity in the world. Millions of people worldwide are suffering from diseases of the musculoskeletal system, and with aging of the population, the expected burden of disease will become progressively larger. Ultrasound can be used in diagnostics, as well as therapy, and as guidance in application of therapy in diseases of the musculoskeletal system. In this paper I am going to discuss the use of ultrasound in some of the most common lesions of the musculoskeletal system.

Key words: ultrasound; musculoskeletal system; diagnostics

2 Sažetak

Ultrazvuk u dijagnostici lezija u muskuloskeletnom sustavu

Katarina Paušek

Ultrazvuk je od svog izuma do danas postao jedan od najraširenijih i najkorištenijih dijagnostičkih metoda. Gotovo svako dijete rođeno u zapadnom dijelu svijeta od 1970-ih nadalje vjerojatno je već u maternici bilo pregledano ultrazvukom.(42) Ultrazvuk se prvi put upotrijebio u dijagnostici mišićno-koštanog sustava 1958. od strane K. T. Dussika, a danas, gotovo 60 godina kasnije, ultrazvuk je postao dijagnostička metoda izbora u Europi za bolesti mišićno-koštanog sustava, a njegova primjena je sve raširenija u Sjevernoj Americi.(92) Takvoj popularnosti pridonosi činjenica da je ultrazvuk jedna od najekonomičnijih dijagnostičkih metoda, pacijenta ne izlaže ionizirajućem zračenju, omogućuje komunikaciju s pacijentom te dinamičan pristup, a nalazi su operateru dostupni odmah. Bolesti mišićno-koštanog sustava glavni su uzročnik kronične boli i tjelesne nesposobnosti (invalidnosti). Stotine milijuna ljudi u svijetu boluju od bolesti mišićno-koštanog sustava. Sa starenjem populacije, očekivano opterećenje ovih bolesti će u budućnosti biti sve veće. Ultrazvuk se može koristiti u dijagnostici, ali i u liječenju te kao pomoć pri primjeni terapije u bolestima mišićno-koštanog sustava. U ovom radu opisat ću primjenu ultrazvuka u nekima od najčešćih bolesti mišićno-koštanog sustava.

Ključne riječi: ultrazvuk; mišićno-koštani sustav; dijagnostika

3 Basic Physics and Technology of Medical Diagnostic Ultrasound

K. T. Dussik was the first person to use ultrasound as a medical imaging modality in 1942.(68) Ultrasound was first used in examination of the musculoskeletal system, also by Dussik, in 1958. Since then, significant advances in the US probe design and refined manufacturing techniques have resulted in transducers with outstandingly high bandwidth and sensitivity, with excellent spatial resolution and penetration.(17) Improvements in technology have led to the widespread use of ultrasound in medical diagnosis.(58)

Ultrasound uses sound waves to create high resolution images in real time. Piezoelectric crystals found in the transducers convert physical energy of sound waves into electrical energy. They have the ability to both emit and receive sound waves. The emitted travel through tissues of different densities, a portion of them are reflected back to the transducer as a series of echoes; echoes provide necessary data to create 2D image of the underlying tissue. The image that is formed is composed of pixels, each pixel having three properties of each reflected echo. First is the intensity of the echo – the brightness being related to the amount of sound that is reflected. Second property is the depth at which the echo is reflected, corresponding to the vertical position of the image – it is related to the time elapsed between sound wave emission and its echo's return; the deeper the structure, the longer the time. The third property is the horizontal position of each pixel - a function of the crystal's position on the transducer.(76)

Most lesions in the musculoskeletal system lie near the surface, and it is important to select proper equipment that meets the demands for this type of examination. High resolution ultrasound scanning with 10-12 megahertz probes is used when examining the musculoskeletal system.(20) Low frequencies (~2-5 MHz) are used to evaluate deep structures, for example the hip. Low frequencies have deeper beam penetration. Mid-range frequencies (<8-12 MHz) are used for evaluation of the knee or deeper structures of the shoulder. Higher frequencies (10-18 MHz) are used for evaluating superficial structures such as the wrist, foot, ankle, and have a greater resolution. Absorption increases proportionally with frequency. Higher frequencies provide greater resolution, and lower frequencies provide greater depth of penetration. Curvilinear array probes produce lower frequencies, and linear array transducers produce middle

and higher range frequencies. Using highest frequency possible that allows for sufficient depth of penetration is advised; a classic linear array is usually used. B-mode is basically the only mode used when imaging the musculoskeletal system. Pulses are reflected from tissues according to their physical properties, and the amplitude of the returning echo is represented as “brightness” in a designated pixel on the screen.(76)

Artefacts can occur due to the change of sound propagation through tissues of different densities, and alterations in the path taken by the ultrasound beam. Anisotropy occurs during imaging of tendons, which exhibit the greatest amount of anisotropy, as well as nerves and muscle. When the US beam is at an angle of less than 85° , most of the waves do not reflect back to the transducer causing a hyperechoic structure to become hypoechoic. This may lead to misdiagnosis, and can be corrected by angling the probe sound waves perpendicular to the structure with a rocking (heel-toe) maneuver. Acoustic shadowing occurs when imaging bone, foreign bodies, and areas of calcification. The dense substance reflects sound waves, which prevents the operator from visualizing tissues deep to the structure. Acoustic enhancement occurs when visualizing anechoic structures. The structures deep to the anechoic lesion appear more echogenic. Reverberation artefact occurs when imaging highly echogenic structures. The sound waves reflect back and forth between the transducer and the echogenic structure. Comet tail artefact is seen in objects that strongly reflect ultrasound waves, such as crystals, metallic and glass foreign bodies. It is seen deep to the structure, and is gradually decreasing in size. Refraction artefact (edge shadowing) is caused by waves being reflected/bent from their original direction after impacting curved surfaces.(76)

“The Doppler effect is the change in the observed frequency of the sound wave (f_r) compared to the emitted frequency (f_t) which occurs due to the relative motion between the observer and the source.”(58) When tissues move with respect to the sound beam emitted from the transducer, there is a change in the frequency of the sound reflected from the tissue proportional to the velocity of the moving interface relative to the transducer. Doppler can be used to evaluate vascularity of tissues and hyperaemia, which might point to inflammation, or formation of granulation tissue.(76)

Ultrasound utilizes a type of energy we are exposed to every day – acoustic energy. Since inception human beings are constantly surrounded by and exposed to sounds.

Our bodies, and our insides are producing sounds as well as receiving them. We are constantly absorbing and emitting acoustic energy; our bodies are used to this form of energy.(9)

In general, ultrasound is seen as a relatively safe diagnostic method, but there are still some questions left unanswered regarding its safety. Even though ultrasound produces little or no ionisation at diagnostic imaging levels, there is a possibility of minute amounts of irreversible mechanical change associated with its use. At high power levels, ultrasound waves have the ability of destroying tissues. Ultrasound waves are inducing molecular vibrations, changes in fluid flow, and movement in cellular structures, as well as influencing membrane permeability and neuronal migration.(42) There is a rise in tissue temperature caused by the ultrasound beam, which is highest at the bone surfaces and the surrounding soft tissues. The heating of the tissue arises due to the absorption of the ultrasound beam by the bone and its emission of heat to the nearby tissues. The operator should have this in mind whilst examining the eye as the eye is poorly perfused, and therefore has a decreased capability for getting rid of the excess heat.(89) One should also be cautious when examining embryos and foetuses, as they could be sensitive to the rise in temperature caused by the ultrasound beam.(41) The extent of the effects of ultrasound on the human body are still not completely clear.

Ultrasound has been in use for many decades. Most of the safety data available is quite outdated, as the information is derived from B-mode scanners which were widely used before the mid-1990s. With the development of new machines (the ones in use today use 10-15x higher acoustic output levels), and new imaging trends such as “souvenir scanning” and 4D ultrasound, higher doses are being delivered to patients. This raises concerns about the safety, and there is a need to be on the lookout for possible adverse effects. Most of the information we have concerning bioeffects of ultrasound is coming from animal studies, and we don't know how the results relate to humans, such as a study linking the exposure to ultrasound waves to changes in neuronal migration in mouse embryos.(40, 89) Interestingly enough, the use of ultrasound has been linked to left handedness in male children.

Ultrasound operators should be skilled and well educated, and should keep the thermal and mechanical indices as low as reasonably possible by regulating the acoustic output during the examination. Examinations should be performed only in cases when

there is medical indication to do them. Recent surveys show that a lot of ultrasound users aren't well informed about the bioeffects of ultrasound on the human body.(41, 107) There is a need for better education regarding the safety of ultrasound, and a need for further research on this topic.

4 Normal and Pathological Appearance of Structures in the Musculoskeletal System

Basically every structure contained within the musculoskeletal system can be readily assessed with the help of ultrasound examination; however some can be assessed more easily than others.

US is gold standard technique for examination of tendons. Tendons appear hyperechoic and have a fibrillar pattern on ultrasound examination. This appearance is due to the visualization of tendon fibres forming the tendon. The dense arrangement of the fibres produces anisotropy on US imaging; when the US beam is positioned perpendicularly to the tendon, the tendon will appear normal – hyperechoic with a fibrillar pattern, but as the angle changes to one less than or greater than 90°, the tendon will appear artifactually hypoechoic.(80, 29, 49) In short axis view, the tendons appear oval or round, and are characterized by several homogeneously scattered spotty echoes.(109) Tendon pathology includes tendinosis, tendinopathy, tears, calcifications, and calcific tendinitis. In tendinosis, the tendon is morphologically altered and its echogenicity is changed on ultrasound examination.(1, 104, 65) There may be hypoechoic linear regions of decreased echogenicity, and mucoid degeneration presenting with more globular regions having decreased echogenicity. Tears appear as discretely marginated lesions involving a portion or the full width of the tendon, depending on the extent of the tear (full-thickness vs. partial tear). They can be hypoechoic or anechoic. Parts of the tendon can calcify or ossify, and the calcifications can present as linear or globular foci of increased echogenicity, and posterior acoustic shadowing.(1)

Ligaments appear similar to tendons on US examination, but are generally thinner and shorter. Ligaments look like hyperechoic bands with internal fibrils that join unossified hypoechoic epiphyses of adjacent bones. Ligaments exhibit anisotropy, and the operator should take care not to confuse a hypoechoic area with a partial tear.(137)

Muscles are composed of individual fibers, cylindrical or prismatic in shape. The epimysium can be seen as a hyperechoic external band 2-3 mm in thickness, continuing along the corresponding tendon profile on longitudinal view. The perimysium can be observed as a hyperechoic line separating contiguous hypoechoic muscular fascicles from one another. The pennate structure of muscles can be assessed in longitudinal axis views where the hypoechoic fibro-adipose septa converge with a mainly parallel course, a central aponeurosis, appearing as a thin highly reflective band. US evaluation of muscle fiber direction represents an important parameter to measure the pennation angle, which is measured between the muscular fibers' direction and the central aponeurosis axis (usually corresponding with the longitudinal muscular axis). The value of the pennation angle depends on the function of the muscle and on the functional state of the muscle (contraction vs. relaxation).(103)

Ultrasound provides higher spatial resolution over MR imaging, when imaging nerves. On long axis, nerves appear elongated, with multiple hypo/hyperechoic parallel lines, corresponding to the neuronal fascicles. On short axis, high resolution US depicts nerves as honeycomb-like structures, composed of hypoechoic rounded areas (the fascicles) embedded in a hyperechoic background (interfascicular epineurium).(103)

Hyaline cartilage appears as a hypoanechoic layer delimited by thin, sharp, hyperechoic margins. Normal articular cartilage appears as a well-defined layer with several distinguishing features. It has a high degree of homogenous transparency, due to high water content, sharp and continuous synovial space-cartilage interface (superficial margin), sharp hyperechoic profile of the bone-cartilage interface (deep margin). The synovial space-cartilage interface is thinner than the bone-cartilage interface, and they are best visualized when the direction of the US beam is perpendicular to the cartilage surface. Sharp margins and homogenous echotexture are hallmarks of normal cartilage.(103)

Only the surface (cortex) of a bone is visible on ultrasound examination. Normal cortex of the bones appears smooth, hyperechoic, with posterior acoustic shadowing. A fracture will be accompanied by a focal discontinuity of the cortex with or without a cortical step-off.(28) Evaluation of stress fractures may show a periosteal reaction with hyperaemia on Doppler examination. There may also be hypoechoic periosteal fluid and haemorrhage, as well as cortical discontinuity.(14)

5 The Shoulder

The shoulder is the most commonly ultrasonographically evaluated joint in the human body.(49) When examining the shoulder the operator is evaluating the rotator cuff tendons (supraspinatus, infraspinatus, subscapularis, and teres minor), long head of the biceps brachii, and the AC joint. Dynamic examination is performed to assess the presence of subacromial impingement.(61)

The most commonly occurring tendon pathology in the shoulder is that of the supraspinatus tendon.(49) Young sportsmen participating in sports involving overhead sporting activities; throwing, swimming (such as water polo), and racquet sports (such as tennis) have higher risk of developing rotator cuff tendinopathy and shoulder impingement syndrome.(137) Such sports cause hypermobility and dysfunction of the static stabilizers of the shoulder. Bursitis can develop along with tendinopathy.

Both ultrasound and MRI are used in evaluating pathology of the shoulder, but ultrasound has an advantage over MRI as it gives the operator an ability to perform dynamic examination of the shoulder joint.(137) High resolution ultrasound is superior to MRI in detecting small and medium-sized rotator cuff tears.(88) Larger tears are better assessed with MRI.

5.1 Rotator cuff tears

Rotator cuff lesions represent up to 60% of shoulder pathology.(122, 81) The rotator cuff is composed of the tendinous insertions of supraspinatus, infraspinatus, teres minor and subscapularis muscle around the head of the humerus. It functions as a depressor of the humeral head. Rotator cuff disease is the most common cause of shoulder pain. Pathology of the rotator cuff ranges from impingement syndrome (a rotator cuff tendinopathy) to degenerative cuff tears.(88) Most rotator cuff tears occur at the site of supraspinatus tendon insertion to the greater tuberosity.(123) They can occur together with anterior dislocation of the shoulder.(111)

A patient having a rotator cuff tear is usually aged over 45, and presents with a history of recurring shoulder pain, stiffness and weakness of the shoulder. Pain in the mid-range of abduction may point to a minor rotator cuff tear. Injection of a local anaesthetic (10 ml 1% lignocaine) into the subacromial space may help to distinguish the cause of

loss of movement due to pain from that due to a rotator cuff tear.(111) There may be weakness on abduction and external rotation of the shoulder. Neer's impingement sign is a clinical test which is over 80% sensitive for subacromial impingement or a rotator cuff tear. It is performed by stabilizing the scapula with one hand, and raising the affected arm in passive flexion, abduction, and internal rotation with the other hand. It is positive when pain is elicited by this manoeuvre.

Ultrasound can be used in imaging of rotator cuff tears. US criteria for full thickness supraspinatus tear are: nonvisualization of the tendon or focal tendon defect filled with fluid and debris, together with loss of normal outward convexity of the tendon, and dipping of the deltoid muscle into the tendon gap. Other US signs are bone irregularity of the greater tuberosity, joint effusion, and fluid in the subdeltoid bursa. Intra-articular fluid within the biceps tendon sheath, when associated with bursal effusion, has a sensitivity of 22%, and a specificity of 99%. When visualizing partial thickness tears, focal hypoechoic or anechoic defect in the tendon may be visible, involving either the bursal or the articular surface. Tendon tears and tendinosis may both appear hypoechoic and secondary findings may aid in differentiating the two conditions. Indirect signs include diminished thickness of the tendon, and although both produce areas of hypoechogenicity, tears tend to create more focal and well defined defects. Ultrasound sensitivity has been shown to be between 57-100%, and specificity 76-100% for full-thickness tears, and 41-93% sensitivity and 85-94% specificity for partial-thickness tears.(75) Therefore, ultrasound imaging is less accurate for diagnosing partial thickness tears. US and MRI have comparable accuracy for detecting full and partial thickness tears

Treatment options are conservative and surgical. Conservative treatment consists of analgesic medication; NSAIDs, subacromial infiltration of lidocaine, and corticosteroids, and physical therapy.(75) If symptoms persist after 3 months of conservative therapy or if they recur, surgery is advised.

6 The Elbow

The elbow has a significant range of motion; it has a great range of hinged as well as rotational motion. This predisposes the elbow to trauma, and development of degenerative processes.(13) Due to its superficial location, the elbow can be readily assessed with the help of ultrasound.(92) Epicondylitis is the most common soft tissue pathology of the elbow.(129) Tendon abnormalities are frequent and problematic, and ultrasound can be used to evaluate tendons for presence of tendinopathy, tears, and enthesisinopathy.(92) Ultrasound can be used in interventional procedures in the elbow joint. Soft tissue injuries and masses, as well as articular abnormalities can also be appreciated.

6.1 Lateral Epicondylitis (“Tennis Elbow”)

Lateral epicondylitis is the most common tendon lesion in the elbow. It got its name due to high prevalence in sportsmen participating in racquet sports.(136) It is caused by eccentric overload of the backhand.(32) Factors contributing to the development of lateral epicondylitis in tennis players are overuse, poor technique, a heavy racquet, and a grip that is too small.(20) The pain may start when the player begins using a new racquet, after playing with wet balls, and due to overhitting the ball (against the wind). Up to 50% of tennis players are affected sometime in their career.(74) Although the name would suggest it being a lesion affecting mostly sportsmen, it is actually more common in people not participating in professional sports. Tennis elbow is common in carpentry, bricklaying, sewing, knitting, cutting meat, plumbing, working on cars... It is most commonly linked to work-related activities, especially repetitive ones, involving repetitive wrist extension, and loaded and repeated gripping.(20, 43, 111) The patients mostly affected by this condition are middle aged persons, 30-60 years old.(48)

The patient feels the pain on the outer side of the elbow, although the pain may radiate into the forearm, is exacerbated by wrist extension, and there is focal pressure tenderness at the lateral epicondyle(70, 110) Specific movements may provoke the onset of pain. Such movements are turning a door handle, shaking hands, pouring our tea, or lifting with the forearm pronated.(20)

Ultrasound has 80% sensitivity and about 50% specificity. Due to such low specificity, ultrasound should be used only to evaluate the extent of disease in patients with specific clinical findings. It may detect structural changes, tendon thickening, hypoechogenicity, fibrillary disruption, tears, and calcification. Presence of hyperaemia may be assessed by Doppler.

The majority of patients respond to conservative therapy (including corticosteroid injections). If the patient doesn't respond well, and the disease remains refractory after 6 months to a year, surgical treatment is pursued.(123)

6.2 Medial Epicondylitis (Golfer's Elbow)

Medial epicondylitis may develop from degeneration and tearing of the common flexor tendon relative to overuse of the flexor-pronator group of muscles.(13) Some sports, where there is repetitive valgus stress to the elbow joint, such as golf, javelin throwing, and squash, may predispose to the development of this condition.(13) It can be caused by repetitive performing of dumbbell curls with supination or barbell curls.(49) Medial epicondylitis is most commonly present in the 3rd through 5th decade, with male to female ratio of 2:1.(123) It is found in manual labourers, and can be seen in individuals requiring repetitive use of the elbow, forearm, and wrist.(18)

This condition usually presents with pain and tenderness over the anterior aspect of the medial epicondyle. Medial epicondylitis is the most common cause of medial elbow pain.(123) The pain may radiate into the forearm and is precipitated by grasping and resisted pronation of the forearm, or resisted wrist flexion. In medial epicondylitis pain can be caused by pressure over the medial common tendon, or by resisted wrist flexion.(13) Ulnar nerve neuropathy is an associated finding in more than 50% of cases.(123)

US appearance is similar to other degenerative tendinopathies, and includes hypoechoic changes in the tendon secondary to tendinosis or a partial-thickness tear.(13) Thickening of the tendon may be observable, as well as the tendon being more heterogenous in echotexture compared to the other side. Partial tears may be seen as anechoic gaps on US examination. Calcifications may be present.(76)

Hyperemia from neovascularization may be visible using Doppler US.(116) Ultrasound sensitivity has been reported to be 95%, and specificity 92% for clinical disease.(95) Radiography and MRI may also be used in imaging of the elbow joint in cases of medial epicondylitis. EMG/NCV is indicated if ulnar neuropathy is suspected.(18)

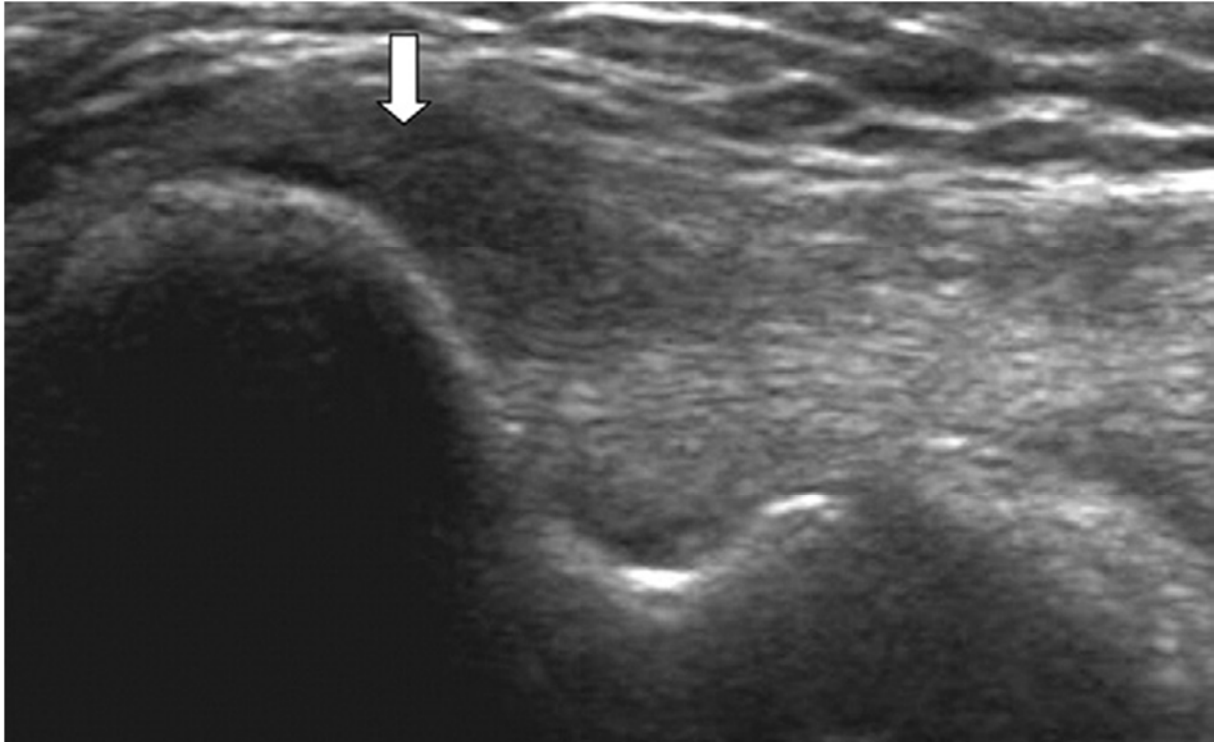


Figure 6.1 A longitudinal ultrasonographic image of the common flexor tendon of the left elbow in a 56-year-old woman with medial epicondylitis. The tendon had a focal hypoechoic area (arrow) that was consistent with tendinosis.(95)

Treatments vary from oral anti-inflammatory medications, rest, ice, physical therapy, injections such as ultrasound-guided corticosteroids, percutaneous needle tenotomy, to surgical treatment.(116)

6.3 Snapping Triceps Syndrome

Snapping triceps syndrome is a relatively rarely occurring condition. The syndrome is more common in males, in manual workers, sportsmen, and patients with previous elbow trauma, with the first symptoms appearing in adolescence and early adulthood.(132, 135, 115) In snapping triceps syndrome there is anterior dislocation of

the medial head of the triceps muscle relative to the medial epicondyle which can occur in combination with the dislocation of the ulnar nerve.(13) Two “snaps” can be felt over the medial elbow, the first snap indicating dislocation of the ulnar nerve at 70° to 90° of flexion, and the second one at 115° of flexion indicating dislocation of the medial head of the triceps muscle. The snapping sensation is most intense during eccentric loading of the triceps muscle, for example when performing push-ups, and the patients should be advised to not do movements which exacerbate the condition such the aforementioned pull-ups, weight training in general, and repeated elbow flexion.(128) This condition has been associated with the cubitus varus deformity, hypoplasia of the medial epicondyle, hypertrophy or prominence of the distal triceps muscle belly, and there have been a few reports of new onset snapping triceps syndrome after ulnar nerve transposition.(53, 115) Dislocation of the triceps muscle over the lateral epicondyle has been described in the literature only once, by Spinner and Goldner in 1999.(114)

Patients may present with medial elbow pain and tenderness, snapping sensation in the elbow, ulnar neuropathy – sensory deficit or paresthaesias in the distribution of the ulnar nerve, with the symptoms being more prominent during physical activity.(13) The snapping causes pain in true snapping triceps syndrome.(132) The examiner should palpate the ulnar nerve in the groove, and examine its laxity in extension whilst trying to dislocate or sublunate the nerve medially by applying digital pressure. Upon elbow flexion, the ulnar nerve will usually relocate itself. The snaps mentioned before, are going to be felt as the examiner flexes the elbow.

Imaging methods used in conjunction with clinical examination of snapping triceps syndrome are MRI and dynamic ultrasound.(132) Ultrasound is the preferred method for diagnosing snapping triceps syndrome as it is fast, inexpensive, and dynamic.

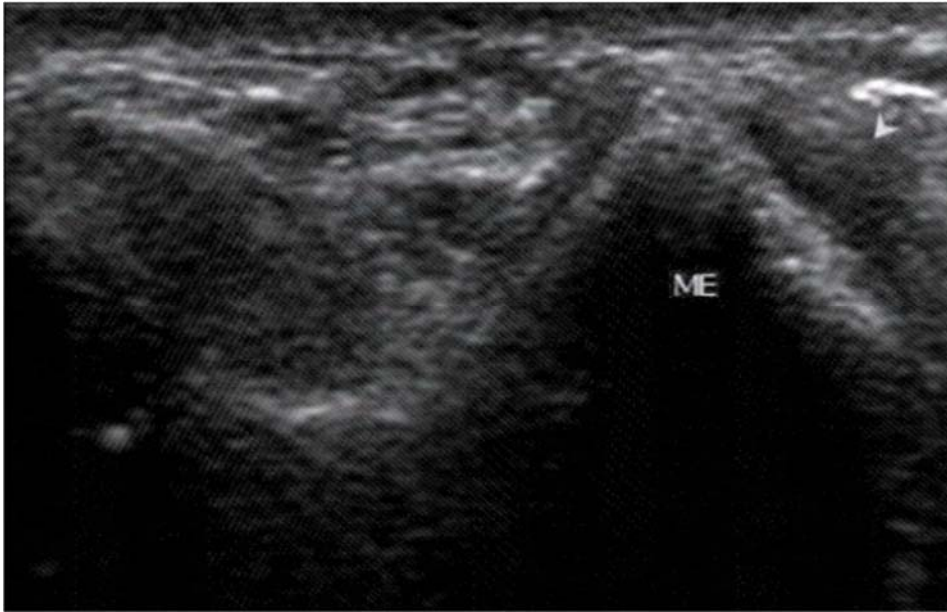


Figure 6.1 At full flexion, the ulnar nerve along with the medial head of the triceps have dislocated (shown by the arrowhead) over the medial epicondyle (ME). The dislocation was perceived as a snapping sensation felt through the transducer. (50)

Cubital tunnel syndrome is a differential diagnosis for snapping triceps syndrome, and snapping triceps syndrome may cause compression of the ulnar nerve inside the cubital tunnel.(82, 91, 54) Cubital tunnel syndrome presents with medial-side elbow pain, and paresthesias.(99) Medial epicondylitis (golfer's elbow) causes pain in the medial side of the elbow, and may present with ulnar nerve symptoms. Distal rupture of the triceps muscle presents with a history of a single snap, pain, swelling, and a lack of complete elbow extension.(131) It is also a differential diagnosis, although quite rare.

The treatment is conservative in the first 3-6 months following diagnosis. This includes avoiding exacerbating activities, as well as use of NSAIDS, elbow splinting, physical therapy, kinesio tape... If there is no improvement in this period, surgical treatment is advised. The results of surgery have been found to be good to excellent.(131)

6.4 Ulnar Nerve Dislocation

Ulnar neuropathy at the elbow can be caused by static structures compressing the ulnar nerve (for example scar tissue) or by dynamic factors resulting from changing

anatomic relationships through movement in the elbow joint.(117) Ulnar nerve instability most commonly occurs in the cubital tunnel, which is an osteofibrous tunnel formed by a groove between the olecranon and the medial epicondyle bridged by the Osborn retinaculum. The abnormal position of the ulnar nerve predisposes it to injury.(25) Ulnar nerve dislocation can be seen in up to 20% of asymptomatic elbows.(92) Etiology is thought to be either traumatic or idiopathic. One proposed cause is the congenital absence of the cubital tunnel retinaculum.

Ultrasound can be used in diagnosing and demonstrating ulnar nerve dislocation, which can occur with or without snapping triceps syndrome.(13) US imaging at full elbow flexion can enable the operator to visualize the intermittent dislocation of the ulnar nerve over the medial epicondyle in case of a loose or absent retinaculum.(62) The operator should not apply excessive pressure over the area, as this may result in a false negative finding.(76) Differentiation of causes of medial elbow snapping, snapping triceps syndrome vs. ulnar nerve dislocation, is important as treatments differ. Ultrasound can aid in differentiating the two conditions.(13) Treatment ranges from anti-inflammatory agents, physical therapy, and splints to ulnar nerve transposition surgery.(62)

7 Hand and Wrist

The structures in the hand and wrist are positioned superficially, and as such are ideal for ultrasound examination.(116) Dynamic scans are easily performed in this region. The wrist is the second commonest joint evaluated in some centers, as it is a joint commonly evaluated in rheumatologic referrals.(92)

7.1 Gamekeeper's Thumb (Skier's Thumb)

It is a common in certain sports, such as cycling and skiing.(133) It is also common in basketball, hockey, and wrestling.(60) Historically, it has been described in gamekeepers (hunters) strangling rabbits (and other little animals) by forcefully extending the neck; those hunters had chronic lesions of the ulnar ligament at the MCP joint.(13, 56) Skiers develop the lesion due to acute injury of the aforementioned

ligament, and skier's thumb accounts for up to 50% of injuries to the hand in skiers.(90) The grip position on the ski pole when the patient is falling causes the injury to the ulnar collateral ligament due to forceful abduction of the thumb when it strikes the pole or is caught in the ski pole strap, or by forced abduction of the thumb as it hits the ground. The impact can cause a simultaneous avulsion of a part of the bone adjacent to the ligament.(110)

The patient presents with pain on the ulnar side of the hand. Inflammation, swelling, and hematoma can be seen upon inspection of the affected limb in acute UCL injury.(6) Prior to performing the stress tests on the injured joint, an X-ray should be obtained to rule out fractures. In case there is an avulsion fracture present on the X-ray, the stress testing should still be performed.(6) The examination is painful, and an anaesthetic can be applied to the adductor side of the thumb ahead of performing the required examinations.(110) There can also be severe swelling accompanying the injury, and in this case a splint can be used and kept on for 3-4 days until the swelling subsides and the patient can be re-examined.(78) Examination of the UCL is done by applying valgus force with the thumb in 30 degrees of flexion; if there is more than 30 degrees laxity, or 15 more than on the healthy thumb, UCL rupture is likely.

The affected ulnar collateral ligament appears hypoechoic, swollen on ultrasound examination, and the ligament itself can look interrupted. According to some studies ultrasound has 88% sensitivity and 83% specificity for displaced ruptures, and 91% for nondisplaced ruptures of the collateral ulnar ligament.(57) Besides X-ray and US imaging, MRI can also be used in evaluation of skier's thumb.

Conservative therapy consists of splinting, and flexion/extension exercises. Stener's thumb is a lesion occurring in cases where there is a complete rupture of the ulnar collateral ligament of the first MCP joint, with the ruptured ligament interpositioned underneath the adductor aponeurosis. Surgery is indicated in this case, and in cases where there is a displaced bony avulsion. It should be delayed until the inflammation has resolved.(6)

Skier's thumb is a frequently missed injury (often misdiagnosed as a simple "sprain"), and not identifying it can lead to the patient developing arthrosis, as well as persistent

instability of the joint.(88,110) The loss of joint stability may cause problems with prehensile (pinching) activities.(111)

7.2 Glomus Tumour

Glomus tumours are a rare type of benign neoplasm.(47) They are derived from a neuromyoarterial glomus, a structure contributing to regulation of body temperature, and are usually found in the skin, especially subungally, at the tips of the digits in patients in 4th and 5th decades of life.(123) They may be associated with extrinsic bone erosion. Glomic tumours account for about 1.6% of all soft tissue tumours.(73)

The patient may present with a “glomus tumour specific” scenario in their history: excruciating pulsatile pain triggered by exposure to cold or pressure exerted over the nail. The classic triad of glomus tumour symptoms are: pain, point tenderness and cold sensitivity, and they are present in about a third of the patients suffering from this condition. Glomus tumours are diagnosed clinically in majority of cases.(93)

On ultrasound, it appears as a small, solid, hypoechoic, well-defined nodule, and is more or less homogenous, with regular borders.(73) Colour Doppler will show internal hypervascularity. Pulsed Doppler may show a large systolic murmur. MRI may also be used in glomus tumour imaging.(123) Radiography can be used to differentiate glomus tumours from exostoses.(73)

The definitive treatment is surgical excision of the lesion. Recurrences are common.(13)

7.3 Carpal Tunnel Syndrome

Carpal tunnel syndrome is the most commonly occurring peripheral nerve entrapment syndrome, and is one of the most commonly encountered pathologies in the upper extremity.(7) The prevalence of CTS is around 4-5%, the age group most affected being 40-60 year olds.(24) It has a predilection for the dominant hand.(123) Carpal tunnel syndrome is characterized by compression and/or traction of the median nerve at the level of the wrist. CTS is more common in, appears in association with or is

precipitated by certain conditions such as pregnancy, myxoedema, rheumatoid arthritis, chronic renal failure, gout, amyloidosis, space occupying lesions, diabetes, flexor tenosynovitis, callus, and fracture dislocation of carpal bones, trauma, haemorrhage, benign tumors (ganglion cyst, hemangioma, neuroma, lipoma), acromegaly...(12,110,123) The association of CTS with diabetes is a significant one as 5-8% percent of patients with carpal tunnel syndrome have diabetes mellitus.(20) Clinicians should exclude diabetes mellitus in all patients with carpal tunnel syndrome. Certain anatomic conditions can make the patient more susceptible to develop carpal tunnel syndrome: narrow tunnel, presence of the median artery, abnormal and accessory tendons and muscles, bifid median nerve at the level of the carpal tunnel, proximal division of median nerve in the forearm.(13) Familial liability to pressure palsy (HNPP) is a dominant disorder which predisposes the patient to develop multiple entrapment mononeuropathies, including carpal tunnel syndrome.

Patients with carpal tunnel syndrome typically present with the complaint of burning night pain, tingling, and numbness in the radial aspect of the hand and the first three fingers.(13) The pain may wake the patient during the night.(110, 111) The night pain, also called brachialgia paresthetica nocturna, is probably caused, at least partially, by oedema and flexion at the wrist joint for prolonged periods of time.(13) Upon waking the patient will typically shake the affected hand in an attempt to “get the circulation going” and relieve the symptoms, or will hang the hand over the side of the bed; although usually just changing the position of the hand and the wrist will help with the symptoms.(110, 111) In more severe cases, patients might present with weakness and clumsiness. There may also be atrophy in the region of the thenar eminence, referred to as “ape hand”. The median nerve pathology changes with the progression of the disease, in early stage the median nerve doesn't show pathologic changes, and as the disease progresses, the changes become visible – the nerve starts to swell, demyelinate, and undergo fibrosclerosis.(13) In longstanding CTS, the patient may experience permanent sensory and motor deficits.

The diagnosis of carpal tunnel syndrome is most commonly based on patient history, and physical examination, as well as on electrodiagnostic studies, and ultrasound.(116) The conduction velocity of the median nerve in the carpal tunnel is reduced in patients with CTS.(110) There are a few provocative tests used when

examining the wrist of a patient suspected to have carpal tunnel syndrome. Sensory symptoms may be reproduced by percussing over the median nerve (Tinel's sign) or by holding the wrist fully flexed for a minute (Phalen's test). On ultrasound examination of the wrist of a patient with carpal tunnel syndrome, one may be able to appreciate the changes in median nerve morphology and echogenicity, as well as changes in surrounding structures such as the transverse carpal ligament and the soft tissues passing through the carpal tunnel. However, normal appearance of the median nerve does not exclude carpal tunnel syndrome, and a "normal" median nerve is often found in early stages of CTS. The flattening ratio of the median nerve, bowing of the flexor retinaculum, swelling of the median nerve, and nerve hypervascularization on Doppler have been used as diagnostic criteria for US examination of patients with carpal tunnel syndrome; median nerve swelling and hypervascularization having the highest accuracies (91% and 95%).(77) Ultrasound is possibly more accurate in helping establish the diagnosis of carpal tunnel syndrome in patients having early or mild CTS.(71)

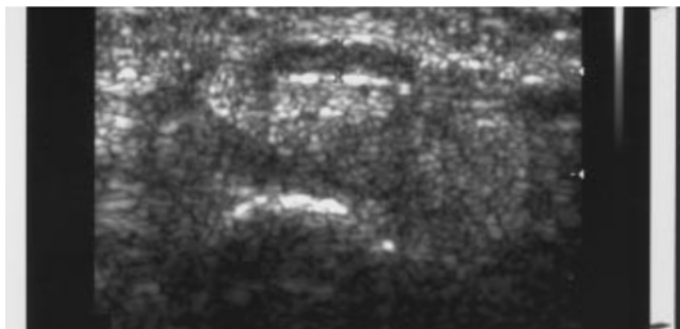


Figure 7.1 43-year-old man with carpal tunnel syndrome. Sonogram shows flattened, swollen, and hypoechoic left median nerve. Flexor retinaculum immediately superficial to nerve is seen to bow anteriorly. Caliper measurements of major and minor axes of nerve are shown. (38)

Patients may be treated conservatively with NSAIDs and splinting. Corticosteroid injections can be used in treatment of carpal tunnel syndrome. They have been shown to decrease pain, paresthesias, and improve function in patients diagnosed with carpal tunnel syndrome.(5,31,45) Persistent cases may require surgical treatment, and can be either open or endoscopic.(20)

7.4 Ganglion Cysts

Ganglion cysts are most commonly occurring space-occupying lesions of the hand and wrist.(120) Female to male ratio is about 3:1.(10) They are most commonly seen in females in their 20's and 30's.(94) The exact mechanism of development of ganglion cysts is unknown.(103) They are articular cysts originating from the articular cavity, usually 1-2 cm in size, filled with gelatinous fluid, and they feel firm on palpation.

The most common presentation is an asymptomatic mass; only 19.5% of patients had symptomatic ganglion cysts according to Barnes et al.(10) Ganglion cysts may appear inside the carpal tunnel, arising from the deep portion of the tunnel.(13) They are able to dislocate the median nerve, as well as flexor tendons against the transverse carpal ligament. Ganglion cysts may cause aches in the wrist, decreased range of motion, decrease in grip strength, and paresthesias in case of nerve compression.(116) They are the leading cause of Guyon tunnel syndrome, and present in 30-40% of cases.(39) Radial tunnel syndrome, also known as radial pronator syndrome, is caused by the compression of the posterior intraosseous nerve in the proximal forearm, and ganglion cysts can cause radial tunnel syndrome by compression at the proximal radioulnar joint.(123) RTS can be confused with lateral epicondylitis, as it has similar pain distribution and mechanism. The pain is felt over the lateral forearm with repetitive elbow extension. Muscle atrophy, fatty tissue infiltration, and oedema may be present, particularly in the supinator muscle.

In ganglion cysts the fluid is located eccentrically to the tendon.(13) Ganglion cysts are usually found over the dorsal or palmar aspects of the wrist.(13) Ganglion cysts are located most commonly on the dorsal side of the wrist - this is the case in 70% of patients having ganglion cysts; they occur on the volar side of the wrist in about 20% of the cases.(121) They appear as lobulated anechoic masses with posterior acoustic enhancement. Although cysts are most commonly described as anechoic, they can be hypoechoic and mixed anechoic/hypoechoic in appearance.(134) They can also be lobular, with varying numbers of lobes; they can have septa, and areas of hyperechogenicity inside the cyst. Trauma can make ganglion cysts appear more complex.(49) Dorsal ganglion cysts appear superficial to the scapholunate ligament.(32)

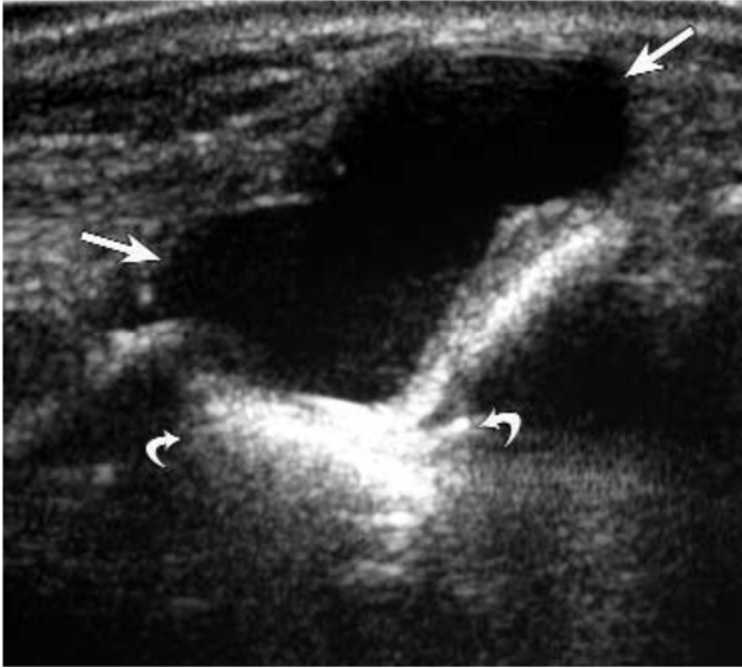


Figure 7.2 Dorsal ganglion cyst in a 32-year-old woman. Sagittal sonography shows a 30-mm anechoic ganglion cyst (arrows) with posterior acoustic enhancement (curved arrows). Note the lobular and well-defined border. (134)

One of the differentials for ganglion cysts are venous aneurysms which can be caused by trauma to the deep or superficial veins.(13) A patent venous aneurysm may be confused with a ganglion cyst. Continuity with a vein, or blood flow through the lesion may help distinguish the two diagnoses, and will reinforce the diagnosis of a venous aneurysm.

There are usually three possibilities in the treatment of wrist ganglia: waiting, aspiration with injection, and surgical treatment.(76) Spontaneous resolution rate of ganglion cysts occurs in around 50% of cases.(34, 35, 84, 139) Therefore, in asymptomatic patients with normal ROM, watchful waiting is the best option. In symptomatic patients, either aspiration, or surgical removal should be used. Surgery might produce more symptoms such as pain and stiffness in the period after removal of the cyst.(19) The surgery can be done via arthroscopic or open air approach.(102) Ultrasound guided aspiration of the cyst is recommended in volar ganglia, due to the risk of trauma to structures surrounding the ganglia – the radial artery, and the recurrent branch of the median nerve.(19)

7.5 Giant Cell Tumour of the Tendon Sheath

The most frequently occurring soft tissue masses in the hand are ganglion cysts, giant cell tumours of the tendon sheath and lipomas.(13) Giant cell tumour of the tendon sheath is a firm, nodular, well-defined, tumour-like mass found most commonly on the palmar aspect of the fingers and hand.(96) They have a predilection for smaller joints, but may occasionally be found around larger joints such as the knee and the hip. There are two types of GCTTS, localized nodular (common in hand) and diffuse type (common in joints). The incidence is about 1:50 000, it affects people between 30 and 50 years old, and the female to male ratio is 3:2.(100) The aetiology of giant cell tumours of the tendon sheath is not well understood; some patients (15%) may present with a history of trauma. GCTTS presents as a slowly growing mass, which may or may not be painful.(21)

Ultrasound can be used as the first imaging method in diagnosing GCTTS. On US, giant cell tumours of the tendon sheath appear as painless, solid, hypoechoic nodules with a hypervascular pattern, and are located adjacent to or enveloping a tendon.(13) GCTTS may cause bone erosions due to mass effect, and changes to the bone cortex may be seen on sonography.(102) Differential diagnoses, such as ganglion cysts may be excluded with the help of ultrasound. MRI and radiography may also aid in diagnosis of GCTTS.

Treatment consists of surgery with or without neoadjuvant radiotherapy. The tumour tends to recur following surgical excision, the recurrence being 25-45%, Radiotherapy may decrease the chance of recurrence.(11, 96)

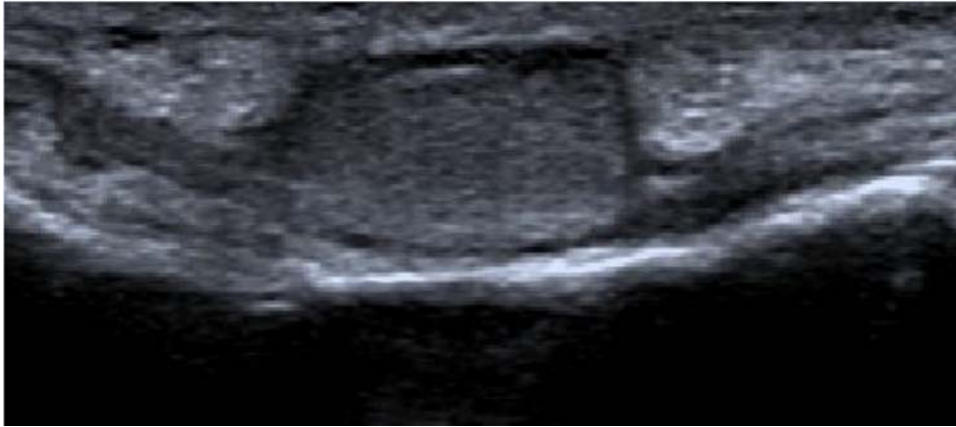


Figure 7.3: *Ultrasonographic image of the first finger of a 69-year-old woman: Hypoechoic vascularized soft tissue mass around the flexor tendon that proved to be a giant cell tumour.(21)*

8 The Hip

Ultrasound is most commonly used in the evaluation of hip pain. Tendon pathology, including tear, tendinopathy, and avulsions and muscle injury can be assessed. US is also gaining a more important role in the evaluation of rheumatological diseases.(92)

8.1 Morel-Lavallee Lesion

Morel-Lavallee lesion is subcutaneous sero-hematic fluid collection, first described by the French physician Maurice Morel-Lavalle in 1853.(49) Morel-Lavallee lesion can occur in athletes who fall off mountain bikes. It is caused by direct trauma to the hip and pelvis, and is a closed internal degloving injury where the subcutaneous tissue is torn away from the fascia.(102) The resulting cavity is filled with hematoma and liquefied fat, and necrotic tissue, and lymph. Morel-Lavallee lesions are not exclusive to the hip (greater trochanter), they can also occur in other parts of the body, for example the flank, buttocks, and lumbodorsal regions. The lesion may organize and form a pseudocapsule, which prevents spontaneous reabsorption. Neglected lesions can become infected.

Acutely presenting patients may have a soft, fluctuant area of ecchymosis; skin hypermobility, soft tissue oedema; palpable bulge; abrasions; local contusions, and hypoesthesia near the region of the trauma (59, 26). Patients with chronic lesions

present one month up to many years following initial trauma, and during that time, the lesions may increase in size, remain stable or regress. Enlarging lesions may become painful and firm, and may lead to a misdiagnosis of a soft tissue tumor.(26, 85)

The lesion is located superficial to the muscle layer and beneath the hypodermis The appearance of the lesion on ultrasound examination depends on the chronologic age of the lesion. Acute lesions appear heterogeneous and have irregular margins. On the other hand, chronic lesions are more homogeneous, and tend to have smoother borders.(49)

Treatment for Morel-Lavallee lesions is usually conservative, and they are managed with compression bandages. Larger lesions may require percutaneous aspiration, but fluid may re-accumulate following aspiration.(102) Steroid injections are not effective.(16) Surgery may be performed and the lesion excised.(22, 66)

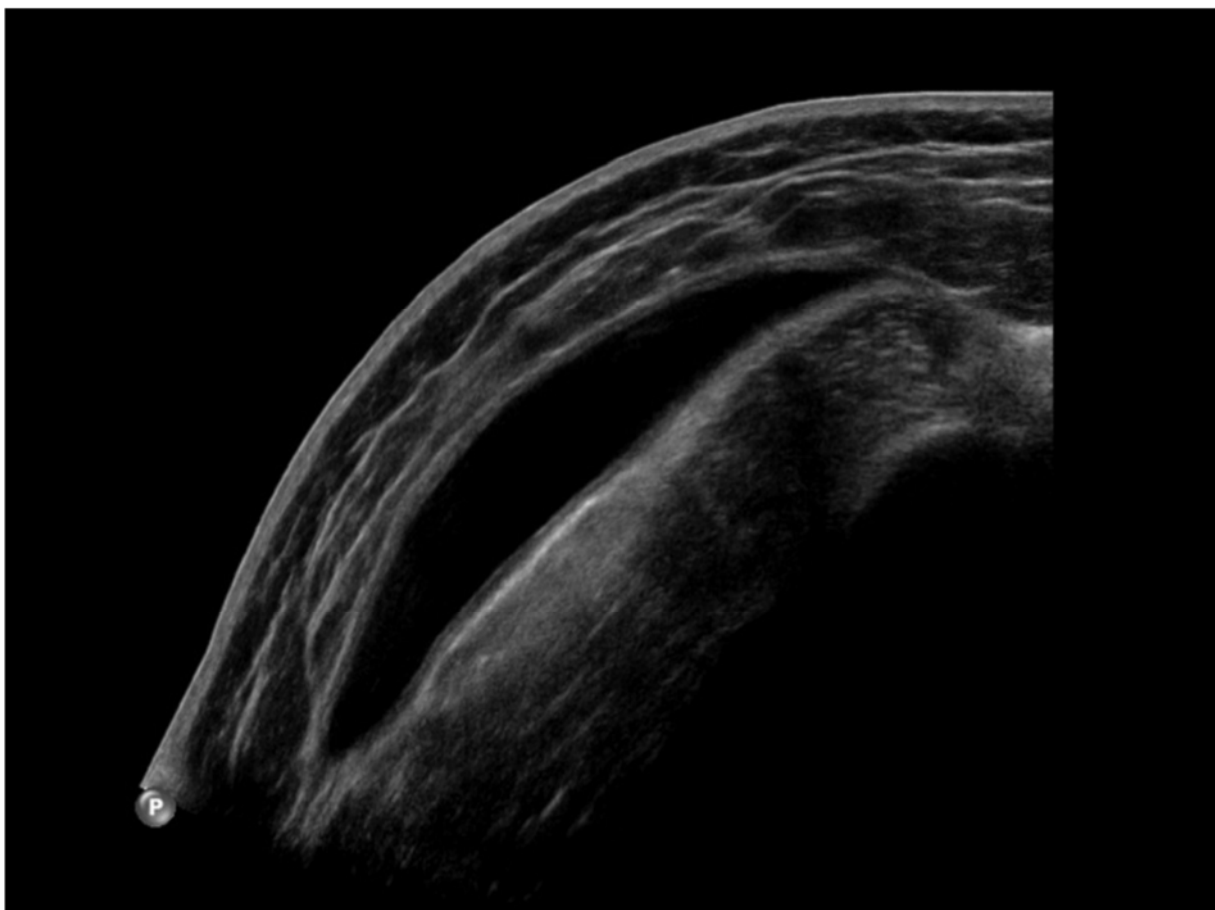


Figure 8.1: Classic US appearance of Morel-Lavallée effusion: anechoic collection between the subcutaneous tissue and the deep fascia.(79)

9 The Knee

Trauma of the knee, and pathology of the knee in general, is very common. Sprains of the knee ligaments are one of the most common injuries in sports, second only to ankle sprains.(49) In addition to acute, the knee is a predilection site for many chronic conditions such as osteoarthritis, rheumatoid arthritis, and a myriad of other rheumatologic conditions. Acute knee trauma can be a trigger for developing early-onset arthritis.

Although MRI is the imaging technique of choice for evaluating knee trauma, and plays a vital role in preoperative evaluation, ultrasound has its own advantages. Ultrasound is a relatively cheap diagnostic method.(92) The operator has the ability to take the patient's history while examining him/her, which can be of great help when evaluating knee pathology and its relation to patient's symptoms. A lesion can produce symptoms in specific joint positions or during specific movements, and manipulating the joint into symptom-producing positions can help the operator better understand and localize the pathology they are evaluating. Ultrasound can also be used for visualizing the lesion during aspiration or biopsy. The ultrasound plays a minor role in the area of knee imaging, but it is more efficient than MRI in imaging of chronic tendinosis, and is of great help in evaluating tendon injuries and ruptures.(32)

When imaging the knee, the operator should follow a specific sequence; for example beginning anteriorly, and progressing medially, laterally, and finally posteriorly. To be able to examine joint systematically and thoroughly, one should perhaps resort to using a check list of structures that need to be assessed.(92)

9.1 Baker's Cyst (Popliteal Cyst)

Baker's cyst is a "synovial fluid filled mass located in the popliteal fossa", in the posteromedial region of the knee, between the belly of the gastrocnemius muscle and semimembranosus tendon.(33, 44) It occurs in both children and adults, but presents differently, and has a different clinical picture in these two age groups. In children Baker's cysts are commonly asymptomatic, have no clinical importance, and tend to be found during routine physical examination. One study found that 6.3% of children

had Baker's cysts on their knee scans.(49) In adults, on the other hand, cysts can be a sign of joint pathology such as meniscal tears (being the most common associated pathology, 82% of patients have lesions of the medial meniscus, and 38% have lesions of the lateral meniscus), ACL deficiencies, cartilage degeneration, osteoarthritis, infections such as tuberculosis, gout, and rheumatoid arthritis.(6) Observing the back of the patient's knee while they are standing will show a tender and swollen mass which can produce pain and a feeling of pressure. Patients can experience pain during squatting and kneeling, and range of motion may be restricted during flexion of the knee.(20)

Popliteal cysts may rupture causing sudden, intense pain in the back of the knee, and lower leg swelling, which can be confused with deep venous thrombosis – a common differential diagnosis.(33) Ultrasound is used as the first diagnostic step to rule out deep venous thrombosis.(123) It can also detect fluid inside soft tissues following the rupture. One might be able to observe a “crescent sign” on the skin – an ecchymotic area around the malleoli secondary to rupture of the cyst.(20) In popliteal venous thrombosis a thrombus will be visible as a hypoechoic structure in an uncompressible vein. Doppler US can help further clarify the diagnosis.(123) Intramuscular myxoma can resemble a Baker's cyst in appearance, but does not communicate with knee the joint itself. Tennis leg is another differential diagnosis. It is caused by the rupture of the medial head of the gastrocnemius muscle, and ultrasound is the diagnostic method of choice in patients in whom this diagnosis is suspected.(20)

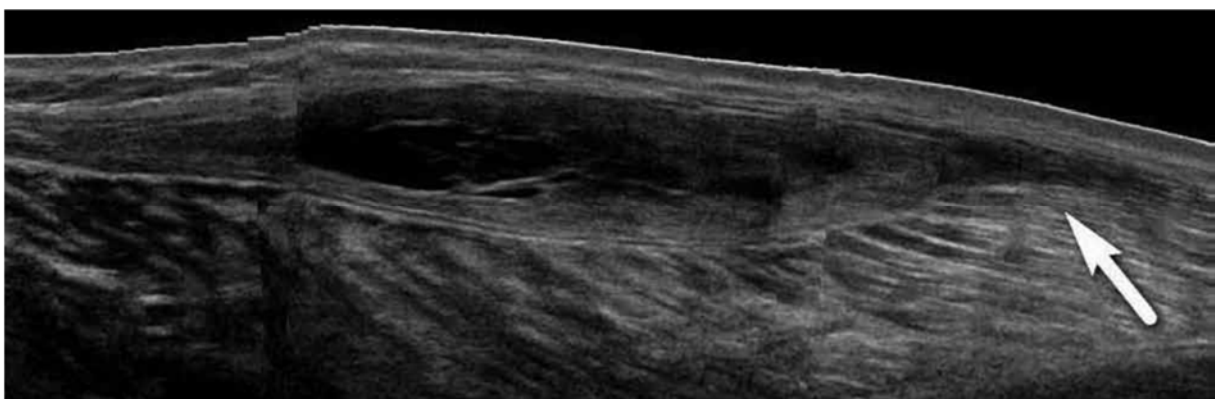


Figure 9.1. *Complicated Baker's cyst: leakage is shown. A longitudinal sonogram shows a Baker's cyst with pointed appearance of distal end (arrow), indicative of recent leakage.(126)*

When diagnosing Baker's cyst by ultrasound it is important to note the location of the cyst, it should be just lateral to the gastrocnemius muscle, for the operator to be able to rule out other pathology.(32) The cyst presents as an anechoic lesion with acoustic enhancement.(137) The ultrasound is the method of choice for detecting cysts in patients diagnosed with intraarticular pathology, as well as detecting complications (rupture, compression) in patients with pre-existing cysts.(13) Other painful lesions in the posterior fossa such as posterior ganglia could be mistaken for a popliteal cyst. Viewing recent radiographs of the patient's knee, and comparing them to ultrasound findings can help with interpreting the results, and may aid in giving the correct diagnosis. US is the first line imaging method used in investigating soft tissue "lumps" in children as it does not require sedation, and doesn't emit ionizing radiation.

Baker's cyst can be aspirated for diagnostic purposes, and to decrease patient discomfort by decreasing the pressure inside of the cyst. Steroids are injected into the cyst following aspiration. This decreases the risk of recurrence and helps with chronic symptoms. Treatment of adult patients relies on treating the underlying knee pathology. Surgery is advised in in large symptomatic cysts.(20) Unless the pre-existing knee pathology is addressed, the cyst may recur after surgical excision. Treatment is generally not required in children, and about half of the lesions resolve with the use of conservative treatment alone.(33, 130) Surgical excision is recommended in symptomatic children with persistent painful symptoms.

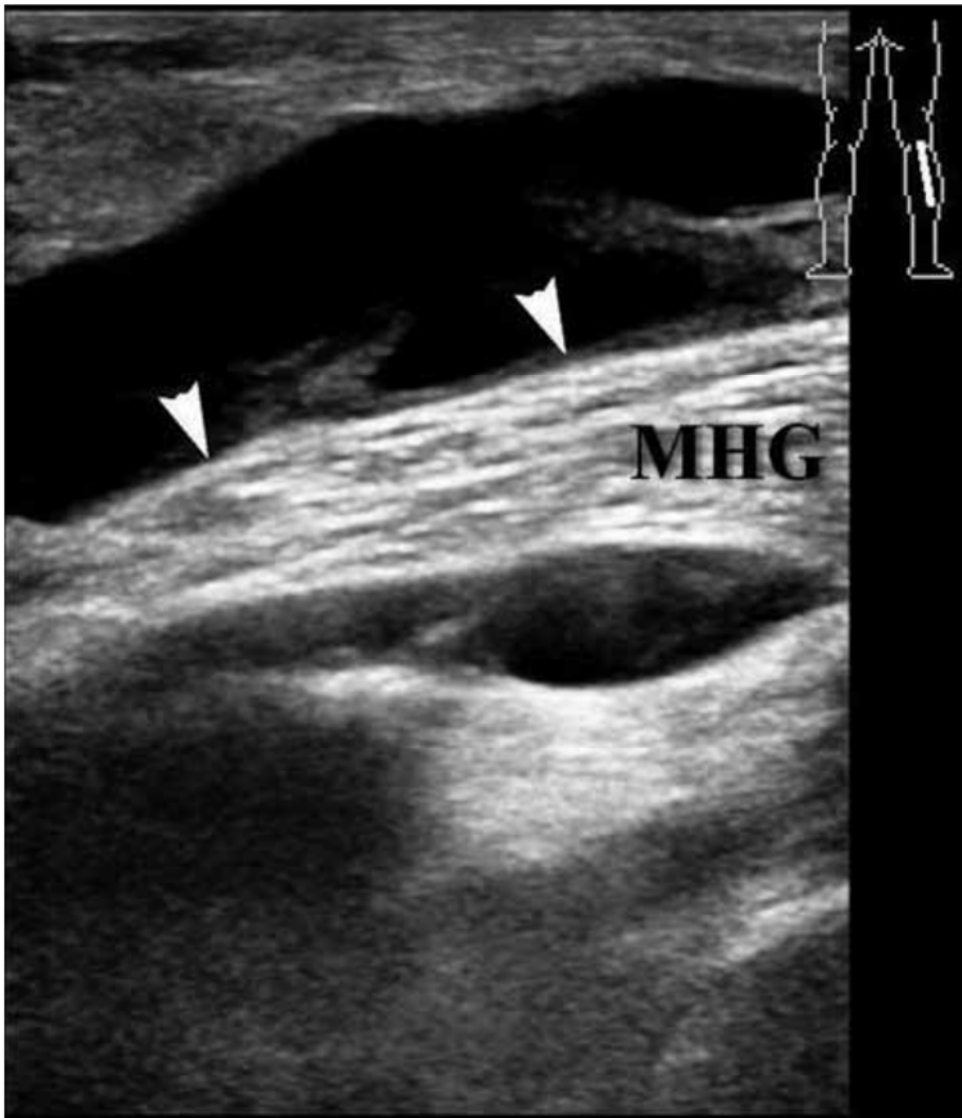


Figure 9.2 Baker's cyst: sonographic appearance. (a) A transverse sonogram shows the different components of a typical Baker's cyst: the base (1), the neck (2) located between the tendon of the semimembranosus (arrow) and the tendon of the medial head of the gastrocnemius (arrowhead), and the large body (3). (b) A longitudinal sonogram depicts the base and the body of the cyst separated by the straight tendon (arrowheads) of the medial head of the gastrocnemius (MHG).(126)

9.1 Infrapatellar Bursitis

In this condition the swelling is located below the patella and superficial to the patellar ligament.(111) Bursitis can be a result of local blunt trauma, or may develop secondary to microtrauma.(13) The disease affects patients who have continuous monotone

movements of the patella or continuous mechanical strain.(67) It can be found in certain occupations such as tiling and carpentry. Deep infrapatellar bursitis is the most common bursitis in children having spondyloarthritis or traumatic lesions caused by sports activities.(30) It can also occur in Osgood-Schlatter disease. Occasionally the bursa can be affected in gout.(111) Athletes, particularly cyclists and sportsmen involved in sports involving jumping, may be affected by this condition.(49) It has also been described in people with abnormal biomechanics of the knee, such as patients with cerebral palsy.(83)

A swollen and hypoechoic distal tendon, which may be associated with fluid distension of the infrapatellar bursa, can be seen on ultrasound examination. A minimal amount of bursal fluid may be seen on US in normal states, this is especially true in cases where high-frequency transducers are used. The finding is thought to be pathologic in cases where there is more than minimal bursal fluid present, and is reliable when the knees are examined bilaterally and there is clinical correlation to the US finding.(13)

Tendon degeneration, subcutaneous infrapatellar bursitis and soft tissue inflammatory changes, seen as a result of prolonged work activity while kneeling in an upright position, is described as “housemaid’s knee” or “clergyman’s knee”. US may show a distended hypoechoic subcutaneous bursa located superficially to the distal patellar tendon.(23) The wall of the bursa may be thickened, internal septations may be present, and in acute lesions a hyperaemic pattern may be visible on colour Doppler imaging. Chronically calcifications may develop inside the aforementioned bursal wall and appear on US examination as hyperechoic masses with posterior acoustic shadowing. Repeated stress causes inflammation, thickening of the bursal wall, and eventually development of calcifications. Treatment consists of analgesic therapy, as required, and physical therapy. The patient should avoid kneeling, or if kneeling is unavoidable, use protective padding. Pretibial ganglion cysts are a differential diagnosis. They occur in patients who had surgery for anterior cruciate ligament reconstruction. A painful mass filled with gelatinous fluid can be seen over the anteromedial proximal tibia. Treatment is surgical en-bloc removal of the cyst.(13)

10 Ankle and Foot

The structures in the foot and the ankle are located superficially, and are therefore particularly suitable for ultrasound evaluation. One of the most common indications is assessment of tendon pathology, particularly the posteromedial and posterolateral compartments. Tendinopathy, tenosynovitis, and tendon tears can be evaluated, and so can subluxations, dislocations, and impingement.

10.1 Morton Neuroma

Morton neuroma is one of the most common nerve entrapment syndromes in the lower extremity.(13) Its development can be explained by local impingement of the interdigital nerve at the point where the interdigital nerve tracks deep to the intermetatarsal ligament and between the metatarsal heads. Repetitive impingement and friction can lead to degeneration of the interdigital nerve, perineural fibrosis, and formation of the Morton neuroma.(4) This is one of the possible pathogenic mechanisms leading to development of Morton neuroma. Other possible mechanisms include: ischemia, enlarged bursa and repetitive microtrauma of the interdigital nerve.

The typical patient is a middle-aged woman complaining of sharp, local pain at the base of the web space radiating to the two involved toes which is exacerbated by walking, wearing pointed and high heeled shoes, and is relieved by taking the shoe off and massaging the foot. Some patients report a feeling of “a rock in the shoe”

Morton neuroma has the appearance of an ovoid, hypoechoic mass.(98) It is located proximal to the metatarsal heads in the intermetatarsal space. It is most commonly located in the space between the heads of the 3rd and 4th metatarsal bones, where the web space is smaller in size, and the interdigital nerve is relatively more fixed in its place.(13) When comparing ultrasound to MRI in diagnostics of Morton neuroma, ultrasound has been found to be more sensitive, especially when imaging small lesions. It is more affordable, less time consuming, and patient friendly.(64) It can also be used in excluding major differential diagnoses, and it can be used as guidance for therapeutic procedures.

The treatment consists of ice to alleviate tenderness, and metatarsal padding, footwear modifications, radiofrequency ablation, physical therapy (extrinsic and intrinsic foot muscle strengthening exercises), local injections (corticosteroid, anaesthetic, alcohol), and surgical therapy.(63)

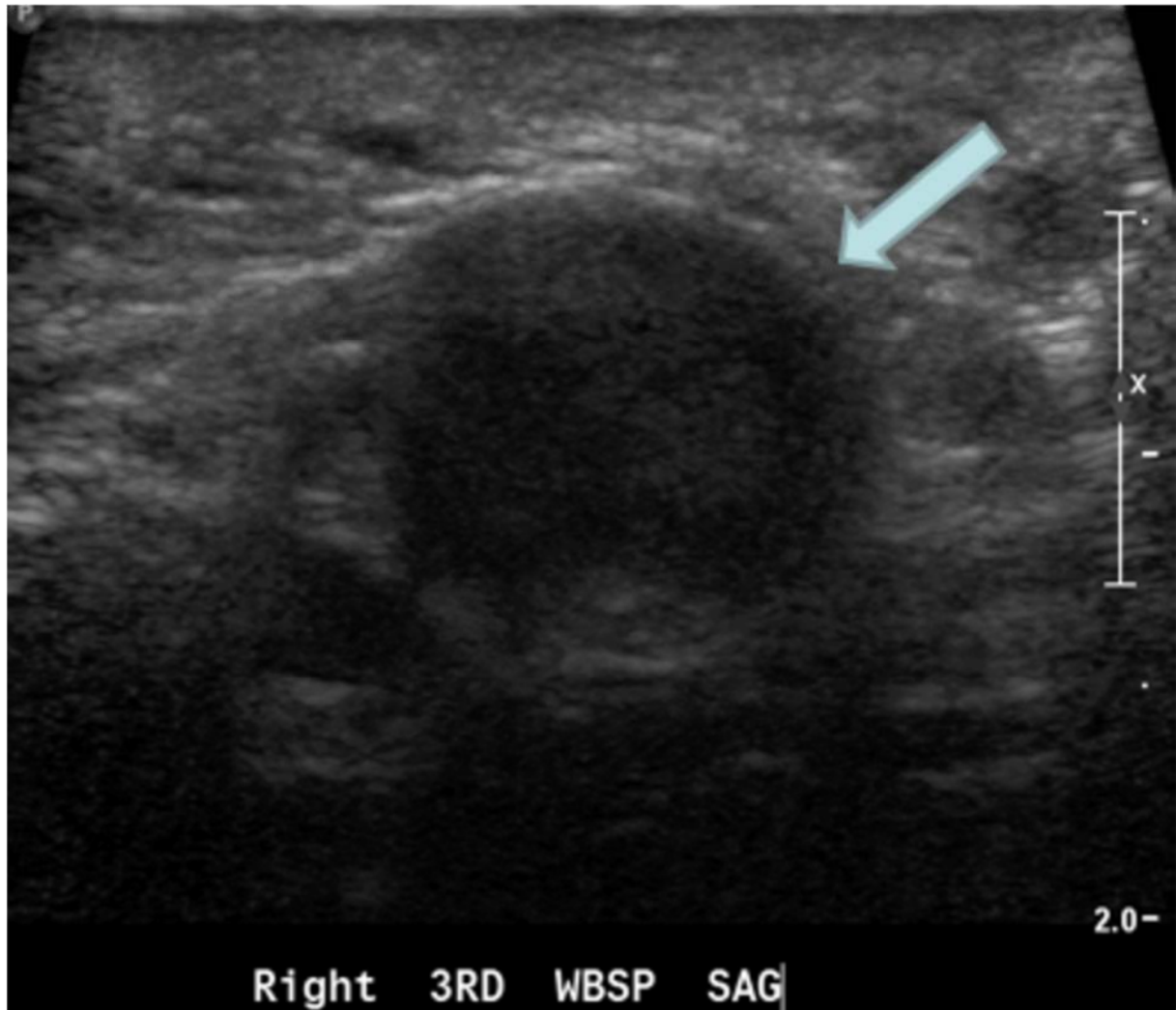

Figure 10.1: Morton's neuroma. Sagittal plane examination of the plantar aspect of the right 3rd intermetatarsal space is performed by slowly moving the probe between the heads of the 3rd and 4th metatarsals (arrow). It confirms presence of a solid hypoechoic mass (Morton's neuroma), allows better delineation and measurement of its longitudinal extent.(64)

11 Pediatric Musculoskeletal Ultrasound

When working with the paediatric population ultrasound as a diagnostic method has many advantages. Unlike the X-ray or CT it is not a source of harmful ionizing radiation.

Magnetic resonance imaging and CT require the patients to keep still, which can be difficult to achieve in a young, anxious child. Restlessness could prompt the use of sedation, or even anaesthesia. Ultrasound is a dynamic method, which gives the operator the ability to interact with the child in a way which is impossible to achieve with some other diagnostic methods. Ultrasound is non-invasive, painless, and relatively inexpensive. In the following text we'll touch upon the roles of diagnostic ultrasound in paediatrics.

11.1 Developmental Dysplasia of the Hip

The femoral head and acetabulum develop in utero as a unit, and as the child is born and continues its development and growth, it is imperative the parts of the joint remain in position for the joint to be able to maintain its optimal growth and function. Acetabular development depends on the head of the femur being in its normal position, and on movement of the joint. If the femoral head is out of place, the acetabulum develops poorly.(37) Developmental dysplasia of the hip is a common name for a spectrum of different abnormalities of the hip joint, with a varying spectrum of severity.(111)

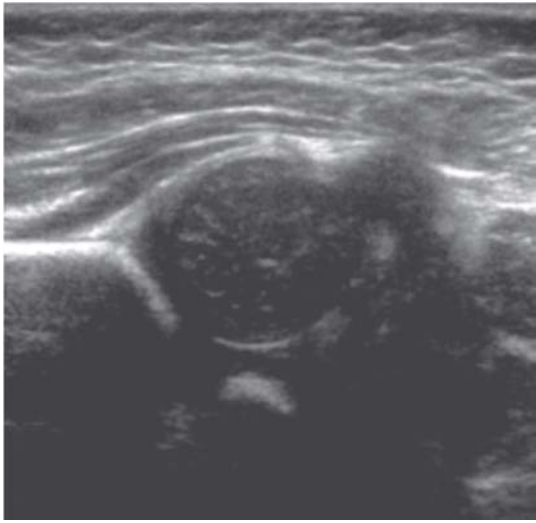
Developmental dysplasia of the hip affects about 1 in 1000 newborns, mostly affects female children (7:1), and the incidence varies worldwide.(110) The factors contributing to the difference in incidence are genetic and cultural. For example, persons of Mediterranean origin may have higher risk of developing developmental dysplasia of the hip.(111) In certain cultures, for example Lapps and North American Indians, where babies are swaddled and their legs kept straight, with their knees and hips extended, dislocation tends to be very common. The incidence in these populations is about 25-50 cases per 1000. Other risk factors contributing to the development of this condition include intrauterine malposition, especially breech position, birth weight of >5 kg, oligohydramnios prematurity, congenital calcaneovalgus foot deformity, being first-born.

Examination of the hips is compulsory in children up to the age of two, even in those in whom the hips appear to be developing normally. Early examination of the hip joints is important as treatment is most effective in the early stage.(110) If there is a full dislocation in the hip joint, and the condition is not treated early, the child will fail to walk normally at around one year of age.(173) It is thought that every 10th hip

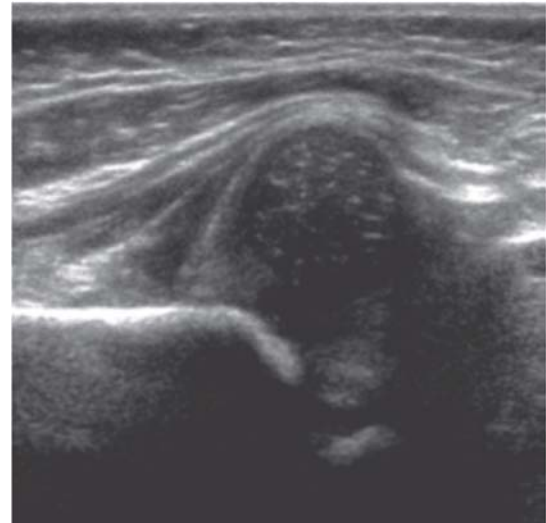
replacement surgery could be the result of secondary osteoarthritis which developed due to mild/subclinical hip dysplasia.(173) DDH is the most common cause of coxarthrosis in women younger than 40.(106) It is important to note that, even in expert hands, not every case of developmental dysplasia of the hip can be detected on physical examination alone. Clinical tests used in detection of developmental dysplasia of the hip – Ortolani and Barlow tests – are accurate only in about 74% of cases that may be demonstrated on imaging. They are highly specific clinical examinations, but they have low sensitivity.(118) These tests are performed at birth, and repeated when the child is 6 weeks old.(105) Ideally, all children should have repeat examinations at 6, 12 and 18 months of age to rule out late-appearing signs of DDH.(110) Radiologic methods used in detection of developmental dysplasia of the hip are US examination and radiography.

Ultrasound is used in newborns and infants up to 4-5 months of age, while their hips are cartilaginous.(105) Examinations should not be performed prior to the child being 4-6 weeks of age, as the hip tends to be hypermobile in the early weeks of life due to the effects of maternal hormones on the ligaments.(123) Static and dynamic ultrasound examinations of the hip joint can be performed.(106) Static US examination will show the coverage of the femoral head by the acetabulum (α angle), while dynamic examination will show the image of the hip joint whilst Ortolani and Barlow tests are being performed. Dynamic ultrasound examination allows the operator to detect movements in the hip joint which are ≥ 1 mm in size; and displacement of more than 2 mm, when stress is applied to the hip joint during dynamic examination, is pathological and requires treatment. There are two ways of using ultrasound in screening of babies for DDH; either screening the whole population, or screening only the children that are at high risk of having/developing DDH. Overuse of ultrasound examination in diagnosing DDH can lead to overtreatment, and increase in frequency of re-examination.(27) Some countries use ultrasound as a screening method in high risk populations only (for example the United States), whilst others offer a much wider coverage (such as Sweden) (3) It is important to note that clinical examination and ultrasound imaging should both support the same diagnosis; either presence or absence of DDH.(105) If they do not agree, one is probably wrong. Both ultrasound and clinical examination are operator dependant and subjective methods. Femoral capital epiphysis ossifies between 2nd and 6th month of age, and when the process is

finished, radiographs become the preferred imaging method as the ossified femoral head creates a shadow on ultrasound examination of the hip joint.(123)



A. Right



B. Left

Figure 11.1 *Ultrasound images of a 1-month-old baby's hips. (A) shows a located right hip and (B) shows a dislocated left hip.(125)*

AP radiographs are used for imaging of DDH in children older than 4.5 months (3-6 months). If developmental dysplasia of the hip is present, ossification delay of the acetabulum may be present, as well as visible subluxation or dislocation of the hip, and possible anomalies of the pelvis and sacrum.

Different methods, both surgical and nonsurgical, are used in the treatment of DDH depending on the extent of the condition and the age of the patient. Multiple types of splints may be used following hip reposition such as the Pavlik harness, Von Rosen splint and the pillow type splint. While the child is wearing the splint, the hips are held at 100 degrees flexion and in abduction. After the splint is removed, the child should remain in follow up until he/she starts walking. In older children closed reduction can be performed under anaesthesia following traction, and the new position of the joint is evaluated with arthrography. Closed reduction carries a risk of avascular necrosis of the femoral head. Following the procedure, the hips are splinted at 60 degrees of flexion, 40 degrees of abduction and 20 degrees of internal rotation. Severe cases of DDH may require open reduction and possible corrective osteotomy. In cases where

hip reposition surgery is required, MRI and CT are used to evaluate the hip joint postoperatively to assess whether the reposition has been successful. MRI is the preferred imaging method as CT scanning emits ionising radiation. These two methods, together with plain radiography, are used in preoperative evaluation of the hip joint prior to performing corrective osteotomy.(173) Aggressive therapy with Pavlik harness and surgery may cause avascular necrosis of the femoral head.(13) Doppler ultrasound and MRI with contrast can be used in prediction of the development of this much feared complication.(173)

12 Conclusion

Ultrasound has a widespread use in diagnostics of musculoskeletal system pathology. Besides its use in diagnostics, it can also be used as an imaging method in the evaluation of patients following treatment, as well as guidance in application of therapy. It is a versatile method and can be used in static as well as dynamic conditions. The fact that one can perform dynamic exams utilizing ultrasound enables the operator to observe the structure of interest in (full range of) motion. Ultrasound gives the operator an ability to talk to and interact with the patient which may aid in establishing the correct diagnosis. Patients can point out the positions which feel most uncomfortable and painful and in that way direct the course of the examination. Ultrasound is an affordable diagnostic imaging method. It doesn't utilize ionizing radiation, and as such is considered a safe diagnostic method. It is convenient for use in the paediatric population as due to the aforementioned safety, and as it does not require the young patients to be sedated or even anaesthetized during the course of the examination which might be required during MRI and CT imaging. Children needn't be separated from their parents during the examination which could help reduce anxiety associated with being examined. As ultrasound is a subjective and operator dependant imaging method, the operators should be well educated in the subject of both ultrasound and musculoskeletal anatomy and pathology. It is difficult to say what the future holds for musculoskeletal ultrasound. Interesting is the opinion of professor Wayne W. Gibbon who, almost 10 years ago, said that he believes that ultrasound will become a natural extension of the physical examination in disciplines dealing with the musculoskeletal system such as rheumatology, sports medicine, orthopaedic surgery, as is the case with echocardiography in cardiology.(46) Nowadays ultrasound is one of the most

rapidly expanding imaging techniques in musculoskeletal imaging, and MSUS is being utilized by an increasing number of physiatrists, orthopaedists, anaesthesiologists, radiologists and rheumatologists in their daily practice.(36)

Biography

Katarina Paušek was born in Zagreb, where she attended elementary school and high school. She is currently 6th year medical student at University of Zagreb, and is a student assistant in the course History Taking and Physical Examination

References

1. Adler RS, Finzel K (2005) The complementary roles of MR imaging and ultrasound of tendons. *Radiol Clin North Am* 43:771–807
2. Adler RS, Sofka CM (2003) Percutaneous ultrasoundguided injections in the musculoskeletal system. *Ultrasound Q* 19:3–12
3. Afaq A. A., S. Stokes, H. Fareed, H.G. Zadeh, M. Watson, Ultrasound in the selective screening of developmental dysplasia of the hip, *European Review for Medical and Pharmacological Sciences* 2011; 15: 394-398
4. Alexander IJ, Johnson KA, Parr JW: Morton's neuroma: A review of recent concepts, *Orthopedics* 10:103–106, 1987.
5. American Academy of Orthopaedic Surgeons. 2008. Clinical practice guideline on the treatment of carpal tunnel syndrome. <http://www.aaos.org/research/guidelines/ctstreatmentguideline.pdf>
6. Anderson, Daniel, Skier's thumb; Heyman P. Injuries to the ulnar collateral ligament of the thumb metacarpophalangeal joint. *J Am Acad Orthop Surg* 1997;5:224–9.
7. Atroshi I, Gummesson C, Johnsson R, Ornstein E, Ranstam J, Rosén I. Prevalence of Carpal Tunnel Syndrome in a General Population. *JAMA*. 1999;282(2):153-158. doi:10.1001/jama.282.2.153
8. Ayşe Merve Ata, Şule Şahin Onat, Levent Özçakar Ultrasound-Guided Diagnosis and Treatment of Morton's Neuroma; *Pain Physician*: February 2016: 19: E355-E357
9. Azhari, Haim. *Basics of Biomedical Ultrasound for Engineers*. Wiley-IEEE Press, 2010.
10. Barnes WE, Larson RD, Posch JL. Review of ganglia of the hand and wrist with analysis of surgical treatment. *Plast Reconstr Surg* 1964;34:570-578.
11. Bhavuk Garg, Prakash P Kotwal; Giant cell tumour of the tendon sheath of the hand; *Journal of Orthopaedic Surgery* 2011;19(2):218-20
12. Bianchi S, Montet X, Martinoli C, et al: High-resolution sonography of compressive neuropathies of the wrist, *J Clin Ultrasound* 32:451–461, 2004.
13. Bianchi, Stefano, Carlo Martinoli, I.F. Abdelwahab, A.L. Baert, L.E. Derchi, G. Rizzato, M. Valle, M.P. Zamorani. *Ultrasound of the Musculoskeletal System (Medical Radiology)*. Springer, 2007.

14. Bodner G, Stöckl B, Fierlinger A et al (2005) Sonographic findings in stress fracture of the lower limb: preliminary findings. *Eur Radiol* 15:356–359
15. Bomela LN, H Basson, NS Motsitsi, Morel-Lavallée lesion: A review, *SA ORTHOPAEDIC JOURNAL* Autumn 2008, pg 34-37
16. Borrero C, Maxwell N, Kavanagh E (2008) MRI findings of prepatellar Morel-Lavallee effusions. *Skeletal Radiol* 37:451–455
17. Bradley, Mike, Paul O'Donnell. *Atlas of Musculoskeletal Ultrasound Anatomy*. 2nd Edition. Cambridge University Press, 2010.
18. Brady C, Dutta A (2016) Medial Epicondylitis and Medial Elbow Pain Syndrome: Current Treatment Strategies. *J Musculoskelet Disord Treat* 2:014
19. Breidahl WH, Adler RS. Ultrasound-guided injection of ganglia with corticosteroids. *Skeletal Radiol*. 1996;25(7):635–8.
20. Brukner, Peter, Karim Khan. *Brukner & Khan's Clinical Sports Medicine*. 4th Edition. McGraw-Hill Education / Australia, 2011.
21. C. Santos Montón, J. M. Alonso Sánchez, D. C. Cuellar, P. A. Chaparro García, R. Corrales, J. D. Albillo Labarra; Salamanca/ES; Giant-cell tumor of the tendon sheath: when must we suspect it?
22. Carlson DA, Simmons J, Sando W, Weber T, Clemens B. Morel-Lavallee lesion treated with debridement and meticulous dead space closure. *Journal of orthopaedic trauma* 2007;21:140-4
23. Carr JC, Hanly S, Griffin J (2001) Sonography of the patellar tendon and adjacent structures in pediatric and adult patients. *AJR Am J Roentgenol*. 176: 1535–1539
24. Chammas M, Boretto J, Burmann LM, Ramos RM, dos Santos Neto FC, Silva JB. Síndrome do túnel do carpo – Parte I (anatomia, fisiologia, etiologia e diagnóstico). *Rev Bras Ortop*. 2014;49(5):429–36.
25. Childress HM. Recurrent ulnar-nerve dislocation at the elbow. *Clin Orthop* 1975; 108: 168–173.
26. Collinge C, Tornetta P. Soft tissue injuries associated with pelvic fractures. *Orthopaedic clinics of North America* 2004;35:451-6.
27. COMMITTEE ON QUALITY IMPROVEMENT, SUBCOMMITTEE ON DEVELOPMENTAL DYSPLASIA OF THE HIP. Clinical Practice Guideline: Early detection of developmental dysplasia of the hip. *Pediatrics* 2000; 104: 896-895.
28. Crag JG, Jacobson JA, Moed BR (1999) Ultrasound of fracture and bone healing. *Radiol Clin North Am* 37(737–751):ix

29. Crass JR, van de Vegte GL, Harkavy LA et al (1988) Tendon echogenicity: ex vivo study. *Radiology* 167:499–501
30. D'Agostino MA, Said-Nahal R, Hacquard-Bouder C, et al: Assessment of peripheral enthesitis in spondyloarthropathies by ultrasonography combined with power Doppler, *Arthritis Rheum* 48:523–533, 2003.
31. Dammers JW, Veering MM, Vermuelen M. Injection with methylprednisolone proximal to the carpal tunnel: randomized double blind trial. *Br Med J*. 1999;319:884–6.
32. Daniels, James M, William W. Dexter. *Basics of Musculoskeletal Ultrasound*. Springer, 2013.
33. Demange, Marco Kawamura. Baker's cyst. *Rev Bras Ortop*. 2011; 46(6):630-33
34. Dias J. J., V. Dhukaram, and P. Kumar, “ The natural history of untreated dorsal wrist ganglia and patient reported outcome 6 years after intervention,” *Journal of Hand Surgery: European Volume*, vol. 32, no. 5, pp. 502–508, 2007.
35. Dias J.J., K.Buch,“Palmar wrist ganglion: does intervention improve outcome: a prospective study of the natural history and patient-reported treatment outcomes,” *Journal of Hand Surgery*, vol. 28, no. 2, pp. 172–176, 2003.
36. Douis, Hassan, Steven L. J. James, A. Mark Davies. Musculoskeletal imaging: current and future trends, *European Radiology*, 2011, 478-484, DOI: 10.1007/s00330-010-2024-z
37. Duckworth, T., C. M. Blundell, and T. Duckworth. *Lecture Notes. Orthopaedics and Fractures*. 4th ed. The Lecture Notes Series. Chichester, UK ; Hoboken, NJ: Wiley-Blackwell, 2010.
38. Duncan, Ian, Sullivan P., Lomas F. (1999) Sonography in the Diagnosis of Carpal Tunnel Syndrome; *AJR* 173
39. Elias DA, Lax MJ, Anastakis DJ (2001) Musculoskeletal images. Ganglion cyst of Guyon's canal causing ulnar nerve compression. *Can J Surg* 44:331–332
40. Eugenius S. B. C. Ang, Jr, Gluncic V., Duque A., Schafer M.E., and Rakic P. Prenatal exposure to ultrasound waves impacts neuronal migration in mice; *PNAS* 2006 103 (34) 12903-12910, doi:10.1073/pnas.0605294103
41. European Committee of Medical Ultrasound Safety (ECMUS), Clinical Safety Statement for Diagnostic Ultrasound (2011)
42. Ffytche, Dominic H, Chris Guy. *Introduction to the Principles of Medical Imaging*. REV ed. edition. Imperial College Press, 2005.

43. Finestone, H. M., & Rabinovitch, D. L. (2008). Tennis elbow no more: Practical eccentric and concentric exercises to heal the pain. *Canadian Family Physician*, 54(8), 1115–1116.
44. Fritschy D., Fasel J., Imbert J.C., Bianchi S., Verdonk R., Wirth C.J. The popliteal cyst. *Knee Surg Sports Traumatol Arthrosc.* 2006;14:623–628
45. Gelberman RH, Aronson D, Weisman MH. Carpal-tunnel syndrome: results of a prospective trial of steroid injection and splinting. *J Bone Joint Surg Am.* 1980;62:1181–4.
46. Gibbon, Wayne W. The future of musculoskeletal ultrasound A personal perspective ACCESSING THE FUTURE Issue 3 Winter 1998 ISSN 1461-830X
47. Gómez-Sánchez ME, Alfageme-Roldán F, Roustán-Gullón G, Segurado-Rodríguez MA. Tumores glómicos digitales y extradigitales. Utilidad de la ecografía cutánea. *Actas Dermosifiliogr.* 2014;105:e45---e49.
48. Greenfield, C., & Webster, V. (2002). Chronic Lateral Epicondylitis: Survey of current practice in the outpatient departments in Scotland. *Physiotherapy*, 88(10), 578-594. doi: 10.1016/s0031-9406(05)60510-x
49. Guermazi, Ali, Frank W. Roemer, Michel D. Crema. *Imaging in Sports-Specific Musculoskeletal Injuries*. Springer, 2015.
50. Gupta V B, K B Patankar, F Paranjpe, J Patil Ultrasound diagnosis of ulnar nerve dislocation and snapping triceps syndrome *S Afr J Rad* 2012;16(2):65-67
51. Hak DJ, Olson SA, Matta JM. Diagnosis and management of closed internal degloving injuries associated with pelvic and acetabular fractures: The Morel-Lavallee lesion. *Journal of trauma injury infection and critical care* 1997;42(6):1046-51.
52. Haupt HA (2001) Upper extremity injuries associated with strength training. *Clin Sports Med* 20:481–490;
53. Haws M, Brown RE. Bilateral snapping triceps tendon after bilateral ulnar nerve transposition for ulnar nerve subluxation. *Ann Plast Surg* 1995; 34:550–1. 12.
54. Hayashi Y, Kojima T, Kohno T. A case of cubital tunnel syndrome caused by the snapping of the medial head of the triceps brachii muscle. *J Hand Surg [Am]* 1984; 9A:96–9. 25.
55. Hazem Hassouna, Dishan Singh Morton's metatarsalgia: Pathogenesis, aetiology and current management *Acta Orthop. Belg.*, 2005, 71, 646-655
56. Heim D.; The Skier's Thumb; *Acta Orthopaedica Belgica* Vol 65 – 4 – 1999

57. Hergan K., Mittler Ch, Oser W. Ulnar collateral ligament, Differentiation of displaced and nondisplaced tears with US and MR imaging. *Radiology*, 1995,194, 65-71
58. Hoskins Peter R. *Diagnostic Ultrasound*. 2nd Edition. Cambridge University Press, 2010.
59. Hudson DA. Missed closed degloving injuries: late presentation as a contour deformity. *Plastic and Reconstructive Surgery* 1996;98(2):334-7.
60. Husband J. B., McPherson S. A.; Bony skier's thumb injuries. *Clin. Orthop.*, 1996, 327, 79-84.
61. Jacobson JA (2013a) Shoulder ultrasound. In: *Fundamentals of musculoskeletal ultrasound*, 2nd edn. Elsevier, Philadelphia, pp 3–71
62. Jacobson, Jon A., MD Peter J. L. Jebson, MD Andrew W. Jeffers, MD David P. Fessell, MD Curtis W. Hayes, MD, Ulnar Nerve Dislocation and Snapping Triceps Syndrome: Diagnosis with Dynamic Sonography—Report of Three Cases, *Radiology* 2001; 220:601–605
63. Jain S, Mannan K. The diagnosis and management of Morton's neuroma: A literature review. *Foot Ankle Spec* 2013; 6:307-317.
64. Justaniah A., D. Elentuck, R. Chittenden; Burlington, MA/US. Why Ultrasonography for Morton's Neuroma?
65. Kainberger FM, Engel A, Barton P et al (1990) Injury to the Achilles tendon: diagnosis with sonography. *AJR Am J Roentgenol* 155:1031–1036
66. Kalaci A, Karazincir S, Yanet AN. Long standing Morel-Lavallee lesion of the thigh simulating a neoplasm. *Clinical imaging* 2007;31:287-91.
67. Kamper Lars, M.D. Patrick Haage, M.D images in clinical medicine, Infrapatellar Bursitis *The new england journal of medicine* N engl j med 359;22 november 27, 2008
68. Kane D, Grassi W, Sturrock R et al. A brief history of musculoskeletal ultrasound: 'From bats and ships to babies and hips.' *Rheumatology* 2004;43:931–933.
69. Kornaat PR, Bloem JL, Ceulemans RY, Riyazi N, Rosendaal FR, Nelissen RG, et al. Osteoarthritis of the knee: association between clinical features and MR imaging findings. *Radiology*. 2006;239(3):811-7.
70. Kotnis NA, Chiavaras MM, Harish S (2012) Lateral epicondylitis and beyond: imaging of lateral elbow pain with clinical-radiologic correlation. *Skeletal Radiol* 41(4):369–386. doi: 10.1007/s00256-011-1343-8

71. Koyuncuoglu HR, Kutluhan S, Yesildag A, et al: The value of ultrasonographic measurement in carpal tunnel syndrome in patients with negative electrodiagnostic tests, *Eur J Radiol* 56:365–369, 2005.
72. Krieg JC, Mohr M, Amer J, Bottlang M. Pelvic circumferential compression in the presence of soft tissue injury. A case report. *Journal of trauma injury infection and critical care* 2005;59:468-70.
73. Lee DK, Yang JH, Chang S, Won CH, Lee MW, Choi JH, et al. Clinical and pathological characteristics of extradigital and digital glomus tumours: A retrospective comparative study. *JEADV*. 2011;25:1392---7
74. Levent Ediz and Mahmut Alpayci, Electrotherapeutic Interventions For Tennis Elbow Or Lateral Epicondylitis: A Brief Review Of The Literature *Physics International* 3 (2) (2012) 44-49
75. Maffulli N (ed): Rotator Cuff Tear. *Med Sport Sci*. Basel, Karger, 2011, vol 57, pp 90–99
76. Malanga, Gerard, Kenneth Mautner. *Atlas of Ultrasound-Guided Musculoskeletal Injections (Atlas Series)*. McGraw-Hill Education / Medical, 2014.
77. Mallouhi A, Pülzl P, Trieb T, et al: Predictors of carpal tunnel syndrome: Accuracy of gray-scale and color Doppler sonography, *AJR Am J Roentgenol* 186:1240–1245, 2006.
78. Mandhkani Mahajana,, Christine Tolman, B. Würth, Steven J. Rhemrev (Dr.), Clinical evaluation vs magnetic resonance imaging of the skier's thumb: A prospective cohort of 30 patients,
79. Martel J., A. Bueno, L. Serra Bellver, S. Martin; Alcorcon/ES, Madrid, Sp/ES, Palma de Mallorca/ES
80. Martinoli C, Derchi LE, Pastorino C et al (1993) Analysis of echotexture of tendons with US. *Radiology* 186:839–843
81. Matava MJ, Purcell DB, Pudzki JR. Partial-thickness rotator cuff tears. *Am J Sports Med* 2005;33:1405–17.
82. Matsuura S, Kojima T, Kinoshita Y. Cubital tunnel syndrome caused by abnormal insertion of triceps brachii muscle. *J Hand Surg [Br]* 1994; 19:38–9.
83. McCarthy, Eoghan, Murphy, Claire-Louise, Doran, Michele, Cunnane, Gaye Infrapatellar Bursitis: An Occupational Legacy, *Journal of Clinical Rheumatology*, January 2011, Vol 17, Issue 1, pg 49-50; doi: 10.1097/RHU.0b013e3182056751

84. McEvedy B. V., "Simple ganglia," e *British Journal of Surgery*, vol. 49, no. 218, pp. 585–594, 1962.
85. Mellado JM, Perez Del Palomar L, Diaz L, Ramos A, Sauri A. Long-standing Morel-Lavallee lesion of the trochanteric region and proximal thigh; MRI features in 5 patients. *American Journal of Roentgenology* 2004;182:1289-94.
86. Minami A, Kato H, Iwasaki N. Snapping of triceps tendon after anterior nerve transposition for recurrent subluxation of the ulnar nerve. *Hand Surg* 1999; 4:193–6. 13.
87. Mukherjee K, Perrin S, Hughes P. Morel-Lavallee lesion in an adolescent with ultrasound and MRI correlation. *Skeletal radiology* 2007;36:43-5.
88. Murray, James R. D., Erskine J. Holmes, Dr Rakesh R. Misra. *A-Z of Musculoskeletal and Trauma Radiology*. Cambridge University Press, 2008.
89. Nelson, T. R., Fowlkes, J. B., Abramowicz, J. S. and Church, C. C. (2009), Ultrasound Biosafety Considerations for the Practicing Sonographer and Sonologist. *Journal of Ultrasound in Medicine*, 28: 139–150. doi:10.7863/jum.2009.28.2.139
90. O’Callaghan BI, Kohut G, Hoogewoud H. Gamekeeper thumb; identification of the Stener leison with US. *Radiology* 1994;182:477–480.
91. O’Hara JJ, Stone JH. Ulnar nerve compression at the elbow caused by a prominent medial head of the triceps and an anconeus epitrochlearis muscle. *J Hand Surg [Br]* 1996; 21:133–5. .
92. O’Neill, Jonh. *Musculoskeletal Ultrasound: Anatomy and Technique*. Springer, 2008.
93. Pandey CR, et al, Subungual Glomus Tumours: Is Magnetic Resonance Imaging or Ultrasound Necessary for Diagnosis?, *Malaysian Orthopaedic Journal* 2017 Vol 11 No 1
94. Paramhans, D, Nayak, D, Mathur, R, Kushwah K. Double dart technique of instillation of triamcinolone in ganglion over the wrist. *J Cutan Aesthet Surg*. 2010 Jan-Apr;3(1):29–31.
95. Park GY, Lee SM, Lee MY (2008) Diagnostic value of ultrasonography for clinical medial epicondylitis. *Arch Phys Med Rehabil* 89(4):738–742. doi: 10.1016/j.apmr.2007.09.048

96. Prakash P, Kotwal, Vikas Gupta, Rajesh Malhotra; Giant-cell tumour of the tendon sheath IS RADIOTHERAPY INDICATED TO PREVENT RECURRENCE AFTER SURGERY?; *J Bone Joint Surg [Br]* 2000;82-B:571-3.
97. Rao AG, Indira D, Kamal J. Extra digital glomangioma. *Indian J Dermatol.* 2010;55:397---8.
98. Redd RA, Peters VJ, Emery SF *et al.* Morton neuroma: sonographic evaluation. *Radiology* 1989 ; 171 : 415-417.
99. Robertson C, Saratsiotis J. A review of compressive ulnar neuropathy at the elbow. *J Manipulative Physiol Ther* 2005; 28:345
100. Rukavina I, Čaleta D. Giant-cell tumour of the tendon sheath: A review. *OA Orthopaedics* 2014 Jun 11;2(2):11.
101. Santos Montón C., J. M. Alonso Sánchez, D. C. Cuellar, P. A. Chaparro García, R. Corrales, J. D. Albillo Labarra; Salamanca/ES; Giant-cell tumor of the tendon sheath: when must we suspect it?
102. Sconfienza Lucia Maria; Krishna Mohan Gummalla, FRCR, Mathew George, M.D., Rupak Dutta, M.D., Morel-Lavallee lesion: case report of a rare extensive degloving soft tissue injury *Ulus Travma Acil Cerr Derg* 2014;20(1):63-65 doi: 10.5505/tjtes.2014.88403
103. Sconfienza, Luca Maria, Giovanni Serafini, Enzo Silvestri. *Ultrasound-Guided Musculoskeletal Procedures: The Upper Limb*. Springer, 2012.
104. Sell S, Schulz R, Balentsiefen M et al (1996) Lesions of the Achilles tendon. A sonographic, biochemical and histological study. *Arch Orthop Trauma Surg* 115:28–32
105. Sewell M D, K Rosendahl, D M Eastwood. Clinical Review: Developmental Dysplasia of the Hip; *BMJ* 2009;339:b4454 doi: 10.1136/bmj.b4454
106. Shaw BA, Segal LS, AAP SECTION ON ORTHOPAEDICS. Evaluation and Referral for Developmental Dysplasia of the Hip in Infants. *Pediatrics.* 2016;138(6):e20163107
107. Sheiner, E., Shoham-Vardi, I. and Abramowicz, J. S. (2007), What Do Clinical Users Know Regarding Safety of Ultrasound During Pregnancy?. *Journal of Ultrasound in Medicine*, 26: 319–325. doi:10.7863/jum.2007.26.3.319
108. Silver T, Fortenbaugh D, Williams R (2009) Effects of the bench shirt on sagittal bar path. *J Strength Cond Res* 23:1125–1128

109. Silvestri, Enzo, Alessandro Muda, Luca Maria Sconfienza. *Normal Ultrasound Anatomy of the Musculoskeletal System: A Practical Guide*. Springer, 2011.
110. Solomon, Louis, David Warwick, Selvadurai Nayagam, and Louis Solomon. *Apley and Solomon's Concise System of Orthopaedics and Trauma*, 2014.
111. Solomon, Louis, David Warwick, Selvadurai Nayagam. *Apley's System of Orthopaedics and Fractures, Ninth Edition*. Hodder Arnold, 2010.
112. Spinner RJ, An KN, Kim KJ, Goldner RD, O'Driscoll SW. Medial or lateral dislocation (snapping) of a portion of the distal triceps: a biomechanical, anatomic explanation. *J Shoulder Elbow Surg* 2001; 10:561–7. 11.
113. Spinner RJ, Gabel GT. Latrogenic snapping of the medial head of the triceps after ulnar nerve transposition. *J South Orthop Assoc* 2001; 10:236–40.
114. Spinner RJ, Goldner RD, Fada RA, Sotereanos DG. Snapping of the triceps tendon over the lateral epicondyle. *J Hand Surg [Am]* 1999; 24:381–5.
115. Spinner RJ, Goldner RD. Snapping of the medial head of the triceps and recurrent dislocation of the ulnar nerve. Anatomical and dynamic factors. *J Bone Joint Surg Am* 1998; 80:239–47.
116. Spinner, David A., Jonathan S. Kirschner, Joseph E. Herrera. *Atlas of Ultrasound Guided Musculoskeletal Injections*. Springer, 2013.
117. Spinner, Robert J., Frank R. Hayden, Jr., Cynthia T. Hipps, Richard D. Goldner, Imaging the Snapping Triceps, *American Journal of Roentgenology* 1996. 167:1550-1551.
118. Standing Medical Advisory Committee. Screening for the detection of congenital dislocation of the hip in infants. London: Department of Health and Social Security, 1966.
119. Steinbach L, Stevens K (2013) Imaging of cysts and bursae about the knee. *Radiol Clin North Am* 51(3):433–454
120. Steiner E, Steinbach LS, Schnarkowski P et al (1996) Ganglia and cysts around joints. *Radiol Clin North Am* 34:309a95–425
121. Suen Matthew, B. Fung, and C. P. Lung (2013) Treatment of Ganglion Cysts. *ISRN Orthopedics*; Volume 2013, Article ID 940615, 7 pages <http://dx.doi.org/10.1155/2013/940615>
122. Swen WA, Jacobs JW, Algra PR, et al. Sonography and magnetic resonance imaging equivalent for the assessment of full-thickness rotator cuff tears. *Arthritis Rheum* 1999;42:2231–8.

123. Tehranzadeh, Jamshid. *Musculoskeletal Imaging Cases*. McGraw-Hill Education / Medical, 2008.
124. Thorson EP. Tendonitis of the wrist and elbow. *Occup Med*. 1989;4(3):419–34
125. Truong, Walter. (2012). Developmental Dysplasia of the Hip In Brief, July 2012 Volume 1, Number 3
126. Tsang JPK, MK Yuen. Sonography of Baker's Cyst (Popliteal Cyst): the Typical and Atypical Features
127. Tseng S, Tornetta P. Percutaneous management of Morel-Lavallee lesions. *Journal of bone and joint surgery* 2006;88-A:92-6.
128. Vaidya, Aditya, Sucheta Golhar, Shraddha Shah. Management of Snapping Triceps Syndrome. A Case Report. *International Journal of Recent Trends in Science and Technology*, March 2017, 22(2): 82-84 <http://www.statperson.com> (accessed 03 March 2017).
129. Van Holsbeeck MT. Sonography of the elbow, wrist, and hand. In: van Holsbeeck M, Introcaso JH, eds., pp. 517–571. *Musculoskeletal Ultrasound*. St. Louis: Mosby, 2001.
130. Van Rhijn LW, Jansen EJ, Pruijs HE. Long-term follow-up of conservatively treated popliteal cysts in children. *J Pediatr Orthop B*. 2000;9(1):62-4.
131. Van Riet RP, Morrey BF, Ho E, O'Driscoll SW. Surgical treatment of distal triceps ruptures. *J Bone Joint Surg Am* 2003; 85:1961–7.
132. Vanhees Matthias KD, Ghislain FAE, Geurts and Roger P. van Riet. Snapping triceps syndrome: a review of literature. 2009 oct 22; 30-3. *Journal Compilation* © 2009 British Elbow and Shoulder Society. *Shoulder & Elbow* 2010 2, pp 30–33
133. Wakefield Richard J., Maria Antonietta D'Agostino. *Essential Applications of Musculoskeletal Ultrasound in Rheumatology*. Saunders, 2010.
134. Wang George, Jon A. Jacobson, Felix Y. Feng, Gandikota Girish, Elaine M. Caoili, Catherine Brandon, (2007) Sonography of Wrist Ganglion Cysts; Variable and Noncystic Appearances. *J Ultrasound Med*; 26:1323–1328
135. Watts AC, McEachan J, Reid J, Rymaszewski L. The snapping elbow: a diagnostic pitfall. *J Shoulder Elbow Surg* 2009; 18:e9–10.
136. Wenzke DR (2013) MR imaging of the elbow in the injured athlete. *Radiol Clin North Am* 51(2):195–213. doi: 10.1016/j.rcl.2012.09.013
137. Wilson David J. *Paediatric Musculoskeletal Disease: With an Emphasis on Ultrasound*. Springer, 2010.

138. Wu C-H, Wang T-G, Current Trends in Musculoskeletal Ultrasound, *Journal of Medical Ultrasound* (2016), <http://dx.doi.org/10.1016/j.jmu.2016.03.007>
139. Zachariae L. and H. Vibe-Hansen, "Ganglia. Recurrence rate elucidated by a follow up of 347 operated cases," *Acta Chirurgica Scandinavica*, vol. 139, no. 7, pp. 625–628, 1973.