

# Management of keloids and hypertrophic scars

---

El Mcherqui, Imane

Master's thesis / Diplomski rad

2019

Degree Grantor / Ustanova koja je dodijelila akademski / stručni stupanj: **University of Zagreb, School of Medicine / Sveučilište u Zagrebu, Medicinski fakultet**

Permanent link / Trajna poveznica: <https://um.nsk.hr/um:nbn:hr:105:848316>

Rights / Prava: [In copyright](#)/[Zaštićeno autorskim pravom.](#)

Download date / Datum preuzimanja: **2024-07-15**



Repository / Repozitorij:

[Dr Med - University of Zagreb School of Medicine Digital Repository](#)



**UNIVERSITY OF ZAGREB  
SCHOOL OF MEDICINE**

**Imane El Mcherqui**

**Management of keloids and  
hypertrophic scars**

**GRADUATE THESIS**



**Zagreb, 2019.**

This graduation paper was realized at the Department of Dermatology, Clinical Hospital "Šalata", School of Medicine, University of Zagreb, Croatia, under the supervision of Professor Romana Čeović, MD, PhD, and it was submitted for evaluation in the academic year of 2018/2019.

Mentor of the graduate thesis: Professor Romana Čeović, MD, PhD

# Table of contents

<b>Summary</b> .....	<b>VI</b>
<b>1. Introduction</b> .....	<b>1</b>
<b>2. Current strategies for treatment of excessive scarring</b> .....	<b>6</b>
2.1 Intralesional corticosteroid injections and cryotherapy.....	6
2.2 Silicone gel sheeting.....	7
2.3 Surgery.....	8
2.4 Radiotherapy.....	8
2.5 Laser therapy .....	9
2.6 Compression therapy .....	10
<b>3. Emerging treatment options of excessive scarring</b> .....	<b>12</b>
3.1 Five-fluorouracil (5-FU).....	12
3.2 Onion extract gel .....	12
3.3 Imiquimod .....	13
3.4 Bleomycin.....	14
3.4 Interferons.....	14
3.5 Botulinum toxin A (BTA) .....	14
3.6 Photodynamic therapy (PDT).....	15
3.7 Intralesional verapamil .....	15
<b>4. Over-the-counter treatments</b> .....	<b>16</b>
<b>5. Risk factors and prevention</b> .....	<b>17</b>
<b>6. Conclusion</b> .....	<b>18</b>
<b>7. Acknowledgments</b> .....	<b>19</b>
<b>8. References</b> .....	<b>20</b>
<b>9. Biography</b> .....	<b>23</b>



## Summary

### Management of keloids and hypertrophic scars

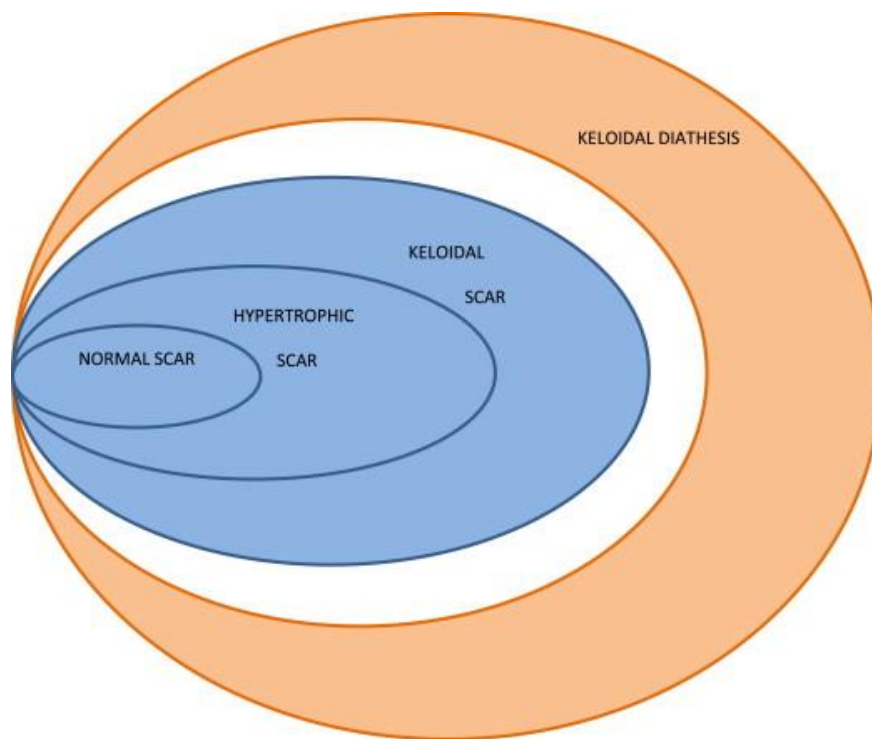
Imane El Mcherqui

Excessive healing response poses a huge challenge because it results in the formation of hypertrophic scars and keloids. Patients at high risk of keloids are usually younger than 30 years and have darker skin. Sternal skin, shoulders and upper arms, earlobes, and cheeks are most susceptible to developing keloids and hypertrophic scars. High-risk trauma includes burns, ear piercing, and any factor that prolongs wound healing. Keloid formation often can be prevented if anticipated with immediate silicone elastomer sheeting, taping to reduce skin tension, or corticosteroid injections. Once established, however, keloids are difficult to treat, with a high recurrence rate regardless of therapy. Evidence supports the currently used methods: silicone sheeting, pressure dressings, and corticosteroid injections as first-line treatments. Cryotherapy may be useful, but should be reserved for smaller lesions. Surgical removal of keloids poses a high recurrence risk unless combined with one or several of these standard therapies. Alternative postsurgical options for refractory scars and new emerging methods include pulsed dye laser, radiation, and possibly imiquimod cream. Intralesional verapamil, fluorouracil, bleomycin, and interferon alfa-2b injections appear to be beneficial for treatment of established keloids. Despite the popularity of over-the-counter herb-based creams, the evidence for their use is mixed, and there is little evidence that vitamin E is helpful.

Key words: keloid, hypertrophic scar, silicon sheeting, compression therapy, corticosteroids, cryotherapy, radiotherapy, fluorouracil, bleomycin, interferon alfa-2b

## 1. Introduction

For centuries, keloids and hypertrophic scars have been recognized as abnormal responses to trauma [1]. The keloid is defined as an abnormal scar that grows beyond the boundaries of the original site of skin injury. Keloids have the clinical appearance of a raised amorphous growth and are frequently associated with pruritus and pain. Scanning electron microscopy reveals a number of distinguishing features, including randomly organized collagen fibers in a dense connective tissue matrix. In normal scars, the collagen bundles are arranged parallel to the skin surface. The hypertrophic scar is defined as a widened or unsightly scar that does not extend beyond the original boundaries of the wound (illustrated on figure 1 and table 1). Unlike keloids, the hypertrophic scar reaches a certain size and subsequently stabilizes or regresses [2]. Similar to keloids, hypertrophic scars are associated with adverse wound healing factors.



*Figure 1. Physiological and pathological scars*

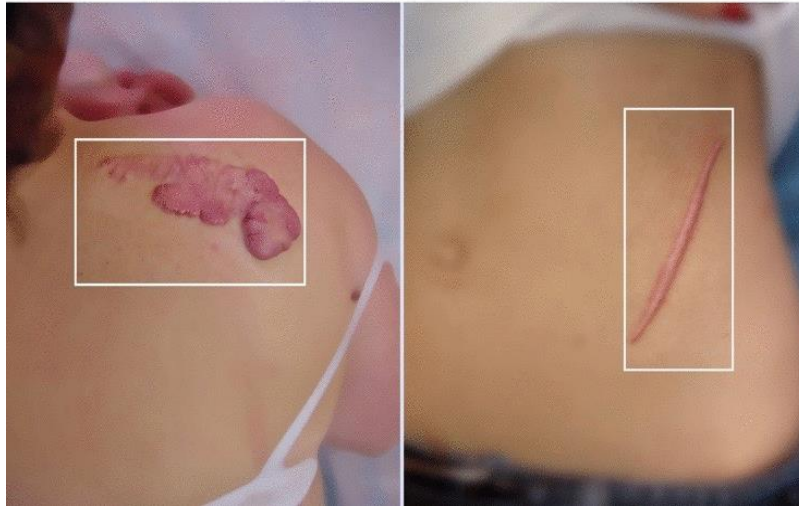Although both keloids and hypertrophic scars are the result of chronic inflammation in the reticular dermis and equal in sex distribution with the highest incidence in the second to third decade, there are major epidemiological, clinical and histological differences ( figure 1 b and table 2 a.) The incidence of hypertrophic scars is 40% to 70% following surgery, and up to 91% following burn injury within 4 to 8 weeks following wounding [3]. After that there is a rapid growth phase for up to 6 months, then a regression over a period of a few years while for keloids it is 6% to 16% mainly In African populations that appears within years after minor injuries or forms spontaneously on the midchest in the absence of any known injury (figure 1a). It also persists for long periods of time with no spontaneous regression. The recurrence rates after excision of the original hypertrophic scar is low and appears mainly in the shoulders, neck, presternum, knees and ankles as a primarily fine, well-organized, wavy type III collagen bundles oriented parallel to the epidermis surface with abundant nodules containing myofibroblasts and plentiful acidic mucopolysaccharide. For the keloids there is a high recurrence rates following excision and appear mostly in the anterior chest, shoulders, earlobes, upper arms and cheeks as disorganized, large, thick, type I and III hypocellular collagen bundles with no nodules or excess myofibroblasts. There is also a poor vascularization with widely scattered dilated blood vessels.



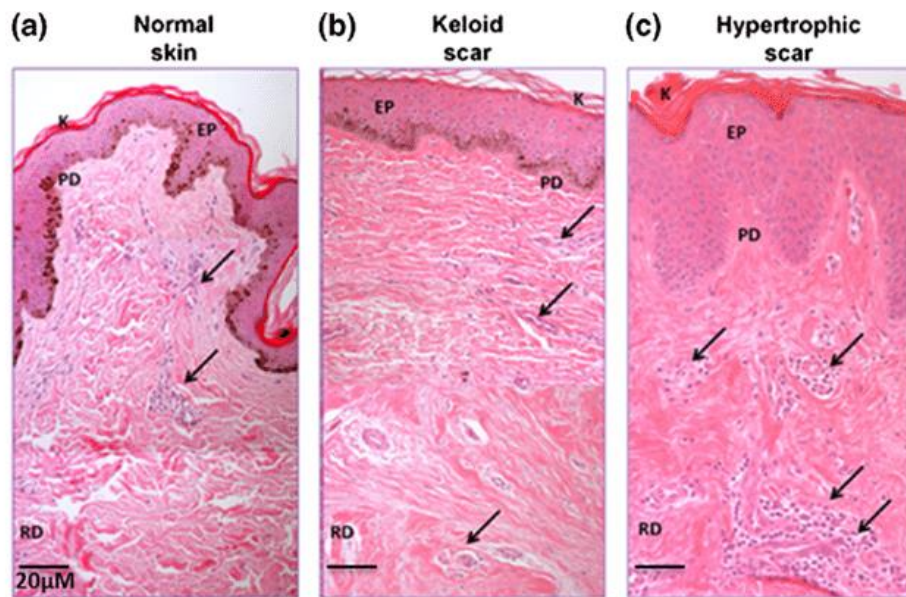
<b>HSs</b>	<b>Keloids</b>
Frequent incidence	Rare incidence
Posttraumatic	Posttraumatic or spontaneous
Develop soon after surgery	May not begin for many months
Usually subside with time	Rarely subside with time
Remain within the wound boundaries	Spread outside the wound boundaries
No predominant anatomical site but often occur when skin creases are at right angle or when scars cross joints	Predominant anatomical sites (chest, shoulders, upper back, earlobes, posterior neck, knees)
Pruritic, rarely painful	Pruritic, painful
Less association with phototype	More common in darker skin types
Genetic predisposition	Less genetic predisposition
Improve with appropriate surgery, low recurrence rate	Often worsened by surgery, high recurrence rate
Increase collagen synthesis; 7 times higher than normal	Increase collagen synthesis; 20 times higher than normal
Collagen type I < III	Collagen type III < I
Fine collagen fibers organized into nodules, predominantly parallel	Large, thick collagen fibers, closely packed random to epidermis
Flatter collagen fibers in wavy pattern	Fibers lie haphazardly
High collagen cross-link	Collagen cross-link twice higher than in HS
Myofibroblasts that express $\alpha$ -SMA	Absence of myofibroblasts
Fibroblasts: $\uparrow$ cell number, $\uparrow\uparrow$ proliferation, $\downarrow\downarrow$ apoptosis, $\uparrow\uparrow$ collagen I	$\uparrow\uparrow$ proliferation, $\uparrow\uparrow$ collagen I
$\uparrow\uparrow$ TGF- $\beta$ 1, $\uparrow$ TGF- $\beta$ 2, $\downarrow\downarrow$ TGF- $\beta$ 3	$\uparrow\uparrow$ TGF- $\beta$ 1, $\uparrow\uparrow$ TGF- $\beta$ 2, $\downarrow\downarrow$ TGF- $\beta$ 3

$\uparrow$ , increase;  $\downarrow$ , decrease; SMA, smooth muscle actin; TGF- $\beta$ , transforming growth factor-beta; HSs, hypertrophic scars.

**Table 1.** Major epidemiological, clinical and histological differences



*Figure 2a. 1- Keloid 2- Hypertrophic scar*



*Figure 2b. Histological differences*

Multiple studies on hypertrophic scar or keloid formation have led to a multitude of therapeutic strategies to prevent or improve keloid and hypertrophic scar formation and have been reviewed in a plethora of articles. However, only a few of them have been supported by well-designed prospective studies with adequate control groups. Today, most of the propagated therapeutic approaches are usually being utilized for both hypertrophic scarring and keloids. Nevertheless, clinical differentiation between

hypertrophic and keloid scars is central before the initiation of any treatment, particularly before starting any surgical or ablative laser related manipulation, due to increased recurrence rates with keloids. There are current and constantly emerging new medical treatments to manage those two types of scars, moreover surgery even if it is believed to be another skin trauma which potentially causes more damage than before is used in combination with other post-operative treatment and had become popular around the world.

## **2. Current strategies for treatment of excessive scarring**

### **2.1 Intralesional corticosteroid injections and cryotherapy**

First of the classical medical treatments are the intralesional steroid injections that have been used for the therapy of excessive scars since the mid-1960s (figure 3) [4]. Corticosteroid injections for prevention and treatment of keloids and hypertrophic scars are perhaps the first-line option for family physicians. Corticosteroids suppress inflammation and mitosis while increasing vasoconstriction in the scar. Triamcinolone acetonide suspension (Kenalog) 10 to 40 mg per mL (depending on the site) is injected intralesionally, which, although painful, will eventually flatten 50 to 100 percent of keloids, with a 9 to 50 percent recurrence rate. Lidocaine (Xylocaine) may be combined with the corticosteroid to lessen pain, whereas using adjunctive cryotherapy 5 immediately before injection may make the procedure easier by softening the scar (based on expert opinion).

Combining cryotherapy and corticosteroid injections also improves outcomes more than either modality alone, although hypopigmentation is always a significant concern. Cryotherapy is a very effective method to treat small scars, such as severe acne scars. Cryotherapy combined with intralesional triamcinolone has been described as the most common traditional therapy for hypertrophic scars and keloids. Its main handicap is permanent hypopigmentation as a common side effect. Usually, two or three injections are given a month apart; however, therapy can continue for six months or longer. Newer keloids are more responsive to therapy than older, established lesions. Corticosteroid injections are more effective if combined with surgery; the sooner instituted, the greater the likelihood of success. Common adverse effects include atrophy, telangiectasias, and hypopigmentation.

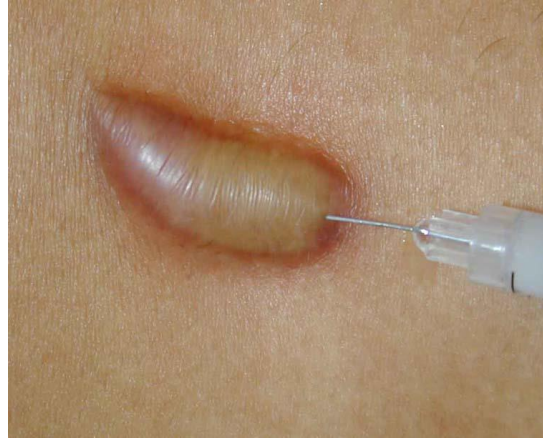


Figure 3. Corticosteroid injection in a hypertrophic scar

## 2.2 Silicone gel sheeting

The 2001 International Advisory Panel for hypertrophic scar and keloid management concluded that silicone gel sheeting for hypertrophic scars, immature keloids, and mature keloids is a viable first-line treatment of choice [6]. It has been used since 1981. Occlusive silicone based devices are effective barriers to transepidermal water loss (figure 4). Silicone in its various forms builds a film on the newly formed skin, protecting it from drying out and thus preserving the moisture balance. By keeping the skin hydrated, inflammation and, therefore, collagen formation remain low resulting in more physiological scar formation.

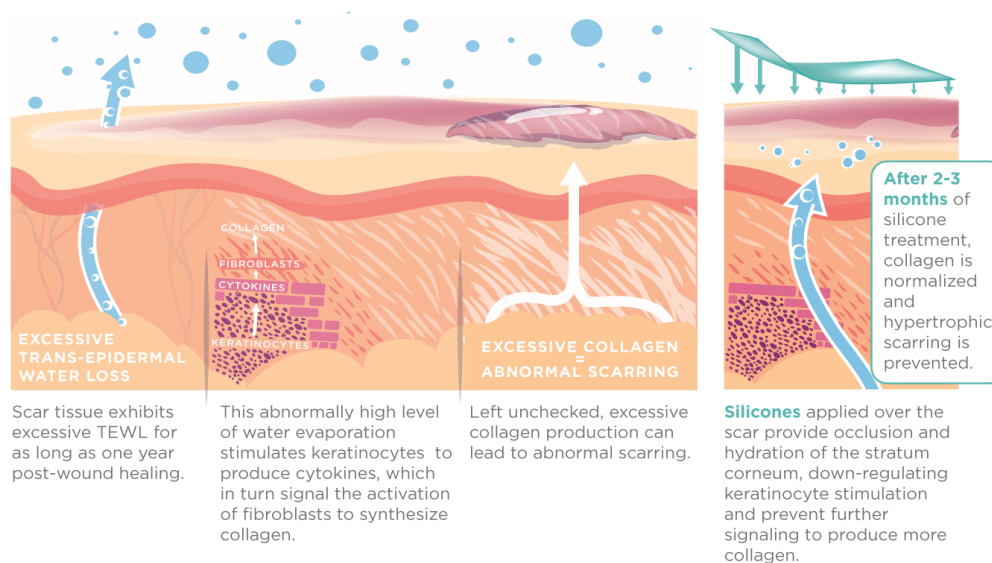


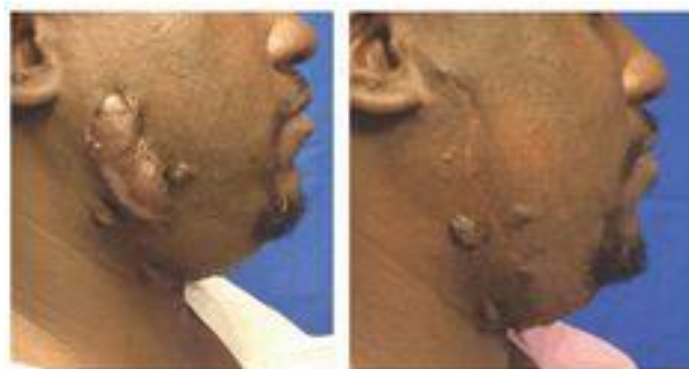Figure 4. Mechanism of action of silicon gel sheeting

## 2.3 Surgery

If neither silicone nor corticosteroids are effective over 12 months, second-line surgical treatment followed by corticosteroids and possibly silicone sheeting should be considered [7]. Surgical treatment of keloids has been usually recommended to be used in mature scars with complementary conservative strategies, such as radiotherapy, interferon, bleomycin, cryotherapy or corticoids, to avoid recurrence (decreasing the risk from 50% to 8% as a combined treatment). Surgical treatment of excessive scars requires a careful personalized indication and patient selection on a case-by-case basis.

## 2.4 Radiotherapy

Among these treatment modalities, combination therapy of surgical excision and radiation therapy was considered as the last resort which can significantly reduce recurrence rate. Compared to surgery or radiation therapy alone, surgical excision followed by immediate postoperative radiation therapy has been shown to be the most effective treatment, with a recurrence rate of about 20%. There is a range of radiation prescriptions that have been used. The recommended total dose ranges from 12 to 20 Gy and historically was low dose per fractionation (3 to 4 fractions daily in 3 to 4 Gy/fx). However, newer data has suggested that using a radiation prescription that delivers a biologic effective dose (BED) of greater than 30 Gy (e.g., 13 Gy/1fx, 16Gy/2fx, 18Gy/3fx over 5 to 7 days), has better long-term control (figure 5).

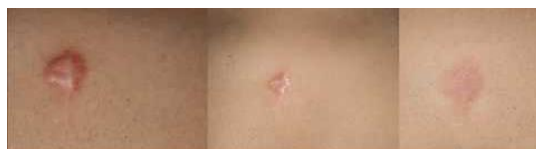

*Figure 5. Before and after surgical excision followed by immediate postoperative radiation therapy of a keloid*



## 2.5 Laser therapy

Another current treatment option is the laser that have been used in the treatment of hypertrophic scars and keloids for more than 20 years. Different laser systems have been examined; among them pulsed dye lasers are currently considered the laser of choice in these settings. The use of the pulsed dye laser 8 was approved by the FDA in the summer of 1988. Since then, many thousands of treatments with this type of laser have been performed worldwide with extremely low complication rates and with significant lightening in most patients with port-wine stains. It is thought that it improves keloids or hypertrophic scars by inducing capillary destruction, which generates hypoxemia and in turn alters local collagen production. Also, an increased production of collagenases has been described. However, the treatment of keloids with short-pulsed, 585-nm pulsed dye laser has shown limited promise, with a 57 to 83 percent improvement rate. It is more vascular-specific than other laser therapies and appears to be most effective if used early and in conjunction with other techniques. Laser-treated portions of keloidal median sternotomy scars showed significant improvement in erythema, pruritus, and scar height compared with untreated portions of the same scars, and these improvements persisted for at least six months. The principal effect of a pulsed dye laser is on scar microvasculature, reducing erythema and pruritus and improving skin texture. The effectiveness of this therapy remains controversial, however, with other studies showing insignificant reduction in scar thickness. Disadvantages include significant expense and availability only through a specialist.



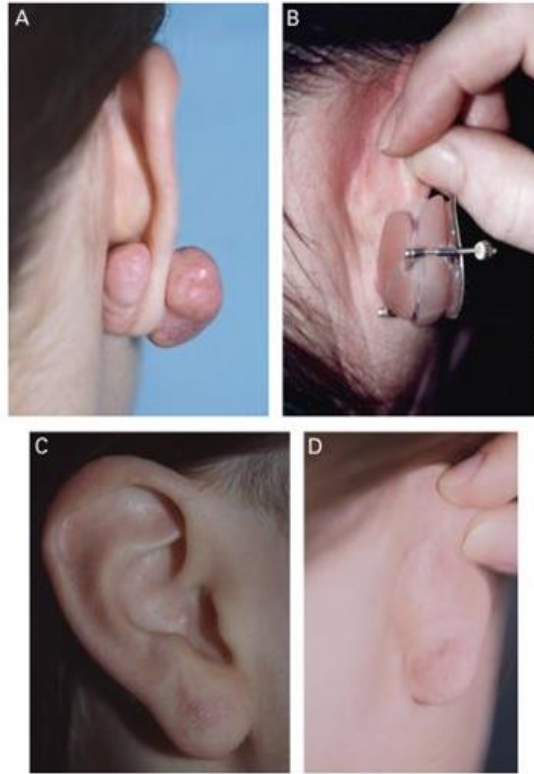
*Figure 6.* 585-nm pulsed dye laser of a 7 mm keloid that progressively disappeared after 2 then 6 weeks

## **2.6 Compression therapy**

Finally, compression therapy has been used for keloids and hypertrophic scars since the 1970s [9]. It involves the use of pressure-gradient garments or other mechanisms to constrict the wound region. Compression therapy became popular after doctors noticed that patients with burns on their legs healed faster and better with pressure stockings. It is often used as a first-line therapy to improve scarring outcomes in burn victims, and to treat keloids and hypertrophic scars in general. Despite decades of acceptance by modern medical practices, evidence supporting its effectiveness when used by itself is primarily anecdotal or from retrospective review studies. However, there are a number of clinical studies that demonstrate its effectiveness in treating and preventing reoccurrence of keloids on the ear.

Using compression therapy along with steroid injections appears to work better than either alone, especially when combined with surgery. Pressure therapy reportedly is more effective on scars less than 12 months old, and is recommended to prevent keloids from developing altogether in wounds that typically take 2-3 weeks to heal. It is usually done daily for at least 6-12 months at 8-24 hour intervals for maximum effectiveness. Patient compliance with applying the pressure mechanism and keeping it on for the required time and frequency can directly affect the outcome. Other concerns about compression therapy include discomfort (especially in humid weather or climates), swelling, rashes, and additional skin injury (e.g., sores).





*Figure 7. A- Keloid, B-Pressure clips, C and D – Progressive and complete recovery*

### **3. Emerging treatment options of excessive scarring**

#### **3.1 Five-fluorouracil (5-FU)**

At the head of the list of the new emerging medical treatments of keloids and hypertrophic scars are chemotherapeutic drugs which are also utilized as a treatment option for recalcitrant and recurrent hypertrophic scars and keloids. Five-fluorouracil (5-FU) is a pyrimidine analog that inhibits the synthesis of deoxyribonucleic acids by irreversibly inhibiting thymidine synthase, which is responsible for converting uridine to thymidine [10]. Without the structural elements of biosynthesis, rapidly proliferating cells such as fibroblasts are halted and scar degradation is promoted. Additionally, 5-FU is believed to hinder type I collagen gene expression and the effects of tumor growth-beta 1. Studies have discovered a dose-related association between 5-FU and reduction in keloid fibroblast proliferation and the fibroblast-populated collagen lattice. In 1999, Fitzpatrick has first introduced 5-FU. In a retrospective study of 1000 patients with hypertrophic scars and keloids over a 9-year period, the most effective regimen was found to be 0.1 mL of TAC (10 mg/mL) and 0.9 mL of 5-FU (50 mg/mL) up to 3 times a week.

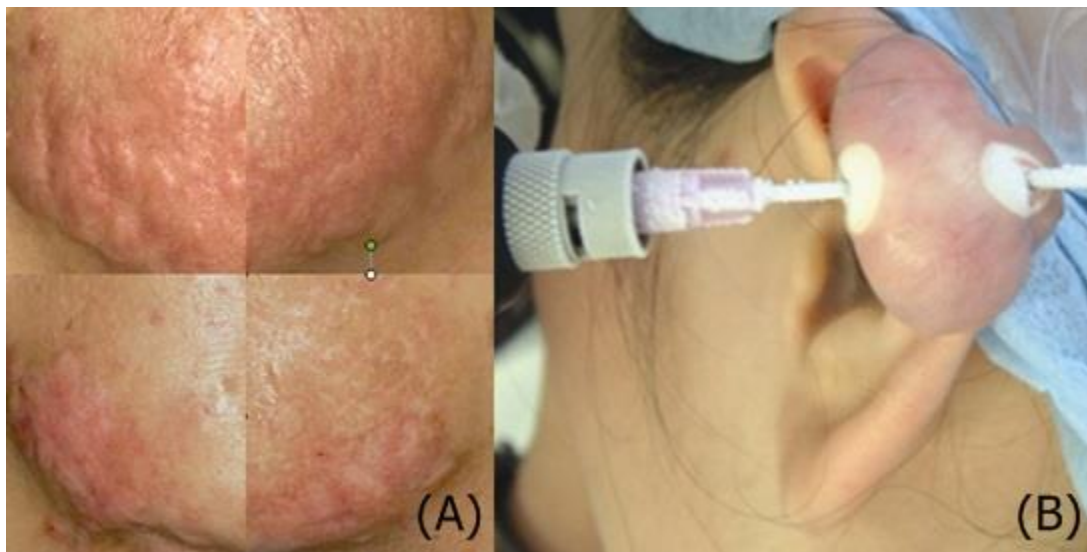
A total of 85% of keloids showed more than 50% improvement in an open study by Kontochristopoulos et al in which 20 keloids were treated once weekly with intralesional 5-FU (50 mg/mL) for an average of 7 treatments, with a recurrence rate of 47% within 1 year of the treatment.

#### **3.2 Onion extract gel**

A new proprietary onion extract gel has been proven to be safe and significantly improves scar appearance after four weeks of once-daily application [11]. Extractum cepae has flavonoids (quercetin and kaempferol) that may play a role in scar reduction by inhibiting fibroblast proliferation. It is hypothesized that these inhibitory effects may be mediated through the inhibition of TGF- $\beta$ 1 and TGF- $\beta$ 2. Considerable industry-driven data have yielded contrasting results, thus diminishing the credibility of using such drugs. However, recent studies have shown that scar creams containing onion extracts

can significantly improve scar height and associated symptoms compared with a placebo. They also appear to be effective in preventing unaesthetic scars in patients who undergo laser removal of tattoos. In addition, such creams are effective when used in combination with intralesional TAC. It is mainly used in prevention.

Intralesional cryotherapy utilises an intralesional needle cryoprobe to produce rapid scar freezing from the core outwards, thus ensuring that all of the adverse scar in question is frozen. In this way, the technique differs from earlier contact cryotherapy, techniques which tend to produce more shallow patterns of freezing and often only partial freezing of the scar. Although still at a relatively early stage in the prevalence of its use, the promise of this technique has been recognised.



*Figure 8. A cryotherapy for hypertrophic acne scar on the chin (A). Intralesional cryotherapy for keloid scar of the ear (B).*

### **3.3 Imiquimod**

Imiquimod 5% cream, a topical immune response modifier, has been approved for the treatment of actinic keratoses, superficial basal cell carcinoma, and genital warts [12]. Imiquimod stimulates interferon, a pro-inflammatory cytokine, which increases collagen breakdown. Additionally, imiquimod alters the expression of apoptosis-

associated genes. It has been proven that topical application of imiquimod 5% cream after surgery reduces keloid recurrences. The results of different studies have demonstrated that imiquimod treatment improved scar quality and color match after surgery.

### **3.4 Bleomycin**

Bleomycin was discovered in 1962 [13]. It is on the World Health Organization's List of Essential Medicines, the most effective and safe medicines needed in a health system. Bleomycin injections cause necrosis of keratinocytes with a mixed inflammatory infiltrate. Several studies have demonstrated that bleomycin can be used effectively to treat keloids and hypertrophic scars after three to five injections (via multiple needle puncture or jet injections) of bleomycin (1.5 IU/mL). However, further investigation and efficacy trials are necessary to include this agent in future treatment protocols.

### **3.4 Interferons**

Interferons are proteins produced by immune cells. They have been used to treat a number of diseases, primarily viral infections (e.g., hepatitis) and as an anti-tumor drug in cancers (e.g., skin cancer and Kaposi sarcoma). After it was discovered (in 1989) that interferons decreased collagen production in the lab, researchers theorized it could help prevent and treat keloids and hypertrophic scars in patients IFN injected into the suture line of keloid excision sites may be prophylactic for reducing recurrences [14]. Berman and Flores reported statistically significant fewer keloid recurrences in a study of 124 keloid lesions after postoperative IFN alfa-2b injection treatment (5 million U, 1 million U injected per cm of scar) into keloid excision sites (18%) versus excision alone (51.1%) and TAC treatment (58.4%).

### **3.5 Botulinum toxin A (BTA)**

Botulinum toxin A (BTA) is a neurotoxin that causes a flaccid paralysis of the local musculature and reduces skin tension [15]. This reduction in the skin tensile force during the course of wound healing may represent a novel therapeutic target for treating keloids. The suggested clinical efficiency of intralesional BTA for the therapy of existent

keloids could not be confirmed yet. Based on our actual data, the potential mechanisms of action of BTA on keloid-derived fibroblasts remain unclear.

### **3.6 Photodynamic therapy (PDT)**

Optimal management for keloid disease is ill defined, with surgical excision resulting in recurrence rates over 50 %. Photodynamic therapy (PDT) uses light to activate a photosensitiser localised in diseased tissues. The potential underlying mechanism is currently unknown. However, the photodynamic reaction generates reactive oxygen species, which in turn leads to cell apoptosis, membrane and mitochondrial damage, and activates various signaling molecules such as tumor necrosis factor- $\alpha$ . PDT has been demonstrated to reduce type I collagen synthesis and fibroblast proliferation in vitro, which may be responsible for the improvement seen clinically [16]. Unfortunately there is little data about this new emerging technique that is promising a good cosmetic outcome with minimal side effects.

### **3.7 Intralesional verapamil**

Intralesional verapamil (2.5 mg per mL) in conjunction with silicone sheeting reduced keloid postsurgical recurrence by 90 percent at 18 months . Calcium antagonists appear to work by reducing collagen production and may be a reasonable and safe alternative to corticosteroid injection in the future [17].

#### 4. Over-the-counter treatments

Many patients use topical vitamin E (alpha-tocopherol) hoping its antioxidant properties will prevent scars. However, there is little evidence that it is helpful, and some patients develop a contact dermatitis that may delay healing. Used early on, vitamin E may also reduce the tensile strength of the scar, and its use should be discouraged. Another over-the-counter option is onion extract topical gels (e.g. mederma) that was discussed earlier, but limited clinical trials have failed to demonstrate any clinical improvement in scar height, erythema, or pruritis. Contractubex gel contains onion extract with heparin, which is thought to promote scar maturity.

Although one trial compared this product favorably with corticosteroids, another showed that it was ineffective in improving scar height and itching [18]. Moist exposed burn ointment contains multiple herbs with betasitosterol, which provides hydration and possible benefits to wound healing. Another plant extract product contains *Centella asiatica* and *Bulbine frutescens* (Alpha Centella cream), which may increase wound strength if used in the first six to eight weeks. All of these commercially available products emphasize preventive use because they are unlikely to reverse well-established keloids.

## 5. Risk factors and prevention

The primary risk factor for keloids is darkly pigmented skin, which carries a 15- to 20-fold increased risk, perhaps because of melanocyte-stimulating hormone anomalies. Familial predisposition, with autosomal dominant and recessive genetic variants is recognized. Black, Hispanic, and Asian persons are far more likely to develop keloids than white persons. Hypertrophic scars, however, are less likely to be associated with skin pigmentation. Keloids are more common in persons younger than 30 years, with risk peaking between 10 to 20 years of age, and in patients with elevated hormone levels (e.g., during puberty or pregnancy) [19]. Sternal skin, shoulders and upper arms, earlobes, and cheeks are most susceptible to developing keloids. Certain types of trauma and delayed healing (longer than three weeks) heighten keloid incidence even more, with burns carrying the highest risk. Acne, ear piercing, chickenpox, vaccinations (particularly bacille Calmette-Guérin vaccination), biopsy procedures, and lacerations may cause abnormal scarring. Acne keloids are particularly common. Keloids are more than just cosmetically unacceptable; many are also pruritic and painful. They often result in severe emotional distress.

Before any surgical procedure, patients should be asked if they have had previous problems with scarring. Discuss the potential for keloids as part of informed consent, and discourage ear piercing and other elective procedures in persons with dark skin. If ears are pierced despite this advice, pressure earrings are commercially available for reducing keloid risk. If surgery cannot be avoided in a high-risk patient, immediate silicone elastomer sheeting or corticosteroid injections should be instituted. Anything that expedites wound healing and diminishes skin tension (e.g. postsurgical taping for 12 weeks) will diminish risk.

## **6. Conclusion**

Management of hypertrophic scars and keloids has advanced from crude, invasive methods such as gross excision and radiation to intralesional or topical agents that act on a cellular level. There is no universally accepted treatment regimen and no evidence-based literature to guide management. Our objectives are to present a list of available treatment regimens and their proposed mechanisms of action. Although the list is continuously expanding, when it comes to hypertrophic scars and keloids, prevention is key.



## **7. Acknowledgments**

Foremost I would like to express my sincere gratitude to my mentor Professor Romana Čeović, MD, PhD, for her help and guidance, as well as for always being available for her students.

Besides my mentor, I would like to thank Vedran Olujić, mag.ing.el, my fiance and biggest support for helping me with proof reading, translations and student life difficulties.

Finally, I can not thank enough my father El Mcherqui Mostafa, MD, PhD, for his financial support and last but not least my mother El Jouaidi Najat for her unconditional love that helped me go through hardships during my medical studies.

## 8. References

1. Rockwell W. Bradford M.D.; Cohen, I. Kelman M.D.; Ehrlich, H. Paul Ph.D. Plastic and reconstructive surgery, November 1989, [https://journals.lww.com/plasreconsurg/Abstract/1989/11000/Keloids\\_and\\_Hypertrophic\\_Scars\\_A\\_Comprehensive.21.aspx](https://journals.lww.com/plasreconsurg/Abstract/1989/11000/Keloids_and_Hypertrophic_Scars_A_Comprehensive.21.aspx)
2. S. Mostinckx, O. Vanhooteghem, B. Richert, M. De La Brassinne, Annals of Dermatology and Venereology, Volume 132, Issue 4, April 2005, Pages 384-387, <https://www.sciencedirect.com/science/article/pii/S0151963805792905>
3. Ghazawi, Feras M. MD, PhD, MSc, Zargham, Ramin MD, PhD, Gilardino, Mirko S. MD, MSc, Sasseville, Denis MD, Jafarian, Fatemeh MD, Insights into the Pathophysiology of Hypertrophic Scars and Keloids: How Do They Differ?, January 2018, Volume 31 Number 1, pages 582 – 595
4. Bushan Premanshu, Manjul Prateek, Lata Swarn, Intralesional Steroid Injections: Look Before You Leap, Indian Journal of Dermatology, 2014 Jul-Aug; 59(4): 410–411. <https://www.ncbi.nlm.nih.gov/pmc/articles/PMC4103286/>
5. Yosipovitch G, Widijanti Sugeng M, Goon A, Chan YH, Goh CL, A comparison of the combined effect of cryotherapy and corticosteroid injections versus corticosteroids and cryotherapy alone on keloids: a controlled study, Journal of Dermatological Treatment, 2001 Jun;12(2):87-90. <https://www.ncbi.nlm.nih.gov/pubmed/12243664>
6. O'Brien L, Jones DJ, Silicone gel sheeting for preventing the development of hypertrophic and keloid scars and for treating existing hypertrophic and keloid scars, Cochrane, 12 September 2013, [https://www.cochrane.org/CD003826/WOUNDS\\_silicone-gel-sheeting-for-preventing-the-development-of-hypertrophic-and-keloid-scars-and-for-treating-existing-hypertrophic-and-keloid-scars](https://www.cochrane.org/CD003826/WOUNDS_silicone-gel-sheeting-for-preventing-the-development-of-hypertrophic-and-keloid-scars-and-for-treating-existing-hypertrophic-and-keloid-scars)
7. Juckett G, MD, MPH, Hartman-Adams H, MD, Management of Keloids and Hypertrophic Scars, *Am Fam Physician*. 2009 Aug 1;80(3):253-260, <https://www.aafp.org/afp/2009/0801/p253.html>

8. Stephanides S, Rai S, August PJ, Ferguson JE, Madan V, Treatment of refractory keloids with pulsed dye laser alone and with rotational pulsed dye laser and intralesional corticosteroids: A retrospective case series, *Laser Therapy*, 2011; 20(4): 279–286.
9. Berman B, MD, PhD, What are the types of compression treatment for keloids and hypertrophic scars?, Jun 12, 2018, <https://www.medscape.com/answers/1057599-91491/what-are-the-types-of-compression-treatment-for-keloids-and-hypertrophic-scars>
10. Mutalik S, Patwardhan N, Use of Injection Five Fluorouracil (FFU) With or Without Injection Triamcinolone in the Management of Hypertrophic Scars and Keloids, *Journal of Cutaneous and Aesthetic Surgery*, 2008 Jan; 1(1): 36, <https://www.ncbi.nlm.nih.gov/pmc/articles/PMC2840889/>
11. Hosnuter M, The effects of onion extract on hypertrophic and keloid scars, *Journal of Wound Care*, 16(6):251-4 · June 2007, [https://www.researchgate.net/publication/6116856\\_The\\_effects\\_of\\_onion\\_extract\\_on\\_hypertrophic\\_and\\_keloid\\_scars](https://www.researchgate.net/publication/6116856_The_effects_of_onion_extract_on_hypertrophic_and_keloid_scars)
12. Berman B, Harrison-Balestra C, Perez OA, Viera M, Villa A, Zell D, Ramirez C, Treatment of keloid scars post-shave excision with imiquimod 5% cream: A prospective, double-blind, placebo-controlled pilot study, *Journal of Drugs and Dermatology*, 2009 May;8(5):455-8. <https://www.ncbi.nlm.nih.gov/pubmed/19537368>
13. Berman B, MD, PhD, What is the role of bleomycin in the treatment of keloids and hypertrophic scars?, *Medscape*, June 3, 2019, <https://www.medscape.com/answers/1057599-91503/what-is-the-role-of-bleomycin-in-the-treatment-of-keloids-and-hypertrophic-scars>
14. Lee JH, Kim SE, Lee AY, Effects of interferon-alpha2b on keloid treatment with triamcinolone acetonide intralesional injection, *International Journal of Dermatology*, 2008 Feb;47(2):183-6, <https://www.ncbi.nlm.nih.gov/pubmed/18211495>
15. Prodromidou A, MD, Frountzas M, MD, Botulinum toxin for the prevention and healing of wound scars: A systematic review of the literature, *Plastic Surgery*, 2015 Winter; 23(4): 260–264.

16. Ud-Din S, Thomas G, Morris J, Bayat A, Photodynamic therapy: an innovative approach to the treatment of keloid disease evaluated using subjective and objective non-invasive tools, *Archives of Dermatological Research*, April 2013, Volume 305, Issue 3, pages 205-214
17. S.B. Kant, E. Van den Kerckhove, A new treatment of hypertrophic and keloid scars with combined triamcinolone and verapamil: a retrospective study, *European Journal of Plastic Surgery*, 2018; 41(1): 69–80.
18. G.P. Sidgwick, D. McGeorge, A. Bayat, A comprehensive evidence-based review on the role of topicals and dressings in the management of skin scarring, *Archives of Dermatological Research*, 2015; 307(6) 461–477.
19. Wolfram D, MD, Tzankov A, MD, Hypertrophic Scars and Keloids—A Review of Their Pathophysiology, Risk Factors, and Therapeutic Management, *Dermatologic Surgery*, Volume 35, Issue 2, February 2009, Pages 171-181

## **9. Biography**

I was born in Casablanca, in Morocco on the 5th of February 1989. I graduated from high school in the French High School of Casablanca then I moved to France to pursue a degree in microbiology.

Unsatisfied with my choice of carrier and supported by my father, I decided to continue my education and move to Zagreb to become a medical doctor and perpetuate our family tradition since we are doctors in my family: from fathers to sons, and in my case, to daughter.

Since a very young age I was involved in my father's charity that gathers doctors from all specialties and brings them to remote areas to provide desperately needed healthcare. So my interest for medicine begun at a very young age especially for the field of dermatology.

I am fluent in speaking English, French, Arabic and Croatian.