

Sixth cranial nerve palsy and ipsilateral segmental carotid arteritis after tooth alveolectomy

Ivančić, Biljana Đapić; Jovanović, Ivan; Ljevak, Josip; Poljaković, Zdravka

Source / Izvornik: **Neurological Sciences, 2019, 40, 1975 - 1977**

Journal article, Accepted version

Rad u časopisu, Završna verzija rukopisa prihvaćena za objavljivanje (postprint)

<https://doi.org/10.1007/s10072-019-03888-2>

Permanent link / Trajna poveznica: <https://um.nsk.hr/um:nbn:hr:105:608623>

Rights / Prava: [In copyright](#)

Download date / Datum preuzimanja: **2022-01-23**



Repository / Repozitorij:

[Dr Med - University of Zagreb School of Medicine
Digital Repository](#)



SIXTH CRANIAL NERVE PALSY AND IPSILATERAL SEGMENTAL CAROTID ARTERITIS AFTER TOOTH ALVEOLECTOMY

Biljana Dapic Ivancic¹, Ivan Jovanovic², Josip Ljevak³, Zdravka Poljakovic³

¹Division for Neurology, General Hospital Zadar, B. Pericica 5, 23 000 Zadar, Croatia, biljana.dapic@gmail.com

²Department of Diagnostic and Interventional Radiology, University Hospital Centre Zagreb, School of Medicine, University of Zagreb, Kispaticeva 12, 10000 Zagreb, Croatia

³Department of Neurology, University Hospital Centre Zagreb, School of Medicine, University of Zagreb, Referral Centre of the Ministry of Health of the Republic of Croatia for intensive neurology and endovascular treatment of stroke and vascular malformations of the central nervous system, Kispaticeva 12, 10000 Zagreb, Croatia

Dear editor,

isolated sixth cranial nerve palsy caused by sphenoid sinusitis is a rare condition especially if associated with segmental internal carotid arteritis (ICA). To our knowledge, there are 17 case reports describing sixth cranial nerve palsy secondary to sphenoid sinusitis and 18 case reports describing an isolated atypical arteritis of ICA. One of these reports presented novel “isolated internal carotid arteritis” disease concept which suggest arteritis caused by autoimmune disease of unknown cause, is confirmed with the efficacy of steroid therapy, and has no other symptoms or organ involvements, or autoantibodies (such as systemic lupus erythematosus and medium- or small-vessel vasculitis or Behçet’s disease) indicating autoimmune disease. Tuberculosis also has to be excluded, due to possible infectious vasculitis of sole ICA in tuberculous patient. (1,2,3)

On the other hand, isolated sphenoid sinusitis (ISS) is a rare disease which accounts for 1% to 2% of all paranasal sinus infections. It is characterised with subtle onset and symptoms like headache and nonspecific facial pain but sometimes in severe cases it can spread to nearby anatomic structures including cranial nerves. Early antibiotic treatment or/and surgical intervention to the affected sinuses are warranted. (2,4)

We present a patient who developed pansinusitis, sixth cranial nerve palsy and segmental arteritis of internal carotid artery (ICA) after tooth alveolectomy. Segmental arteritis of ICA was diagnosed by neuroradiological investigations (magnetic resonance brain imaging (MRI), magnetic resonance angiography (MRA), and digital subtraction angiography (DSA)), showing no other blood vessel and organ involvement. Patient had proven pansinusitis with mostly affected sphenoid sinus, and no autoantibodies or findings who could indicate autoimmune disease or tuberculosis.

CASE REPORT:

We are presenting a 43 years old female patient, who has been admitted in our University Hospital Center, Neurological Intensive Care Unit, for a further evaluation of double vision and sixth cranial nerve palsy.

During her life, she had two miscarriages, has allergic asthma and takes montelukast not regularly.

Three months before admission to our hospital, the lady started to feel some pain on the right side of her face, mostly supra and infraorbital. She had been taking antibiotics and anti-inflammatory drugs (NSAID) for two weeks, but the pain got even worse. Therefore, the radiogram of the jaw was performed and the inflammation of the right fifth tooth was described. Due to this finding, maxillofacial surgeon decided to operate, so alveolectomy was performed. However, the second day after surgery she developed double vision and on neurological examination sixth cranial nerve (n. abducens) palsy was discovered. Hess Lancaster test confirmed the clinical finding.

Extended laboratory (complete blood count, liver function tests, urea, creatinine, troponin, creatinine kinase, cholesterol and triglycerides, thyroid enzymes and antibodies, Aquaporin antibodies,) tests were performed followed by neurosonology exam (Color Doppler Flow Imaging – CDFI) showing normal blood flow and normal neuroimaging of the brain (MSCT of brain). Contrast MRI showed no pathomorphological changes except bilateral edged mucosal thickening of paranasal sinuses without “air-fluid” levels. In spite of anti-inflammatory (NSAID) and intramuscular (im) injections of 4 mg dexamethasone, pain and double vision due to sixth nerve palsy were constant.

Two months after the beginning of illness a control MRI with contrast enhanced 3D TOF angiography was performed. Pansinusitis dominantly affecting sphenoid sinus was observed (Figure 1.A). Contrast-enhanced TOF angiography revealed wall thickening in the right internal carotid artery (ICA) most pronounced at the level of Dorello’s canal (Figure 1.B).

Due to this MRI findings, the therapy was changed and she received intravenous (iv) methylprednisolone (500mg/day) during five days followed by iv antibiotics for two weeks. At this point, pain decreased but sixth nerve palsy persisted.

One month later, the patient was admitted to our Clinic with the same clinical symptom of the sixth nerve palsy. Control brain MRI with 3D TOF was performed, cavernous sinuses were described normal but Coronal T1-weighted MRI images before and after contrast administration showed wall thickening and enhancement in the right ICA (Figure 1. C, D).

Therefore, DSA was performed and showed isolated stenosis of petrous and cavernous segments of the right ICA. No abnormalities on other intracranial arteries were found, and segmental arteritis was hereby confirmed. (Figure 2. A, B).

She was also examined by immunologists, all immunological serum analysis were at reference intervals (ANA, ANCA, SS-A, SS-B, C3, C4, anticardiolipin antibodies, Beta 2 GPI, electrophoresis and immunoelectrophoresis of proteins, immunofixation, sedimentation, lupus anticoagulant), neurotropic serum viruses were negative, HCV and HBV were negative, vitamin B12 and folic acid were also normal findings. Quantiferon test turned out positive but without any clinical correlation. Patient refused lumbar puncture.

After hospitalization of 2 weeks, without any clinical changes and after introducing corticosteroid therapy again (oral methylprednisolone 8mg/day) patient was released from the hospital.

Control MRI and MRA performed one month after hospitalization showed the minimal reduction of ICA stenosis accompanied with regression of clinical symptoms (patient had no more double vision). Sixth nerve palsy by clinical examination of left eye abduction seemed less visible.

A patient continued to take methylprednisolone in dose 8mg a day and after 10months control neuroradiological examinations were performed. MRI before (Figure 1.E) and after contrast administration (Figure 1.F) revealed only minimal residual wall thickening. DSA of right internal carotid artery showed improvement in the stenosis with minimal residual narrowing of the petrous segment (Figure 2. C, D).

Due to this results and with no neurological symptoms we decided to reduce corticosteroid therapy and after 2 weeks completely exclude. Control MRI and MRA are planed in the six months interval.

DISCUSSION:

Sixth cranial nerve palsy after paranasal sinuses infection is an extremely rare clinical condition.

According to our knowledge there are 17 case reports in the literature describing sixth cranial nerve palsy secondary to sphenoid sinusitis (2) and 18 case reports describing an isolated atypical intracranial arteritis (3). However, according to our findings, our patient fulfils the criteria of both conditions.

In our patient there is a direct time correlation between tooth surgery and development of sixth cranial nerve palsy followed by isolated arteritis of ICA, without any other neurological dysfunction but with clear morphological characteristic of inflammatory changed blood vessel and segmental stenosis. By all findings and after excessive neuroimaging and laboratory exams we can conclude that this is a case of localised inflammatory reaction with engaging internal carotid artery wall as well as sixth cranial nerve in the anatomic area of Dorello's canal (Figure1. A, B). Cavernous sinus was clear in all performed MRI and MRA. The most possible mechanism of sixth cranial nerve lesion in patient presented here is spread of the inflammation process from the sinus. Less possible cause is compressive effect to the nerve due to inflamed and thickened artery wall. Whatever the initial mechanism of sixth cranial nerve lesion in our case is, after the targeted antibiotic therapy, there was a significant clinical improvement (pain relief) but with nerve palsy and double vision still present. Further therapy were only corticosteroids, which led to complete regression of the symptoms and significant improvement of neuroradiological findings (Figure1. E, F, Figure 2. C, D).

Therefore, we consider the initial clinical and morphological features in our case of an infectious origin however followed by an unusual immunological response, which may be consistent with the novel concept of segmental intracranial arteritis, and theory of "isolated internal carotid arteritis" as recently described in the report of Kazuki Fukuma et al (3).

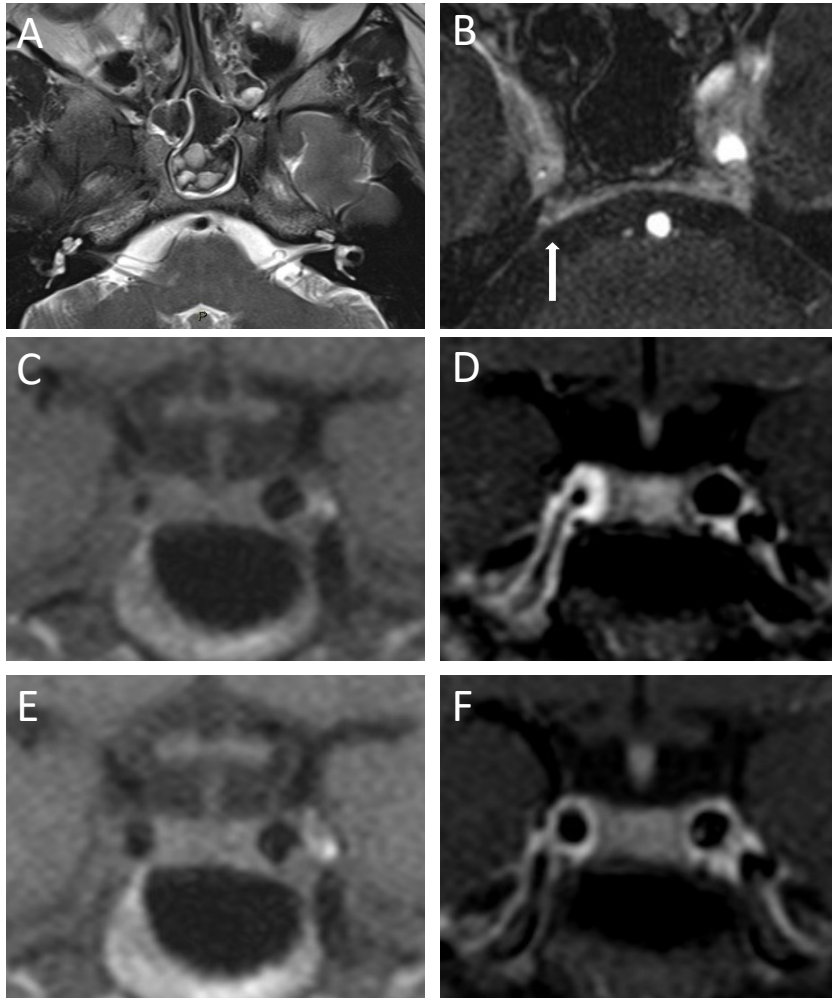


Figure 1.

Initial magnetic resonance imaging (MRI) images showed inflammatory changes in the sphenoid sinus(A). Contrast-enhanced 3D TOF MRI angiography revealed wall thickening in the right internal carotid artery (ICA), most pronounced at the level of Dorello's canal (arrow)(B).

Control coronal T1-weighted (C) and contrast-enhanced T1 weighted (D) MRI images performed 1 month later showed persistent wall thickening and enhancement of the right ICA.

Control T1-weighted images before (E) and after contrast administration (F) performed after 10 months of steroid therapy revealed only minimal residual wall thickening.

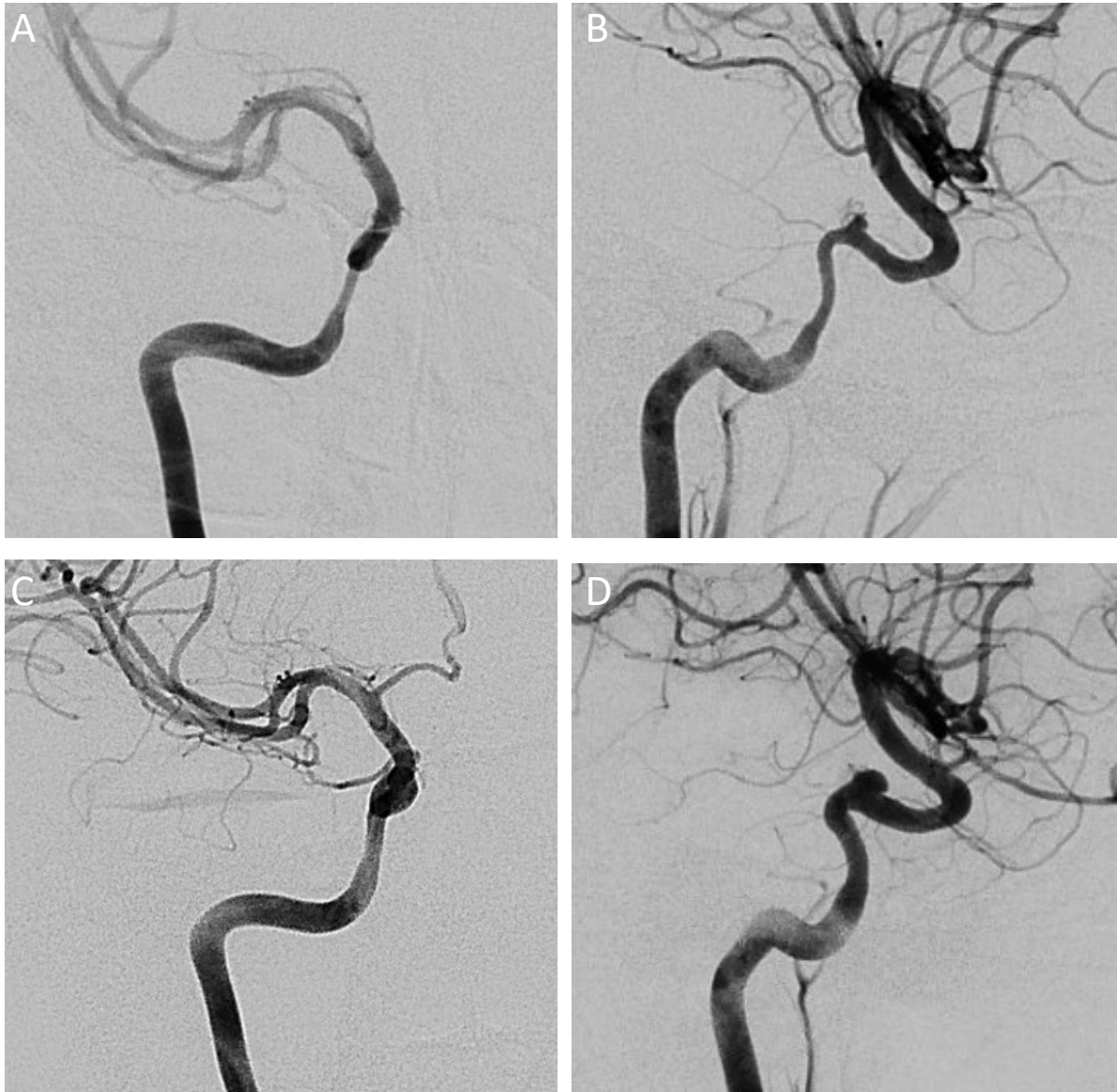

Figure 2. Anteroposterior and lateral projection of right internal carotid artery angiogram prior to initiation of corticosteroid therapy demonstrating narrowing of the petrous and proximal cavernous segments (A,B). Right internal carotid artery angiograms after 10 months of corticosteroid therapy, showing improvement in the stenosis with minimal residual narrowing of the petrous segment(C,D).

Ethical approval: This article does not contain research including human participants or animals performed by any of the authors.

Informed consent: Informed consent was obtained from the patient included in the study.

Declarations of interest: The authors declare that they have no conflict of interest.

References:

1. Azarmina M, Azarmina H. (2013) The six syndromes of the sixth cranial nerve. *J Ophthalmic Vis Res.*;8(2):160-71.
2. El Mograbi A, Soudry E. Ocular cranial nerve palsies secondary to sphenoid sinusitis(2017)*World J Otorhinolaryngol Head Neck Surg.* 3(1):49-53. doi:10.1016/j.wjorl.2017.02.001.
3. Kazuki Fukuma, Hisanori Kowa, Hiroyuki Nakayasu,[†] and Kenji Nakashima[‡](2016)Atypical Arteritis in Internal Carotid Arteries: A Novel Concept of Isolated Internal Carotid. *Yonago Acta Med.* 59(3): 248–254.
4. Gupta R, Shukla R, Mishra A, Parihar A. (2015) Isolated acute sphenoid sinusitis presenting with hemicranial headache and ipsilateral abducens nerve palsy.*BMJ Case Rep.* pii: bcr2015209408. doi: 10.1136/bcr-2015-209408.