

Combined Albenazole-Praziquantel Treatment in Recurrent Brain Echinococcosis: Case Report

Skuhala, Tomislav; Trkulja, Vladimir; Runje, Mislav; Balen-Topić, Mirjana; Vukelić, Dalibor

Source / Izvornik: *Iranian journal of parasitology*, 2019, 14, 492 - 496

Journal article, Published version

Rad u časopisu, Objavljena verzija rada (izdavačev PDF)

Permanent link / Trajna poveznica: <https://um.nsk.hr/um:nbn:hr:105:278798>

Rights / Prava: [Attribution-NonCommercial-NoDerivatives 4.0 International](#)

Download date / Datum preuzimanja: **2021-10-20**



Repository / Repozitorij:

[Dr Med - University of Zagreb School of Medicine
Digital Repository](#)





Tehran University of Medical
Sciences Publication
<http://tums.ac.ir>

Iran J Parasitol

Open access Journal at
<http://ijpa.tums.ac.ir>



Iranian Society of Parasitology
<http://isp.tums.ac.ir>

Case Report

Combined Albendazole-Praziquantel Treatment in Recurrent Brain Echinococcosis: Case Report

*Tomislava SKUHALA¹, Vladimir TRKULJA², Mislav RUNJE³, Mirjana BALEN-TOPIĆ¹, Dalibor VUKELIĆ¹, Boško DESNICA¹

1. University Hospital for Infectious Diseases "Fran Mihaljević", Zagreb, Croatia
2. Department of Pharmacology, School of Medicine, Zagreb University, Zagreb, Croatia
3. TAPI Research and Development Analytics, Pliva Croatia, Zagreb, Croatia

Received 25 Jun 2018

Accepted 11 Aug 2018

Keywords:

Albendazole;
Praziquantel;
Brain echinococcosis;
Albendazole-sulphoxide
concentration

***Correspondence Email:**

tomislava_skuhala@yahoo.com

Abstract

We present a 40-year-old woman with a history of relapsing echinococcosis who had undergone a number of surgical procedures for cyst removal (right pulmectomy, cardiac surgery and 6 subsequent brain surgeries and two gamma knife procedures) and was admitted to University Hospital for Infectious Diseases "Fran Mihaljević", Zagreb, Croatia in 2014 for pre-operative medical treatment of brain hydatidosis in the right parietal region. We aimed to attain a high cyst albendazole sulphoxide (ASO) concentration in order to achieve a more pronounced protoscolex inactivation and a high serum ASO concentration (reflecting the tissue concentrations) to reduce the risk of disease recurrence. The patient was treated with a higher dose of albendazole (15 mg/kg/day for 4 wk) that we had found effective in patients with liver hydatidosis, and combined with praziquantel over the last 14 d at a dose that is typically used to treat neurocysticercosis with an intention to improve ASO bioavailability. Neither serum nor cerebrospinal fluid concentrations on day 10 apparently differed from those on day 24 indicating a lack of an effect of praziquantel on ASO bioavailability. Intra-cystic ASO concentration was below the lower limit of quantification, but above the limit of detection. After the 7th episode of the disease and combined albendazole-praziquantel and surgery treatment, the patient achieved a 3-year remission. With the apparent lack of a meaningful pharmacokinetic praziquantel-albendazole interaction, this is most likely ascribable to the use of a higher albendazole dose than previously.

Introduction

Echinococcosis is an anthroponosis caused by the larvae of *Echinococcus granulosus* (1). In humans, the parasite develops in the form of hydatid cyst(s) mostly affecting the liver or the lungs (1-3). Cerebral cysts are present in 2%-3% of neurologically symptomatic patients typically invading the middle cerebral artery territory, but any location is possible and prevalence of asymptomatic brain infection is unknown. Symptoms depend on the location and may vary from simple headache to uncal herniation (4). Treatment of the brain hydatid cysts includes surgical removal and treatment with benzimidazole anthelmintic drugs. The pharmacological mono treatment is indicated in cases of surgically unreachable cysts, but it is typically adjunctive to surgery (4).

Praziquantel, a broad spectrum anthelmintic ineffective against *E. granulosus* (5), by an unknown mechanism increases bioavailability of albendazole-sulfoxide (ASO), the active metabolite of albendazole and combination of the two is superior to albendazole alone in patients with intra-abdominal hydatid cysts (6-9).

Here we present a patient with brain hydatidosis who experienced a number of recurrent episodes despite the peri-operative treatment with albendazole, and who eventually underwent a combined albendazole-praziquantel peri-operative treatment to achieve a prolonged remission but without apparent effect of praziquantel on bioavailability of ASO.

Case report

Written informed consent was obtained from the patient for publication of this case report and any accompanying images.

In Sep 2014, a 40-year-old woman with a history of relapsing echinococcosis was referred to the University Hospital for Infectious Diseases, Zagreb, Croatia for pre-

operative medical treatment of brain hydatidosis since magnetic resonance imaging revealed a conglomerate of cystic formation (6.3 x 4.5 cm) in the right parietal region. Since 2006, when she was first diagnosed with pulmonary hydatidosis, she had undergone a number of surgical procedures for cyst removal—right pulmectomy in 2006, cardiac surgery and first brain surgery in 2009, and then 5 subsequent surgeries and two gamma knife procedures for brain hydatidosis by the end of 2013 (Fig. 1). Each procedure was preceded by albendazole treatment.

On admission, she complained of headaches, forehead paresthesias, dysgraphia, dyslexia, anxiety, instability and loss of peripheral vision. Apart from a decreased nasolabial fold prominence on the left side and increased gamma glutamyltransferase (GGT) (104 U/L), the results of physical examination and of laboratory tests were unremarkable. The only chronic treatment was methylphenobarbitone 200 mg/day started in 2009, after the first brain surgery.

A 28-day albendazole treatment was commenced: 15 mg/kg/d split into 3 daily administrations with a fatty meal to increase bioavailability. At day 14, praziquantel 50 mg/kg/day (three times daily, together with albendazole) was added for the subsequent 14 d. Within 20 h after the last dose, she underwent craniotomy and cyst removal (Fig. 1). Albendazole was continued post-operatively, as well. Peripheral venous blood samples and cerebrospinal fluid (CSF) samples were taken on days 10 and 24 (day 10 of combined albendazole + praziquantel) of pharmacological pre-treatment at the time of the expected peak (3 h after the morning dose) (6,7) for determination of ASO concentrations. Intraoperatively, a sample of the cyst content was taken for the same purpose, and another sample was taken for microbiological evaluation. ASO concentrations were measured by high-pressure liquid

chromatography method with UV detection (10). Neither serum nor CSF concentrations on day 10 (albendazole-only treatment) apparently differed from those on day 24 (day 10 of

combined treatment) indicating a lack of an effect of praziquantel on ASO bioavailability (Fig. 1).

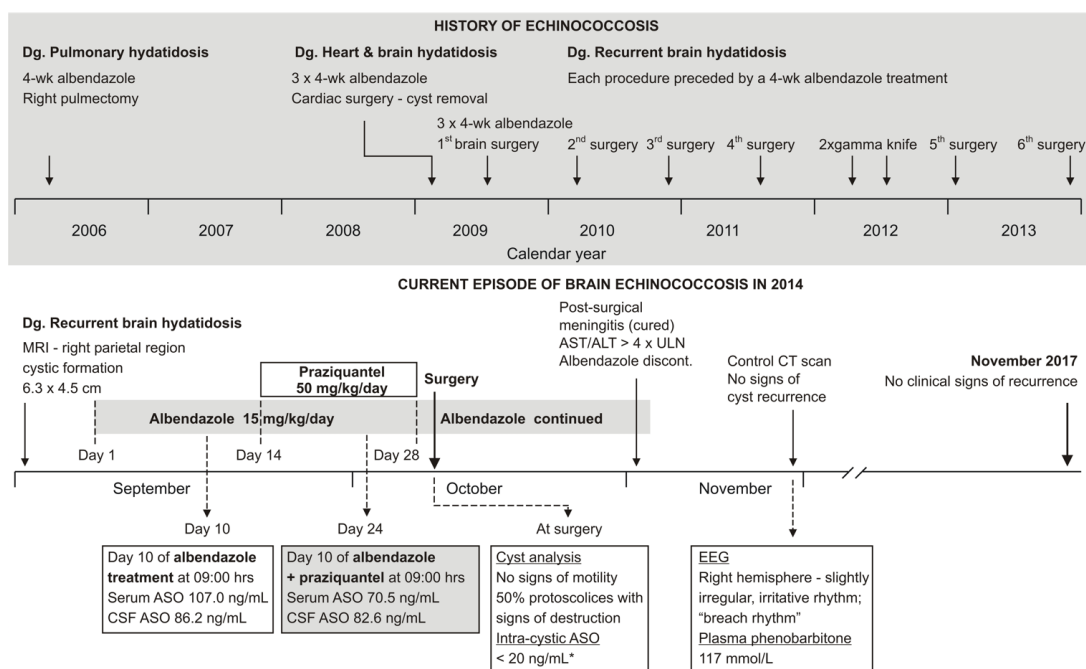


Fig. 1: Schematic outline of the patient's echinococcosis history (upper panel) and sequence of treatments, evaluations and outcomes of the current episode (lower panel).

ALT – alanine aminotransferase; ASO – albendazole-sulphoxide; AST – aspartat aminotransferase; CSF – cerebrospinal fluid; CT – computed tomography; EEG – electroencephalography; MRI – magnetic resonance imaging; ULN – upper limit of normal

*The lower limit of quantification of the method was 20 ng/mL and the lower limit of detection was 2.0 ng/mL. The measured value could not be precisely quantified since it was between the two values

Intra-cystic concentration was below the lower limit of quantification (20 ng/mL), but above the limit of detection (2.0 ng/mL). Unstained wet mount confirmed echinococcosis, whereas further analysis (samples incubated with sodium taurocholate in Hank's buffer for 48 h at 37 °C to re-create conditions of the canine gastrointestinal system"stimulation" (10)) revealed lack of viable protoscolices, whereas 50% of protoscolices showed signs of destruction. Subsequently (Fig.1), she developed post-surgical bacterial meningitis which resolved upon a 14-day meropenem and vancomycin treatment. At that time rise of aspar-

tate aminotransferase (89 U/L), alanine aminotransferase (143 U/L), GGT (464 U/L) and alkaline phosphatase (136 U/L) was observed and albendazole was discontinued (Fig. 1). One week after resolution of meningitis, a computed tomography brain scan revealed no signs of echinococcosis recurrence with a lesion at the sight of the previous cyst location (Fig. 2). Neurological evaluation was unremarkable and plasma phenobarbitone concentration (117 mmol/L) was within the therapeutic range (60-170 mmol/L). In Nov 2017, 3 years after the index craniotomy, the patient is without signs of disease recurrence.

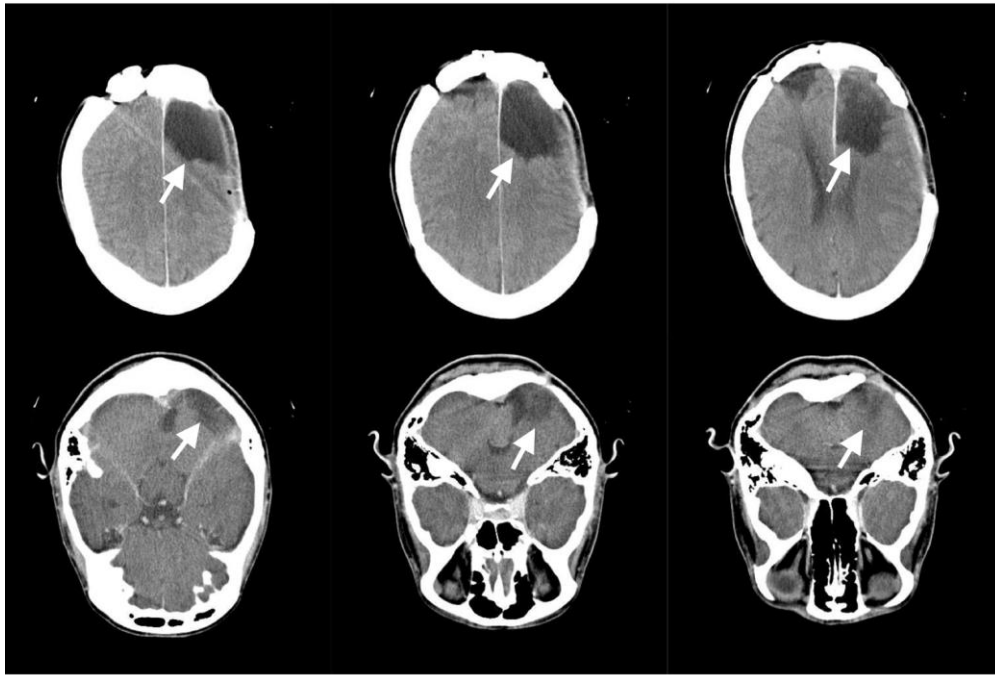


Fig. 2: Axial native and postcontrast computer tomography (CT) scan at the parietal lobe level. An 5.6x3.7 cm encephalomalacic area is seen in the right parietal region, as a consequence of previous cystic lesion conglomerate extirpation. Encephalomalacic lesions in the right cerebellar hemisphere and the left parietal lobe did not change in comparison with previous images performed. There are no neuroradiologic signs of echinococcosis recurrence

Discussion

All fourteen 4-week treatments implemented prior to surgical procedures before the index surgery used the most common albendazole dosing schedules (10 mg/kg/day twice daily) yet the disease relapsed after each procedure. Therefore, the present episode was treated with a higher dose of albendazole (15 mg/kg/day in 3 administrations) that we found effective in patients with liver hydatidosis (10), and was combined with praziquantel over the last 14 d at a dose typically used to treat neurocysticercosis (5) with an intention to improve ASO bioavailability (11,12).

Upon ingestion, albendazole is pre-systemically rapidly oxidized to ASO] mainly via cytochrome P450 (CYP) 3A4], which is further oxidized to inactive sulphone (by CYPs) (13). Patients with brain hydatidosis are maintained on antiepileptic drugs, typically

carbamazepine, phenytoine or (methyl) phenobarbitone, all of which induce CYP3A4 and reduce systemic ASO concentrations (by around 65% in the case of phenobarbitone) (13), but increased ASO bioavailability by praziquantel is seen in patients with CYP induction, as well (11). In this patient, praziquantel did not increase systemic or CSF availability of ASO, which is in line with the reported high inter-individual variability of the praziquantel-albendazole interaction (13). The intra-cystic ASO concentration appeared low, much lower than reported for non-brain cyst locations (10, 14), but according to the microbiological analysis, it was sufficient to inhibit viability and induce a considerable destruction of proto-scolices. Although the observed 3-year remission does not exclude a possibility of a further disease relapse, it is the longest disease-free period in this patient since the initial occurrence of brain hydatidosis in 2009. With ap-

parent lack of a meaningful pharmacokinetic praziquantel-albendazole interaction, it is most likely ascribable to the use of a higher (15 mg/kg/day) albendazole dose than in the previous cycles.

Conclusion

Brain echinococcosis is a rare localization of echinococcosis, there are no available data of ASO concentration in brain cysts, no potential positive drug interactions for treatment of this location of cysts and optimal treatment for long remission, and therefore further studies are needed.

Acknowledgements

No financial support was required.

Conflict of interests

The authors declare that there is no conflict of interest.

References

1. Brunetti E, Kern P, Vuitton DA. Expert consensus for the diagnosis and treatment of cystic and alveolar echinococcosis in humans. *Acta Trop.* 2010;114(1):1-16
2. Sabzevari S, Badirzadeh A, Shahkaram R, Seyyedini M. Traumatic rupture of liver hydatid cysts into the peritoneal cavity of an 11-year-old boy: a case report from Iran. *Rev Soc Bras Med Trop.* 2017;50(6):864-867.
3. McManus DP, Gray DJ, Zhang W, Yang Y. Diagnosis, treatment and management of echinococcosis. *BMJ.* 2012;344:e3866.
4. Nourbakhsh A, Vannemreddy P, Minagar A et al. Hydatid disease of the central nervous system: a review of literature with an emphasis on Latin American countries. *Neurol Res.* 2010;32(3):245-51.
5. Chai JY. Praziquantel treatment in trematode and cestode infections: an update. *Infect Chemother.* 2013;45(1):32-43.
6. Homeida M, Leahy W, Copeland S, Ali MM, Harron DW. Pharmacokinetic interaction between praziquantel and albendazole in Sudanese men. *Ann Trop Med Parasitol.* 1994;88(5):551-9.
7. Lima RM, Ferreira MA, de Jesus Ponte Carvalho TM et al. Albendazole-praziquantel interaction in healthy volunteers: kinetic disposition, metabolism and enantioselectivity. *Br J Clin Pharmacol.* 2011;71(4):528-35.
8. Mohamed AE, Yasawy MI, Al Karawi MA. Combined albendazole and praziquantel versus albendazole alone in the treatment of hydatid disease. *Hepatogastroenterology.* 1998; 45(23):1690-4.
9. Cobo F, Yarnoz C, Sesma B et al. Albendazole plus praziquantel versus albendazole alone as a pre-operative treatment in intra-abdominal hydatidosis caused by *Echinococcus granulosus*. *Trop Med Int Health.* 1998;3(6):462-6.
10. Skuhala T, Trkulja V, Runje M, Vukelic D, Desnica B. Albendazole sulphoxide concentrations in plasma and hydatid cyst and prediction of parasitological and clinical outcomes in patients with liver hydatidosis caused by *Echinococcus granulosus*. *Croat Med J.* 2014;55(2):146-55.
11. Garcia HH, Lescano AG, Lanchote VL et al. Pharmacokinetics of combined treatment with praziquantel and albendazole in neurocysticercosis. *Br J Clin Pharmacol.* 2011;72(1):77-84.
12. Garcia HH, Gonzales I, Lescano AG et al. Efficacy of combined antiparasitic therapy with praziquantel and albendazole for neurocysticercosis: a double-blind, randomized controlled trial. *Lancet Infect Dis.* 2014;14(8):687-695.
13. Pawluk SA, Roels CA, Wilby KJ, Ensom MH. A review of pharmacokinetic drug-drug interactions with the anthelmintic medications albendazole and mebendazole. *Clin Pharmacokinet.* 2015;54(4):371-83.
14. Lötsch F, Naderer J, Skuhala T. Intra-cystic concentrations of albendazole-sulphoxide in human cystic echinococcosis: a systematic review and analysis of individual patient data. *Parasitol Res.* 2016;115(8):2995-3001.