

Evaluation of synthetic ceramics as compression resistant matrix to promote osteogenesis of autologous blood coagulum containing recombinant human bone morphogenetic protein 6 in rabbit posterolateral lumbar fusion model

Štoković, Nikola; Ivanjko, Natalia; Pećin, Marko; Erjavec, Igor; Karlović, Sven; Smajlović, Ana; Capak, Hrvoje; Milošević, Milan; Bubić Špoljar, Jadranka; Vnuk, Dražen; ...

Source / Izvornik: **Bone**, 2020, 140

Journal article, Published version

Rad u časopisu, Objavljena verzija rada (izdavačev PDF)

<https://doi.org/10.1016/j.bone.2020.115544>

Permanent link / Trajna poveznica: <https://um.nsk.hr/um:nbn:hr:105:435020>

Rights / Prava: [Attribution 4.0 International](#)/[Imenovanje 4.0 međunarodna](#)

Download date / Datum preuzimanja: **2024-07-05**



Repository / Repozitorij:

[Dr Med - University of Zagreb School of Medicine](#)
[Digital Repository](#)

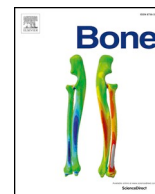




ELSEVIER

Contents lists available at ScienceDirect

Bone

journal homepage: www.elsevier.com/locate/bone

Evaluation of synthetic ceramics as compression resistant matrix to promote osteogenesis of autologous blood coagulum containing recombinant human bone morphogenetic protein 6 in rabbit posterolateral lumbar fusion model



Nikola Štoković^{a,b}, Natalia Ivanjko^{a,b}, Marko Pećin^c, Igor Erjavec^{a,b}, Sven Karlović^d, Ana Smajlović^c, Hrvoje Capak^c, Milan Milošević^e, Jadranka Bubić Špoljar^{a,b}, Dražen Vnuk^c, Dražen Maticić^c, Hermann Oppermann^f, T. Kuber Sampath^g, Slobodan Vukičević^{a,b,*}

^a Laboratory for Mineralized Tissues, School of Medicine, University of Zagreb, Zagreb, Croatia

^b Scientific Center of Excellence for Reproductive and Regenerative Medicine, Zagreb, Croatia

^c Clinics for Surgery, Orthopedics and Ophthalmology, School of Veterinary Medicine, University of Zagreb, Zagreb, Croatia

^d Faculty of Food Technology and Biotechnology, University of Zagreb, Zagreb, Croatia

^e Department for Environmental Health, Occupational and Sports Medicine, Andrija Štampar School of Public Health, School of Medicine, University of Zagreb, Zagreb, Croatia

^f Genera Research, Kalinovica, Rakov Potok, Croatia

^g perForm Biologics Inc, Holliston, MA, USA

ARTICLE INFO

Keywords:

Posterolateral lumbar fusion (PLF)
BMP6
Synthetic ceramics
Autologous bone graft substitute (ABGS)
BMP carrier
Autologous blood coagulum

ABSTRACT

Posterolateral lumbar fusion (PLF) is a commonly performed surgical procedure for the treatment of pathological conditions of the lumbosacral spine. In the present study, we evaluated an autologous bone graft substitute (ABGS) containing rhBMP6 in autologous blood coagulum (ABC) and synthetic ceramics used as compression resistant matrix (CRM) in the rabbit PLF model. In the pilot PLF rabbit experiment, we tested four different CRMs (BCP 500–1700 μm, BCP 1700–2500 μm and two different TCP in the form of slabs) which were selected based on achieving uniform ABC distribution. Next, ABGS implants composed of 2.5 mL ABC with 0.5 g ceramic particles (TCP or BCP (TCP/HA 80/20) of particle size 500–1700 μm) and 125 μg rhBMP6 (added to blood or lyophilized on ceramics) were placed bilaterally between transverse processes of the lumbar vertebrae (L5-L6) following exposition and decortication in 12 New Zealand White Rabbits observed for 7 weeks following surgery. Spinal fusion outcome was analysed by μCT, palpatory segmental mobility testing and selected specimens were either tested biomechanically (three-point bending test) and/or processed histologically. The total fusion success rate was 90.9% by both μCT analyses and by palpatory segmental mobility testing. The volume of newly formed bone between experimental groups with TCP or BCP ceramics and the different method of rhBMP6 application was comparable. The newly formed bone and ceramic particles integrated with the transverse processes on histological sections resulting in superior biomechanical properties. The results were retrospectively found superior to allograft devitalized mineralized bone as a CRM as reported previously in rabbit PLF. Overall, this novel ABGS containing rhBMP6, ABC and the specific 500–1700 μm synthetic ceramic particles supported new bone formation for the first time and successfully promoted posterolateral lumbar fusion in rabbits.

1. Introduction

Posterolateral spinal fusion (PLF) is a commonly performed surgical procedure for the treatment of pathological conditions of the lumbosacral spine including degenerative disc disease, spondylolisthesis, spinal instability and symptomatic scoliosis [1–4]. Most spinal arthrodesis procedures consist of an autologous bone graft (autograft;

ABG) or an autologous bone graft substitute (ABGS) combined with a posterior instrumentation consisting of pedicle screws and rods [1].

Autologous bone grafts are currently considered as the gold standard for PLF because they possess inherent osteoconductivity, osteogenicity and osteoinductivity [5–7]. However, the use of autografts has several limitations including small amount of bone graft which can be harvested and morbidities associated with the donor site (acute and

* Corresponding author at: Laboratory for Mineralized Tissues, School of Medicine, University of Zagreb, Zagreb, Croatia.

E-mail address: slobodan.vukicevic@mef.hr (S. Vukičević).

<https://doi.org/10.1016/j.bone.2020.115544>

Received 19 May 2020; Received in revised form 30 June 2020; Accepted 7 July 2020

Available online 27 July 2020

8756-3282/ © 2020 The Authors. Published by Elsevier Inc. This is an open access article under the CC BY license (<http://creativecommons.org/licenses/by/4.0/>).

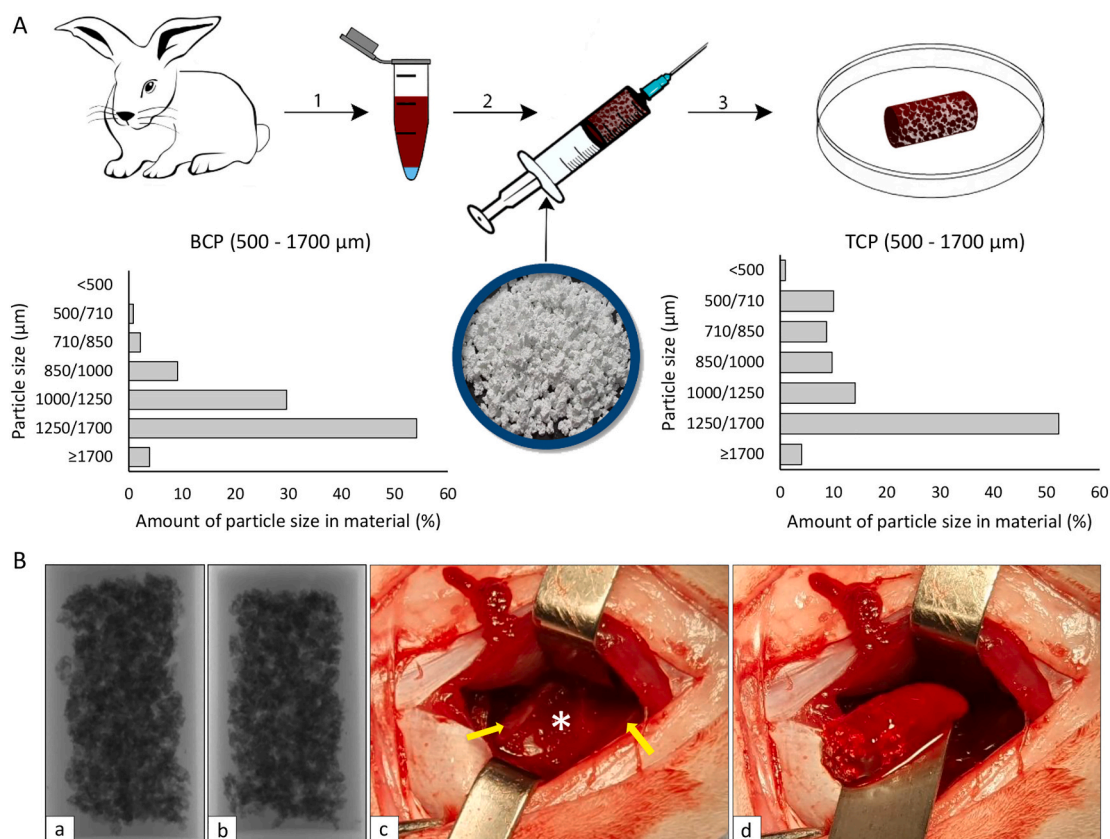


Fig. 1. (A) Implant preparation; steps are marked with numbers: 1 – blood was withdrawn from the ear vein in a volume of 2,5 mL per implant and transferred to the tube with aliquoted solution of rhBMP6; 2 – blood with rhBMP6 is transferred into the syringe containing CRM and was left on room temperature to coagulate; 3 – final product (ABGS containing CRM) was ready for implantation. Graphs showed the distribution of BCP and TCP ceramics with the largest particle size fraction from 1250 to 1700 μm (BCP - 54,2%, TCP - 52,4%) following particle size of 1000–1250 μm (BCP - 29,7%, TCP - 14,1%). (B) Frontal (a) and lateral (b) X - ray of implant showing the distribution of CRM; c - exposed space (white asterisk) between transverse processes (yellow arrow) prior to implantation; d - implantation and placement of the implant between transverse processes. (For interpretation of the references to colour in this figure legend, the reader is referred to the web version of this article.)

chronic pain, risk for wound infection, skin scarring and deformity) or secondary surgery (increased blood loss and length of the procedure) [1,2,7–10]. Therefore, there is an imminent medical need for osteoinductive autologous bone graft substitute (ABGS), which would replace the use of autografts and provide a safe solution for treatment of patients with spinal pathology.

Bone morphogenetic proteins (BMPs) are well known osteoinductive molecules and their efficacy to achieve posterolateral spinal fusion has been demonstrated in preclinical rabbit, sheep and primate studies [1,3,4,8,9,11–20]. However, a major challenge which still remains unresolved is the development of an optimal carrier/delivery system for BMPs [3]. The ideal BMP carrier should be biocompatible, sustain the BMP concentration at the treatment site, enable vascular and cellular invasion, define the contours of the resulting bone, prevent ectopic ossification [19,21–24] and most importantly, maintain its biological and biomechanical function for an extended time avoiding thus rapid loss of compression resistant matrix (CRM) and favouring biomechanically competent bone.

BMP carriers consist of: natural polymers, synthetic polymers, inorganic materials and composites of the same [24,25]. Bovine sourced collagen has been the most widely used as a BMP carrier [25], although it has shown major disadvantages including compressibility, a weak affinity for BMPs thus allowing enhanced release of the large amount of rhBMP used at the implant site and provoking unwanted safety issues i.e., heterotopic bone formation, and immune reactions [8,11]. Aforementioned problems required search of an alternative carrier [8] including synthetic ceramics such as tri-calcium phosphate (TCP) and hydroxyapatite (HA) either alone or in combination with collagen [3,8,11–14]. Although TCP has shown faster resorption rate than HA

[21] the strength and speed of resorption might be adjusted using bi-phasic calcium phosphate ceramic (BCP; containing both TCP and HA) with a different TCP to HA ratio [13].

We have shown recently that autologous blood coagulum (ABC) serves as a physiological native carrier for rhBMP6 to effect osteogenesis in various models such as rat subcutaneous assays, rabbit segmental bone defect and anterior lumbar inter-body and posterolateral lumbar fusion in rabbit and sheep [15,27]. Furthermore, we demonstrated that ABC suppresses foreign body response elicited by mineral containing compression resistant matrix like allograft, promotes rhBMP6 binding to plasma proteins within the fibrin meshwork, allows a sustained release of rhBMP6 and protects rhBMP6 against generation of rhBMP6 antibodies [15,22,26]. The safety and efficacy outcome obtained from these preclinical studies prompted us to evaluate a new ABGS (ABC/rhBMP6) containing allograft as compared to autograft in a randomized controlled clinical trial in patients undergoing PLIF due to the lumbar pain because of degenerative disc disease (EudraCT number 2017–000860-14). In the present study, we examined the use of synthetic ceramics as a CRM to substitute for devitalized mineralized allograft in conjunction with ABC containing rhBMP6 (ABGS) to promote osteogenesis and achieve complete spinal fusion in a rabbit PLF model.

2. Material and methods

2.1. Experimental design

Prior to in vivo testing synthetic ceramic particles of various sizes from 74 to 420 μm to 1700–2500 μm, and slabs were mixed with 2,5 mL of

rabbit blood to evaluate the uniformity of ceramic distribution in the ABGS prior to implantation. Since the ceramics below 500 µm size were not uniformly distributed following a standardized procedure with allograft (data not shown) as a CRM *in vitro* [15,26,27], in the further *in vivo* experiments we used ceramic composites of 500 µm and above. In the pilot PLF experiment four different ceramic composites (BCP 500–1700 µm particles, BCP 1700–2500 µm particles, two different TCP slabs – high and low porosity) in combination with 125 µg rhBMP6 and 2,5 mL ABC have been tested in 2 rabbits. The mass of the ceramic particles was 0,5 g/per implant, while the mass of slabs was approximately 0,75 g/per implant. Slabs were defined as cuboid, one-piece ceramics containing pores. Both tested TCP slabs were sintered at 1175 °C while the slurry weight/foam weight ratio was 24:1 and 35:1. The observation period in the pilot experiment was 60 days. The highest amount of newly formed bone followed by complete osseointegration with transverse processes was observed in the rabbits containing 500–1700 µm particles as CRM while ABGS containing slabs failed to achieve spinal fusion (see Fig. 2 in Results). Based on this experiment we designed and performed another rabbit experiment in which rhBMP6 was either added to blood and mixed with ceramic granules or priorly lyophilized on ceramics and mixed with blood. As a CRM we used the biphasic ceramic composed of tri-calcium phosphate and hydroxyapatite (TCP/HA ratio 80/20, particle size 500–1700 µm) and tri-calcium phosphate ceramics (particle size 500–1700 µm). The quantity and distribution of various particle size fractions among selected particle size range is shown in Fig. 1A. The average pore diameter for BCP was 175 µm and for TCP 157 µm while the total porous volume was 86% in BCP and 82% in TCP, respectively. Twelve White New Zealand rabbits (9 months old, weight 4 kg) were used and assigned to following experimental groups: A) Biphasic ceramic (BCP) 500–1700 µm + 2,5 mL ABC + 125 µgBMP6; B) Biphasic ceramic (BCP) 500–1700 µm + 2,5 mL ABC + 125 µgBMP6 (lyophilized on BCP); C) Tri-calcium phosphate ceramic (TCP) 500–1700 µm + 2,5 mL ABC + 125 µgBMP6; D) Tri-calcium phosphate ceramic (TCP) 500–1700 µm + 2,5 mL ABC + 125 µgBMP6 (lyophilized on TCP). Number of samples was 6 per group with an observation period of 50 days. In order to minimize the biological variability of implants on the results, ABGS implants from group A and B in rabbits 1–6 and groups C and D in rabbits 7–12 were alternated on the left and right lumbar spine side. In both experiments the rhBMP6 (Lot No 20160411) produced by Genera Research (Zagreb, Croatia) was used [15]. The ceramic particles and slabs were produced by CaP BioMaterials (East Troy, Wisconsin, USA).

2.2. ABGS preparation

Blood samples were collected from rabbit marginal ear vein into tubes without an anticoagulant substance in a volume of 2,5 mL (Fig. 1A). In the pilot experiment rhBMP6 (125 µg) was mixed with blood and ceramics, while in the subsequent experiment rhBMP6 (125 µg) was either mixed with blood and ceramics (group A and C) or lyophilized on the ceramics and then mixed with blood (group B and D). After blood and ceramics were mixed, the implant was rotated until blood coagulated in order to achieve a uniform distribution of the ceramic particles. Uniformity of particle distribution was confirmed using x-ray images (Fig. 1B-a,b). All implants were implanted in the animals 60 min after preparation.

2.3. Surgical procedure and X-ray monitoring

The surgery was carried out under general anesthesia and was performed by the same surgical team. The space between transverse processes of the lumbar L5-L6 vertebrae was exposed (Fig. 1B-c), and followed by bone decortication using a high speed burr. Implants were then placed bilaterally between the transverse processes (Fig. 1B-d). Animals were euthanized on day 60 in the pilot experiment and day 50 in the second experiment following sedation, premedication (3 mg/kg xylapane and 20 mg/kg ketamine *i.m.*) and administration of T61

(1 mL/kg) *i.v.* One rabbit died due to complications after surgery.

2.4. Radiological monitoring and analysis

X-ray images of rabbit lumbar spine were taken immediately after surgery (day 0) and at the end of experiments. Lumbar transverse processes and newly formed bone between them were scanned using 1076 SkyScan µCT machine to visualize new ectopic bone formation and to analyse osseointegration on µCT sections. Scanning resolution was set at 18 µm spatial resolution with 0.5 mm aluminium filter and frame averaging set to a value of 2. Due to larger size of specimens the scanning width was set to 68 mm. Acquired images were reconstructed using NRecon software (SkyScan, Belgium). Fused areas between the vertebrae were manually delineated and newly formed bone and the unresorbed CRM were analysed using CTAn software (SkyScan, Belgium). To distinguish bone tissue from CRM, based on the density, 4-level Otsu thresholding was used [28] with a concurrent use of global threshold for bone and CRM, respectively.

2.5. Biomechanical testing

Following µCT scanning, the region of interest was dissected and segmental mobility of fused transverse processes was tested. Mobility between the fused transverse processes was tested by palpation. The test was performed by two independent researchers. Fusion was considered successful if upon compression with fingers there was an absence of motion regularly observed between the vertebrae. Next, the three-point bending test was conducted to determine biomechanical parameters (maximum force, work-to-fracture and elasticity) of fusion mass consisting of newly formed bone and adjacent transverse processes. Three-point bending instrument (TA.HDPlus, Stable Micro Systems, Surrey, UK) used in this study was set with a 50 kg load cell. The fusion mass was placed on the two supports and the measured amount of force was applied perpendicular to the midpoint. Speed was adjusted at 0,5 mm/s, and the force was applied using a single-pronged loading device with flat-tipped wedge.

2.6. Histology

Undecalcified histology sections were done on 2 samples per group following µCT scanning and fixation in 10% neutral buffered formalin. Specimens were cut by saw in the frontal plane to expose transverse processes and newly formed bone between them. Specimens were dehydrated in graded solutions of ethyl alcohol (70%/80%/95%/100%) using an automated tissue processing system (ASP300S, Leica Biosystems, Buffalo Grove, Illinois, USA) and cleared manually with methyl salicylate and xylenes before being polymerized into hardened acrylic resin blocks (MMA). Semi-thin microtomed sections (thickness of 5 µm) were collected in the frontal plane using tungsten-carbide knives (D-profile, Delaware Diamond Knives, Wilmington, Delaware, USA), and an automated sledge microtome (SM2500, Leica Biosystems, Buffalo Grove, Illinois, USA). Each section was mounted on custom prepared gelatin coated (Haupt's Adhesive) glass microscope slides. Prior to staining, sections were deplasticized and hydrated. Finally, sections were stained with Von Kossa and modified Goldner's stain.

2.7. Histomorphometry

Quantitative analysis of newly formed bone, compression resistant matrix and bone marrow was achieved using histomorphometry. Histology sections were stained by Goldner, staining bone turquoise and CRM white. Images were taken using an Olympus microscopy system - Olympus BX53 Upright Microscope equipped with a DP27 camera (5 megapixels, 15 fps) and operated by cellSens Dimension software (Olympus, Japan). Goldner stained sections were imaged at 4 x (0.73 pixel/µm) magnification. The whole area of histological section,

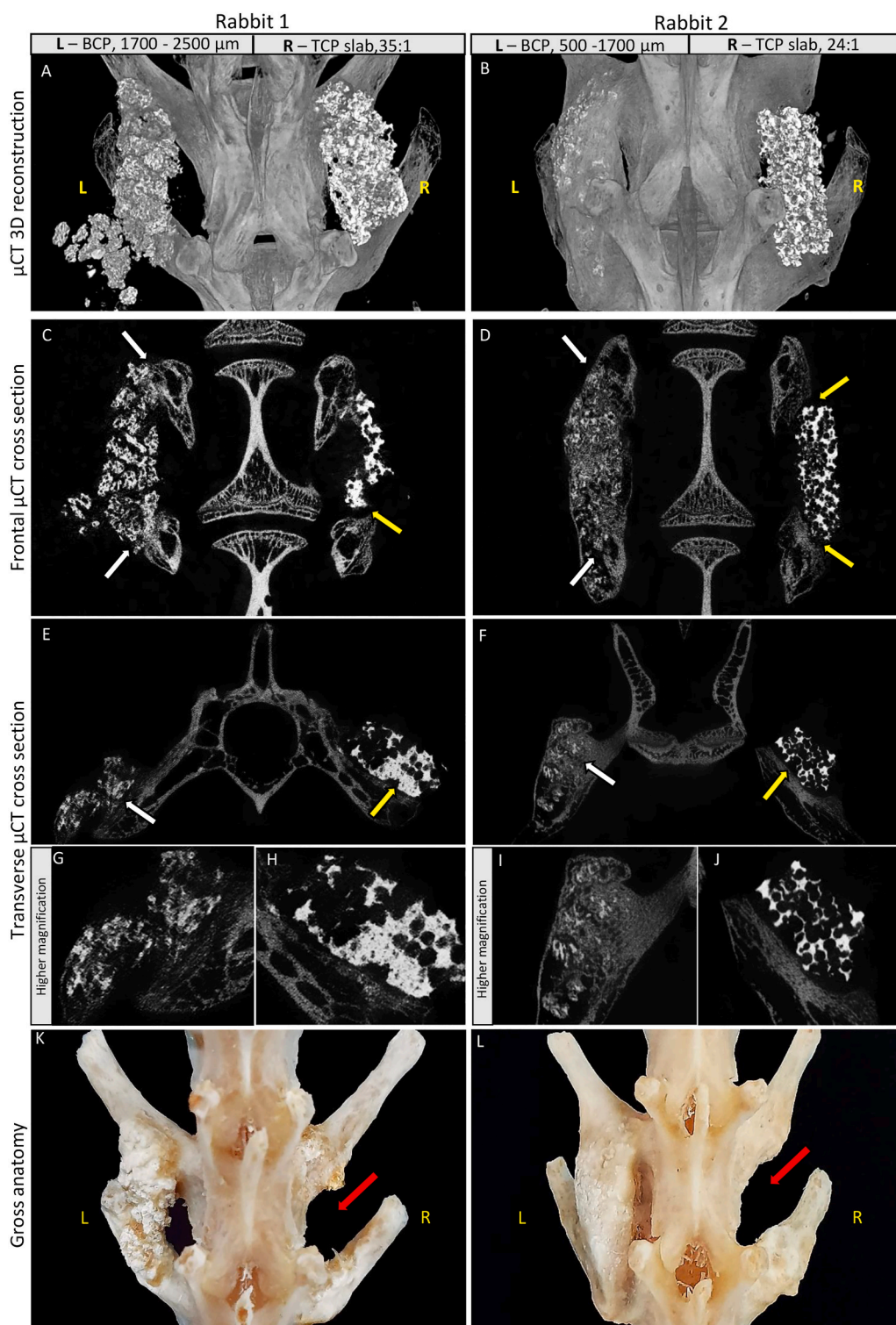


Fig. 2. The pilot study. The rabbit spinal fusion (L5-L6) was conducted with ABGS containing various types of CRM - different size ceramics particles (BCP) and slabs (TCP) with different porosity: Rabbit 1 (L = BCP, 1700–2500 μm , R = TCP slab, porosity - 35:1); Rabbit 2 (L = BCP, 500–1700 μm , R = TCP slab, porosity - 24:1). (A, B) μCT 3D reconstruction indicated a successful fusion on the left sides, while on the right sides the fusion of ceramic slabs failed. (C, D) Frontal μCT cross sections showing successful (white arrow) and failed (yellow arrow) integration of new bone with transverse processes. (E, F) Transverse μCT cross sections presenting successful (white arrow) and failed (yellow arrow) integration. (G, H, I, J) Successful and failed integration at higher magnification on transverse μCT cross sections. (K, L) Gross anatomy of the same specimen. During the maceration, ceramics slabs on the right side detached (red arrows) from the transverse processes since they were not integrated. L – left side; R – right side. (For interpretation of the references to colour in this figure legend, the reader is referred to the web version of this article.)

the bone area and the area of CRM particles were selected manually and masked with the distinctive colour (black) in Photoshop software (Adobe Systems, San Jose, CA) in order to be recognised by the measuring software. Masked areas (bone, CRM, whole area) were converted to RGB stacks that were further thresholded and measured in Fiji ImageJ software (version 1.51r; NIH, Maryland, USA). Bone marrow area was calculated as remaining pixels – bone area and CRM area were subtracted from the whole area. Results were expressed as the area percentage. The histomorphometric analysis was done on 2 histology slides per group; for every slide 4–6 images were taken and measured.

2.8. Data analysis

Data distribution were analysed with Kolmogorov-Smirnov test and differences between groups were processed with Kruskal-Wallis test (all groups together) followed with post-hoc Mann-Whitney U test (comparison between the two groups). The data have been shown in Box and Whisker's plots, and P value below 0.05 was considered significant. Statistical software IBM SPSS Statistics, version 25.0 have been used in all statistical procedures.

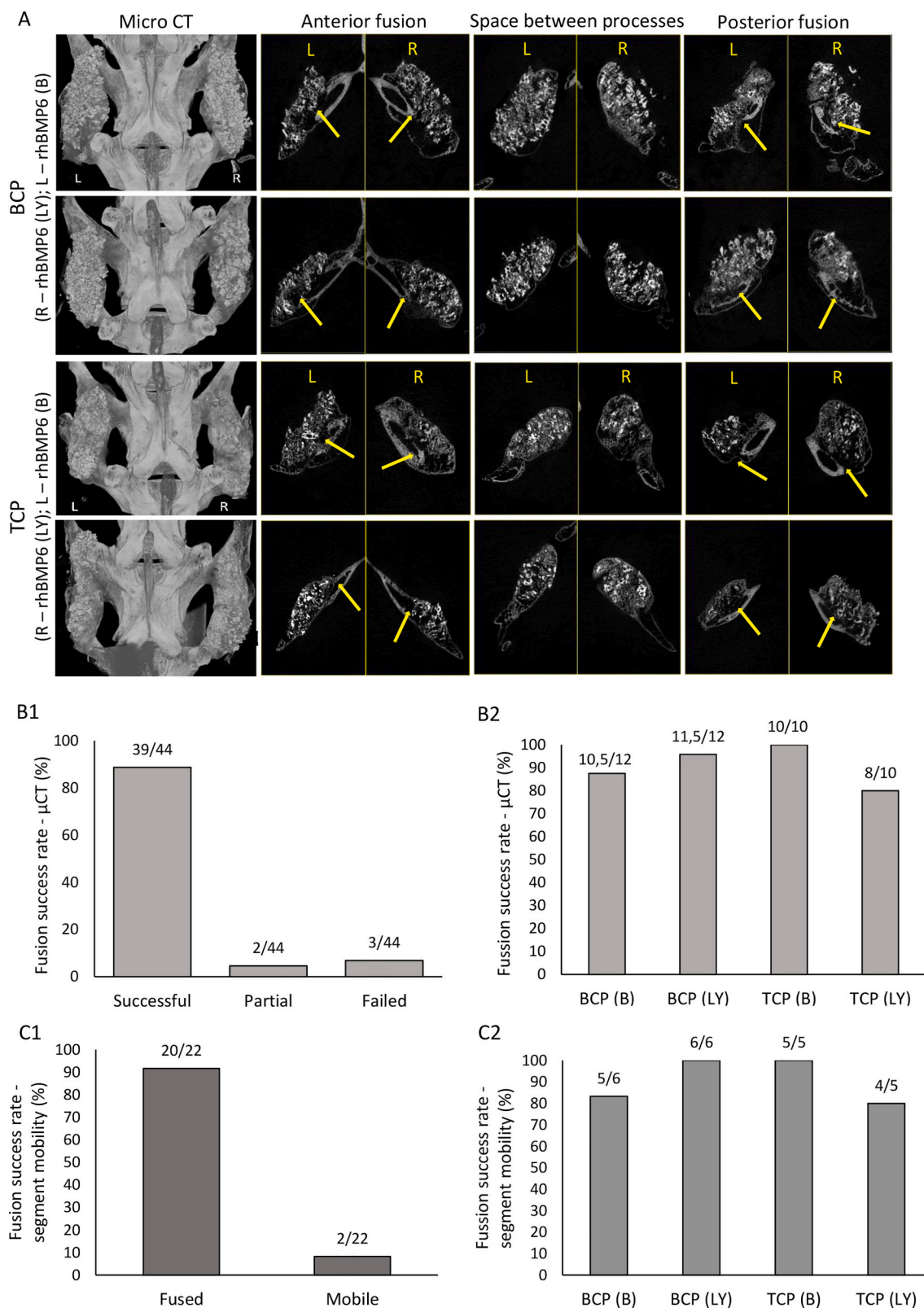


Fig. 3. (A) μ CT 3D reconstruction of PLF in rabbits showed successful integration with the transverse processes. μ CT cross sections through anterior transverse process, space between transverse processes and posterior transverse process of rabbits. L = left side (rhBMP6 applied directly in autologous blood); R = right side (rhBMP6 lyophilized on ceramics particles); yellow arrows point at fusion site between newly formed bone and the transverse process. (B1) Total fusion success rate (%) determined on μ CT cross sections through the anterior and posterior transverse processes (successful, partial and failed fusion). (B2) Fusion success rate (%) among experimental groups determined on μ CT cross sections through the anterior and posterior transverse processes. Number of specimens was 5–6 per group (for each specimen fusion with anterior and posterior transverse processes was evaluated). (C1) Total fusion success rate (%) determined by the segmental mobility testing (fused and mobile). (C2) Fusion success rate (%) among experimental groups determined by the segmental mobility testing. Number of specimens was 5–6 per group. B – rhBMP6 applied directly in autologous blood; LY - rhBMP6 lyophilized on ceramics particles.

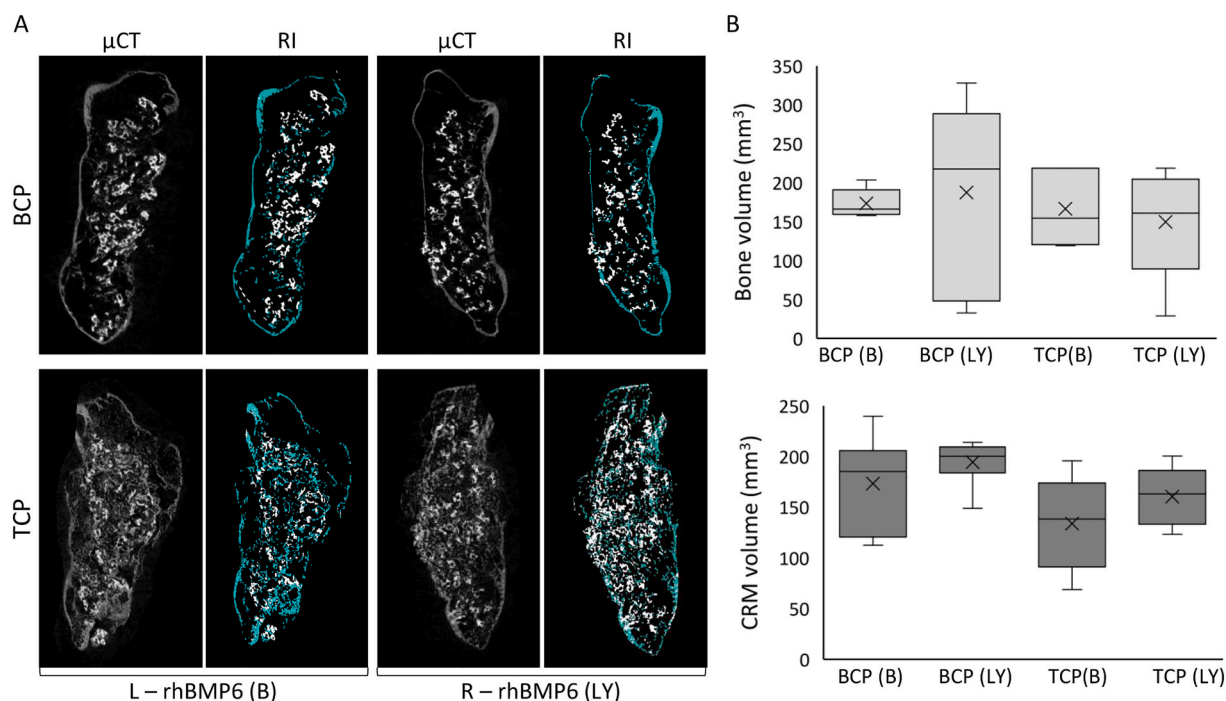


Fig. 4. μ CT analyses of PLF in rabbits. (A) μ CT sagittal cross sections and reconstructed μ CT images (RI) showing separation of the new bone and CRM. (B) Bone volume and CRM volume (mm^3) among experimental groups on day 50. Results are shown as median with interquartile range (IQR). Non-parametric Kruskal Wallis test was used with post hoc Mann Whitney U - test. B - rhBMP6 applied directly in autologous blood; LY - rhBMP6 lyophilized on ceramics particles. L - left side; R - right side.

3. Results

3.1. Selection of ceramics particle size

In the pilot experiment, rhBMP6 induced bone in all tested formulations containing ABC and synthetic ceramics. However, the degree of osseointegration of the newly formed bone with the transverse processes was different (Fig. 2A-L). In the implant with BCP 500–1700 μm particles the osseointegration was complete (white arrow at Fig. 2D, F, I), in the implant containing BCP 1700–2500 μm particles it was moderate (white arrow at Fig. 2C, E, G), while in implants containing TCP slabs the osseointegration did not occur (yellow arrows at Fig. 2C-F, H, J and red arrows at Fig. 2K and L). Moreover, the volume of newly formed bone was highest when 500–1700 μm particles were used. Therefore, we further used particles of 500–1700 μm size and tested two different chemical compositions of specific ceramic particles including TCP and BCP as well as two methods of rhBMP6 application. The results below refer to the second experiment.

3.2. Spinal fusion success rate and segmental mobility testing

The success of spinal fusion was analysed by μ CT of the anterior and posterior transverse processes in conjunction with the newly formed ectopic bone connecting them into a new columnar ectopic bone structure (Fig. 3A). The success rate of the spinal fusion observed by μ CT analyses was in total 90,9% (39 successful, 3 failed and 2 partially fused) (Fig. 3B1) while success rate among experimental groups varied between 80% and 100% (Fig. 3B2). The segmental mobility was tested by individual segment palpation. Spinal fusion/segment immobility was found in 90,9% cases (80–100% among experimental groups, Fig. 3C1 and C2) confirming the successful fusion rate as determined by μ CT analyses.

3.3. μ CT analyses of newly formed bone

The new bone was quantitatively separated from the CRM (Fig. 4A) and then the bone volume (Fig. 4B), unresorbed CRM volume (Fig. 4B)

and trabecular parameters (data not shown) were calculated. The new bone volume was robust in all treated animals. The highest average amount of bone formed was observed in implants containing rhBMP6 lyophilized on the BCP, while less bone formed in implants containing rhBMP6 lyophilized on TCP ceramics. However, the differences in the bone volume, CRM volume, and trabecular parameters (data not shown) among the experimental animals were not significant neither regarding the ceramics type (BCP vs TCP) nor the rhBMP6 delivered directly in blood or priorly lyophilized on the ceramic particles (Fig. 4).

3.4. Biomechanical testing

Biomechanical properties of fusion mass containing newly formed bone and transverse processes are shown in Fig. 5. Results are presented for each group separately (Fig. 5A) and by grouping samples according to the success rate of the spinal fusion (successful/failed fusion; Fig. 5B). Force needed to break the new bone forming a successful fusion was significantly higher compared to adjacent transverse processes used as control samples and specimens with failed fusion. On the other hand, elasticity of the successfully fused implants and of transverse processes was significantly lower than in specimens with a failed fusion. Work needed to break the newly formed bone in successfully fused samples was significantly higher when compared to the transverse processes (Fig. 5).

3.5. Histology

Formation and osseointegration of new bone was analysed on frontal sections of undecalcified samples stained by Goldner and Von Kossa (Fig. 6 and 7). New bone was present around and between the ceramic particles. The fusion and complete osseointegration of new bone with the adjacent transverse processes was shown in histological sections (Fig. 7A1 and 7A2) and in the μ CT analyses (see Fig. 2I and Fig. 3A). However, there were still small areas of implants in which endochondral ossification was still continued (Fig. 7 A3). On histological sections there was no difference regarding the resorption rate between BCP and TCP particles. Importantly, ceramic particles were

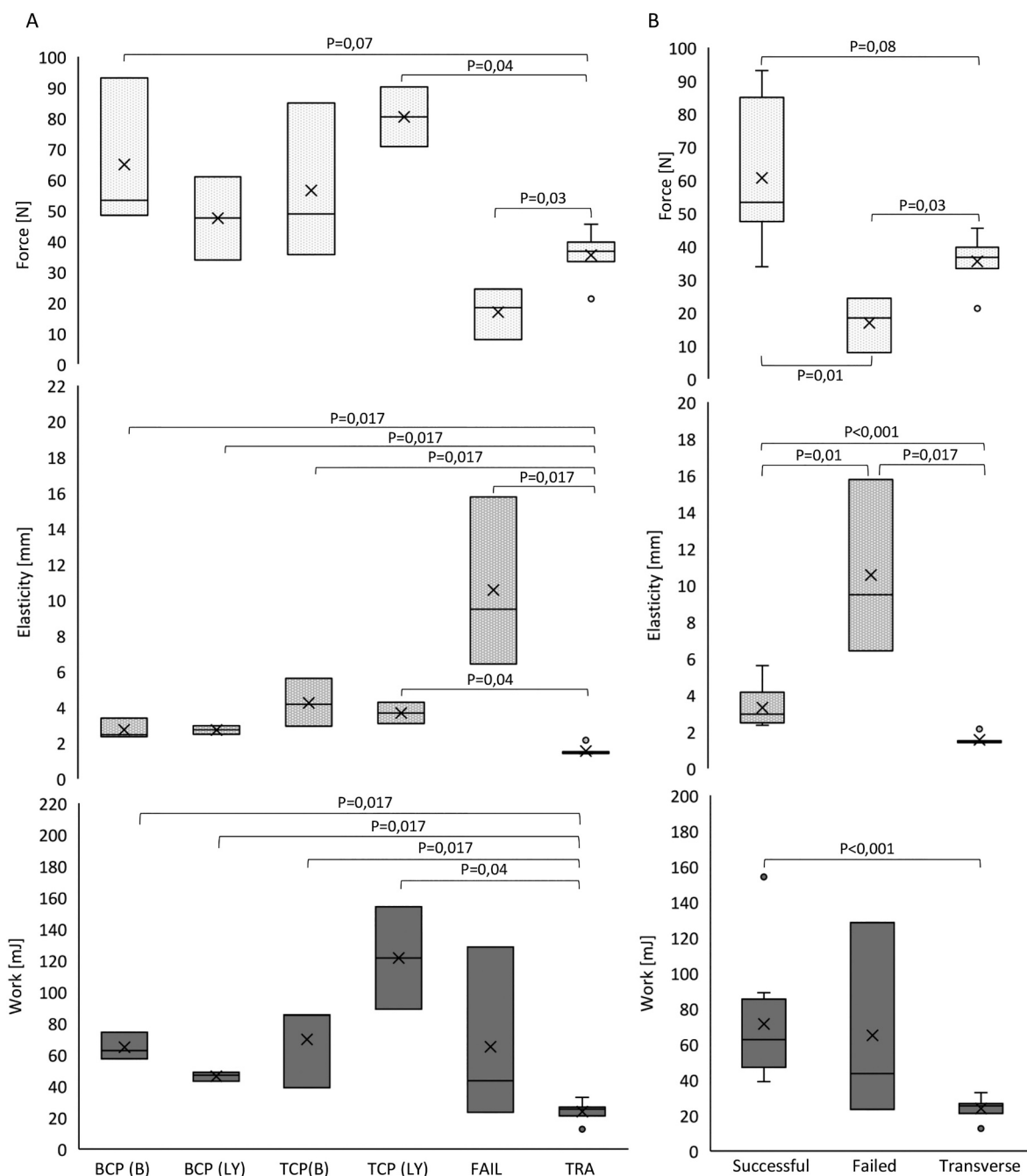


Fig. 5. Three-point bending test of newly formed bone and adjacent transverse processes. Test was performed using Texture Analyser TA.HDPlus (Stable Micro Systems, Surrey, UK). (A) Force (N), elasticity (mm) and work (mJ) were measured on samples belonging to groups: BCP (B), BCP (LY), TCP (B), TCP (LY); FAIL - failed fusion, TRA - transverse processes. B - rhBMP6 applied directly in autologous blood; LY - rhBMP6 lyophilized on ceramics particles. Number of samples was 3 per group. (B) Force (N), elasticity (mm) and work (mJ) measured on samples grouped based on the fusion success (successful/failed fusion) and isolated transverse processes. All results are shown as median with interquartile range (IQR). Non-parametric Kruskal Wallis H - test was used with post hoc Mann Whitney U - test.

integrated as well into the transverse processes supporting a uniform distribution of bone and biomechanical properties of the new bone-ceramic structure (Fig. 6).

3.6. Histomorphometry

Next we measured the proportion of new ectopic bone, CRM and bone marrow on histological sections from different parts of fusion mass (Fig. 7B). The proportion of observed components was similar in all experimental groups; with the bone marrow as a predominant component in more than half of the analysed area followed by the areas containing bone and CRM (Fig. 7C).

4. Discussion

In the present study, we showed that ABGS (rhBMP6/ABC) fabricated with a synthetic ceramic (TCP or BCP) as a compression resistant matrix (CRM) was capable of inducing new bone formation and to promote spinal fusion in a rabbit PLF model. The newly formed bone underwent a physiological bone remodeling establishing osteointegration with the trabeculae of native transverse processes containing bone marrow elements. The newly formed bone induced by ABGS at ectopic site is populated with the lining osteoblasts that lay down osteoid, osteocytes that are trapped within the mineralizing bone and osteoclasts at the resorptive lacunae. The bone marrow elements generated in the ectopic

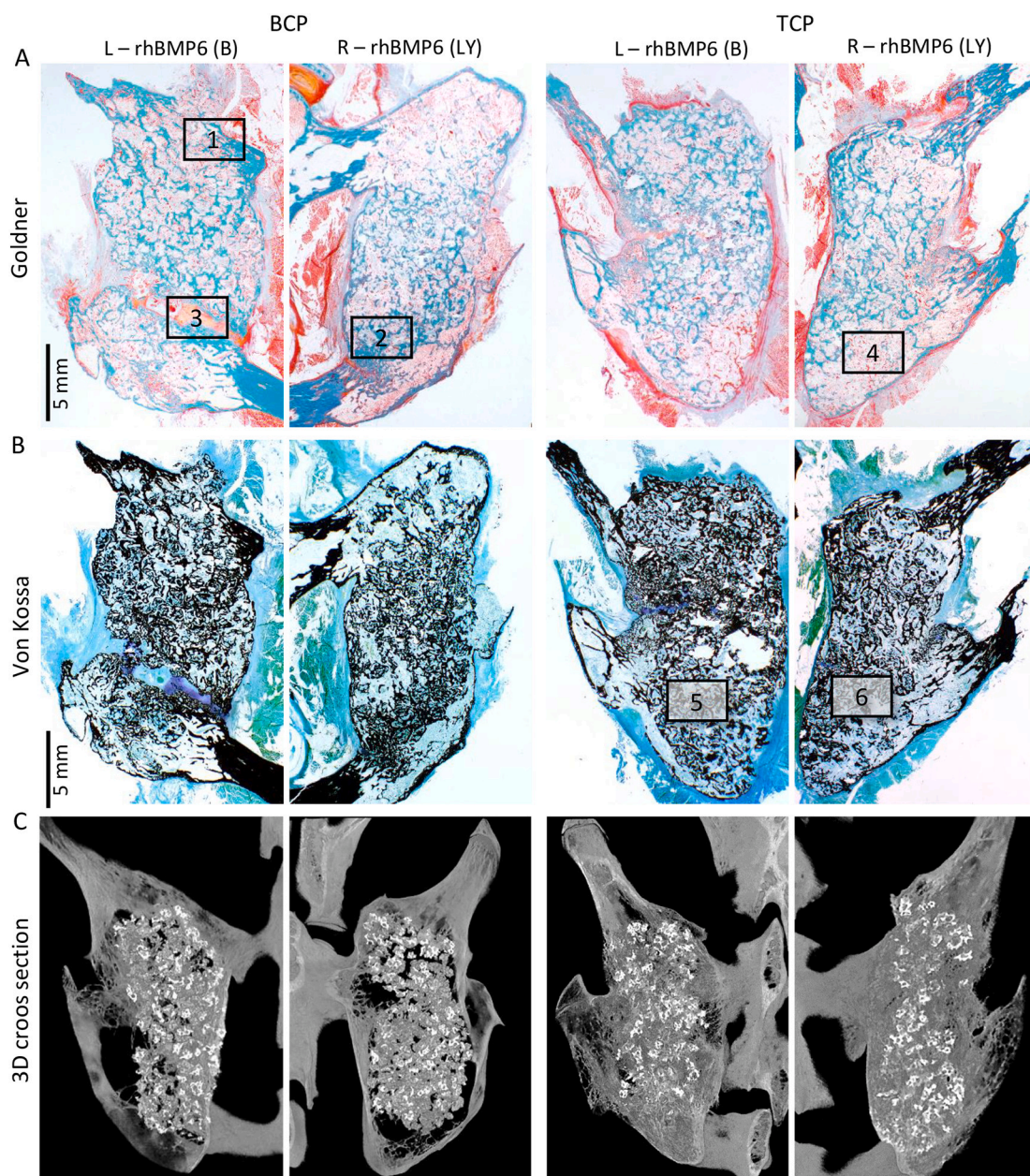


Fig. 6. (A, B) Histology sections stained by Goldner and Von Kossa staining, respectively of BCP and TCP ceramics. On the left (L) side rhBMP6 was added in blood (B), while on the right side (R) rhBMP6 was lyophilized (LY). (C) 3D cross sections of new ectopic bone fused with adjacent transverse processes among different experimental groups. Squares marked from 1 to 6 are enlarged and presented in Fig. 7A (1–6). Scale bars are indicated in the left corner of the histology images.

bone were shown to follow normal hematopoiesis in the colony forming assays [29]. The salient features of this finding is that TCP or BCP could be used as a CRM substitute for devitalized allograft with ABGS. Autologous blood coagulum (ABC) renders protection against inflammation and minimizes the foreign-body response elicited by high mineral containing ceramics in particles of 500–1700 μm size when placed in the gutter bilaterally between two transverse processes. To our surprise, we found that a specific particle size of ceramics is of critical importance to induce new bone uniformly within the implant and to promote the osseointegration. Both TCP and BCP yielded a complete fusion as there was no difference in the quality and quantity of bone formed. Moreover, we demonstrated for the first time that ABGS could be fabricated by adding rhBMP6 in the blood prior to coagulation or lyophilizing it onto ceramics then adding blood to make the coagulum.

Like allograft, synthetic ceramics as a CRM in ABGS provides a better handling properties but avoids the disadvantages that allograft possesses including the potential for transmission of infectious diseases and rejection

due to its immunogenicity [4,5]. Moreover, we previously found that ceramics underwent creeping substitution orderly in time than allograft which was rapidly replaced in a short period of time resulting eventually in biomechanical dysfunction [15]. Synthetic ceramics composites could also be engineered if needed to offer a better biomechanical stability. TCP is a more biodegradable and soluble ceramics, while HA provides a more stable phase, therefore TCP/HA in 80:20 or 60:40 ratio could be used in conjunction with a BMP to promote a long term sustainability and provide compressive resistance as required for certain spine fusion indications. We examined the effects of rhBMP6 with one dose (50 μg/mL of ABC), chosen based on our previous ABGS dose ranging studies with or without allograft [15]. The success rate in the tested dose in combination with ceramics and ABC was above 90%. In our previous studies when rhBMP6 was used in the combination with ABC without CRM or with allograft as CRM, the optimal rhBMP6 dose was around 250 μg (100 μg/mL of ABC), while the dose of 125 μg (50 μg/mL of ABC) was only moderately successful (fusion in two out of four rabbits) [15]. This suggested that the use of ceramics as CRM

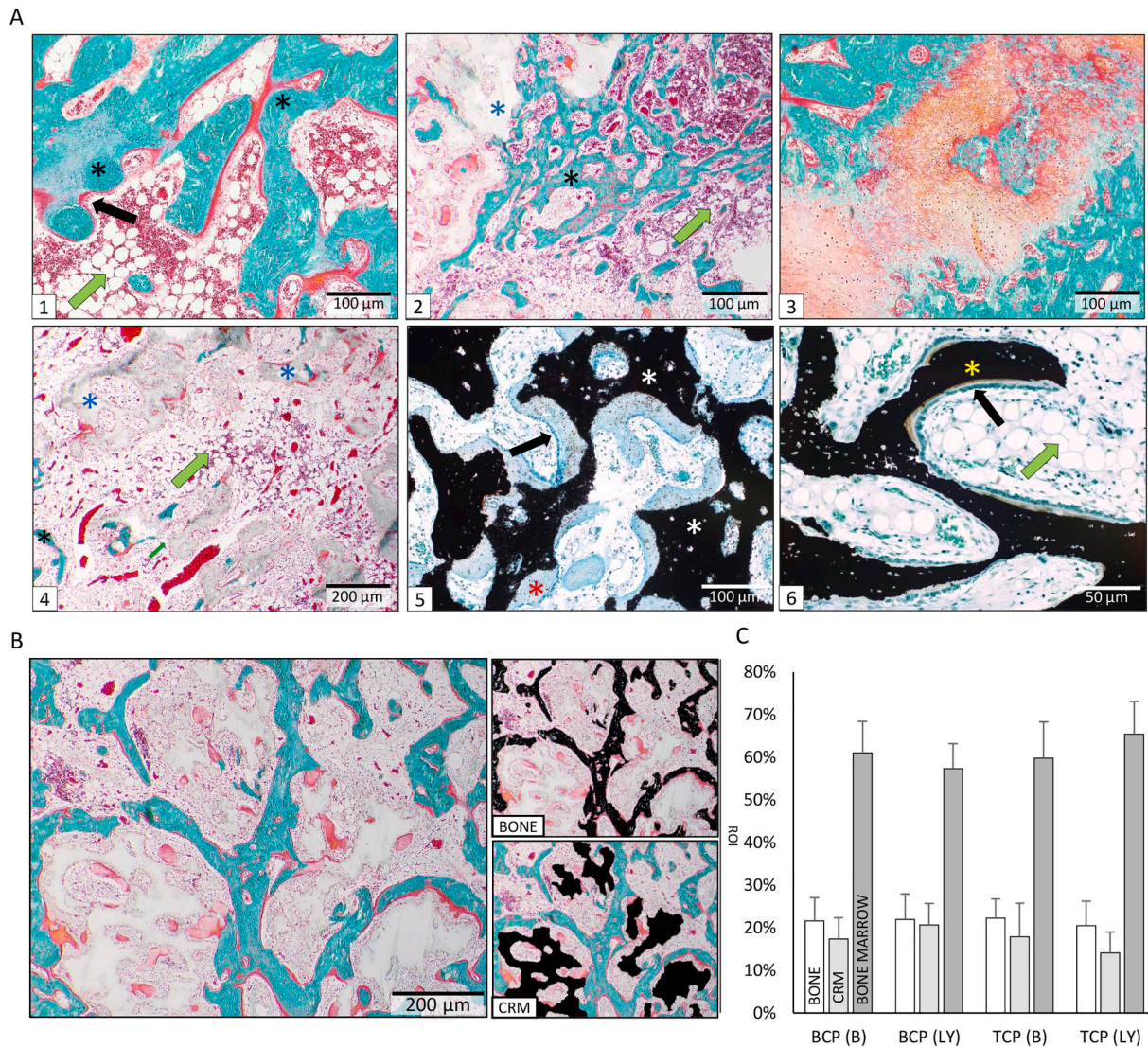


Fig. 7. (A) 1, 2 – area of histology section (Goldner) showing successful osseointegration of newly formed bone and transverse processes. Black asterisk indicates a bone, while blue asterisk indicates CRM. Black arrow indicates osteoblasts, while green arrow indicates bone marrow. 3 – area of histology section (Goldner) showing ongoing endochondral ossification. 4 – area of histology section containing bone marrow and CRM. 5, 6 – histology sections (Von Kossa) showing mineralized (yellow asterisk), non-mineralized bone (red asterisk) and CRM (white asterisk). (B) Static histomorphometry analysis done on the histology sections stained by Goldner, where bone was turquoise while CRM was white. Regions of interest (bone, CRM) were masked with distinctive colour (black) which were further thresholded and measured. (C) Graphs are showing region of interest (%) - bone, CRM and bone marrow on histology sections among experimental groups. The histomorphometric analysis was done on two histology slides per group; for every slide 4–6 images were taken and measured. Results are shown as mean \pm SD. Scale bars in lower right corner indicate different magnifications. (For interpretation of the references to colour in this figure legend, the reader is referred to the web version of this article.)

shifted the rhBMP6 amount required to achieve the successful fusion to the lower range when compared to our previous study with the allograft as CRM [15].

We have previously described that ABC serves as a physiological native BMP carrier [15,22,26] and provided a tight binding for rhBMP6 with plasma proteins within the fibrin meshwork, allowing a sustained release of rhBMP6 and suppressed inflammation when implanted with CRM to improve the handling properties. ABC with low dose of rhBMP6 masks T-cell recognition and reduces the formation of multi-nucleated giant cells when in conjunction with ceramics.

In addition to chemical properties, the physical attributes of ceramics like surface area, pore volume and particle size are known to play a significant role as a carrier for BMP in bone induction [21,30]. In the present study, we observed for the first time that the geometry of ceramics plays a critical role in achieving a complete fusion and promoting osseointegration between the transverse processes and new bone when implanted with ABGS. Calcium phosphate ceramics are

engineered into preformed granules or blocks [24] in order to provide osteoconductivity for bone in-growth on to its surface or down into pores, channels or pipes [31]. Interconnected pores within the ceramics allow vascularization, cell migration and nutrient diffusion required for sustained cell viability and tissue function [32]. We discovered that the most critical property for ceramics in the ABGS fabrication is the particle size and subsequently the surface area. RhBMP6 is bound tightly within fibrin mesh work and plasma proteins when added directly to ABC or upon release from the lyophilized rhBMP6-ceramics composite. Examination of BCP ceramic of two different particle sizes (BCP 500–1700 μ m and 1700–2500 μ m) and TCP ceramic in two different slabs (high and low porous) as CRM in ABGS (rhBMP6/ABC) suggested that although bone formed in all implants, successful fusion with adjacent transverse processes was observed only in implants containing properly selected ceramic particles. Namely, the volume of newly formed bone was higher and the osseointegration was profound only in implants containing the ceramics of 500–1700 μ m particle size.

Although rabbit PLF model is a useful preclinical model to rapidly evaluate the potential use of new ABGS formulations for achieving PLF, it remains to be extrapolated in larger animals including non-human primates and confirmed in clinical studies. It has been previously suggested that BMP delivered in animal (bovine) derived collagen carrier in phylogenetically higher order animals have a diminished potential for bone regeneration and might therefore require increased amount of BMPs [16,33]. Moreover, there are also significant differences in the spine anatomy between rabbit and higher order species including humans. For example, in humans the distance between the transverse processes is twofold larger and the transverse processes are placed more horizontally than in rabbits. However, as ABGS formulations contain ABC we found the dose required for rhBMP6 per mL ABC comparable and extrapolated from small to large animals [27] and in human clinical trials (EudraCT number 2017-000860-14). A limitation of this study was the assessment of the spinal fusion success rate at only one time point. Previously, it has been shown that the bone formation in the rabbit PLF model reaches the peak between 12 and 24 weeks after surgery [4]. However, it is widely accepted that the spinal fusion outcome in the rabbit PLF model might be evaluated as well 6 weeks after surgery [3,9,12,13,18,19,34].

In the currently ongoing human clinical trial (EudraCT number 2017-000860-14), ABGS containing rhBMP6 added to blood and mixed with allograft is evaluated as a therapeutic solution for the treatment of degenerative disc disease. Findings of this study indicate that in the future clinical application allograft might be replaced by ceramics to overcome the disadvantages associated with allograft while rhBMP6 might be prelyophilized on CRM which would reduce the number of steps in ABGS preparation.

5. Conclusions

We demonstrated the efficacy of a novel ABGS containing rhBMP6, ABC and ceramic particles in the PLF rabbit model. Successful spinal fusion of above 90% achieved by induction of new bone and its integration with adjacent transverse processes was confirmed by X-rays, μ CT analyses, histology and by palpatory segmental mobility testing. Moreover, the successful osseointegration of newly formed bone with the transverse processes was confirmed by biomechanical testing. Therefore, tested ABGS containing synthetic ceramic formulations achieved a successful PLF in rabbits and offer a better solution as a replacement to allograft for a safe and efficient spinal fusion to warrant further testing in the clinic.

CRedit authorship contribution statement

Nikola Štoković: Conceptualization, Methodology, Validation, Investigation, Data curation, Writing - original draft, Writing - review & editing, Visualization, Project administration. **Natalia Ivanjko:** Conceptualization, Methodology, Validation, Investigation, Data curation, Writing - original draft, Writing - review & editing, Visualization. **Marko Pećin:** Methodology, Investigation, Writing - review & editing. **Igor Erjavec:** Methodology, Validation, Data curation, Writing - review & editing, Visualization. **Sven Karlović:** Investigation, Writing - review & editing. **Ana Smajlović:** Investigation, Writing - review & editing. **Hrvoje Capak:** Investigation, Data curation, Writing - review & editing. **Milan Milošević:** Formal analysis, Writing - review & editing, Visualization. **Jadranka Bubić Špoljar:** Investigation, Writing - review & editing, Project administration. **Dražen Vnuuk:** Methodology, Validation, Resources, Writing - review & editing, Supervision, Project administration. **Dražen Matičić:** Methodology, Validation, Resources, Writing - review & editing, Supervision, Project administration. **Hermann Oppermann:** Conceptualization, Validation, Resources, Writing - review & editing, Supervision. **T. Kuber Sampath:** Conceptualization, Writing - review & editing, Supervision. **Slobodan Vukićević:** Conceptualization, Methodology, Validation, Investigation, Resources, Data curation, Writing -

original draft, Writing - review & editing, Supervision, Visualization, Project administration, Funding acquisition.

Acknowledgements

This programme was funded by the FP7 Health Program (FP7/2007-2013) under grant agreement HEALTH-F4-2011-279239 (Osteogrow), H2020 Health GA 779340 (OSTEOproSPINE), and European Regional Development Fund - Scientific Center of Excellence for Reproductive and Regenerative Medicine (project "Reproductive and regenerative medicine - exploration of new platforms and potentials," GA KK01.1.1.01.0008 funded by the EU through the ERDF). For animal studies, we thank Mirjana Marija Renic and Djurdjica Car for their excellent technical assistance.

References

- [1] J.M. Toth, M. Wang, J. Lawson, J.M. Badura, K.B. DuBose, Radiographic, biomechanical, and histological evaluation of rhBMP-2 in a 3-level intertransverse process spine fusion: an ovine study, *J Neurosurg Spine* 25 (6) (2016) 733–739.
- [2] J.R. Dimar, S.D. Glassman, K.J. Burkus, L.Y. Carreon, Clinical outcomes and fusion success at 2 years of single-level instrumented posterolateral fusions with recombinant human bone morphogenetic protein-2/compression resistant matrix versus iliac crest bone graft, *Spine (Phila Pa 1976)* 31 (22) (2006) 2534–2539 (discussion 2540).
- [3] J.H. Lee, C.H. Yu, J.J. Yang, H.R. Baek, K.M. Lee, T.Y. Koo, B.S. Chang, C.K. Lee, Comparative study of fusion rate induced by different dosages of *Escherichia coli*-derived recombinant human bone morphogenetic protein-2 using hydroxyapatite carrier, *Spine J.* 12 (3) (2012) 239–248.
- [4] H. Itoh, S. Ebara, M. Kamimura, Y. Tateiwa, T. Kinoshita, Y. Yuzawa, K. Takaoka, Experimental spinal fusion with use of recombinant human bone morphogenetic protein 2, *Spine (Phila Pa 1976)* 24 (14) (1999) 1402–1405.
- [5] T.M. Chu, S.J. Warden, C.H. Turner, R.L. Stewart, Segmental bone regeneration using a load-bearing biodegradable carrier of bone morphogenetic protein-2, *Biomaterials* 28 (3) (2007) 459–467.
- [6] M.F. Hoffmann, C.B. Jones, D.L. Sietsema, Recombinant human bone morphogenetic Protein-2 in posterolateral spinal fusion: what's the right dose? *Asian Spine J* 10 (3) (2016) 457–464.
- [7] S.H. Lee, H. Shin, Matrices and scaffolds for delivery of bioactive molecules in bone and cartilage tissue engineering, *Adv. Drug Deliv. Rev.* 59 (4–5) (2007) 339–359.
- [8] T. Akamaru, D. Suh, S.D. Boden, H.S. Kim, A. Minamide, J. Louis-Ugbo, Simple carrier modifications can enhance delivery of recombinant human bone morphogenetic protein-2 for posterolateral spine fusion, *Spine (Phila Pa 1976)* 28 (5) (2003) 429–434.
- [9] T. Namikawa, H. Terai, E. Suzuki, M. Hoshino, H. Toyoda, H. Nakamura, S. Miyamoto, N. Takahashi, T. Ninomiya, K. Takaoka, Experimental spinal fusion with recombinant human bone morphogenetic protein-2 delivered by a synthetic polymer and beta-tricalcium phosphate in a rabbit model, *Spine (Phila Pa 1976)* 30 (15) (2005) 1717–1722.
- [10] S.D. Glassman, J.R. Dimar, L.Y. Carreon, M.J. Campbell, R.M. Puno, J.R. Johnson, Initial fusion rates with recombinant human bone morphogenetic protein-2/compression resistant matrix and a hydroxyapatite and tricalcium phosphate/collagen carrier in posterolateral spinal fusion, *Spine (Phila Pa 1976)* 30 (15) (2005) 1694–1698.
- [11] M.H. Pelletier, R.A. Oliver, C. Christou, Y. Yu, N. Bertollo, H. Irie, W.R. Walsh, Lumbar spinal fusion with beta-TCP granules and variable *Escherichia coli*-derived rhBMP-2 dose, *Spine J.* 14 (8) (2014) 1758–1768.
- [12] J. Louis-Ugbo, H.S. Kim, S.D. Boden, M.T. Mayr, R.C. Li, H. Seeherman, D. D'Augusta, C. Blake, A. Jiao, S. Peckham, Retention of 125I-labeled recombinant human bone morphogenetic protein-2 by biphasic calcium phosphate or a composite sponge in a rabbit posterolateral spine arthrodesis model, *J. Orthop. Res.* 20 (5) (2002) 1050–1059.
- [13] D.Y. Suh, S.D. Boden, J. Louis-Ugbo, M. Mayr, H. Murakami, H.S. Kim, A. Minamide, W.C. Hutton, Delivery of recombinant human bone morphogenetic protein-2 using a compression-resistant matrix in posterolateral spine fusion in the rabbit and in the non-human primate, *Spine (Phila Pa 1976)* 27 (4) (2002) 353–360.
- [14] S. Dohzono, Y. Imai, H. Nakamura, S. Wakitani, K. Takaoka, Successful spinal fusion by *E. coli*-derived BMP-2-adsorbed porous beta-TCP granules: a pilot study, *Clin Orthop Relat Res* 467 (12) (2009) 3206–3212.
- [15] S. Vukicevic, L. Grgurevic, I. Erjavec, M. Pecin, T. Bordukalo-Niksic, N. Stokovic, M. Lipar, H. Capak, D. Maticic, R. Windhager, T.K. Sampath, M. Gupta, Autologous blood coagulum is a physiological carrier for BMP6 to induce new bone formation and promote posterolateral lumbar spine fusion in rabbits, *J. Tissue Eng. Regen. Med.* 14 (1) (2020) 147–159.
- [16] S.D. Boden, J.H. Schimandle, W.C. Hutton, Volvo Award in basic sciences. The use of an osteoinductive growth factor for lumbar spinal fusion. Part II: Study of dose, carrier, and species, *Spine (Phila Pa 1976)* 20 (24) (1995) 2633–2644.
- [17] L.G. Jennis, D. Wheeler, S.J. Parazin, R.J. Connolly, The effect of osteogenic protein-1 in instrumented and noninstrumented posterolateral fusion in rabbits, *Spine J.* 2 (3) (2002) 173–178.

- [18] S. Konishi, H. Nakamura, M. Seki, R. Nagayama, Y. Yamano, Hydroxyapatite granule graft combined with recombinant human bone morphogenetic protein-2 for solid lumbar fusion, *J. Spinal Disord. Tech.* 15 (3) (2002) 237–244.
- [19] A. Minamide, M. Kawakami, H. Hashizume, R. Sakata, M. Yoshida, T. Tamaki, Experimental study of carriers of bone morphogenetic protein used for spinal fusion, *J. Orthop. Sci.* 9 (2) (2004) 142–151.
- [20] J.W. Lee, S. Lee, S.H. Lee, H.S. Yang, G.I. Im, C.S. Kim, J.H. Park, B.S. Kim, Improved spinal fusion efficacy by long-term delivery of bone morphogenetic protein-2 in a rabbit model, *Acta Orthop.* 82 (6) (2011) 756–760.
- [21] M.I. Alam, I. Asahina, K. Ohmamiuda, K. Takahashi, S. Yokota, S. Enomoto, Evaluation of ceramics composed of different hydroxyapatite to tricalcium phosphate ratios as carriers for rhBMP-2, *Biomaterials* 22 (12) (2001) 1643–1651.
- [22] L. Grgurevic, H. Oppermann, M. Pecin, I. Erjavec, H. Capak, M. Pauk, S. Karlovic, V. Kufner, M. Lipar, J. Bubic Spoljar, T. Bordukalo-Niksic, D. Maticic, M. Peric, R. Windhager, T.K. Sampath, S. Vukicevic, Recombinant human bone morphogenetic protein 6 delivered within autologous blood coagulum restores critical size segmental defects of ulna in rabbits, *JBMR Plus* 3 (5) (2019) e10085.
- [23] U.W. Jung, S.Y. Choi, E.K. Pang, C.S. Kim, S.H. Choi, K.S. Cho, The effect of varying the particle size of beta tricalcium phosphate carrier of recombinant human bone morphogenetic protein-4 on bone formation in rat calvarial defects, *J. Periodontol.* 77 (5) (2006) 765–772.
- [24] H. Seeherman, J.M. Wozney, Delivery of bone morphogenetic proteins for orthopedic tissue regeneration, *Cytokine Growth Factor Rev.* 16 (3) (2005) 329–345.
- [25] I. El Bialy, W. Jiskoot, M. Reza Nejadnik, Formulation, delivery and stability of bone morphogenetic proteins for effective bone regeneration, *Pharm Res* 34 (6) (2017) 1152–1170.
- [26] S. Vukicevic, H. Oppermann, D. Verbanac, M. Jankolija, I. Popcek, J. Curak, J. Brkljacic, M. Pauk, I. Erjavec, I. Francetic, I. Dumic-Cule, M. Jelic, D. Durdevic, T. Vlahovic, R. Novak, V. Kufner, T. Bordukalo Niksic, M. Kozlovic, Z. Banic Tomisic, J. Bubic-Spoljar, I. Bastalic, S. Vikić-Topic, M. Peric, M. Pecina, L. Grgurevic, The clinical use of bone morphogenetic proteins revisited: a novel biocompatible carrier device OSTEOGROW for bone healing, *Int. Orthop.* 38 (3) (2014) 635–647.
- [27] L. Grgurevic, I. Erjavec, M. Gupta, M. Pecin, T. Bordukalo-Niksic, N. Stokovic, D. Vnuk, V. Farkas, H. Capak, M. Milosevic, J.B. Spoljar, M. Peric, M. Vuckovic, D. Maticic, R. Windhager, H. Oppermann, T.K. Sampath, S. Vukicevic, Autologous blood coagulum containing rhBMP6 induces new bone formation to promote anterior lumbar interbody fusion (ALIF) and posterolateral lumbar fusion (PLF) of spine in sheep, *Bone* 115448 (2020), <https://doi.org/10.1016/j.bone.2020.115448>.
- [28] E.C. Walker, K. Truong, N.E. McGregor, I.J. Poulton, T. Isojima, J.H. Gooi, T.J. Martin, N.A. Sims, Cortical Bone Maturation in Mice Requires SOCS3 Suppression of gp130/STAT3 Signalling in Osteocytes, *Elife* 9, (2020).
- [29] K.F. McCarthy, S. Wientroub, M. Hale, A.H. Reddi, Establishment of the hematopoietic microenvironment in the marrow of matrix-induced endochondral bone, *Exp. Hematol.* 12 (2) (1984) 131–138.
- [30] E. Tsuruga, H. Takita, H. Itoh, Y. Wakisaka, Y. Kuboki, Pore size of porous hydroxyapatite as the cell-substratum controls BMP-induced osteogenesis, *J. Biochem.* 121 (2) (1997) 317–324.
- [31] T. Albrektsson, C. Johansson, Osteoinduction, osteoconduction and osseointegration, *Eur. Spine J.* 10 (Suppl. 2) (2001) S96–101.
- [32] S.V. Dorozhkin, Bioceramics of calcium orthophosphates, *Biomaterials* 31 (7) (2010) 1465–1485.
- [33] B. McKay, Development of the first commercially available recombinant human bone morphogenetic protein (rhBMP-2) as an autograft replacement for spinal fusion and ongoing R&D direction, in: S. Vukicevic, K.T. Sampath (Eds.), *Bone Morphogenetic Proteins: Regeneration of Bone and Beyond*, Birkhäuser, Basel, 2004, pp. 163–185.
- [34] M. Valdes, D.C. Moore, M. Palumbo, P.R. Lucas, A. Robertson, J. Appel, M.G. Ehrlich, H.S. Keeping, rhBMP-6 stimulated osteoprogenitor cells enhance posterolateral spinal fusion in the New Zealand white rabbit, *Spine J* 7 (3) (2007) 318–325.