

# Childhood onset of Wilson's disease

---

**Kalamar, Vilim**

**Master's thesis / Diplomski rad**

**2014**

*Degree Grantor / Ustanova koja je dodijelila akademski / stručni stupanj:* **University of Zagreb, School of Medicine / Sveučilište u Zagrebu, Medicinski fakultet**

*Permanent link / Trajna poveznica:* <https://um.nsk.hr/um:nbn:hr:105:142560>

*Rights / Prava:* [In copyright](#)

*Download date / Datum preuzimanja:* **2021-12-06**



*Repository / Repozitorij:*

[Dr Med - University of Zagreb School of Medicine  
Digital Repository](#)



**UNIVERSITY OF ZAGREB  
SCHOOL OF MEDICINE**

**Vilim Kalamar**

**Childhood Onset of Wilson's Disease  
A Case Report**

**Graduate Thesis**

**Zagreb, 2014**

This graduate thesis was made at the Department of Pediatrics, University Hospital Center Zagreb, mentored by Prof. Jurica Vuković, and was submitted for evaluation during the academic year 2013/2014.

## ABBREVIATIONS

ALP:	alkaline phosphatase
ALT:	alanine aminotransferase
ANA:	anti-nuclear antibody
ANCA:	anti-nuclear cytoplasmic antibody
APPT:	activated partial thromboplastin time
AST:	aspartate aminotransferase
BID:	<i>bis in die</i> (two times per day)
CMV:	cytomegalovirus
CRP:	C-reactive protein
EBV:	epstein-barr virus
GGT:	gamma-glutamyl transpeptidase
INR:	international normalized ratio
LDH:	lactate dehydrogenase
LKM-1:	liver kidney microsomal type 1 antibody
PT:	prothrombin time
TID:	<i>ter in die</i> (three times per day)

**TABLE OF CONTENTS**

Abstract.....1

Introduction.....2

Case Reports.....4

Discussion.....14

Conclusion.....18

Acknowledgements.....19

References.....20

Biography.....21

## **ABSTRACT**

Wilson's disease is a rare genetic disease that can present very early in life as a clinically non-specific illness with abnormal biochemical tests to life-threatening cirrhosis, liver failure and irreversible neurological deficits. Diagnosis can be challenging if symptoms are minimal. Wilson's disease can range from a relatively mild disease if strict adherence to medications is maintained to a very difficult disease that requires liver transplantation as the only option for a normal life. I have analyzed the cases of three patients. Patient 1 initially presented with hepatic lesions at age sixteen. This was the first step in clinical workup that eventually led to his diagnosis of Wilson's disease. He has had a difficult course and has recently been placed on the liver transplantation list. Patient 2 presented with deranged liver transaminases, decreased serum copper and decreased ceruloplasmin while hospitalized with mononucleosis at the age of 10. Patient 3 is the older sister of patient 2. At age seventeen, she presented with fatigue, leg swelling and absence of menstruation for five months at the time of initial hospitalization.

## INTRODUCTION

Wilson's disease is a rare autosomal recessive genetic disease that results in ineffective metabolism of copper. Copper is an essential trace metal in the human body that acts as a cofactor and permits electron transfer in many endogenous metabolic reactions (4). The liver is the central organ involved in copper metabolism and homeostasis. It has an exceptional capacity for storage and excretion of this metal. Wilson's disease is caused by a mutation in the ATP7B gene on chromosome 13 responsible for coding a copper-transporting p-type ATPase enzyme (7). There are over three hundred mutations of Wilson's ATPase and H1069q is the most common. Not all identified mutations necessarily lead to this metabolic illness, however. The ATPase is responsible for copper transport within the hepatocyte and incorporating copper into ceruloplasmin—the major copper carrying glycoprotein synthesized by the liver. The overwhelming majority of ceruloplasmin is found in the plasma. Mutations to ATP7B causes a decrease in both copper excreted through the biliary system and the quantity of copper bound to ceruloplasmin. The end result is copper accumulation in many different tissues such as the liver, central nervous system, cornea, and kidneys (5). Clinical signs and symptoms are relative to these locations and they include for example: hepatomegaly, acute hepatitis, movement disorders, seizures, depression, Kayser-Fleischer rings (copper deposits in Descemet's membrane of the Cornea), nephrolithiasis, and musculoskeletal abnormalities. If clinical onset occurs in childhood, hepatic dysfunction is the most common presentation (2). In an individual with excess copper in their system, there can be a rapid deterioration in hepatic function following a viral illness or other external factor that has triggered injury. With regards to hepatic dysfunction in a patient with Wilson's disease, the Nazer et al prognostic classification was developed in order to assess the prognosis of a patient with Wilson's disease based on three parameters of liver function: level of serum bilirubin, AST, and INR. The objective is to identify patients who will probably not respond well to therapy and are at an increased risk of dying if liver transplantation is not performed. A score of greater than 7 suggests a risk of death if transplantation is not performed (Table 1) (6,9).

In the general population, Wilson's disease is found in 1/30 000 people and 1/90 000 are carriers (4). *Socio et al* state that it is even more rare—occurring in 1/40 000 people (9). Diagnosis is based on a combination of features such as clinical presentation, biochemical laboratory testing, and mutation analysis. No single diagnostic test can exclude or confirm Wilson's disease with complete certainty. Parameters that can direct a medical team to a correct diagnosis include: A positive family history, Kayser-Fleischer rings, low ceruloplasmin level (<20mcg/dL), free copper >25mcg/dL, and 24hr urine copper >100mcg/24hr (9). Many patients don't display these parameters in an undisputed way and this poses a challenge in achieving a prompt and definitive diagnosis. Patients may require genetic testing if necessary. Either way, early detection is desirable in order to avoid dramatic disease progression (7). The intent of treatment is to restore hepatic copper homeostasis by systemic chelation (7). The measurement of copper content is important to rule out other liver disorders such as autoimmune hepatitis, chronic hepatitis B and C, Alpha-1 Antitrypsin deficiency, Rotor syndrome, Gilbert syndrome. The most widely used treatment for Wilson's disease is Penicillamine. It is classified as an anti-copper drug or chelating agent. Penicillamine has been available longer than all anti-copper drugs (10). It does come with some serious side effects, however, such as toxicity, hypersensitivity reactions, activation of autoimmune diseases, and neurologic worsening, and is being replaced by other equally effective and less toxic drugs as stated by Brewer and Askari (2). Zinc is also very commonly used as effective treatment and/or maintenance therapy of Wilson's disease. It works by inducing intestinal cell metallothionein and inhibits the absorption of copper (2,11). Other drugs include Trientine, which is a chelating agent, and Tetrathiomolybdate, which acts through a novel mechanism of action. It forms an unabsorbable tripartite complex with protein, copper, and itself, which will place the patient in a negative copper balance according to Bremner et al. (1,2). Classically, Penicillamine has remained the first-line treatment of Wilson's disease, however there is a growing shift towards selecting Zinc first instead (1). If not treated sufficiently, Wilson's disease can progress to liver failure and irreversible neurological deficits such as decreased cognition and gait ataxia before death.



## **CASE REPORTS**

### **Patient 1**

Patient D.V. was born on September 25<sup>th</sup>, 1991 in his mother's third regularly controlled pregnancy. He was first hospitalized at University Hospital Center Zagreb at the Department of Pediatric Gastroenterology as a 16 year old between June 20<sup>th</sup>-July 24<sup>th</sup>, 2007 for the purpose of diagnostic workup. He was initially sent from OB Bjelovar with the diagnosis of liver lesions of unknown etiology. Other than an episode of bronchitis at the age of four and chicken pox later on, the patient had a clinically uneventful childhood. Physical and psychomotor development was described as normal and on time. The patient was regularly vaccinated and did not have any post-vaccination complications. For a couple of years prior to his initial hospitalization in OB Bjelovar, the patient suffered from occasional spasms of both hands, both forearms, and both thighs. Sometimes the spasms were caused by exertion and they lasted about 5 minutes, but they would pass spontaneously. The complaints initially appeared about once a week, but ten days prior to his hospitalization at OB Bjelovar they became more frequent and severe. The day before admission, he had thirty episodes of finger and hand spasms but he didn't suffer from any while hospitalized.

On initial physical examination, the patient presented with slight jaundice, icteric sclera, and his liver was palpable two centimeters below his right costal margin. Abdominal ultrasound revealed a mildly enlarged liver, and an extremely enlarged gall bladder (12x6cm) that lacked concretions and signs of inflammation. Ophthalmologic examination did not reveal Kayser-Fleischer rings. On biochemical testing, the patient had elevated transaminases (AST 127 U/L and ALT 151 U/L). Immunological testing involving the following antibodies: ANA, ANCA, LKM-1 were all negative. EBV Viral Capsid Antigen and EBV Nuclear Antigen were positive, which meant that the patient previously had mononucleosis. The patient's coagulation tests were very poor. He had a PT activity percentage of 36% and his APPT was 49.6 seconds—well above the normal range of 29-33 seconds. He was also

thrombocytopenic. As a result, the patient received fresh frozen plasma multiple times throughout his hospitalization. The patient's serum copper was 11.2 $\mu$ mol/L, his urine copper content was measured at 10.6  $\mu$ mol/dU, and his ceruloplasmin was 0.12g/L. A sample of dried hepatic tissue was found to have 1387.9  $\mu$ g of copper per gram of tissue.

During his stay, the patient had a 1.4cm in length sample of his liver undergo biopsy. Histologically, there was a strong disturbance in architecture and remodeling of liver parenchyma due to expansion and fibrosis of the portal passages and numerous portal septa. There was ductal proliferation with mononuclear cell infiltrate. Many hepatocytes were described as foamy and there was the occasional appearance of Mallory bodies. In some hepatocytes, macro- and microsteatosis was found. Copper was found only in trace amounts. There was extensive fibrosis that was worrisome. The pathologist suggested that these findings were consistent with what could be expected in a patient with Wilson's disease. Based on all the findings over the course of his hospitalization, the patient was diagnosed with Wilson's disease and therapy was initiated. His initial regimen was Metalcaptase (Penicillamine) 300mg 2+1+1 either half an hour before a meal or two hours after and vitamin B6. He was also told to avoid foods rich in copper such as shellfish, chocolate.

On August, 3<sup>rd</sup>, 2007 the patient visited the outpatient clinic ten days after returning home from his initial and extensive five week hospitalization. At the time, three weeks had passed since chelating therapy was initiated. The patient reported no nosebleeds, he was not jaundiced, but his sclera were still mildly icteric. On physical examination there was no organomegaly. Biochemical tests revealed elevated transaminases (AST 149U/L and ALT 136 U/L), elevated bilirubin (77  $\mu$ mol), and coagulation issues. PT activity percentage was 33%, APPT was 53.5s, and he had platelet count of 120x10<sup>9</sup>/L.

Two weeks later on August 17<sup>th</sup>, 2007, the patient once again visited the outpatient clinic. It was noted that he was not healing as desired based on his coagulation tests despite regularly taking his prescribed medications. On physical examination, the patient was jaundiced and his liver was palpable below the right costal margin. He did not have edema, petechiae, angiomas, nor xantomas.

Between August 23<sup>rd</sup> and October 26<sup>th</sup>, 2007, the patient was hospitalized for the second time. Initially, prominent urination of copper was achieved but there was unsatisfactory correction of the PT so he was often transfused with fresh frozen plasma. Two days before his arrival, the patient developed swelling in his lower extremities and notable weight gain. He was jaundiced, he had very prominent veins on his anterior trunk due to ascites, he had angiomas around his umbilicus and his liver was palpable two centimeters below his right costal margin. During his stay, he immediately received replacement of albumin and was given diuretics. Dosage of Metalcaptase was raised too, which resulted in transient leucopenia. After ten days, the patient lost 13kg of weight, his jaundice faded, but his notable coagulation defects persisted. The patient's Nazer score correlated with a good prognosis and that conservative treatment with medication was sufficient. On the 21<sup>st</sup> day of hospitalization, he was given Zinc Acetate (50mg TID) to complement the chelating effects of Penicillamine. By the second month, the PT was finally satisfactory and he received no fresh frozen plasma in his final twenty days of hospitalization. By the end of the patient's hospitalization, it was noted that his most chronic problem was his slow functional healing and return of hepatic function—relative to his PT value. It was concluded that combined chelating therapy with Zinc Acetate and Metalcaptase was the best way to move forwards towards clinically stability. 500mg 3x3 daily of KCl and 1g of CaCO<sub>3</sub> were also added in his treatment regimen.

The patient's third hospitalization occurred between September 11<sup>th</sup> to 23<sup>rd</sup>, 2007. He described subjectively feeling well despite being febrile, sleepy, and feeling pain in his throat. On the basis of imaging, biochemical lab results, and the patient's physical examination, which notably presented weakened breathing sounds on the right side of his lungs, it was concluded that the patient had an airway infection and subsequent right-sided basal pneumonia with effusion. Parenteral antibiotic therapy (Cefuroxime, a third-generation cephalosporin) was required for fourteen days. The patient also received multiple infusions of albumin because of hypoalbuminemia and displayed prompt improvement in labs and clinical status. Biochemical laboratory results also unexpectedly showed a low value of copper in urine and high copper in serum despite regular therapy.

The patient had two separate visits as an outpatient, one week apart, on November 30<sup>th</sup>, 2007 and December 7<sup>th</sup>, 2007. He did not look icteric however and

he had his best PT activity percentage (45%) until that point in time. Liver function tests remained elevated. Copper in serum was measured at 7.4µmol/L and urine copper content was 16 mmol/dU. Chest x-ray examination showed complete restitution of his lung fields relative to his hospitalization two months prior.

The patient was admitted for his fourth hospitalization between March 26<sup>th</sup>, 2008 and April 15<sup>th</sup> 2008. On the day of admittance, the patient reported pain in his left knee and neck. The patient initially went to visit OB Pakrac where he was thoroughly examined, rehydrated, and received antibiotic therapy (1g of Ceftriaxone) before being sent to KBC Zagreb.

The patient was hypotensive, tachycardic, and febrile but had no jaundice. He also had a petechial rash. It was noted that the patient had dried blood in his posterior pharynx which suggested previous episodes of bleeding. A rheumatologist was consulted and concluded that the patient, based on anamnesis and lab results, most likely had reactive arthritis— but a complication of Wilson's disease could not be ruled out. The patient continued Ceftriaxone for another two weeks, received fresh frozen plasma three times for his coagulation defects, and was given 1.2g of Ibuprofen daily for his arthritis. Due to constant venepuncture and weak regeneration red blood cells, the patient developed anemia, which was worrisome. 100mg of Iron was added to his daily treatment regimen. It was concluded that the patient suffered an acute episode of gastroenterocolitis that destabilized his main illness. This showed that his liver does not have the reserves in the case of increased demand.

On September 5<sup>th</sup>, 2008, iron supplementation was removed from therapy.

On November 7<sup>th</sup>, 2008 the patient started receiving Aldactone 2x40mg for an unspecified reason. Lab results showed that his serum copper concentration was 3.6 µmol/L and urine copper concentration of 17.26 µmols/dU

On February 12<sup>th</sup>, 2012, dosage of Aldactone was raised to one 100mg tablet daily.

D.V. was hospitalized for the fifth time October 12<sup>th</sup> to 15<sup>th</sup>, 2010 for extensive follow-up. After his visit in the outpatient clinic on November 7<sup>th</sup>, 2008, the patient visited the outpatient clinic another six times prior to this hospitalization. Throughout these visits, elevated liver function enzymes and coagulation defects remained. Also

in the meantime, the patient developed spider nevi on his forearms, hands and neck, diffuse hypopigmented changes developed between his scapulas, his dose of Aldactone was lowered to 100mg daily, and his older brother had his urine tested for copper content which resulted within normal range.

During this visit, the patient was consulted by an ophthalmologist and a neurologist and nothing remarkable was noted by either. It was recommended to do thyroid hormone status. Ultrasound of the abdomen revealed a normal sized liver, biliary tract, and pancreas without visible focal lesions. Once again, the patients coagulation tests were poor—especially his platelet count which was  $88 \times 10^9$  cells/L. AST and ALT were also both elevated at 56 U/L and 108 U/L respectively. It was concluded at the end of this hospitalization that the patient's status was stable. Due to age, the patient would now continue to be followed by an adult gastroenterologist and specialist of hepatalogy, Dr. Mirjana Kalauz.

At the outpatient clinic on November 3<sup>rd</sup>, 2011, thyroid hormones came back normal normal. The patient would have two more unremarkable outpatient visits in the next year. For unspecified reasons, Zinc Acetate and Aldactone were removed from therapy.

In November 2012, the patient was hospitalized in OB Pakrac because of suspicion of appendicitis. The patient felt pain in his abdomen, initially at the top of his abdomen then diffuse then localized iliocecal, febrile without diarrhea. With conservative treatment, his pain subsided and he wasn't operated.

The patient arrived on January 17<sup>th</sup>, 2013 for a one-day scheduled hospitalization. Abdominal ultrasound was unremarkable. For the first time the patient underwent an upper endoscopy. The patient's esophagus revealed visible first degree varices, without redness. The stomach was normally positioned but had mucosal erosions and subcardial varicosities. The patient needed further follow-up to analyze the patient's portal circulation system. The patient continues to have poor coagulation tests. There was 8.43  $\mu\text{mol/dU}$  of copper found in the urine. PT activity percentage was 43% and thrombocytes were measured to be a low  $55 \times 10^9$ /L.. Transaminases were elevated (AST 64 U/L and ALT 67 U/L) and the patient's direct bilirubin concentration was slightly elevated at 54  $\mu\text{mol/L}$ . It was noted that the

patient had a six month old daughter and that it is recommended to do molecular analysis of her DNA once she reaches the age of two.

The patient was once again hospitalized between April 10<sup>th</sup> to 16<sup>th</sup>, 2013, at University Hospital Center Zagreb for extensive workup to evaluate the current state of his illness and to also assess his portal circulation due to esophageal and subcardial varices that were discovered three months prior. A contrast MSCT of the abdomen performed showed that the patient's liver had a prominent lobular contour that looked cirrhotic. Focal lesions were lacking, however. The gallbladder was distended due to a high quantity of bile but there were no signs of inorganic lithiasis. Arterial blood supply of the liver was typical. Portosystemic collaterals were present. Morphologically a normal pancreas was found. Multiple enlarged lymph nodes were also found locally and also in the retroperitoneum. Kidneys and adrenal glands were normal—with no dilation of the kidney canal system. Colonoscopy revealed external hemorrhoids. Finally, abdominal x-ray of the small intestinal tract showed completely normal passage.

The laboratory results today showed elevated liver transaminases (AST 78 U/L and ALT 79 U/L), elevated direct bilirubin (71  $\mu\text{mol/L}$ ), severe thrombocytopenia ( $44 \times 10^9/\text{L}$ ) and serum copper was 10.1  $\mu\text{mol/L}$ .

The patient was prescribed Propranolol 20mg BID to conservatively begin treatment of his varices.

The patient was hospitalized at KBC Zagreb on September 25<sup>th</sup>, 2013—his twenty-second birthday for re-evaluation of his illness. Abdominal ultrasound was unremarkable.

Upper endoscopy showed a normally dilated esophagus with varices in a chain-like formation down the middle third. The stomach was in normal position and there was normal peristalsis that followed down to the pylorus. Hyperemia with multiple chronic erosions was noted at the junction of the antrum and pylorus. It was described that the patient had newly found elements of progressive liver cirrhosis, splenomegaly, and lowered coagulation function. On his next hospitalization it was asked to perform: routine labs plus ceruloplasmin, copper in serum, 24h copper in urine, beta2 microglobulin, PET scan of the patient's periportal lymph nodes, MR

angiography, EUS with imaging of periportal lymphadenopathy, examination by hepatologist, evaluation if liver transplant is required.

Once again liver function tests showed elevated transaminases (AST 63 U/L and ALT 68 U/L) and prolonged APPT (40.3s). The patient's platelet count was at its lowest ever ( $38 \times 10^9$  cells/L). Serum copper was 9.5  $\mu\text{mol/L}$  and 12.35  $\mu\text{mol/dU}$  of copper content in urine. The patient was given furosemide 40mg.

The patient was hospitalized on February 19th, 2014 for re-evaluation of his disease state. For one month prior, he described an 'accumulation of water' in his body and that his shins and hands bothered him the most in particular. He stated that he is often fatigued. 100mg of Aldactone was reintroduced as therapy combined with Furosemide. On physical examination, it was noted that the patient had ascites, swollen feet and ankles, mildly jaundiced skin, icteric sclera, and hepatosplenomegaly. He also has decreased walking coordination. On mental examination, patient is slow to respond in conversation. It was concluded that patient D.V. urgently required a liver transplantation due to decompensated liver cirrhosis.

## **Patient 2**

Patient I.B. was born in her mother's fourth uneventful pregnancy on March 8<sup>th</sup>, 2002. At birth she weighed 4000g. She was breastfed for her first six months of life and vaccinated regularly. Beginning in November 2012, she complained of having a burning sensation in her throat and a fever only lasting one day. She was given Klavocin (Amoxicillin-Klavulanic Acid) but upon first dose she developed urticaria and therapy was discontinued. Two days later, laboratory results showed elevated liver enzymes and she was sent to the clinic of infectious diseases in Mostar for clinical workup where she was ultimately diagnosed with mononucleosis. Here, it was also proven that she had decreased serum copper and ceruloplasmin values (no documentation).

The patient was referred to and admitted to KBC Zagreb at the Department of Pediatric Gastroenterology for the first time between April 2<sup>nd</sup> -17<sup>th</sup>, 2013 under the suspicion of having Wilson's disease. A 2.5cm biopsy sample of hepatic tissue taken for analysis. The tissue was described as having disordered architecture, moderate

inflammatory infiltrate, and some peripheral portal fields displayed piecemeal necrosis. Neither Prussian Blue, PAS, and Rhodanine dye showed positive staining for hemosiderin, iron, nor copper in the cytoplasm of the hepatocytes. The pathologist stated that although copper deposits were not identified, the diagnosis of Wilson's disease could not be excluded. Analysis of dry liver tissue showed 864.5µg of copper per gram of dry tissue however. Toxicology analysis proved that iron was within normal range. Genetic analysis of the patient's DNA did not prove the most common H1069Q mutation. An abdominal ultrasound that was performed described her liver and spleen as slightly enlarged. Serology for hepatitis B and hepatitis C were negative, however she was positive for EBV VCA IgG that would support her previous diagnosis of having mononucleosis. She was also positive for CMV IgG. Furthermore, detection for the selected antibodies: ANA, ANCA, LKM1 were all negative thus narrowing the differential diagnosis. Ophthalmologic examination was unremarkable. It did not show pathognomic Kayser-Fleischer rings. Pediatric neurologist examination noted a discrete tremor in the patient's fingers. EEG was normal.

The patient, however, did have liver function test derangements such as raised transaminases (AST 163 U/L and ALT 352 U/L.) Coagulation tests were normal. Her copper in urine was measured at 2.18 µmol/L, her urine copper after penicillamine challenge was 17.64µmol/L. On the basis of her copper levels in urine pre- and post-penicillamine challenge test, her dry tissue liver biopsy, and the abundance of copper in her dry liver tissue, it was concluded that the patient has Wilson's disease. As initial treatment, the patient was sent home with Penicillamine 300mg TID and told to avoid foods with high copper content.

### **Patient 3**

Patient D.B. was born in her mother's third uneventful pregnancy on February 4<sup>th</sup>, 1996. She had normal psychomotor development and was regularly vaccinated. She had had menarche at the age of thirteen. Her first hospitalization at University Hospital Center Zagreb was between May 20<sup>th</sup>-May 24<sup>th</sup>, 2013. In the spring of 2013, her younger sister I.B. was diagnosed with Wilson's disease. At the time of her sister's diagnosis, doctors in Zagreb arranged with the father of the two girls to



perform lab screening on all members of I.B.'s immediate family members back home in Mostar, Bosnia.

The patient was at the time of her first hospitalization in the third year of high school and actively playing volleyball for the first league team. In April 2013, she described feeling tired she has felt tired and for two straight weeks her legs would swell at any time of day. She stated that she had not menstruated since January 2013.

She had a percutaneous biopsy of the liver performed whilst under mild sedation with 5mg Midazolam IV without any side effects. She received some fresh frozen plasma before this procedure. Samples from her biopsy showed enlarged and moderately polymorphic hepatocytes with an abundance of inflammatory infiltrates such as lymphocytes, histiocytes, plasma cells, and a few eosinophils (councilman bodies between Ductal proliferation was very prominent. Mallory inclusion bodies were identified within the cytoplasm. Peripheral portal fields showed piecemeal necrosis. Perisinusoidal and pericellular fibrosis was very prominent. Histochemical staining with Prussian Blue dye for hemosiderin and Rhodanine for copper were negative. The pathologist concluded that there was mildly active cirrhosis of the liver. A differential diagnosis of Autoimmune Hepatitis, toxic damage to liver parenchyma, and Wilson's Disease was suggested. In a separate dry tissue sample of the patients liver, 711.2 µg/g of dry weight tissue.

Biochemical laboratory tests showed raised transaminases (AST 136 U/L and ALT 118 U/L). Coagulation tests showed PT activity percentage to be 40%, and a 41.3s APPT. Her copper in urine was measured at 14.52 µmol/dU and after Penicillamine challenge it was 15.65µmol/dU. Her albumin was only 28.5 g/L which is below reference range.

Based on all these results, it was concluded that D.B., like her younger sister, had Wilson's disease which was discovered in an early hepatic insufficiency phase. As initial treatment, she was given Penicillamine 300mg 2 + 1 + 2 tablets which she was advised to take two hours after her meals and 50mg of vitamin B6 daily.

At her second hospitalization between June 14th to 19<sup>th</sup>, 2013, it was determined that D.B. did not have the most common H1069Q (exon 14) mutation of

ATP7B that we would expect in the Eastern European region. She didn't gain any weight since her previous hospitalization but continued to have ankle swelling. She had a head MRI performed in the area of her basal ganglia but imaging came back normal. The patient's hepatic functional capacity is still poor as evidenced by her 42.6s APPT and low 28.5 g/L of albumin. Her 24hr urine copper content was a very elevated 82.42  $\mu\text{mol/dU}$

It was noted that it was important to exclude presumptions of neurological disease. The MRI of her basal ganglia, as noted above, was encouraging. As of now it appears that only the hepatic and gonadal diseases have been effected. It was suggested that the patient abstain from all physical activity for the time being.

On July 15<sup>th</sup>, 2013 the patient was hospitalized again as part of a scheduled work-up of her illness. She continued to complain about ankle edemas around any time of the day.

Her transaminases were elevated (AST 97 U/L and ALT 101 U/L). Her urine copper content was 43.24  $\mu\text{mol/dU}$

On September 2<sup>nd</sup>, 2013, the patient stated that she hasn't had ankle swelling for the previous month. She had biochemical improvements with faster APPT, reduced liver transaminases (AST 64 U/L and ALT 59 U/L). She was advised to be careful with her intensity of exercise.

The patient was hospitalized for three days between December 16th-19th, 2013. The patient noted just mild ankle edema on a few occasions within the past few months.

## DISCUSSION

It is evident that Wilson's disease can present with a varying degree of symptoms. It is one of the more rare causes of liver diseases in children and typically presents in the second decade of life (7). In the patients I observed, all three presented differently. One presented with hepatic lesions, another presented with fatigue, ankle swelling and lack of menstruation for five months and the third was found to have incidental lab findings that could indicate presence of Wilson's disease as part of workup for a separate illness. At time of diagnosis, the average age of all patients studied was fourteen years and nine months. Patient 1 had the most extensive amount of history to analyze. He was the only one of three patients to have all three parameters of "classic presentation": hepatic, neurologic, and ophthalmologic involvement as described by Socio *et al.*— although they didn't occur simultaneously (7). Throughout his entire illness, he had a deteriorating trend of health status and is now awaiting a liver transplant due to chronic cirrhosis and portal hypertension six and a half years after his initial diagnosis. The patient's persistent liver damage is evidenced by elevated ALT values consistently over the upper limit of normal throughout his history (Figure 1). This downward trend can also be seen in some of his lab parameters, for example, his thrombocyte count (Figure 3). During his latest hospitalization, the patient was described as have mental delay in conversation and decreased coordination when walking. The question of whether or not he had been placed on the waiting list for liver transplant too late must be posed. Would it have been more beneficial to give him a new liver at an earlier point in time than allow his illness to progress to his central nervous system as much as it has? In this particular case, as a representative of other cases with similar presentations and histories like this one, the resounding answer is yes. Furthermore, patient 1 had a poor transition between pediatric care to adult care and as a result his health took a turn for the worse. Focused continuity of care is of high priority in patients with Wilson's disease and must be addressed by a multidisciplinary team through active communication. As of now, patient 2 and patient 3 have had liver biopsies performed that showed extensive hepatocellular damage. They should both be carefully

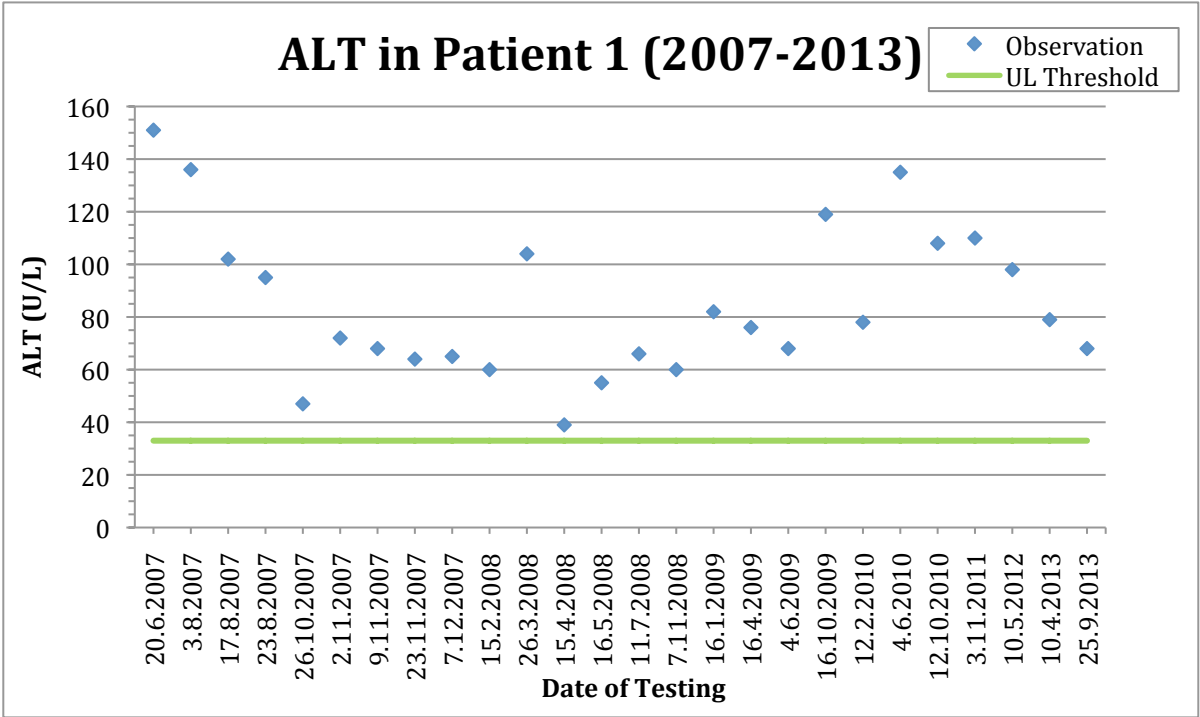
monitored for the next year and if there is no clinical or biochemical improvements, additional medical therapy or liver transplantation should be considered. If additional medical treatment was selected, re-evaluation should be repeated after six months. Patient 2 and patient 3 also have never had a Nazer et al prognostic score evaluated. Since it is so simple, I recommend calculating it at every hospitalization for a patient with Wilson’s disease. It is necessary to always evaluate the liver for possible deterioration of function.

**Table 1** Nazer *et al* (6) prognostic classification based on liver function. Score >7 suggests a risk of death if liver transplantation not performed.

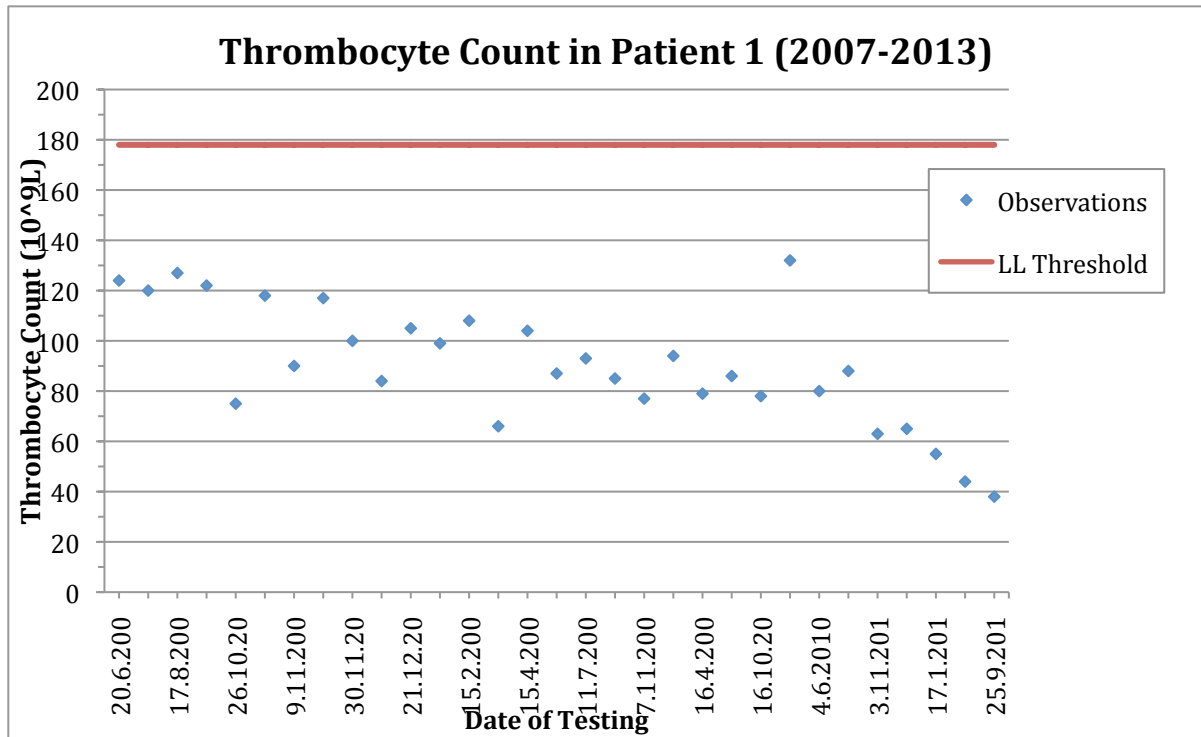
	BILIRUBIN (mg/dL)	AST (IU/L)	INR
0	<5.8	<100	<1.3
1	5.9-8.8	100-150	1.3-1.6
2	8.9-11.7	151-200	1.6-1.9
3	11.8-17.5	201-300	1.9-2.4
4	>17.5	>301	>2.4

Currently, patient 2 and patient 3, who are sisters, are taking their medications regularly and are clinically stable. Patient 3 also had an MRI of her head performed that was concluded to be unremarkable. It is important to track status of brain involvement in patients with Wilson’s disease because it is critical to avoid debilitating central nervous system involvement that presents with poor cognition and ataxia for example. If there is a patient with psychiatric symptoms with another clinical feature of probable Wilson’s disease, a complete workup must be done. What is also concerning about Patient 3, however, is that she did not menstruate for close to a year but that has recently returned to normal which is a very encouraging clinical improvement. Gonadal dysfunction is a serious consequence of Wilson’s disease. When you see a patient with delayed puberty in addition to at least one other clinical feature of probable Wilson’s disease, once again, a complete workup is suggested. With regards to gonadal dysfunction in a patient with Wilson’s disease, there is

accumulating evidence that switching to Zinc may correct menstrual abnormalities better (12).



**Figure 1.** Observed concentration of ALT in Patient 1 between the years 2007-2013. Abbreviation: UL, upper limit



**Figure 2.** Observed concentrations of thrombocytes in Patient 1 between the years 2007-2013. Abbreviation: LL, lower limit

## CONCLUSION

The presentation of Wilson's disease in children is highly variable. This can make establishing a definitive diagnosis challenging if these symptoms are minimal. Furthermore, no single diagnostic test can exclude or confirm Wilson's disease with complete certainty. If a patient has a confirmed diagnosis of Wilson's disease, strict adherence to medical treatment, whether given Penicillamine or Zinc initially, and a low-copper diet is strongly advised to avoid dire clinical manifestations such as progressive hepatic failure or irreversible neurological deficits. It is also critical to promptly recognize unrelated febrile illness in a patient with Wilson's disease. In such cases, the liver can be exhausted to the point of irreversible damage. It is also suggested to do a Nazer et al prognostic score as often as possible to track the snapshot status of the patient's liver functions and analyze trends over time. Wilson's disease can be unnecessarily devastating if not treated promptly and efficiently therefore the consequences of poor disease control must be at the forefront of the medical team—especially if treating a young, maturing child or adolescent with many quality years of life ahead.

## **ACKNOWLEDGMENT**

I would like to thank Professor Jurica Vuković from the Department of Pediatrics at University Hospital Center Zagreb, for his mentorship throughout this paper. I would also like to thank my parents, Tibor and Tanja, for all their love and continued support.



## REFERENCES

1. Brewer George J, Askari Fred K Wilson's disease: clinical management and therapy *Journal of Hepatology* 2005 S13-S21
2. Dhawan A, Taylor RM, Cheeseman P, de Silva P, Katsiyiannakis L, Mieli-Vergani G. Wilson's Disease in Children; 37-Year Experience and Revised King's Score for Liver Transplantation. *Liver Transpl* 2005;11(4): 441-8
3. Ferenci P, Caca K, Loudianos G. et al Diagnosis and phenotypic classification of Wilson disease. *Liver Int* 2003. 23:139–142.
4. Loudianos G, Gitlin JD. Wilson's Disease. *Seminars in Liver Disease*. 2000; 20:353-64
5. Manolaki N et al. Wilson Disease in Children: Analysis of 57 Cases. *Journal of Pediatric Gastroenterology and Nutrition*. 2009; 48; 72-77
6. Nazer H, Ede RJ, Mowat AP, Williams R. Wilson's disease: Clinical presentation and use of prognostic index. *Gut* 1986; 27:1377-81.
7. Nicastro E et al. Re-evaluation of the Diagnostic Criteria for Wilson Disease in Children With Mild Liver Disease *Hepatology*. 2010; 52:1948–1956
8. Roberts Eve A., Schilsky Michael L. Diagnosis and Treatment of Wilson Disease: An Update. *HEPATOLOGY* 2008; 47(6):2089-2111
9. Socio SA et al. Wilson's Disease in children and adolescents: diagnosis and treatment. *Rev Paul Pediatr* 2010; 28 (2): 134-40
10. Walsh JM. Penicillamine, a new oral therapy for Wilson's disease. *Am J Med* 1956;21:487-495
11. Yuzbasiyan-Gurkan V et al. Treatment of Wilson's disease with zinc: X. Intestinal metallothionein induction. *J Lab Clin Med* 1992; 120:380-386
12. Krysiak R et al. Endocrine symptoms as the initial manifestation of Wilson's disease. *Yale J Biol Med*. 2012 Jun;85(2):249-54

## **BIOGRAPHY**

Vilim Kalamar was born on March 14th, 1990 in Zagreb, Croatia. In 1991, his family immigrated to Vancouver, Canada. After graduating from Windsor Secondary School in North Vancouver in 2008, Vilim made the personal choice to move back to Croatia to study and pursue a career in medicine at the University of Zagreb School of Medicine. During his studies, Vilim was actively involved in the Zagreb branch of the European Medical Students' Association (EMSA) which throughout the year organizes three major events: EMSA Dubrovnik Summer School of Emergency Medicine in Dubrovnik, Croatia, the annual Zagreb International Medical Summit (ZIMS), and Teddy Bear Hospital. He also had an incredible experience doing a two-month clinical clerkship abroad at the Department of Endocrinology and Metabolism at Montreal General Hospital in Montreal, Canada following his fifth year of studies. Besides from medicine, Vilim's interests include traveling and exercising. Vilim is undecided about which field of medicine he would like to specialize in or which country he would like to work in one day. He is considering the United States of America, England, Sweden, or Croatia.