

# Sexual dimorphism of the extraorbital lacrimal glands in SF-1 knockout mice

---

Šemanjski, Kristina; Majdič, Gregor; Kozina, Viviana; Ježek, Davor

Source / Izvornik: **Acta Histochemica, 2021, 123**

Journal article, Accepted version

Rad u časopisu, Završna verzija rukopisa prihvaćena za objavljivanje (postprint)

<https://doi.org/10.1016/j.acthis.2020.151669>

Permanent link / Trajna poveznica: <https://um.nsk.hr/um:nbn:hr:105:071402>

Rights / Prava: [In copyright](#) / [Zaštićeno autorskim pravom.](#)

Download date / Datum preuzimanja: **2024-07-28**



Repository / Repozitorij:

[Dr Med - University of Zagreb School of Medicine  
Digital Repository](#)



Kristina Šemanjski<sup>1</sup>, Gregor Majdič<sup>2</sup>, Viviana Kozina<sup>3</sup>, Davor Ježek<sup>3</sup>

## ***Sexual Dimorphism of the Extraorbital Lacrimal Glands in Sf-1 Knockout Mice***

Affiliations: <sup>1</sup>Clinical Hospital "Sveti Duh", Zagreb, Department of Surgery, <sup>2</sup>University of Ljubljana, Veterinary Faculty, Centre for Animal Genomics, <sup>3</sup>University of Zagreb, School of Medicine, Department of Histology and Embryology

Corresponding author: Kristina Šemanjski, ksemanj@gmail.com; +385977253750, Cankareva 5, 10000 Zagreb, Croatia

**Abstract:** Sexual dimorphism (SD) represents all the differences between males and females of the same species. SD of the murine lacrimal gland and the major effect of testosterone on its formation are well documented. Steroidogenic factor-1 (SF-1, NR5a1) is a nuclear receptor essential for the fetal development of steroid hormones producing organs and SF-1 knockout mice (*Sf-1* KO) are therefore born without gonads and adrenal glands. The aim of this study was to investigate whether SD in lacrimal glands is present in the absence of exposure to sex hormones during development. Lacrimal glands from adult *Sf-1* KO male and female mice without hormonal exposure, and from males that were treated with testosterone propionate (TP) prior to sacrifice, were examined. After sacrifice, glandular tissue was processed using standard histological procedures. Paraffin sections were analysed by stereology and immunostained against the androgen receptor (AR). Our results showed that there were no statistically significant differences in the mean volumes of acini, connective tissue or ductal system between males, females, and males on TP. The same pertains to the mean length of the ducts in all three groups. In the absence of sex hormones, sex chromosomes proved to be insufficient in inducing sexual dimorphism in LG. However, nuclei of the acinar cells in males on TP were positive for AR, whereas in males without TP no expression of AR was detected. Administration of TP induced the expression of AR in the nuclei of acinar cells of males but did not affect the morphology of LG. We conclude that SD in the lacrimal gland is not present in *Sf-1* KO mice and this suggests that sex hormones have a major role in the development of SD in the lacrimal gland.

Keywords: sexual dimorphism, lacrimal gland, testosterone, *Sf-1* KO mice

Acknowledgments: This research was supported by a grant from the Croatian Ministry of Education and Science (108-1080399-0383, Male and female reproductive system: development, normal histophysiology and infertility) and the European Union through the European Regional Development Fund, Operational Programme Competitiveness and Cohesion, under grant agreement No. KK.01.1.1.01.0008, Regenerative and Reproductive Medicine - Exploring New Platforms and Potentials.

There are no competing interests to declare.

We would like to thank the Department of Histology and Embryology, School of medicine, Zagreb for providing help and technical support in our research.

## Introduction

Sexual dimorphism (SD) represents all the characteristics that differentiate two sexes - male and female. Those differences go well beyond visible physical characteristics. Fundamental sex-related differences exist in almost every cell, tissue and organ of the body (respiration, digestion, metabolism, musculoskeletal system, circulation, renal function, neural and endocrine activity) and finally in the organism as a whole.

Biological sex also has a significant impact on the eye. Lacrimal gland (LG) is one of the most studied ocular tissues that exert sexual dimorphism. It produces a serous component of the tear film and can be acinar or tubuloacinar gland. In contrast to human one pair of intraorbital lacrimal glands, rodents have three pairs. Two pairs are inside the eye orbit (lacrimal and Harderian gland). Remaining one pair of lacrimal glands is extraorbital, located below the outer ear in the subcutaneous tissue. Its location near the parotid gland and histological similarity is the reason why investigations of the lacrimal gland began at the same time as salivary glands. The first evidence of sexual dimorphism of salivary glands and histologically similar lacrimal glands dates back to the middle of the 20<sup>th</sup> century (Lacassagne A., 1940). Throughout the years, the lacrimal gland has been extensively studied, so today many studies of mammal LG can be found in the literature. The absolute weight of lacrimal tissue is usually greater in males and the acinar area is larger in males in all studied species. Acini of males are larger with wide lumina, while female acini are smaller and more regular with narrow lumina. Acinar cells in females show clearer cytoplasm with heavy perinuclear basophilic staining, while in males the cytoplasm is lightly basophilic. Male acinar cells show distinct nuclear polymorphisms and often they have prominent nucleoli (Cornell-Bell et al., 1985). Apart from anatomical and morphological differences, SD of the lacrimal gland is demonstrated on a molecular and biochemical level with the differences in secretion and composition of the tear film, immunological system and gene expression (Sullivan et al., 1998). With ageing in rodents, SD becomes more prominent with the appearance of "harderisation" only in males, a phenomenon that consists of the appearance of lipid foci in the acinar cells of lacrimal glands (Sashima et al., 1989).

The reasons for SD in LG can be attributed to genetic and hormonal factors. The genetic effect is demonstrated by numerous studies. Sex-related differences in gene expression of specific tissue play a role in the sexual dimorphism of the salivary (Treister et al., 2005) and lacrimal gland. Sex has a significant influence on the expression of over 490 genes involved in a wide range of cellular components and morphology, various biological processes and molecular functions in the mouse lacrimal gland. The expression of selected genes was confirmed using GEM gene chips and qPCR (Richards et al., 2006).

The studies conducted, firstly on the salivary gland and subsequently on the lacrimal gland, have demonstrated the significant impact of sex hormones, especially androgens, in the development of sexual dimorphism of LG and normal functioning of the gland. Salivary and lacrimal glands are target organs for testosterone (Chrétien, 1977; Sullivan et al., 1996). Orchiectomy or treatment with the androgen receptor antagonist leads to degenerative changes in lacrimal tissue and transformation to the "female" type of gland (Ježek et al., 1996;

Sullivan et al., 1998). Testosterone regulates expression of more than 2000 genes in LG (Richards et al., 2005) via nuclear androgen receptors. It contributes to the development of SD and the maintenance of the function of LG (Azzarolo et al., 1997). The sex and endocrine system can affect the number of ligands for androgens in the lacrimal gland and androgens themselves can up-regulate the number of AR (Rocha et al., 1993, 1994; Vanaken et al., 1998).

The action of estrogen and progesterone on the lacrimal gland involves the regulation of numerous genes. However, these hormonal effects do not appear to represent a major factor underlying the sexual dimorphism of gene expression in lacrimal tissue (Suzuki et al., 2006). Prolactin plays a small role in establishing the sexual dimorphism of male lacrimal glands. In females, hyperprolactinemia causes a hyper female morphology (McClellan et al., 2001). Also, increased prolactin levels and decreased serum levels of estrogen and progesterone result in the impairment of the function of the lacrimal gland (Araujo et al., 2015).

Steroidogenic factor-1 (SF-1/Ad4BP/NR5a1) is a transcription factor and belongs to the nuclear steroid receptor family (Honda et al., 1993). Firstly was identified as a coordinator of the expression of genes encoding enzymes required for the biosynthesis of steroid hormones in the adrenal cortex (Lala, 1992; Lynch et al., 1993; Morohashi et al., 1993, Morohashi and Omura, 1996). Studies that used knock-outs for SF-1 gen showed that this factor is essential for the development of the gonads and adrenal glands (Luo et al., 1995; Sadovsky et al., 1995) as well as for the development of ventromedial hypothalamus (Ikeda et al., 1995) and the proper functioning of pituitary gonadotropins (Ingraham et al., 1994). SF-1 plays a significant role in regulating the genes involved in sex determination cascade. It participates in the expression of AMH, antimullerian hormone (Shen et al., 1994) and contributes to the action of SOX-9 (Shen and Ingraham, 2002) and sex-determining region Y (Sekido, 2010) in mammalian sex determination. Studies of both global and tissue-specific knock-out mice have demonstrated that many genes are transcriptionally regulated by SF-1, also according to its dosage, and many proteins, in turn, interact with SF-1 and modulate its activity (Schimmer and White, 2010; Doghman et al., 2013). In mice is expressed in all primary steroidogenic tissues and the embryonic urogenital ridge (Crawford et al., 1997). It has a central role in the differentiation of the cells into the steroidogenic lineage (Jeyasuria et al., 2004). Mice lacking SF-1 gen have no adrenal glands and gonads (Luo et al., 1994) and die soon after birth due to adrenal insufficiency.

These mice represent one of the models for investigations of SD. Although they lack gonads and subsequently sex hormones, their cells have normal XX or XY genomes, thus they have normal genetic sex. Previous studies of SD in the brains of *Sf-1* KO mice have demonstrated the altered position of cell bodies and fibres in the VMH region in male and female *Sf-1* KO mice (Büdefeld et al., 2008, 2011).

Although several studies about SD in the lacrimal gland has been done before, the effect of sex hormones on SD has been studied mostly by gonadectomy of adult animals. In the present study, we have used mice who have genetic sex but are hormonally "naive" and are thus never exposed to sex steroid hormones. We, therefore, tested two hypotheses using this murine

model: Is sexual dimorphism in LG solely dependent on sex hormones or is also influenced by sex chromosomes and whether the replacement of testosterone in adult life could induce SD or the expression of androgen receptors in the acinar cells?

## **Materials and methods**

### *Animals and tissue recovery*

C57BL/6J SF-1heterozygous mice (*Sf-1* +/- backcrossed to C57BL/6J for more than ten generations and inbred for more than ten generations) were bred to generate *Sf-1* KO and littermate wild type (WT) control mice. Mice were maintained at a constant temperature (20°-24° C) on a 12:12 dark-light cycle with a phytoestrogen free chow (Global 16% protein rodent diet, Harlan Teklad, Bicester, Oxfordshire, UK) and water ad libitum.

Usually, *Sf-1* KO mice die within 24 h of birth due to adrenal insufficiency. Therefore, all new-born pups (WT and *Sf-1*) received daily subcutaneous injections of 50 µl of corticosteroids in corn oil (400 µg/ml hydrocortisone /Sigma, Steinheim, Germany/, 40 ng/ml dexamethasone /Sigma/ and 25 ng/ml fludrocortisone acetate /Sigma/ in 1 ml of corn oil) until genotyping. Animals were genotyped on days 6-7 postnatally using PCR assay to determine *Sf-1* genotype and chromosomal sex. DNA samples were obtained by tail clipping and digested in a thermostatic shaker in 200 µl of PCR DNA buffer (Promega, Madison, WI, USA) containing 0.15 mg of Proteinase K (Sigma) at 55° C overnight. Three µl of lysate was used for PCR reaction to determine the presence of WT or KO *Sf-1* allele and the presence or absence of *Sry* gene (Luo et al., 1994).

### *Adrenal glands transplantation*

Immediately after genotyping, on postnatal days 7 or 8, WT littermates were used as a source of adrenal transplants for male and female *Sf-1* KO pups. After sacrifice, the WT adrenal glands were excised through an incision on the back, washed in ice-cold PBS, and transferred into ice-cold PBS containing 100 pg/mL fibroblast growth factor (Sigma). A small transdermal puncture was made with a 20-gauge needle in the subaxillary region of all *Sf-1* KO mice. Two adrenal glands were placed subcutaneously using sharp forceps, and the skin was closed (Majdic et al., 2002). On the first and second day after adrenal transplantation, pups received 50 µl of corticosteroid cocktail (400 µg hydrocortisone /Sigma/, 40 ng dexamethasone /Sigma/ and 25 ng fludrocortisone acetate /Sigma/ in 1 ml of corn oil). Subsequently, the above-mentioned steroid cocktail injections were given to *Sf-1* KO mice on days 14, 17 and 21 postnatally, and they received no further steroid treatment after weaning at 3 wk.

### *Isolation of lacrimal glands*

For our study, we used lacrimal gland tissue of male mice *Sf-1* KO (N=10) and female mice *Sf-1* KO (N=11). We had a third group of male mice *Sf-1* KO (N=8) that received the same treatment as male and female *Sf-1* KO mice but were given substitution therapy in the form of testosterone propionate (TP) in corn oil (0.1 mg sc.) daily 2 wks. before sacrifice at six months of age. (Table 1)

Group	N=
Male <i>Sf-1</i>	10
Female <i>Sf-1</i>	11
Male <i>Sf-1</i> +TP	8

Table 1

At six month of age all *Sf-1* KO mice were anaesthetized using a mixture of ketamine (Vetoquinol Biowet, Gorzowie, Poland; 100 µg/g BW), xylazine (Chanelle Pharmaceuticals Ltd, Loughrea, Ireland; 10 µg/g BW) and acepromazine (Fort Dodge Animal Health, Fort Dodge, IA, USA; 2 µg/g BW). Anaesthesia was followed by cervical dislocation. Immediately after sacrifice, extraorbital lacrimal glands were excised and put into Bouin's fixative.

### ***Histological and immunohistochemical analysis***

The tissue of lacrimal glands was subjected to standard histological procedures. Tissue was embedded in paraffin. Sections 5 microns thick were cut with a microtome and stained with hematoxylin and eosin (H&E), PAS method, modified Masson method and trichrome Azan method. We used PAS method to evaluate the granules in the cytoplasm of acinar cells, while Azan staining and modified Masson method were used to identify the collagen fibres in the connective tissue of LG.

Qualitative analysis and photographing were done using a light microscope (Nikon Eclipse E200). For the quantitative analysis following stereological parameters were analysed: acinar volume density ( $V_{va}$ ), duct volume density ( $V_{vd}$ ), the volume density of connective tissue ( $V_{vct}$ ), the longitudinal density of intralobular ducts ( $L_{vi}$ ) and longitudinal density of extralobular ducts ( $L_{ve}$ ). The analysis was performed on an Olympus Bx61 microscope with the use of software for stereological analysis Stereoinvestigator 10 (MBF Bioscience, Williston, VT USA) at the Croatian Institute for Brain Research, Zagreb, Croatia.

In our research, we used tissue of lacrimal glands of 29 *Sf-1* KO mice (Table 1). The whole gland was serially cut. We used every 10<sup>th</sup> section to be sure we are not counting the same acini in our investigation. The whole gland was outlined at 4x, and the analysis was done at 40x objective magnification. The outlined section was sampled by the principle of SURS (Systematic Uniform Random Sampling). Area fraction/fractionator probe was used to assess the percentage of tissue which is taken by the acini, ducts or connective tissue. The total area of tissue examined per group is demonstrated in Figure 1.

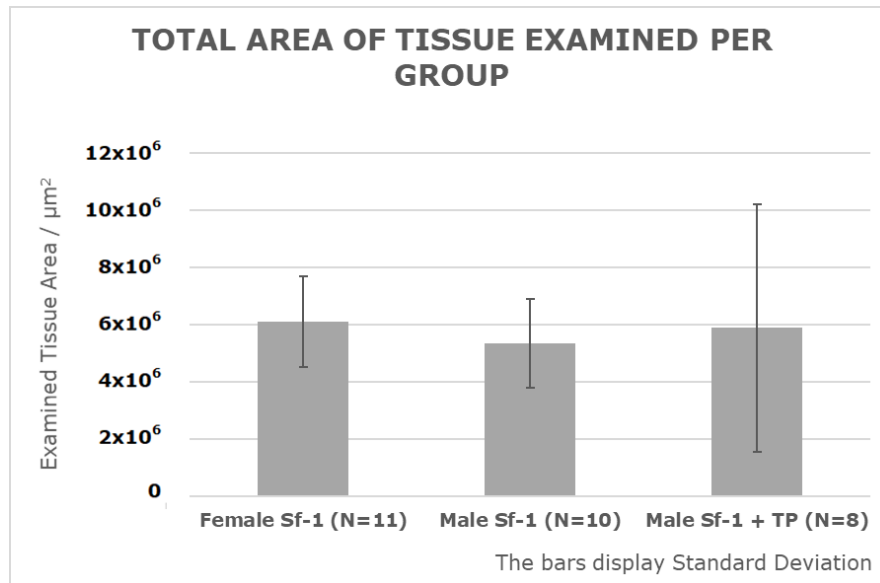


Figure 1

For the detection of AR in the nuclei of acinar cells, we used the tissue of lacrimal glands of hormonally naïve *Sf-1* KO males and *Sf-1* KO males who received testosterone substitution before sacrifice. Immunostaining for AR expression was performed using Vectastain ABC-AP Kit (Rabbit IgG) (Vector Laboratories, Inc., Burlingame, CA, USA) with the ImmPACT Vector Red Alkaline Phosphatase Substrate Kit (Vector Laboratories). Immunohistochemical staining was performed on paraffin-embedded sections (4 microns thick), mounted on positively - charged slides for each sample. Sections were deparaffinized in 2 changes of xylene, 5 minutes each, and then rehydrated in descending grades of ethanol. Antigen retrieval was carried out by the microwave oven method for 40 min in citrate buffer (10mM Citric Acid, 0.05% Tween 20, pH 6.0). The slides were allowed to cool for 20 minutes at room temperature and then rinsed in PBS Tween 20 for 5 minutes. Sections were blocked with a diluted normal blocking serum included in Vectastain ABC-AP Kit (Vector Laboratories, Burlingame, CA, USA) for 20 minutes. Primary anti-androgen receptor antibodies (Rabbit monoclonal /EPR1535(2)/ to Androgen Receptor, Abcam) were diluted 1:100 in antibody diluents and sections were incubated overnight at 4° C. Following incubation, the sections were washed three times in bath of PBS Tween 20 for 5 min each. Sections were then incubated with secondary biotinylated anti-rabbit IgG (Vector) for 1 hour at room temperature and then rinsed in PBS Tween 20 for 3x5 minutes. After second antibody treatment, sections were exposed to Vectastain ABC-AP reagent (Vector) at a dilution of 1 in 100 in PBS for 30 min at room temperature. After further washing in PBS, visualisation was carried out using alkaline phosphatase substrate solution ImmPACT Vector Red Alkaline Phosphatase Substrate Kit (Vector Laboratories) by incubation of sections 40 min in dark. After checking the staining intensity, the sections were washed in water. Finally, all sections were counterstained for 1 minute with hematoxylin and dehydrated in ascending grades of ethanol. Xylene was used to clear the slides before being mounted in BioMount. In these studies, positive (tissue of mouse testes) and negative (tissue of mouse lungs) control sections were also included. The ImmPACT Vector Red substrate produces an intensively red reaction in the presence of alkaline phosphatase (AP) enzyme and can be seen exclusively in nuclei of

acinar cells in LG (Rocha et al., 1993). AR expression was detected and qualitatively analysed using a microscope Nikon Eclipse E200.

### ***Statistical analysis***

Data from the experiment were subjected to ANOVA to identify a statistically significant difference between groups. Mean length of the ductal system in all three groups was analysed using the Kruskal-Wallis test. All statistical analyses were performed with GraphPad software package for PC (GraphPad Software, La Jolla, CA, USA).

## **Results**

### ***Stereological analysis***

The graph on Figure 2 represents the mean  $\pm$  SD of the volume density in  $\text{mm}^3$  of the acinar volume density (Vva), duct volume density (Vvd), and the volume density of connective tissue (Vvct) on the extraorbital lacrimal gland (LG) to groups: male mice *Sf-1* KO (male *Sf-1*), female mice *Sf-1* KO (female *Sf-1*), and male mice *Sf-1* KO + TP (male *Sf-1* + TP) groups. There was no statistically significant difference in the different statistical analyzes performed among three tested groups ( $p > 0.05$ ).

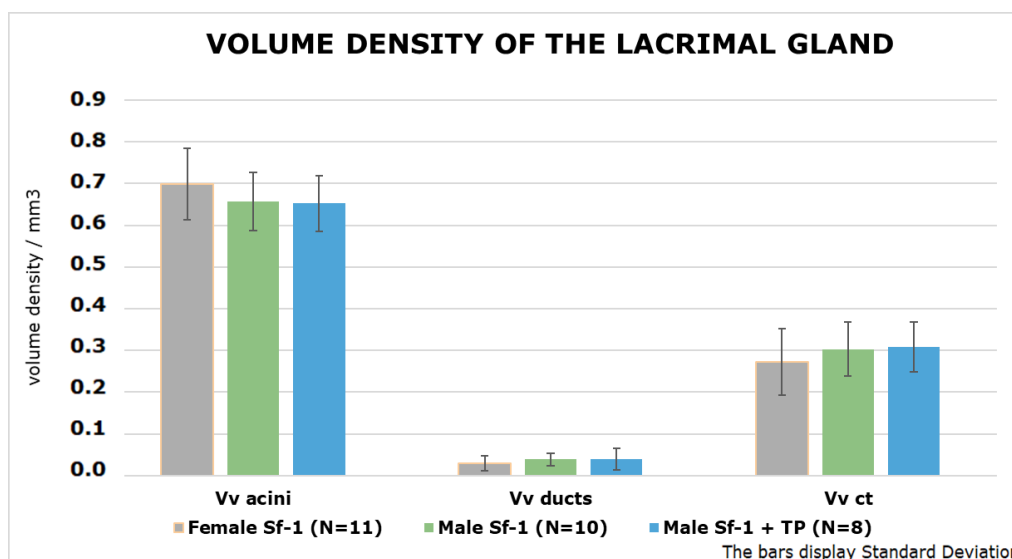


Figure 2

The graph on Figure 3 represents the mean  $\pm$  SD of the length in  $\text{mm}^2$  of the longitudinal density of intralobular ducts (Lvi), and longitudinal density of extralobular ducts (Lve) on the extraorbital lacrimal gland (LG) belonging to the groups: male mice *Sf-1* KO (male *Sf-1*), female mice *Sf-1* KO (female *Sf-1*), and male mice *Sf-1* KO + TP (male *Sf-1* + TP) groups. There was no statistically significant difference in the different statistical analyzes performed among three tested groups ( $p > 0.05$ ).



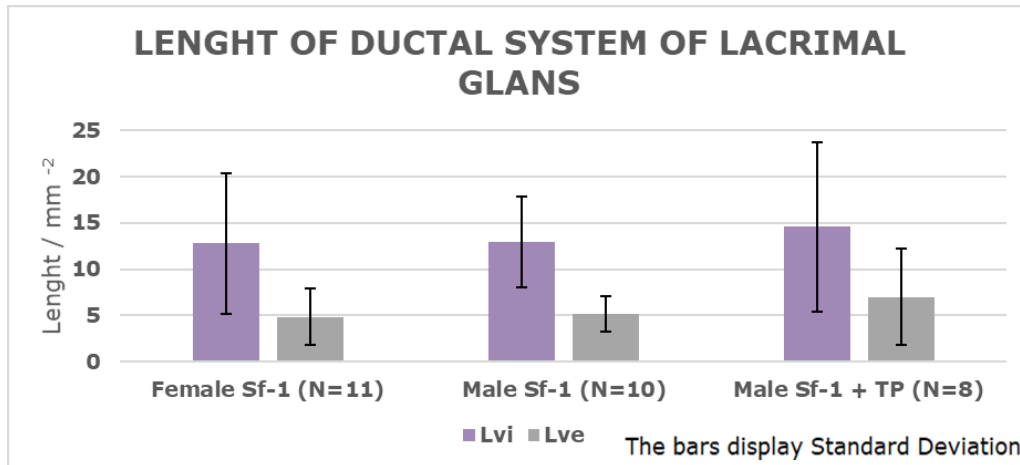


Figure 3

### Immunohistochemistry

Nuclei of the acinar cells in males on substitution therapy with testosterone propionate (male *Sf-1* + TP) were positive for the androgen receptor, whereas androgen receptor expression in males without TP signal was negative (Figure 4).

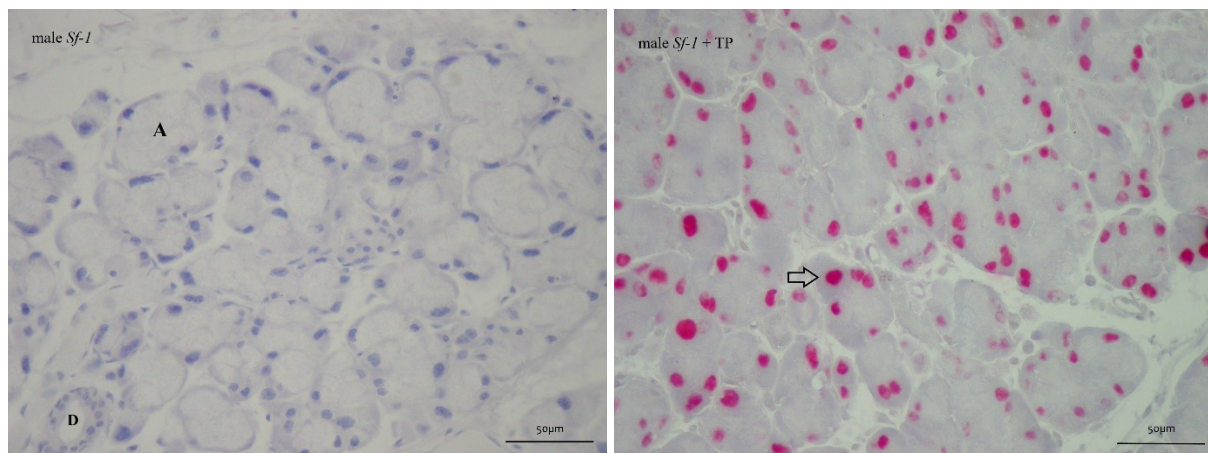


Figure 4. Immunohistochemistry for androgen receptors on the extraorbital lacrimal gland (LG) belonging to the groups: male mice *Sf-1* KO (male *Sf-1*) and male mice *Sf1* KO + TP (male *Sf-1* + TP) groups. The red colour corresponds to the immunopositivity to androgen receptors in nuclei of the acinar cells (arrow). One acinus labelled with A and a transverse section of ductus labelled with D. Observation in magnification 40X, Bar 50µm

### Discussion

The tear film is an essential part of the ocular surface microenvironment. The lacrimal gland contributes to it by secreting the aqueous portion of the tear film. The disturbance in the homeostasis of the microenvironment leads to the condition called dry eye syndrome (DES). Dry eye is the most common ocular surface disease throughout the world, and the prevalence

of dry eye is greater than 10% with a rising trend (Sahai and Malik, 2005). The symptoms can vary from discomfort and burning or stinging sensation to blurred vision or even blindness. Although the aetiology of DES is multifactorial, women experience the dry eye problems and in the particular autoimmune variant of dry eye called Sjogren syndrome, more frequently than men. Because the main risk factors for DES are female gender and advanced age, low levels of testosterone might be one of the factors contributing to the development of this condition. It has been proven that androgens have a significant effect on the gene expression, protein synthesis, secretion and immune response of the ocular tissue, especially lacrimal gland (Rocha et al., 1993, 1994, 2000; Truong et al., 2014). Also, androgens exert an anti-inflammatory role in the lacrimal gland. They induce synthesis and up-regulation of TGF- $\beta$  associated with the reduction of interleukin-1 $\beta$  and TNF- $\alpha$ , thus suppressing the activity of T lymphocytes (Beauregard and Brandt, 2004). Thus, sex-steroid imbalance, primarily reduction in the androgen levels, may predispose individuals to the development of dry eye and autoimmune conditions affecting the ocular surface (Versura et al., 2015).

For a long time, treatment of dry eye has been symptomatic - lubrication with artificial tears. In the last two decades, significant progress has been made with the anti-inflammatory, immunomodulatory agents and secretagogues stimulating the tear secretion (Zhang et al., 2017). One of the lines of the treatment considered is topical application of androgens (Worda et al., 2001; Li et al., 2015). Also, there have been experiments with plants that contain flavonoids that have a similar chemical structure and function to androgens. One research showed that topical treatment with Buddleia on castrated rats could inhibit the development of DES after androgen level is lowered (Jiang et al., 2017). Research on postmenopausal women showed that extract of mistletoe could alleviate the symptoms and signs of dry eye symptoms (Peng et al., 2010).

The lacrimal gland has been extensively studied since the middle of the 20<sup>th</sup> century.

Numerous studies have shown that LG is a sexually dimorphic organ and that androgens play a significant role in establishing male and female glands. It has been proven that orchietomy or administration of antagonists of androgen receptors leads to degenerative changes in the gland, whereas administration of androgens reactivates the gland.

All studies so far have been conducted on adult animals whose LG had normal morphology and function before physical or chemical castration. In this study, we wanted to analyse the glands of male and female mice who were not subjected to the sex hormones during development. Thus, in the current study, we used *Sf-1* KO mice. Although these mice have normal sex chromosomes and genetic sex, lack of *Sf-1* gene and its product leads to agenesis of steroid producing tissue. Thus, *Sf-1* KO mice are born without testes or ovaries and are therefore not exposed to sex hormones (androgens and estrogens) both pre- and postnatally. The primary question was if a sexual dimorphism exists in lacrimal glands of these hormonally naive animals.

Previous studies examining the brain of *Sf-1* KO mice demonstrated that some areas previously reported being sexually dimorphic in the mammalian brain show SD also in *Sf-1* knockout mice, suggesting sex chromosome dependent sex differences (Büdefeld et al., 2008, 2011).

Contrary to these results, the results of our study demonstrated that there is no sexual dimorphism of the lacrimal gland of *Sf-1* KO mice. Genetic factors in the absence of

hormones, especially androgens, did not induce morphological sexual dimorphism in the lacrimal gland. On all tested components of the lacrimal gland, we showed that there is no statistically significant difference in volume density of acini, ducts, and connective tissue, and also no statistical difference in the mean length of the ductal system (intralobular and excretory ducts) in all three groups of mice. While there were no differences in the mean length of the ductal system (intralobular and excretory ducts) between all three groups, the total length of intralobular ducts was always surpassing one of the excretory ducts. Interestingly, the analysis showed a slight but not statistically significant difference ( $p=0,05824$ ) in the length of the excretory ducts of *Sf-1* KO males treated with testosterone before sacrifice (Figure 3). Previous research carried out on the rat parotid gland (Ježek et al., 1999) showed that there is a shortening of ducts on the 8<sup>th</sup> day after the orchietomy and this could be one of the first indicators of morphological changes of the gland due to lack of testosterone. It is possible that in our study, the substitution of T leads to the opposite effect, but further investigation is needed, perhaps with prolonged administration of TP.

Administration of testosterone for two weeks before the sacrifice of male mice induced the expression of androgen receptors in the nuclei of acinar cells while there was no expression of AR in the control group of males that did not receive testosterone. This confirms that androgens can induce and up-regulate their receptors as it has been reported before for other tissues. Thus, it seems testosterone has a considerable role in the ocular tissue, although the exact function of this hormone, acting through AR, is not yet understood (Rocha et al., 1993, 1994). As ARs were absent in the cells from mice without testosterone supplementation, it is plausible to speculate that perhaps extended treatment with testosterone would be needed to induce morphological changes in LG, as a certain period after the beginning of the treatment is needed only for the induction of AR expression.

Although animals used in this experiment were not aged when they were sacrificed (6 months), interestingly, during the qualitative analysis of histological slides of all three groups we found alterations in the morphology of glands often visible in senescent male mice. Some studies described metaplasia of acini and their transformation into Harderian gland-like structures (“harderization”), accumulation of gland ducts (“ductularization”), cytomegaly, karyomegaly, and cell and nuclear polymorphisms in some of the acinar cells. During the final stages of age-related transformations, lacrimal gland tissue is morphologically similar to the neoplasms and has neoplastic morphology but no other features of the tumour (Ríos et al., 2005; El-Fadaly et al., 2014; Goncharova and Manskikh, 2014). We also found areas of chronic inflammation with the accumulation of lymphocytes (especially around ducts) (figure 5), lipofuscin like inclusion and vacuolisation of acinar cells. Also, some of the acini exhibited enlarged lumina due to the reduced height of the acinar cells (Figure 6). The shape of these cells appeared cuboidal or even almost squamous, so they formed the structures much like “pseudofollicles” (Ježek et al., 1996). Morphological changes of the nuclei of acinar cells such as karyomegaly and nuclear polymorphisms were also found (Figure 7).

The causes of these age-related changes are not fully known and are probably multifactorial. Some studies demonstrated that the drop of circulating testosterone in ageing, with other factors like oxidative stress, immune or inflammatory mediated decrease in nerve function could cause such changes (Rocha et al., 2008). Thus, we can assume that observed changes in *Sf-1* KO mice might be, at least partially, a consequence of lack of T in adult life, whose one

of the role is to maintain the function of LG. Interestingly, these changes were also observed in the group treated with testosterone, and it would be interesting to see if such changes could be averted by lifelong supplementation of testosterone in *Sf-1* KO mice, but this was beyond the aim of this research and would require completely new study.

## Conclusion

In summary, sexual dimorphism in LG seems to be entirely dependent on the exposure to sex hormones as we did not observe sex differences in LG of *Sf-1* KO mice not exposed to sex steroid hormones. Administration of testosterone two weeks before sacrifice induced the expression of AR in the nuclei of the acinar cells in male *Sf-1* KO mice, but had no effect on the morphology of LG, possibly due to the short treatment period. *Sf-1* KO mice are very well suited to study genetic vs hormonal factors since the agenesis of testes or ovaries excludes the exposure to sex hormones both pre- and postnatally.

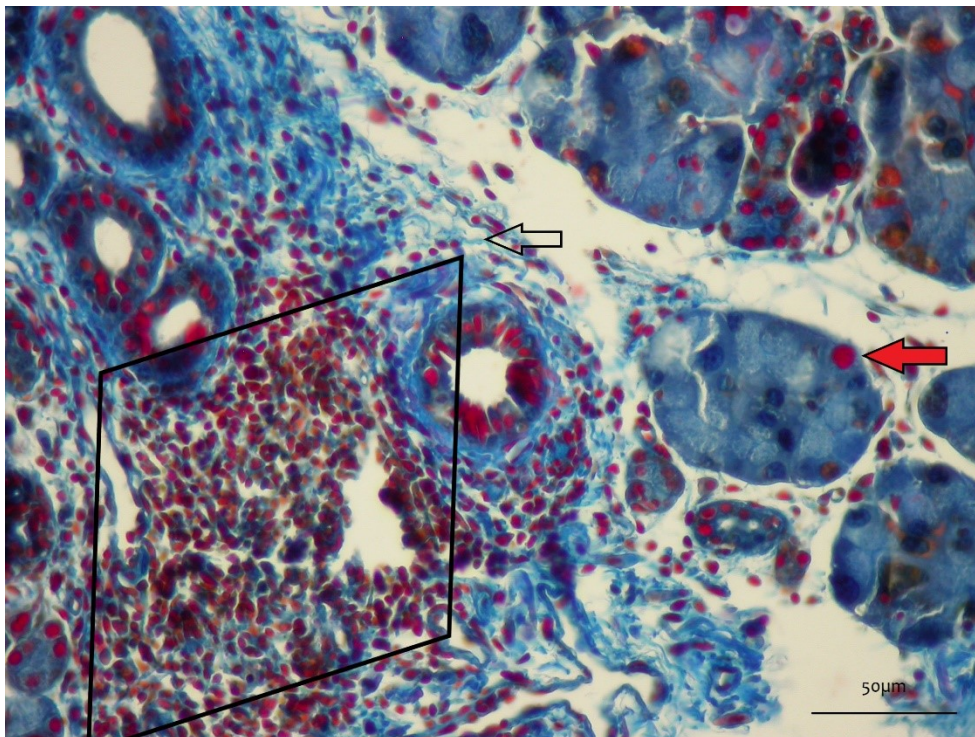


Figure 5. *Lymphocytic infiltration of periductal tissue in the rhombus on the extraorbital lacrimal gland (LG) sections stained with Azan method. An empty arrow is indicating the collagen fibres in blue in the connective tissue. Note the nucleus of the acinar cell (red arrow). Observation in magnification 40X, Bar 50μm*

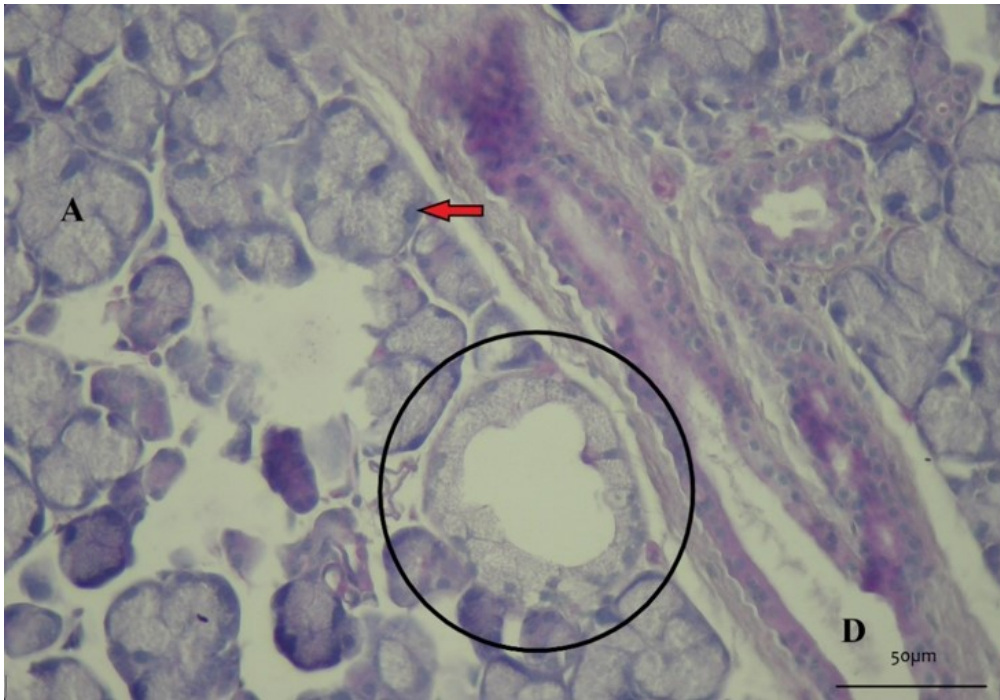


Figure 6. "Pseudofollicle" in the circle on the extraorbital lacrimal gland (LG) sections stained with PAS method. Note the nucleus of the acinar cells (red arrow), one acinus labelled with A and a longitudinal section of ductus (D). Observation in magnification 40X, Bar 50µm

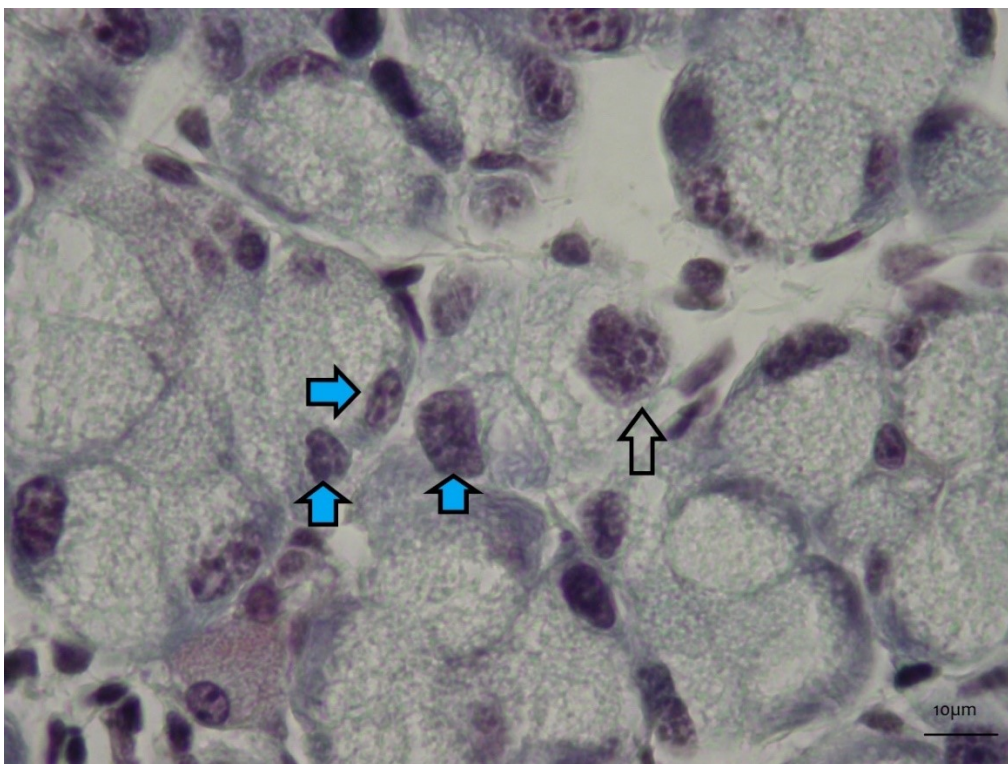


Figure 7. Nuclear polymorphism of acinar cells (blue arrows) and karyomegaly (empty arrow) on the extraorbital lacrimal gland (LG) sections stained with Masson method. Observation at 100X magnification, Bar 10µm

## References:

- Araujo, A.S.L., de Jesus Simões, M., Verna, C., Simões, R.S., Júnior, J.M.S., Baracat, E.C., Gomes, R.C.T., 2015. Influence of hyperprolactinemia on collagen fibers in the lacrimal gland of female mice. *Clinics*. [https://doi.org/10.6061/clinics/2015\(09\)07](https://doi.org/10.6061/clinics/2015(09)07)
- Azzarolo, A.M., Mircheff, A.K., Kaswan, R.L., Stanczyk, F.Z., Centschein, E., Becker, L., Nassir, B., Warren, D.W., 1997. Androgen support of lacrimal gland function. *Endocrine*. <https://doi.org/10.1007/bf02738800>
- Beauregard, C., Brandt, P.C., 2004. Down regulation of interleukin-1 $\beta$ -induced nitric oxide production in lacrimal gland acinar cells by sex steroids. *Curr. Eye Res.* <https://doi.org/10.1080/02713680490513227>
- Büdefeld, T., Grgurevic, N., Tobet, S.A., Majdic, G., 2008. Sex differences in brain developing in the presence or absence of gonads. *Dev. Neurobiol.* <https://doi.org/10.1002/dneu.20638>
- Büdefeld, T., Tobet, S.A., Majdic, G., 2011. Altered position of cell bodies and fibers in the ventromedial region in SF-1 knockout mice. *Exp. Neurol.* <https://doi.org/10.1016/j.expneurol.2011.08.021>
- Chrétien, M., 1977. Action of Testosterone on the Differentiation and Secretory Activity of a Target Organ: The Submaxillary Gland of the Mouse. *Int. Rev. Cytol.* 50, 333–369.
- Cornell-Bell, A.H., Sullivan, D.A., Allansmith, M.R., 1985. Gender-related differences in the morphology of the lacrimal gland. *Investig. Ophthalmol. Vis. Sci.*
- Crawford, P.A., Sadovsky, Y., Milbrandt, J., 1997. Nuclear receptor steroidogenic factor 1 directs embryonic stem cells toward the steroidogenic lineage. *Mol. Cell. Biol.* 17, 3997–4006. <https://doi.org/10.1128/mcb.17.7.3997>
- Doghman, M., Figueiredo, B.C., Volante, M., Papotti, M., Lalli, E., 2013. Integrative analysis of SF-1 transcription factor dosage impact on genome-wide binding and gene expression regulation. *Nucleic Acids Res.* 41, 8896–8907. <https://doi.org/10.1093/nar/gkt658>
- El-Fadaly, A.B., El-Shaarawy, E.A.A., Rizk, A.A., Nasralla, M.M., Shuaib, D.M.A., 2014. Age-related alterations in the lacrimal gland of adult albino rat: A light and electron microscopic study. *Ann. Anat.* <https://doi.org/10.1016/j.aanat.2014.06.005>
- Goncharova, O.S., Manskikh, V.N., 2014. [Age-related changes in the rat lacrimal gland: specific morphology and unknown nature]. *Ontogenez.* <https://doi.org/10.7868/s047514501405005x>
- Honda, S.I., Morohashi, K.I., Nomura, M., Takeya, H., Kitajima, M., Omura, T., 1993. Ad4BP regulating steroidogenic P-450 gene is a member of steroid hormone receptor superfamily. *J. Biol. Chem.*
- Ikeda, Y., Luo, X., Abbud, R., Nilson, J.H., Parker, K.L., 1995. The nuclear receptor steroidogenic factor 1 is essential for the formation of the ventromedial hypothalamic nucleus. *Mol. Endocrinol.* <https://doi.org/10.1210/mend.9.4.7659091>
- Ingraham, H.A., Lala, D.S., Ikeda, Y., Luo, X., Shen, W.H., Nachtigal, M.W., Abbud, R., Nilson, J.H., Parker, K.L., 1994. The nuclear receptor steroidogenic factor 1 acts at multiple levels of the reproductive axis. *Genes Dev.* <https://doi.org/10.1101/gad.8.19.2302>
- Jeyasuria, P., Ikeda, Y., Jamin, S.P., Zhao, L., De Rooij, D.G., Themmen, A.P.N., Behringer, R.R., Parker, K.L., 2004. Cell-specific knockout of steroidogenic factor 1 reveals its essential roles in gonadal function. *Mol. Endocrinol.* <https://doi.org/10.1210/me.2003-0404>
- Ježek, D., Banek, L., Jurić-Lekić, G., Grgić, M., 1996. Effects of orchietomy on the structure of the exorbital lacrimal gland acini in the rat - A histologic and morphometric study. *Vet. Arh.*
- Ježek, D., Banek, L., Pezerović-Panijan, R., Pezerović, D., 1999. Quantitative study on the rat

- parotid gland after orchietomy. *Vet. Arh.*
- Jiang, N., Ye, L.H., Ye, L., Yu, J., Yang, Q.C., Yuan, Q., Zhu, P.W., Shao, Y., 2017. Effect of mistletoe combined with carboxymethyl cellulose on dry eye in postmenopausal women. *Int. J. Ophthalmol.* <https://doi.org/10.18240/ijo.2017.11.06>
- Lacassagne A., 1940. Dimorphisme sexuel de la glande sous-maxillaire chez la souris. *Comptes Rendus des Seances la Soc. Biol. des ses Fil.* 133, 180–181.
- Lala, D.S., 1992. Steroidogenic factor I, a key regulator of steroidogenic enzyme expression, is the mouse homolog of fushi tarazu-factor I. *Mol. Endocrinol.* <https://doi.org/10.1210/me.6.8.1249>
- Li, L., Kang, Q., Wang, S., Zheng, X., 2015. Effects of androgen on ultrastructure of corneal epithelium and function of the tear film in BALB/c mice. *Cornea.* <https://doi.org/10.1097/ICO.0000000000000292>
- Luo, X., Ikeda, Y., Parker, K.L., 1994. A cell-specific nuclear receptor is essential for adrenal and gonadal development and sexual differentiation. *Cell.* [https://doi.org/10.1016/0092-8674\(94\)90211-9](https://doi.org/10.1016/0092-8674(94)90211-9)
- Luo, X., Ikeda, Y., Schlosser, D.A., Parker, K.L., 1995. Steroidogenic factor 1 is the essential transcript of the mouse Ftz-F1 gene. *Mol. Endocrinol.* <https://doi.org/10.1210/mend.9.9.7491115>
- Lynch, J.P., Lala, D.S., Peluso, J.J., Luo, W., Parker, K.L., White, B.A., 1993. Steroidogenic factor 1, an orphan nuclear receptor, regulates the expression of the rat aromatase gene in gonadal tissues. *Mol. Endocrinol.* <https://doi.org/10.1210/mend.7.6.8395654>
- Majdic, G., Young, M., Gomez-Sanchez, E., Anderson, P., Szczepaniak, L.S., Dobbins, R.L., McGarry, J.D., Parker, K.L., 2002. Knockout mice lacking steroidogenic factor 1 are a novel genetic model of hypothalamic obesity. *Endocrinology.* <https://doi.org/10.1210/endo.143.2.8652>
- McClellan, K.A., Robertson, F.G., Kindblom, J., Wennbo, H., Törnell, J., Bouchard, B., Kelly, P.A., Ormandy, C.J., 2001. Investigation of the role of prolactin in the development and function of the lacrimal and Harderian glands using genetically modified mice. *Investig. Ophthalmol. Vis. Sci.*
- Morohashi, K., Omura, T., 1996. Ad4BP/SF-1, a transcription factor essential for the transcription of steroidogenic cytochrome P450 genes and for the establishment of the reproductive function. *FASEB J.* <https://doi.org/10.1096/fasebj.10.14.9002548>
- Morohashi, K.I., Zanger, U.M., Honda, S.I., Hara, M., Waterman, M.R., Omura, T., 1993. Activation of CYP11A and CYP11B gene promoters by the steroidogenic cell-specific transcription factor, Ad4BP. *Mol. Endocrinol.* <https://doi.org/10.1210/mend.7.9.8247022>
- Peng, Q.H., Yao, X.L., Wu, Q.L., Tan, H.Y., Zhang, J.R., 2010. Effects of extract of *Buddleja officinalis* eye drops on androgen receptors of lacrimal gland cells of castrated rats with dry eye. *Int. J. Ophthalmol.* <https://doi.org/10.3980/j.issn.2222-3959.2010.01.10>
- Richards, S.M., Jensen, R. V., Liu, M., Sullivan, B.D., Lombardi, M.J., Rowley, P., Schirra, F., Treister, N.S., Suzuki, T., Steagall, R.J., Yamagami, H., Sullivan, D.A., 2006. Influence of sex on gene expression in the mouse lacrimal gland. *Exp. Eye Res.* <https://doi.org/10.1016/j.exer.2005.04.014>
- Richards, S.M., Liu, M., Jensen, R. V., Schirra, F., Yamagami, H., Lombardi, M.J., Rowley, P., Treister, N.S., Suzuki, T., Sullivan, B.D., Sullivan, D.A., 2005. Androgen regulation of gene expression in the mouse lacrimal gland. *J. Steroid Biochem. Mol. Biol.* <https://doi.org/10.1016/j.jsbmb.2005.04.037>
- Ríos, J.D., Horikawa, Y., Chen, L.L., Kublin, C.L., Hodges, R.R., Dartt, D.A., Zoukhri, D., 2005. Age-dependent alterations in mouse exorbital lacrimal gland structure, innervation and secretory response. *Exp. Eye Res.* <https://doi.org/10.1016/j.exer.2004.10.012>
- Rocha, E.M., Alves, M., Rios, J.D., Dartt, D.A., 2008. The aging lacrimal gland: Changes in

- structure and function. *Ocul. Surf.* [https://doi.org/10.1016/S1542-0124\(12\)70177-5](https://doi.org/10.1016/S1542-0124(12)70177-5)
- Rocha, E.M., Wickham, L.A., Da Silveira, L.A., Krenzer, K.L., Yu, F.S., Toda, I., Sullivan, B.D., Sullivan, D.A., 2000. Identification of androgen receptor protein and 5 $\alpha$ -reductase mRNA in human ocular tissues. *Br. J. Ophthalmol.* <https://doi.org/10.1136/bjo.84.1.76>
- Rocha, F.J., Alexandra Wickham, L., Pena, J.D.O., Gao, J., Ono, M., Lambert, R.W., Kelleher, R.S., Sullivan, D.A., 1993. Influence of gender and the endocrine environment on the distribution of androgen receptors in the lacrimal gland. *J. Steroid Biochem. Mol. Biol.* [https://doi.org/10.1016/0960-0760\(93\)90314-M](https://doi.org/10.1016/0960-0760(93)90314-M)
- Rocha, F.J., Kelleher, R.S., Edwards, J.A., Pena, J.D.O., Ono, M., Sullivan, D.A., 1994. Binding characteristics, immunocytochemical location and hormonal regulation of androgen receptors in lacrimal tissue, in: *Advances in Experimental Medicine and Biology.* [https://doi.org/10.1007/978-1-4615-2417-5\\_27](https://doi.org/10.1007/978-1-4615-2417-5_27)
- Sadovsky, Y., Crawford, P.A., Woodson, K.G., Polish, J.A., Clements, M.A., Tourtellotte, L.M., Simburger, K., Milbrandt, J., 1995. Mice deficient in the orphan receptor steroidogenic factor 1 lack adrenal glands and gonads but express P450 side-chain-cleavage enzyme in the placenta and have normal embryonic serum levels of corticosteroids. *Proc. Natl. Acad. Sci. U. S. A.* <https://doi.org/10.1073/pnas.92.24.10939>
- Sahai, A., Malik, P., 2005. Dry eye: Prevalence and attributable risk factors in a hospital-based population. *Indian J. Ophthalmol.* <https://doi.org/10.4103/0301-4738.16170>
- Sashima, M., Hatakeyama, S., Satoh, M., Suzuki, A., 1989. Harderianization is another sexual dimorphism of rat exorbital lacrimal gland. *Cells Tissues Organs.* <https://doi.org/10.1159/000146773>
- Schimmer, B.P., White, P.C., 2010. Minireview: Steroidogenic factor 1: Its roles in differentiation, development, and disease. *Mol. Endocrinol.* <https://doi.org/10.1210/me.2009-0519>
- Sekido, R., 2010. SRY: A transcriptional activator of mammalian testis determination. *Int. J. Biochem. Cell Biol.* <https://doi.org/10.1016/j.biocel.2009.12.005>
- Shen, J.H.C., Ingraham, H.A., 2002. Regulation of the orphan nuclear receptor steroidogenic factor 1 by Sox proteins. *Mol. Endocrinol.* <https://doi.org/10.1210/mend.16.3.0782>
- Shen, W.H., Moore, C.C.D., Ikeda, Y., Parker, K.L., Ingraham, H.A., 1994. Nuclear receptor steroidogenic factor 1 regulates the müllerian inhibiting substance gene: A link to the sex determination cascade. *Cell.* [https://doi.org/10.1016/0092-8674\(94\)90050-7](https://doi.org/10.1016/0092-8674(94)90050-7)
- Sullivan, D.A., Edwards, J.A., Wickham, L.A., Pena, J.D.O., Gao, J., Ono, M., Kelleher, R.S., 1996. Identification and endocrine control of sex steroid binding sites in the lacrimal gland. *Curr. Eye Res.* <https://doi.org/10.3109/02713689609007622>
- Sullivan, D.A., Wickham, L.A., Rocha, E.M., Kelleher, R.S., Da Silveira, L.A., Toda, I., 1998. Influence of gender, sex steroid hormones, and the hypothalamic-pituitary axis on the structure and function of the lacrimal gland. *Adv. Exp. Med. Biol.* [https://doi.org/10.1007/978-1-4615-5359-5\\_2](https://doi.org/10.1007/978-1-4615-5359-5_2)
- Suzuki, T., Schirra, F., Richards, S.M., Treister, N.S., Lombardi, M.J., Rowley, P., Jensen, R. V., Sullivan, D.A., 2006. Estrogen's and progesterone's impact on gene expression in the mouse lacrimal gland. *Investig. Ophthalmol. Vis. Sci.* <https://doi.org/10.1167/iovs.05-1003>
- Treister, N.S., Richards, S.M., Lombardi, M.J., Rowley, P., Jensen, R. V., Sullivan, D.A., 2005. Sex-related differences in gene expression in salivary glands of BALB/c mice. *J. Dent. Res.* <https://doi.org/10.1177/154405910508400210>
- Truong, S., Cole, N., Stapleton, F., Golebiowski, B., 2014. Sex hormones and the dry eye. *Clin. Exp. Optom.* <https://doi.org/10.1111/cxo.12147>
- Vanaken, H., Vercaeren, I., Claessens, F., De Vos, R., Dewolf-Peeters, C., Vaerman, J.P., Heyns, W., Rombauts, W., Peeters, B., 1998. Primary rat lacrimal cells undergo acinar-



like morphogenesis on reconstituted basement membrane and express secretory component under androgen stimulation. *Exp. Cell Res.* <https://doi.org/10.1006/excr.1997.3856>

Versura, P., Giannaccare, G., Campos, E.C., 2015. Sex-steroid imbalance in females and dry eye. *Curr. Eye Res.* <https://doi.org/10.3109/02713683.2014.966847>

Worda, C., Nepp, J., Huber, J.C., Sator, M.O., 2001. Treatment of keratoconjunctivitis sicca with topical androgen. *Maturitas.* [https://doi.org/10.1016/S0378-5122\(00\)00181-X](https://doi.org/10.1016/S0378-5122(00)00181-X)

Zhang, X., Vimalin Jeyalatha, M., Qu, Y., He, X., Ou, S., Bu, J., Jia, C., Wang, J., Wu, H., Liu, Z., Li, W., 2017. Dry eye management: Targeting the ocular surface microenvironment. *Int. J. Mol. Sci.* <https://doi.org/10.3390/ijms18071398>