

Trans-brachial approach as the first alternative to the trans-radial approach for coronary angiography

Gudelj, Lara

Master's thesis / Diplomski rad

2020

Degree Grantor / Ustanova koja je dodijelila akademski / stručni stupanj: **University of Zagreb, School of Medicine / Sveučilište u Zagrebu, Medicinski fakultet**

Permanent link / Trajna poveznica: <https://um.nsk.hr/um:nbn:hr:105:632680>

Rights / Prava: [In copyright](#) / [Zaštićeno autorskim pravom.](#)

Download date / Datum preuzimanja: **2025-04-01**



Repository / Repozitorij:

[Dr Med - University of Zagreb School of Medicine Digital Repository](#)



UNIVERSITY OF ZAGREB

SCHOOL OF MEDICINE

Lara Gudelj

**Trans-brachial approach as the first alternative
to the trans-radial approach for coronary
angiography**

GRADUATE THESIS



Zagreb, 2020.

This graduate thesis paper was completed at the Cardiology department at Sisters of Charity Hospital Zagreb under the supervision and guidance of doc.dr.sc. Matias Trbušić and it was submitted for evaluation in academic year 2019. /2020.

Mentor: doc.dr.sc. Matias. Trbušić dr.med.

ABBREVIATIONS

TRA trans-radial approach

TBA trans-brachial approach

TFA trans-femoral approach

ESC European Society of Cardiology

CAD Coronary artery disease

PCI Percutaneous Coronary Intervention

CABG Coronary artery bypass grafting

BMS Bare metal stents

DES Drug eluting stents

ISR In stent restenosis

ACD Arteriotomy closure device

Table of Contents

SUMMARY

SAŽETAK

3. PREFACE	1
3.1. ANGINA PECTORIS	1
3.2. STABLE ANGINA PECTORIS	3
3.3. ACUTE CORONARY SYNDROME.....	4
3.4. CORONARY ANGIOGRAPHY	6
3.4.1. Trans-femoral approach (TFA)	8
3.4.2. Trans-radial approach (TRA)	9
3.4.3. Trans-ulnar approach (TUA).....	11
3.4.4. Trans-brachial approach (TBA)	12
4. HYPOTHESIS	14
5. OBJECTIVES	14
6. MATERIALS AND METHODS	15
6.1. Procedure.....	15
6.2. Definition of complications.....	15
6.3. Statistical Analysis	15
6.4. Ethical approval.....	16
7. RESULTS	16
8. DISCUSSION	20
9. CONCLUSION	23
10. ACKNOWLEDGMENTS	24
11. REFERENCES	25
12. BIOGRAPHY	28

1. SUMMARY

Title: „Trans-brachial approach as the first alternative to the trans-radial approach for coronary angiography “

Author: Lara Gudelj

Objective: Trans-radial approach for coronary angiography is the most appropriate route for intervention due to its low risk of complications and adverse events. However, trans-radial approach has its own limitations and whenever radial access is not feasible, trans-brachial approach should be considered due to its similar benefit with forearm artery access. The aim of this study was to evaluate the efficacy and safety of trans-brachial approach for coronary angiography.

Methods: We retrospectively evaluated all cases of trans-brachial approach in our hospital at Cardiology department at Sisters of Charity Hospital from November 2012 to February 2020. 117 patients were included in this study.

Results: There were 117 procedures, 5 patients were excluded from the study due to incomplete data, 112 patients were left in the study with 98.21% success rate. There was only one major complication and one minor.

Conclusion: Brachial approach is safe and efficient alternative to trans-radial approach if performed by skilled operators who are experienced in arm approaches and if standardized post-procedure protocol is being used after the procedure.

Keywords: trans-brachial approach, coronary angiography,

2. SAŽETAK

Naslov: „Transbrahijalni pristup kao prva alternativa transradijalnom pristupu kod koronarne angiografije“

Autor: Lara Gudelj

Cilj: Transradijalni pristup kod koronarne angiografije je česta metoda koja se koristi zbog malog rizika komplikacija i nuspojava. Unatoč tome transradijalni pristup nije uvijek moguć i ima svoja ograničenja te se traže druga dostupna mjesta za intervenciju. Transbrahijalni pristup je dobra alternativa zbog sličnih pogodnosti u pristupu nadlaktičnoj arteriji.

Metode: U ovoj retrospektivnoj studiji pregledani su svi pacijenti kod koji je korišten transbrahijalni pristup na odjelu kardiologije u KBC Sestre Milosrdnice, u periodu od Studenog 2012. do Veljače 2020.

Rezultati: Ukupno je napravljeno 117 procedura, od koji je 5 pacijenata isključeno iz studije zbog nepotpunih podataka, u studiji je ostalo uključeno 112 pacijenata sa 98.21% uspjeha. Zabilježena je samo jedna velika komplikacija i jedna mala komplikacija.

Zaključak: Brahijalni pristup je sigurna i efikasna alternativa radijalnom pristupu ako ju izvodi vješti operater koji ima iskustva u pristupu iz ruke te ako se koristi standardizirani post-operativni protokol nakon intervencije.

Ključne riječi: transbrahijalni pristup, koronarna angiografija,

3. PREFACE

3.1. ANGINA PECTORIS

Angina pectoris is a clinical symptom that is the result of myocardial ischemia, occurring when there is imbalance of myocardial blood supply and oxygen demand. (1)

Angina pectoris can be sub classified into stable angina or angina on effort and unstable angina or acute coronary syndrome.

The most common cause of angina pectoris is atherosclerosis; other causes include aortitis, vasculitis and autoimmune connective tissue diseases. Other main causes can also include coronary artery spasm, syndrome X, aortic stenosis and hypertrophic cardiomyopathy. (1)

Coronary artery spasm

Coronary artery spasm can occur in patient with angina together with atherosclerosis or it can occur as an isolated phenomenon in less than 1% of patients. Prinzmetal angina is a term used for coronary artery spasm with transient ST elevation on ECG. (1)

Syndrome X

Syndrome X is classified as group of symptoms such as angina on effort, evidence of myocardial ischemia during stress testing while there are normal arteries during coronary angiography.

Furthermore, most of these patients are women and presenting symptoms are not specific, although this syndrome does respond to anti-angina therapy. (1)

Atherosclerosis

Atherosclerosis is the principal cause of Coronary artery disease (CAD) where changes appear within the walls of the coronary arteries. (1) Atherosclerosis is the principal cause of death among men and women causing approximately half of all deaths in the Western world. (2) Furthermore, it is defined as progressive chronic inflammatory disorder characterized by intimal lesions (atheroma's) that occlude vessel lumen and can rupture causing sudden thrombotic event. (1,2) Atheromatous plaques are elevated lesions which are made of soft lipid core mainly consisting of cholesterol, cholesterol esters

and necrotic debris while the outside of the lipid core is covered with fibrous cap. There are several modifiable risk factors that are the most common causes leading to atherosclerosis; such as hyperlipidemia or more specifically hypercholesterolemia both of which are enough to cause atherosclerosis even in the absence of other risk factors. Some other modifiable risk factors are hypertension, cigarette smoking and diabetes mellitus. Today the accepted theory of atherosclerosis views its pathogenesis through response- to- injury hypothesis. This hypothesis observes atherosclerosis as a chronic inflammatory process that occurs due to endothelial injury, the process consists of many steps (accumulation of lipoproteins, platelet adhesion, monocyte adhesion to lipoproteins, lipid accumulation within macrophages...) that all result in atheroma formation. Atherosclerotic plaques are at risk of undergoing several clinically important changes; rupture, erosion or ulceration which can lead to fatal thromboembolic events, rupture of fibrous cap can lead to intra-plaque hemorrhage which can subsequently cause hematoma that has increased chance of rupture. Risk of aneurysm formation occurs due to pressure of the media and loss of elastic tissue that structurally weakens the vessels wall making it prone to distention and rupture. Due to atherosclerosis vessel tries to preserve its lumen by remodeling, once the atheroma limits the blood flow it causes critical stenosis. This can occur gradually, but it can also occur due to acute plaque changes once the tissue demand is exceeded by its supply. Mostly, in coronary arteries this occurs once 70% of lumen is compromised. Acute plaque changes can be divided in three categories rupture, erosion or hemorrhage into the atheroma; all of them lead to thrombotic events that impinge total or partial vessel occlusion and tissue infarction. (2)

3.2. STABLE ANGINA PECTORIS

Stable angina or angina on effort is defined as chest pain that occurs during moderate exertion. (2)

Angina pectoris develops due to hemodynamically significant narrowing of coronary arteries that leads to myocardial ischemia. Symptoms of angina pectoris present once the coronary circulation can't maintain cardiac muscles need for oxygen; which causes ischemia and dysfunction of the left ventricle.

This usually manifests during exercise when the demand for oxygen is increased. Patients that suffer from chronic stable angina pectoris often experience symptoms of chest pain and dyspnea, usually during exercise or mild exertion and symptoms subside with rest or sublingual application of nitroglycerin. The most common cause of stable angina pectoris is atherosclerosis of one or more coronary arteries, affecting more than 50% of the vessel lumen. Stable angina pectoris can also be aggravated by endothelial dysfunction due to constriction of stenotic coronary arteries during exercise or stressful states. In patients with stable angina pectoris, coronary arteries usually have atherosclerotic plaques that don't completely obstruct coronary vessels. (3)

Silent myocardial ischemia is diagnosed when there are objective evidences of myocardial ischemia but in the absence of angina symptoms. (4)

Silent myocardial ischemia is frequent in patients with stable angina pectoris, it can manifest even during the night and while the patient is resting. In diseases and conditions where there is increased demand for oxygen; anginal symptoms occur during small exertions and during the rest. Some of these conditions are thyrotoxicosis, significant anemia, supraventricular tachycardia (SVT), aortic stenosis (AS). (3)

Main goals in treatment of stable angina pectoris are to reduce the frequency of anginal attacks, to increase the tolerance to exercise without anginal symptoms and to reduce the risk of major negative events such as unstable angina, sudden death caused by myocardial ischemia and myocardial infarction.

(3) The mainstay therapy in treatment of stable angina consists of acetylsalicylic acid with antianginal drugs, beta-blockers and antihypertensive drugs, recommendation for smoking cessation, diabetic therapy and diet change as well as recommendation for daily exercise. (3) Once the medication therapy and lifestyle changes aren't enough to decrease angina symptoms, invasive methods are considered. The aim of invasive methods is to open the coronary arteries, permit free blood flow to cardiac muscle and avoid ischemia. Revascularization of myocardial tissue can be achieved through percutaneous coronary

intervention (PCI) that dilates coronary vessel or with the cardiosurgical method of coronary bypass surgery (CABG). (3) In new guidelines stable angina is today referred as chronic coronary syndrome but since this is a retrospective study we used old classification. (5)

3.3. ACUTE CORONARY SYNDROME

Acute Coronary Syndrome is defined as condition that describes acute myocardial ischemia, it encompasses unstable angina and acute myocardial infarction. Unstable angina is distinguished as angina during rest without myocardial damage, rapidly progressing angina (crescendo angina) and angina on minimal exertion. (1) Myocardial Infarction is different from unstable angina by the presence of myocardial necrosis. Acute Coronary Syndrome can present in patient that have no previous history of cardiac disease as well as in patients that suffer from chronic stable angina. Within the diagnosis of Myocardial infarction (MI) patients can be subclassified based on their early ECG changes into unstable angina pectoris or Non-ST-Elevation Myocardial Infarction (NSTEMI) and ST-Elevation Myocardial Infarction (STEMI). (6) This classification is important because it determines the method for the acute treatment. (6) Furthermore, values of specific cardiac enzymes are also used to determine diagnosis and protocol of treatment. Cardiac enzymes most commonly used are Creatine Kinase (CK) or more specifically ratio of CK and its MB fraction or cardiac troponin T or I (CTnT, CTnI). High values of troponin are a sensitive reflection of myocardial necrosis, so from those values we can conclude that patient is suffering from myocardial infarction. (6) Some of the risk factors that suggest poor prognosis in patients with Acute coronary syndrome are extensive ECG changes during pain or at rest, recurrent ischemia, raised troponin T or I, arrhythmias, hemodynamic complications during episodes of ischemia. (1) Troponins are highly cardio-specific and very sensitive markers of myocardial necrosis. (6) Acute coronary syndrome is the most common cause of deaths all around the world and it is estimated that every minute in USA one person dies from coronary artery disease while in one year 47% of people will die due to acute coronary event. (6) In Croatia, cardiovascular diseases especially coronary artery diseases are leading cause of death, it is estimated that more than 50% of population mortality is due to coronary artery diseases. (6) Most common pathogenesis of acute coronary syndrome is atherosclerosis; the culprit lesion occurs on complex ulcerated or fissured atheromatous plaque that has adherent platelet-rich thrombus and adjacent coronary artery spasm. (1) Sudden injury or rupture of atheromatous plaque

leads to formation of thrombus that can incompletely or completely close coronary artery causing ischemia, if the vessel obstruction is not removed promptly it causes myocardial necrosis to occur. (6) In acute coronary syndrome vascular changes are dynamic so the degree coronary artery obstruction can increase.(1) Specific atheromatous plaques are more prone to rupture, these vulnerable plaques have bigger part of lipid core, thin fibrous cap and emphasized inflammatory cells in fibrous cover and adventitia. (1) They are expanding towards adventitia during the process of positive remodeling, due to their thin fibrous cap they are more prone to rupture. (6) Acute coronary syndrome is an emergency, so the accurate initial diagnosis is of the utmost importance. (6) It is essential to recognize the clinical picture and ECG changes which should be enough to make the right diagnosis, without waiting for laboratory indicators of myocardial necrosis. (6) In patients with acute coronary syndrome ECG changes can categorize patients in two main categories; those with ST elevation (STEMI infarction) and those without ST elevation (NSTEMI infarction) which can be with high levels of troponin and/or CK-MB or without when we are talking about unstable angina. Patients with ST elevation that have high levels of troponin and/or CK-MB can be subdivided into those that have q wave present on their ECG and those that don't. (6) Along with clinical picture and ECG changes, physician should also take into consideration patients family history of coronary artery diseases as well as patients risk factors such as hyperlipidemia, smoking, hypertension, diabetes and obesity. (6) Final diagnosis of acute myocardial infarction is made after the laboratory test are analyzed and by that time there is usually clear sign of q wave that indicates presence of myocardial necrosis. (6) Cardinal symptom of acute coronary syndrome is chest pain at rest, but breathlessness, vomiting and collapse can also be seen. (1) Chest pain can appear as burning pain, dull pain or discomfort located in the middle of the chest behind the sternum. (6) Pain can sometimes radiate to neck, arms (most commonly left arm and shoulder) or it can also be perceived as tingling and numb pain in lower jaw, or less commonly it can radiate to back or epigastrium. (6) Sometimes symptoms of acute coronary syndrome can be precipitated by stress, physical exertion and emotional trauma or sometimes they can occur without any cause. (6) In case there is massive ischemia of myocardium it can lead to heart failure, pulmonary edema and cardiogenic shock. (6) Since the process of acute MI progresses over several hours, most patients will present during the time frame when it is still possible to salvage the myocardium, although in 20-30% of patients that don't receive treatment,

artery will remain permanently occluded. (1) Main goal in treatment of patient with STEMI infarction is recanalization of occluded coronary artery, this can be accomplished through fibrinolysis or with PCI (percutaneous coronary intervention). European Society of Cardiology (ESC) is recommending primary PCI as treatment of STEMI infarction in first 90 minutes from the start of the symptoms. Primary PCI is safe and cost-effective procedure with better post-procedure reperfusion of coronary artery and lower rate of intracranial bleedings and other hemorrhagic incidents. (6) Fibrinolysis is indicated in guidelines of ESC to all patients with symptoms of acute coronary syndrome with ST elevation or newly established left bundle branch block, fibrinolysis should also be given to all patients undergoing PCI that can't be performed within 90 minutes. (6) In ESC guidelines there are four fibrinolytics that are recommended for use these are; streptokinase, alteplase, reteplase and tenecteplase, in Croatia most commonly used is streptokinase and rarely alteplase. (6) Treatment of NSTEMI infarction depends on grading of risk factors, so patients at higher risk would be the ones that have high levels of troponin as well as ischemic changes on ECG especially ST depressions. Depending on patients' symptoms and history of ischemic episodes, physicians will decide if the patient is eligible for urgent primary PCI or if he should be treated with medications. (6)

3.4. CORONARY ANGIOGRAPHY

Coronary angiography is a procedure that gives us information about coronary arteries that supply the heart, in this procedure radiopaque contrast is injected into coronary arteries and their anatomy is seen on x-ray pictures that are being continuously taken. Coronary angiography has significantly reduced mortality from cardiovascular diseases especially from coronary artery diseases. Charles Theodore Dotter was a father of interventional radiology who on 16th of January 1964 with his trainee Melvin Judkins performed first intentional transluminal angioplasty on short segmental stenosis of the superficial femoral artery. (7) First successful percutaneous transluminal coronary angioplasty was performed in 1977. by Andreas Gruentzig on a patient with stable angina and severe stenosis of the proximal left anterior descending (LAD) artery. After the balloon catheter was inserted into occluded coronary artery the blood flow was restored and there was no residual stenosis or recurrent angina. (8) Soon after, American cardiologist Geoffrey Hartzler demonstrated feasibility of coronary angioplasty in treatment of acute MI. (8) History of percutaneous coronary interventions and stents began in 1986.

when Siegart et al. introduced first bare metal stent (BMS) into human coronary artery. (9) In 1994. Palmaz-Schatz stent was developed by US Food and Drug Administration and it was first balloon-expandable intracoronary device, it had metal mesh that protected from restenosis and re-occlusion following primary coronary intervention. (8) Due to development of neointimal hyperplasia at the site of stent placement and resulting progressive luminal narrowing in 10-40% of patients by 6 months, patients needed to undergo revascularization. (8) To avoid unnecessary procedures antiproliferative drugs were coated onto bare metal stents, first generation of drug eluting stents (DES) were obtainable in USA in 2003.,2004., the Cypher sirolimus-eluting stent and Taxus paclitaxel-eluting stent. (8) The newer generations of drug eluting stents are continuously evolving with thinner stent struts and newer anti-proliferative drugs, which reduce even more stent thrombosis and in-stent restenosis. (8) Second-generation of drug- eluting stents especially everolimus-eluting stents have shown to be more effective and safer. (10) However in case of in-stent restenosis treatment with drug-eluting stents (DES) has poorer prognosis than with bare metal stents (BMS). (10) Drug-eluting balloons emerged as an alternative in treatment of patients with drug eluting stents and in-stent restenosis (DES-ISR) and for patients with bare-metal stents and in-stent restenosis (BMS-ISR). (10) Drug-eluting balloons (DEB) have shown promising results in treatment due to their high dose administration of antiproliferative drugs to arterial tissue without permanent stent placement. (11) In retrospective non-randomized clinical trial that collected patients from main clinical centers in Croatia that underwent percutaneous coronary intervention with drug-eluting balloons from February 2011. to January 2014., demonstrated excellent results in treatment of patients in most cases with in-stent restenosis. (11) There are four main sites for arterial access for percutaneous coronary intervention these are; femoral artery, radial artery ulnar artery and brachial artery.

3.4.1. Trans-femoral approach (TFA)

Femoral artery approach is considered to be classical approach for coronary angiography and intervention because it is well established with a long history of experience which is the reason why it is still preferred access route for some clinicians. (12,13) In the 1970s femoral artery access became the main approach route for coronary angiography and intervention because guiding catheters used at the time were large and they required large lumen arterial access. (13) Owing to its large lumen and the fact that it was easily palpable, and it enabled easy access which resulted in femoral artery being the primary site for coronary angiography. Considering its long history of use, possible complications are well known as well as their management. Some of the most common complications possible with transfemoral access are hematomas, arteriovenous fistulas, arterial pseudoaneurysms and retroperitoneal hemorrhage. (12) Usual technique to induce hemostasis is through manual compression but to secure it for femoral artery access in 1995 first arteriotomy closure devices (ACD) were introduced to decrease vascular complications and diminish the time to hemostasis and ambulation. (14,15) Since then several generations of active and passive arteriotomy closure devices were introduced with different mechanisms of action to achieve faster hemostasis. Although arteriotomy closure devices (ACD) reduce mortality, shorten the time to hemostasis, increase patient satisfaction and comfort and shorten the duration of observation they still pose the risk of severe groin infections, embolization of devices and collagen material. Even though these complications are rare they still represent risk and they should be considered in each individual patient. (15) Moreover, arteriotomy closure devices increase the price of the entire intervention which creates a problem especially in countries with lower BDP. Before obtaining femoral access its safety should ideally be checked by ultrasound of femoral artery, fluoroscopy, micro puncture access and femoral angiography. (16) Preferred femoral artery access route is in common femoral artery above femoral bifurcation and below hypogastric artery. (14) Although femoral artery access has higher rate of complications and radial artery access is in increased use worldwide, femoral artery remains necessary route for many procedures that require large-bore needle access. (16) Femoral artery access is still used in most cases

that require mechanical circulatory support, transcatheter aortic valve replacement, high-risk PCI with devices like Impella, intra-aortic balloon pump and venoarterial extracorporeal membrane oxygenation. (16)

Table 1. Pros and cons of trans-femoral vs. trans-radial approach

PROS	CONS
Large lumen of artery	High bleeding risk
Easily palpable and easy access	Longer hospital stays
Long history of successful approach	Risk of clot formation and pseudoaneurysm
	Higher procedure cost
	Retroperitoneal bleeding/ Risk of death
	Uncomfortable for patient

3.4.2. Trans-radial approach (TRA)

Radial access for coronary angiography was first described by Lucien Campeau in 1989., he postulated that radial artery approach can be free of any significant complications due to dual blood supply of the hand as well as the fact that anatomically there are no major nerves or veins near the puncture sight. This approach became possible with invention of small French 5 introducer sheaths and pre-shaped catheters. (17) Report included first 100 patients that were subjected to radial artery access, it was performed only in patients with patent ulnar artery which was tested before the procedure with Allen’s test. They concluded that although radial artery was more difficult to puncture and cannulate, the failure rate should decrease with experience in this approach. Only significant complications they encountered were arterial dissection in one patient and radial artery occlusion in one patient but without hand ischemia. Although radial artery occlusion is more common with this approach due to smaller diameter of radial artery due to dual blood supply with ulnar artery and presence of palmar arches hand ischemia is prevented. (17) Radial access for percutaneous transluminal coronary angioplasty and stenting was further improved upon by Kiemeneij and Laarman. (18) Increased interest in trans-radial approach relates to many benefits that this approach offers, most importantly vascular complications are greatly reduced, it is convenient for patients, it allows shorter hospitalization, immediate immobilization of patient and earlier discharge. Lower rate of vascular complications is associated with already mentioned favorable anatomy, smaller sheaths

and faster hemostasis. Even though bleeding complications are minor when they occur radial artery access allows easy compressibility of radial artery. Furthermore, this approach is associated with high success rate. (19) Radial artery access is beneficial also for hospitals that decrease their expenditures due to shorter hospitalizations after the procedures. (19) On the other hand, there is a longer learning curve making it more difficult for operator, entry site failure is possible, it limits the devices used in interventions that require large vessel access and it may not be the best option for patients with anomalous palmar arch. (19) In a comparative study that included 400 patients over a period of 2 years and 2 months, where half of the patients underwent femoral artery approach and other half radial approach; results were in favor of radial access. Although there was a higher time requirement for radial access due to abnormal radial artery anatomy, tortuosity of subclavian arteries, spasm of radial artery that can be prevented with vasodilators, still complication rate was lower than in femoral group. Most common complications were puncture site ecchymosis in femoral group 20.5% and in radial group 12.5%. (19) The biggest concern when performing catheterization through radial artery is gaining access, given the smaller diameter of radial artery and its tendency to spasm, sometimes it is harder to place the sheath. Cohort study that retrospectively evaluated patients that underwent coronary catheterizations in period of one year focused on alternative arterial access after radial artery cannulation failure. (20) In this research after radial access failure, alternative access site was contralateral radial artery, ipsilateral ulnar, contralateral ulnar and femoral artery. They concluded that forearm arteries can be used as an alternative to femoral artery once radial access fails if performed by experienced forearm interventionalist. (20) Another limitation of trans-radial approach are anatomical variations, in a clinical study done in Chinese population alternative site after radial access failure that occurred in only 3.4% of patients was contralateral radial artery, brachial artery or femoral artery. (21) From this research we can see that radial artery variations are common and make an important limitation in trans-radial access but this can be overcome with alternative access and selection of appropriate instruments and tips. (21)

When comparing radial and femoral artery access it is evident that since the femoral artery is large-caliber vessel its risk of bleeding complications and complications of hemostasis are higher. (14) In

comparison to femoral access which usually requires vascular closure devices, in radial access hemostasis consists of compressive bandages and devices that mimic manual compression. (16) Finally, today radial artery access is considered to be the first choice in coronary angiography and intervention due to its low risk of bleeding and complications, although due to possibility of failure of radial artery access alternative forearm accesses that have same benefits as radial artery access have to be considered.

Table 2. Pros and cons of trans-radial vs. other approaches

PROS	CONS
Faster hemostasis	More common occlusions
Dual blood supply of the hand	Longer learning curve
Superficial artery (negligible risk of pseudoaneurysm, AV fistula and nerve damage)	Difficult to manipulate with catheter in case of tortuosity of supra-aortic trunk
Better patient comfort, shorter hospitalization	Risk of spasm
More casual administration of anticoagulation medications	Impossible to insert catheter sheets bigger than 6-7 French units
Reduces mortality	Difficult to manipulate catheter and puncture artery in patients in shock

3.4.3. Trans-ulnar approach (TUA)

Trans-ulnar approach has emerged as an alternative access site to trans-radial and trans-femoral approaches due to its safety and feasibility. Several studies have investigated trans-ulnar route either as an alternative to radial artery or after its failure to puncture or as alternative to femoral access. One of these studies after radial artery cannulation failure proceeded with alternative sites cannulation; using contralateral radial, ipsilateral ulnar, contralateral ulnar and femoral approach. (20) They have concluded that use of other forearm arteries facilitates decreasing rate of trans-femoral access during cardiac catheterizations with reduces access site complications and subsequently reduces mortality. (20) Furthermore, utilization and safety of ulnar artery for coronary angiography and PCI was demonstrated in study that collected 97 patients that underwent coronary angiography (81 patients) and PCI (16 patients) via trans-ulnar route. (22) Out of all 97 patients none suffered from major complications and 5 patients experienced grade 1 hematoma over ulnar artery region that subsided with local compression, bandage and oral analgesics and all 5 were discharged the next day. (22)

Another study that compared trans-radial and trans-ulnar approach revealed positive aspect of ulnar artery due to less cases of anatomic variations in comparison to radial artery as well as larger size of ulnar artery which prevents arterial spasm. Moreover, this study demonstrated that there were no significant differences in minor complications like paresthesia/pain and hematoma between trans-radial and trans-ulnar approach nevertheless radial artery showed significantly higher incidence of radial artery occlusion and spasm. (23) On the other hand, although there are less cases of spasm with ulnar artery compared to radial artery; spasm of radial artery is also beneficial for the whole procedure since it reduced the bleeding from radial artery. It is also important to mention that compared to other arteries used for catheterization ulnar artery is hard to palpate and difficult to puncture, which is the reason why most cardiologist don't use it as first alternative to radial artery approach.

Table 3. Pros and cons of trans-ulnar approach

PROS	CONS
Same as for radial artery	Difficult to palpate
	Difficult to puncture
	Risk of ischemia if radial artery is occluded

3.4.4. Trans-brachial approach (TBA)

As already mentioned, radial access failure can sometimes occur, and we are in search of an alternative access that offers us the same advantages and benefits as radial artery access with lesser risk of bleeding than femoral artery access. Radial approach is not always possible due to small diameter of radial artery, tortuosity, anatomic variants, abnormal origin of radial artery, stenosis of radial artery, hypoplasia's. (21) Whenever radial access is not possible brachial artery access should be a preferred route due to its beneficial forearm artery access instead of femoral artery. Still most clinicians perceive brachial angiography as obsolete and hazardous and rather choose femoral route due to complications that brachial approach can cause. One of the studies presented brachial coronarography as dangerous due to unacceptably high complication rate of 36% . (24) In this study 55 patients underwent percutaneous brachial coronary angiography and in all of them there was a contraindication for femoral route. Out of 55 patients, in 46 patient's (84%) procedure was successfully completed, in 9 patients (16%) there was failure to complete procedure due to failure to

obtain access (two patients), brachial artery spasm (one patient), brachial/subclavian tortuosity (two), dissection of brachial artery (two), inability to intubate a vein graft (two); and in 6 patients access from alternative route was required. (24) Complications have occurred in 20 patients; 3 patients suffered from major complications and 17 from minor. From major complications there was false aneurysm that required surgical repair in one patient, hematoma with clinical median nerve dysfunction that lasted one month and large brachial hematoma that required surgical exploration and arterial repair. On the other side, minor complications that presented were weakness of radial pulse that required overnight stay for observation (two patients), brachial artery dissection without clinical sequelae (two), brachial artery spasm terminating procedure (two), wound oozing necessitating overnight stay (two), wound oozing in self-presentation to emergency room next day (one), need for repeat coronary angiography with alternative approach (six), significant hematoma over brachial artery without clinical sequelae (three), transient ischemic attack (one), postprocedural aneurysmal dilatation of brachial artery (one). (24) It is important to also mention that out of these patients two of them suffered from more than one minor complication. However, even though authors of this study have concluded that complications from brachial angiography are unacceptable they still emphasize that one of the limitations in their study was that operators that performed these procedures were only occasional brachial approach operators and they were experienced femoral operators. They have concluded that brachial approach is hazardous procedure when performed by occasional brachial operators, and people that require forearm approach for coronary angiography should be referred to specialist that are experienced in radial and brachial approach which will reduce complication rate. (24) Therefore, since brachial artery has many advantages for coronary catheterization the complications can be diminished if used and performed by clinicians that are experienced in arm approaches. Furthermore, in the first randomized clinical trial that compared radial, brachial and femoral approach (The Access Study) for percutaneous transluminal coronary angioplasty it demonstrated that there were no entry site complications in radial access group, while in brachial access group 2.3% had major complication and 2.0% in femoral group. (18) However, the study done in single-center Macau in China demonstrated the feasibility and safety of brachial approach which was conducted after trans-radial approach wasn't possible. Although, this study had only 25 patients that underwent brachial artery

approach compared to 118 cases of TFA, success rate of TBA was 96.2% with only two vascular complications (one major and one minor) while there were four cases of vascular complications (one minor and three major) in trans-femoral group. (25)

4. HYPOTHESIS

It was hypothesized that brachial artery approach can be safe and effective first alternative to radial access due to its many advantages over femoral artery access when performed by experienced trans-radial cardiologists.

5. OBJECTIVES

The aim of this study was to demonstrate effectiveness and feasibility of trans-brachial approach (TBA) for percutaneous coronary intervention in patients in whom trans-radial approach (TRA) is not possible. In this retrospective case series, we wanted to present our results of using trans-brachial approach as the first alternative to trans-radial approach when radial access isn't feasible. Radial artery access is well-established approach that is even recommended by European Society of Cardiology with several studies that are proving its safety and efficacy, it ensures lower risk of bleeding and other vascular complications compared to femoral approach. (26) However, there is a possibility of unsuccessful trans-radial approach due to anatomic vascular anomalies (tortuosity, hypoplasia, stenosis, radioulnar loop, abnormal origin of radial artery), radial artery spasm or dissection and calcified atherosclerosis of radial artery. Subsequently, in these situations different approach is necessary and while many physicians will choose trans-femoral approach because they are well trained and experienced in this approach, trans-brachial approach should be considered as an equal alternative. It should also be emphasized that trans-radial cardiologist that are well-trained in that approach and have high success rate are used to radial artery access and are rarely using femoral approach in their day to day practice so for them brachial artery approach is easier and more suitable first alternative. Considering that there are confounding results that are presented when it comes to complication rates of trans-brachial approach, we decided to investigate and demonstrate results of brachial artery approach for coronary angiography and intervention at our center.

6. MATERIALS AND METHODS

In this retrospective study we collected all the cases that underwent diagnostic coronary angiography and coronary intervention from August 2012 to February 2020. All the data was collected from our hospital databases and medical records. There was total of 116 patients included in this study.

6.1. Procedure

Patient's elbow is slightly hyperextended, sterile preparation with a povidone-iodine solution is applied, the right or left brachial artery is cannulated with a needle using percutaneous transluminal technique. Angle of needle insertion was 45 degrees. After that, a guidewire was advanced into the brachial artery lumen and introducer sheath followed. It has to be mentioned that the material we used was trans-radial access kit: Radial Source (Cordis) (sheath 6F/10 cm and 0.014" bare metal spring wire). After sheath insertion, an initial bolus of 5000 IU of unfractionated heparin and a spasmolytic cocktail of 5 mg of verapamil were routinely administered. Catheters were used based on operator's choice. After the procedure, patients were transported back to the ward. The arterial sheath was removed 6 hours after the procedure if coronary intervention was performed or 3 hours after diagnostic coronary angiography. Direct manual pressure was applied to brachial artery for 10 minutes, after hemostasis was secured, further local pressure was provided by elastic bandages for 2 hours. Patients were advised to restrict movements of the hand, especially elbow, and bed rest for additional 6 hours.

6.2. Definition of complications

Entry site complications were divided into major and minor complications. Major vascular complications were defined as major bleeding event that required blood transfusion and vascular complications that required surgical vascular repair, vessel occlusion, or loss of pulse as well as permanent neurological deficit in the arm. Minor vascular complications include small subcutaneous hematoma (less than 10 cm), pseudoaneurysm or arteriovenous fistula.

6.3. Statistical Analysis

Since this is retrospective case series in which we had small group of patients we didn't do complicated statistical analysis only descriptive statistical analysis. Also this was simply used to present our cases with their success rate and low complication rate so control group wasn't used because we know that radial approach is the best approach for coronary angiography and intervention

but we wanted to describe that brachial artery approach is the best first alternative to radial access. To demonstrate results chi squared test was used and everything was done in SPSS statistics program.

6.4. Ethical approval

Permission to conduct this study was obtained from ethical committee, since this is a retrospective study, ethical approval was obtained prior than conducting this study.

7. RESULTS

5 patients were excluded from the study due to incomplete data (more than 20% was missing). There were 111 patients left in the study. Median patient age was 69 years with interquartile range (1.-3.) 63-78 years. In this study there was 70 male patients (63%) included and 41 women (27%) patients. From these patients 17 (15%) were active smokers, 43 patients (39%) used to smoke before and 51 (46%) never smoked in their life.

49 patients suffered from diabetes (44%) and 64 patients (58%) from dyslipidemia.

91 patients (82%) were diagnosed with hypertension.

During the procedures median expenditure of contrast was 122 mL with interquartile range (1.-3.) 76-176 mL.

Median consumption of radiation was 2490 cGycm with interquartile range 81.-3-) 1118-5883 cGycm.

From 117 patients only one patient suffered from major complication he developed arterial thrombosis.

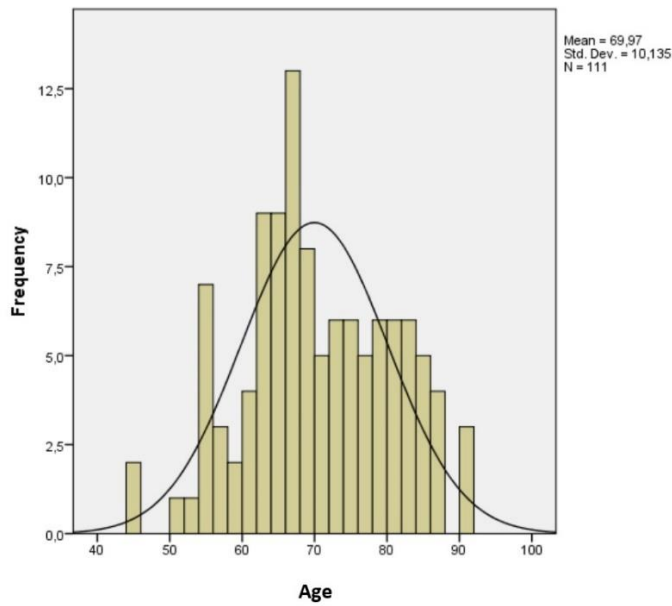


Figure 1.

This figure demonstrates that median age of patient’s male and female was 69 years of age, which means that most patients undergoing trans-brachial coronary procedure were around 70 years of age.

Reason for PCI

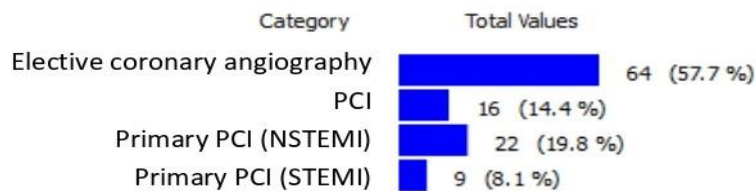


Figure 2.

In this figure we can see that more than 57 % of patients undergoing trans-brachial approach coronary angiography and intervention were scheduled for elective coronarography. There were 22 patients (19.8%) that had NSTEMI and 9 patients (8.1%) with STEMI and they were treated with trans-brachial coronary intervention.

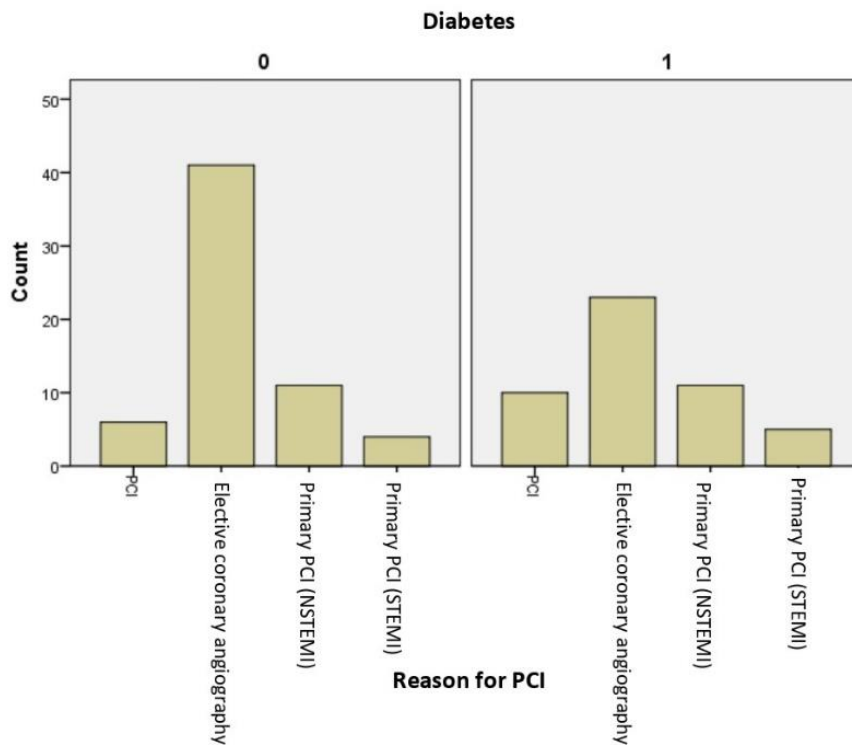


Figure 5.

Difference in frequency of diabetes mellitus in category of indications

It is interesting that there is statistically significant difference in frequency of diabetes mellitus in category of indications (there is by far more cases of diabetes mellitus in acute myocardial infarction cases than in cases that underwent elective coronary angiography 21/41 vs 26/23), what is to be expected. χ^2 4.13, P=0.042.

Because diabetes mellitus is a metabolic disorder its many adverse effect of vasculature and metabolic factors result in reported restenosis rates in diabetic patients being 47% as compared to non-diabetic patients. Also it should be emphasized that restenosis process will more often result in complete occlusion, MI and ventricular dysfunction in diabetic than non-diabetic patients. (27)

Since $P < 0.05$ we consider these results statistically significant. From which we can conclude that our results confirm our hypothesis that brachial approach for coronary angiography and intervention should be used as a first alternative to radial approach.

8. DISCUSSION

Results that we have presented show that brachial artery approach is effective and feasible alternative to radial artery approach with many advantages in comparison to femoral artery approach such as early ambulation, positive feedback from patients and availability in aortoiliac disease. There were two instances when brachial artery approach was used, either when there was weak or absent radial pulse (primary trans-brachial approach) or after unsuccessful radial artery puncture. In addition to weak or absent radial pulse primary trans-brachial approach was performed also in patients in whom it was proven by ultrasound that diameter of radial artery was small, when radial artery was used for CABG and when due to tortuosity of subclavian artery or aorta catheters were too short. Brachial artery approach was performed by skilled clinicians that were well-trained in trans-radial approach. Since brachial artery is more anatomically like radial artery by its size and depth at which it is located than femoral artery, when performed by cardiologists with high trans-radial success rate it is a more advantageous approach. Furthermore, one of the reasons why we have low complication rate could be the fact that we used material intended for radial artery puncture and accurate puncture technique was performed with gentle, delicate maneuver of catheter. When observing complications, it is important to emphasize that there was only one case of major complications where patient developed arterial thrombosis. Patient started to feel some discomfort and pain in the arm few days after the intervention. He was admitted to vascular surgery department due to subacute arterial thrombosis and he was well recovered after surgical thrombectomy was performed. After surgical thrombectomy patient was well recovered without any consequences. Although he was feeling pain in the arm, he didn't report it promptly to nurses and doctors which is why they didn't react to it at that time. When observing this case, possible cause for arterial thrombosis in this patient could be the fact that during the period when he had elastic compression on his arm after the intervention, he experienced pain, he was holding elastic compression for two hours as it was protocol in other patients. In future it would be recommended to follow up patients such as this patient to prevent subsequent complications. On the other hand, we had one minor complications, where patient developed hematoma that resolved in few

weeks. There were no cases where blood transfusion was required and no cases with transient or permanent puncture-related neurological deficits in the arm.

Moreover, this research also put in light the fact that there was statistically significant incidence of diabetes mellitus in patients with acute myocardial infarction. Which can be explained due to endothelial dysfunction in diabetic patients and prothrombotic state that puts them in greater danger for and acute event. In these patients their unique pathophysiological response to arterial injury has immense effect on outcome of percutaneous coronary intervention. (27) It is interesting that in acute myocardial infarction group as well as in group of patients undergoing elective coronarography there was high percentage of patients with myocardial infarction, 21 vs 26. Which means that 42% of patients enrolled in this study had diabetes mellitus. We could speculate that this could be due to the fact that patients with diabetes mellitus more commonly lose radial artery. But we haven't found specific information in literature that state that diabetic patients have more commonly occluded radial artery which would immediately make them more suitable for alternative approach.

In the observed literature, there are reports of frequent complications after trans-brachial coronary angiography, while our series showed relatively low incidence of complications. Another reason why our patients didn't develop significant entry-site complication could be the standardized protocol which included deferred removal of arterial sheath (3 or 6 hours after the procedure), direct manual pressure applied to the brachial artery for 10 minutes, further local pressure with elastic bandages for 2 hours and bed rest for additional 6 hours. While in comparable studies, arterial sheath was removed directly after removal of guiding catheter. (18,25)

Table 4. Pros and cons of trans-brachial vs trans-femoral as secondary approach

PROS	CONS
Lesser bleeding risk	Risk of failure to obtain access
Beneficial forearm access	Risk of pseudoaneurysm, dissection
Easily palpable	Risk of median nerve damage
Shorter hospitalization/ Reduced hospital cost	More difficult to puncture than femoral artery
Easy immobilization	Difficult to puncture in case of subclavian tortuosity
Suitable for patients with aortoiliac disease	Inability to insert bigger sheaths
High success rate	
Low complication rate	

Furthermore, the significance of this case series also lays in the number of patients in whom trans-brachial approach was used since the paper we used for reference that had similar postprocedural protocol as ours had only 25 patients that were subjected to brachial artery puncture.(25) In addition, in their research from 25 patients there was one major and one minor complication whilst in ours there was total of 116 brachial artery punctures with also one major and one minor complication.

According to reviewed studies it is revealed that some clinicians believe that brachial artery approach for coronary angiography or intervention is dangerous with many complications while others use it occasionally. In our hospital, trans-radial approach is the first choice with more than 95% of coronary angiographies done via radial artery. However, when radial artery approach isn't feasible many cardiologists will opt for femoral artery access as an alternative. One of the studies retrospectively observed all cases of brachial and femoral approach in period of more than two years; in all cases there was always failure to radial access. There were 180 cases selected for brachial approach and 121 patients for femoral artery access, out of these patients in brachial artery group there was only one case of major complication where patient developed pseudoaneurysm of brachial artery and 8 patients developed ecchymosis and hematomas. On the other side, in femoral access group 3 patients developed major complications; pseudoaneurysm of right femoral artery, iatrogenic arteriovenous fistula and right venous dissection and third patient had pre-existing peripheral vascular disease and he developed critical limb ischemia after femoral puncture. In addition, 6 patients from femoral group developed ecchymosis and hematomas. (28) Authors of this paper concluded that brachial artery

access can be performed with equal or even lower risk in comparison to femoral artery access. (28)

Some of the advantages of brachial approach over femoral are that is suitable for patients with severe occlusive aortoiliac disease, for patients that have difficulty laying down such as patients with back pain, chronic heart failure and obesity. Brachial artery access allows earlier ambulation, decreases hospitalization of patients, decreases hospital costs and reduces post-procedure nursing requirements. (28) It is also important to mention that most patients prefer arm approach since it makes them more comfortable. However, brachial access has some limitations and disadvantages; unsuccessful attempt can cause bleeding that can lead to compartment syndrome which can induce ischemic injury of median nerve and ischemia of hand, guide placement is more challenging and it requires a lot of practice, heparin should be given routinely to prevent artery thrombosis due to smaller diameter of artery. (28) All in all, this study concluded that TBA for coronary angiography could be good alternative with considerable safety and efficacy. (28) Moreover, another study that proven benefit of brachial approach over femoral was done in center in Macau, they demonstrated only two vascular complications in brachial group (one major and one minor) to four vascular complications (three major and one minor) in femoral group. (25) Even though this study had few limitations such as small sample size of TBA (only 25 patients) and TFA patients (117 patients) , they still concluded from their result that brachial access is feasible and safe alternative to radial artery access. (25)

One of the limitations of this research is the missing data for few patients, while it is documented that radial artery approach wasn't possible, the reason why wasn't documented in medical data at the time. And this is something that we would want to improve in future research concerning this topic.

9. CONCLUSION

Coronary angiography and intervention can be safely and efficiently preformed via brachial artery access as a first alternative to trans-radial approach if done by operators experienced in arm approaches and if careful standardized post-procedural protocol is followed.

10. ACKNOWLEDGMENTS

First, I would like to express my sincere gratitude to my mentor doc.dr.sc. Matias Trbušić for giving me the opportunity to do this research at his department, answering my numerous questions and organizing help that made this thesis possible. His personal experience and expertise, motivation, guidance and teaching inspired me to choose this subject for my thesis. His love and devotion for cardiology has been inspiring me since first year of medical school when he was my mentor for “Fundamentals of Medical Skills” which made me decide since then that I will pursue cardiology in my future specialization and studies.

Besides my mentor I would like to thank the rest of my graduate thesis committee:

Doc.dr.sc. Nikola Bulj and doc.dr.sc. Boško Skorić.

Finally, I would like to thank my closest family and friends for their endless love and support throughout these six years and their encouragement in the pursuit of my dreams.

11. REFERENCES

1. Ralston SH, Penman ID, Strachan MWJ, Hobson RP. Davidson Principles and Practice of Medicine 23rd Edition 2018. 23rd ed.
2. Kumar, Vinay MBBS, MD Frcp, Abbas AKM, Aster JCMP. Robbins Basic Pathology 10 th edition. 10th ed. Elsevier; 2018. 910 p.
3. Bergovec M. Stabilna Angina Pectoris - Konzervativno ili Intervencijsko Liječenje. *Medicus*. 2003;12(1):43–9.
4. Cohn PF, Fox KM, Daly C. Silent myocardial ischemia. *Circulation*. 2003;108(10):1263–77.
5. Knuuti J, Wijns W, Achenbach S, Agewall S, Barbato E, Bax JJ, et al. 2019 ESC guidelines for the diagnosis and management of chronic coronary syndromes. *Eur Heart J*. 2020;41(3):407–77.
6. Miličić D. Pristup Bolesniku s Akutnim Koronarnim Sindromom. *Medicus*. 2003;12(1):51–63.
7. Payne MM. Charles Theodore Dotter: The father of intervention. *Texas Hear Inst J*. 2001;28(1):28–38.
8. Smilowitz NR, Feit F. The History of Primary Angioplasty and Stenting for Acute Myocardial Infarction. *Curr Cardiol Rep*. 2016;18(1):1–11.
9. Iqbal J, Gunn J, Serruys PW. Coronary stents: Historical development, current status and future directions. *Br Med Bull*. 2013;106(1):193–211.
10. Alfonso F, Pérez-Vizcayno MJ, Cárdenas A, García Del Blanco B, García-Touchard A, López-Minguéz JR, et al. A Prospective Randomized Trial of Drug-Eluting Balloons Versus Everolimus-Eluting Stents in Patients with In-Stent Restenosis of Drug-Eluting Stents the RIBS IV Randomized Clinical Trial. *J Am Coll Cardiol [Internet]*. 2015;66(1):23–33. Available from: <http://dx.doi.org/10.1016/j.jacc.2015.04.063>
11. Prvulović Đ. Perkutana koronarna intervencija balonom obloženim lijekom : hrvatsko iskustvo Percutaneous Coronary Interventions with Drug-eluting Balloons : Croatian Experience. 2014;9:289–98.
12. Franchi E, Marino P, Biondi-Zoccai GG, Luca G, Vassanelli C, Agostoni P. Transradial versus transfemoral approach for percutaneous coronary procedures. *Curr Cardiol Rep*.

- 2009;11(5):391–7.
13. Anjum I, Khan MA, Aadil M, Faraz A, Farooqui M, Hashmi A. Transradial vs. Transfemoral Approach in Cardiac Catheterization: A Literature Review. *Cureus*. 2017;9(6).
 14. Rao S V., Stone GW. Arterial access and arteriotomy site closure devices. *Nat Rev Cardiol*. 2016;13(11):1–10.
 15. Patel MR, Jneid H, Derdeyn CP, Klein LW, Levine GN, Lookstein RA, et al. Arteriotomy closure devices for cardiovascular procedures: A scientific statement from the american heart association. *Circulation*. 2010;122(18):1882–93.
 16. Sandoval Y, Burke MN, Lobo AS, Lips DL, Seto AH, Chavez I, et al. Contemporary Arterial Access in the Cardiac Catheterization Laboratory. *JACC Cardiovasc Interv*. 2017;10(22):2233–41.
 17. Campeau L. Percutaneous radial artery approach for coronary angiography. *Cathet Cardiovasc Diagn*. 1989;16(1):3–7.
 18. Kiemeneij F, Laarman GJ, Odekerken D, Slagboom T, Van Der Wieken R. A randomized comparison of percutaneous transluminal coronary angioplasty by the radial, brachial and femoral approaches: The access study. *J Am Coll Cardiol*. 1997;29(6):1269–75.
 19. Bhat FA, Changal KH, Raina H, Tramboo NA, Rather HA. Transradial versus transfemoral approach for coronary angiography and angioplasty - A prospective, randomized comparison. *BMC Cardiovasc Disord* [Internet]. 2017;17(1):1–7. Available from: <http://dx.doi.org/10.1186/s12872-016-0457-2>
 20. Gatzopoulos D, Rigatou A, Kontopodis E, Tsiafoutis I, Agelaki M, Lazaris E, et al. Alternative access site choice after initial radial access site failure for coronary angiography and intervention. *J Geriatr Cardiol*. 2018;15(9):585–90.
 21. Nie B, Zhou YJ, Li GZ, Shi DM, Wang JL. Clinical study of arterial anatomic variations for transradial coronary procedure in Chinese population. *Chin Med J (Engl)*. 2009;122(18):2097–102.
 22. Roghani-Dehkordi F, Hadizadeh M, Hadizadeh F. Percutaneous trans-ulnar artery approach for coronary angiography and angioplasty; A case series study. *ARYA Atheroscler*. 2015;11(5):305–9.
 23. Roghani-Dehkordi F, Mansouri R, Khosravi A, Mahaki B, Akbarzadeh M, Kermani-Alghoraishi M. Transulnar versus transradial approach for coronary angiography and

- angioplasty: Considering their complications. *ARYA Atheroscler*. 2018;14(3):128–31.
24. Hildick-Smith DJR, Khan ZI, Shapiro LM, Petch MC. Occasional-operator percutaneous brachial coronary angiography: First, do no arm. *Catheter Cardiovasc Interv*. 2002;57(2):161–5.
 25. Lam UP, Lopes Lao EP, Lam KC, Evora M, Wu NQ. Trans-brachial artery access for coronary artery procedures is feasible and safe: data from a single-center in Macau. *Chin Med J (Engl)*. 2019;132(12):1478–81.
 26. Neumann FJ, Sousa-Uva M, Ahlsson A, Alfonso F, Banning AP, Benedetto U, et al. 2018 ESC/EACTS Guidelines on myocardial revascularization. *Eur Heart J*. 2019;40(2):87–165.
 27. Malviya A, Mishra A. Coronary intervention in diabetes: Is it different. *Heart Asia*. 2015;7(1):9–14.
 28. Gan HW, Yip HK, Wu CJ. Brachial approach for coronary angiography and intervention: Totally obsolete, or a feasible alternative when radial access is not possible? *Ann Acad Med Singapore*. 2010;39(5):368–73.

12. BIOGRAPHY

Lara Gudelj was born on 8th of November 1994 in Rijeka, Croatia. She finished her primary and secondary school in Rijeka. She was enrolled in the Medical Studies in English Program at the University of Zagreb in 2014, where she has been studying since. From first year she was a member of Student section of Cardiology where from forth year she was an active member and on fifth year she has taken apart of group “Čuvajmo naše srce” with whom she was holding lectures and practical’s in numerous high schools around Zagreb. For this program she became one of group leaders this year. She became student demonstrator for subject history taking and physical examination on her fifth and sixth year of studies and she was holding practical’s on Clinical hospital Dubrava on department of cardiology for numerous groups alongside her mentor doc.dr.sc. Ivana Jurin dr.med.

