

# The effect of astaxanthin on testicular torsion-detorsion injury in rats - Detailed morphometric evaluation of histological sections

---

**Bašković, Marko; Katušić Bojanac, Ana; Sinčić, Nino; Himelreich Perić, Marta; Krsnik, Dajana; Ježek, Davor**

*Source / Izvornik:* **Journal of Pediatric Urology, 2021, 17, 439.e1 - 439.e12**

**Journal article, Accepted version**

**Rad u časopisu, Završna verzija rukopisa prihvaćena za objavljivanje (postprint)**

<https://doi.org/10.1016/j.jpurol.2021.03.020>

*Permanent link / Trajna poveznica:* <https://um.nsk.hr/um:nbn:hr:105:701363>

*Rights / Prava:* [In copyright](#)/[Zaštićeno autorskim pravom.](#)

*Download date / Datum preuzimanja:* **2025-02-02**



*Repository / Repozitorij:*

[Dr Med - University of Zagreb School of Medicine](#)  
[Digital Repository](#)



# **The effect of astaxanthin on testicular torsion-detorsion injury in rats - detailed morphometric evaluation of histological sections**

**Marko Bašković<sup>1</sup>, Ana Katušić Bojanac<sup>2</sup>, Nino Sinčić<sup>2</sup>,  
Marta Himmelreich Perić<sup>2</sup>, Dajana Krsnik<sup>2</sup>, Davor Ježek<sup>3</sup>**

<sup>1</sup>Department of Pediatric Urology, Children's Hospital Zagreb,  
Ulica Vjekoslava Klaića 16, 10000 Zagreb, Croatia

<sup>2</sup>Department of Medical Biology, University of Zagreb, School of Medicine,  
Šalata 3, 10000 Zagreb, Croatia

<sup>3</sup>Department of Histology and Embryology, University of Zagreb, School of Medicine,  
Šalata 3, 10000 Zagreb, Croatia

## SUMMARY

**Introduction:** Testicular torsion is one of the conditions of the acute scrotum that requires immediate surgical intervention. If not recognized at time, it can result of ischemic injuries and testicular loss. Restoration of blood flow is essential to save ischemic tissue, but reperfusion itself paradoxically causes further damage. Seaweed and sponges are considered to be the richest source of bioactive compounds that have antioxidant activity. The antioxidant activity of astaxanthin is 10 times higher than zeaxanthin, lutein, cantaxanthin,  $\beta$ -carotene and 100 times higher than  $\alpha$ -tocopherol. Since to date there is no drug given to patients with torsion-detorsion testicular injury, we have investigated the effect of this powerful antioxidant.

**Objective:** The aim of this study was to determine the effect of astaxanthin (ASX) on testicular torsion-detorsion injury in rats.

**Materials and Methods:** Thirty-two male Fischer prepubertal rats were divided into 4 groups of 8 individuals. Group 1 underwent sham surgery to determine basal values for histological evaluation. In group 2 (torsion-detorsion group), right testis was twisted at  $720^\circ$  for 90 min. After 90min of reperfusion, the testis was removed. Astaxanthin was administered intraperitoneally at the time of detorsion (group 3) and 45 minutes after detorsion (group 4) in the treatment groups. Using software ImageJ®, histological morphometric values were measured.

**Results:** MSTD (mean seminiferous tubule diameter) values increase statistically significantly in ASX groups compared to T/D group. MSLD (mean seminiferous lumen diameter) value was statistically significantly lower in the ASX group 3 compared to the T/D group. Epithelial height was statistically significantly higher in ASX groups compared to the T/D group. Tubular area is statistically significantly higher in ASX group 4, while the luminal area is statistically

significantly lower in the ASX group 3 compared to the T/D group. Johnsen score was statistically significantly higher in the ASX groups compared to the T/D group.

**Discussion:** This is the first scientific paper to study the effects of a single powerful antioxidant on all morphometric parameters. In previous scientific papers, scientists have mainly measured MSTD and the Johnsen score.

**Conclusion:** By measuring all histological morphometric parameters (mean seminiferous tubule diameter, mean seminiferous lumen diameter, epithelial height, tubular area, luminal area, Johnsen score) it can be concluded that astaxanthin has a favorable effect comparing the treated groups to untreated group.

**Keywords:** astaxanthin; testis; torsion-detorsion; ischemia-reperfusion injury

## INTRODUCTION

Testicular torsion is one of the conditions of the acute scrotum that requires immediate surgical intervention. Testicular torsion means the rotation of the testicle about a longitudinal axis by 180 degrees or more, followed by a cessation of circulation in the testis. If not recognized at time, it can result of ischemic injuries and testicular loss. It is a common belief that testicular torsion lasting longer than 6 hours is outside the time frame for survival (1). The incidence of testicular torsion is 1/4000 men aged 1 to 25 years. The prevalence of testicular torsion out of a total of all acute scrotal conditions is 25-50%. It can occur at any age, but usually occurs in young men. It is most commonly seen in infants and boys at puberty (2-6).

Ischemia-reperfusion injury (IRI) is defined as a paradoxical exacerbation of cell dysfunction and death, following restoration of blood flow in previously ischemic tissues. Restoration of blood flow is essential to save ischemic tissue, but reperfusion itself paradoxically causes further damage, threatening organ function and vitality. Free oxygen radicals are responsible for causing the inflammatory response in the local tissue, with accompanying damage. During reperfusion itself, oxygen influx catalyzes xanthine oxidase by degrading hypoxanthine to uric acid. This releases highly reactive anionic superoxide ( $O_2^-$ ). The superoxide is then converted to hydrogen peroxide ( $H_2O_2$ ) and a hydroxyl radical ( $OH\cdot$ ). The main consequence of the production of hydroxyl radicals is the peroxidation of the lipid structures of cell membranes resulting in the production and systemic release of proinflammatory eicosanoids, disruption of cell permeability and ultimately cell death (7-9). An increase in the concentration of free oxygen radicals usually occurs if the mechanisms responsible for their removal at some point become insufficient. This upsets the balance between prooxidants and antioxidants in favour of prooxidants (a state of oxidative stress).

Antioxidants are molecules capable of inhibiting the oxidation of other molecules. They are the body's defense system against potential damage by free oxygen radicals that occur during oxidative stress (10). In recent decades, interest in natural sources of antioxidants has risen sharply. Recently, organisms living in the marine environment have gained much attention from the pharmaceutical industry due to the possession of various interesting and useful chemical compounds (11). Seaweed and sponges are considered to be the richest source of bioactive compounds that have antimicrobial and antioxidant activity (12). A large number of different species of algae have been studied for the use of their bioactive compounds as functional components of food. Algae grow in extreme environmental conditions resulting in the production of large numbers of free oxygen radicals. To cope with this, algae produce various secondary metabolites with antioxidant activities such as phycobilins, polyphenols, carotenoids, and vitamins (13).

Astaxanthin ( $C_{40}H_{52}O_4$ ) is a pigment from the xanthophyll family, oxygenated derivatives of carotenoids whose synthesis in plants originates from lycopene (14). The green microalga *Haematococcus pluvialis* under stress conditions accumulates a high content of astaxanthin (15). In addition to this microalga, astaxanthin is also found in salmon, shrimp and crabs, which also gives them a specific shade of red (16). The antioxidant activity of astaxanthin is 10 times higher than zeaxanthin, lutein, cantaxanthin,  $\beta$ -carotene and 100 times higher than  $\alpha$ -tocopherol (17). Astaxanthin and its esters showed 80% antilipid peroxidative activity in rats (18). It is soluble in lipids, accumulates in animal tissues, and no toxic effects have been found (19).

Since to date there is no drug given to patients with torsion-detorsion testicular injury, we have investigated the effect of this powerful antioxidant.

## **MATERIALS AND METHODS**

### **Animals and reagents**

The research was approved by the School of Medicine, University of Zagreb (classification; 641-01/19-02/01 / registry number; 380-59-10106-19-111/162) and the Croatian National Ethics Committee (EP 217/2019). 3R principles were used; "reduction", "refinement" and "replacement" and the concept of five freedoms was respected. Thirty-two prepubertal male Fischer rats (weight 160-210g, 35 days old) were used in this study. The space in which the animals were housed met the following conditions in accordance with good laboratory practice (GLP); temperature 20-24°C, relative humidity 55% +/- 10%, controlled lighting, light dark cycle 12h/12h and noise level did not exceed 60dB. According to GLP, data were provided in such a way that the whole experiment could be repeated in the same way as it was performed (traceability). Astaxanthin was purchased from Sigma-Aldrich® (St. Louis, Missouri, USA) ( $\geq 97\%$  (HPLC), from *Blakeslea trispora*). Astaxanthin was administered intraperitoneally at a dose of 75 mg/kg.

### **Experimental groups**

Rats were randomly divided into 4 groups of 8 individuals in each group; sham-operated (S) group, torsion-detorsion (T/D) group, torsion-detorsion + astaxanthin (T/D + ASX) groups.

Group 1 (S) underwent sham surgery to determine basal values for histological evaluation. After the intraperitoneal injection of anesthetic, an incision was made in the right inguinal region, in order to pull out the ipsilateral testis, which was immediately returned to its natural position.

The skin was sutured with monofilament polyglactin suture 6/0. After suture removal, the orchidectomy was performed after 3 hours.

Group 2 (T - 90min / D - 90min); After an intraperitoneal injection of anesthetic, an incision was made in the right inguinal region, to pull out the ipsilateral testis, which was then twisted around its axis by 720° **in a clockwise direction**. It was fixed in that position for 90 minutes. After 90 minutes, a detorsion was performed. The skin was sutured twice (0 min, 90 min). Orchidectomy was performed 90 minutes from the moment of detorsion.

Group 3 (T - 90min / D - 90min + ASX at the time of detorsion); After an intraperitoneal injection of anesthetic, an incision was made in the right inguinal region, to pull out the ipsilateral testis, which was then twisted around its axis by 720° **in a clockwise direction**. It was fixed in that position for 90 minutes. After 90 minutes, a detorsion was performed. At the time of detorsion, astaxanthin (75 mg/kg) was administered intraperitoneally. The skin was sutured twice (0 min, 90 min). Orchidectomy was performed 90 minutes from the moment of detorsion.

Group 4 (T - 90min / D - 90min + ASX 45 minutes from the moment of detorsion); After an intraperitoneal injection of anesthetic, an incision was made in the right inguinal region, to pull out the ipsilateral testis, which was then twisted around its axis by 720° **in a clockwise direction**. It was fixed in that position for 90 minutes. After 90 minutes, a detorsion was performed. Astaxanthin (75 mg/kg) was administered intraperitoneally 45 minutes after the moment of detorsion. The skin was sutured twice (0 min, 90 min). Orchidectomy was performed 90 minutes from the moment of detorsion.



## **Surgical procedure**

All surgical procedures were performed under aseptic conditions. After shaving the hairs in the right inguinoscrotal region, the region was washed with chlorhexidine gluconate (PLIVA®sept, Pliva d.o.o., Croatia), then dried and treated with a solution of povidone-iodine (Betadine®10%, Alkaloid, Skopje, North Macedonia). An incision was made in the midline of the scrotum. Upon opening tunica vaginalis, testis was twisted manually around its axis by 720° **in a clockwise direction**. The testis was fixed to the inner wall of the scrotum with a monofilament polyglactin suture 6/0 (Vicryl; Ethicon Inc., Johnson & Johnson Co., Somerville, NJ, USA). By removing the suture, the right testicle was manually detorsed to its natural position. The skin of the scrotum was also sutured with a monofilament polyglactin suture 6/0. All surgical procedures were performed under general anaesthesia induced by intraperitoneal injection of ketamine (90 mg/kg) and xylazine (10 mg/kg). The animals were constantly monitored. In case of movement, twitching or other signs of awakening, intraperitoneal anaesthesia was supplemented in a smaller dose. No animals died during the experiment. The opioid analgesic was not used since the experiment was irreversible, ie the animals were euthanized from the maintained deep anaesthesia. After the realization of the experimental endpoint (orchidectomy), ie the scientific realization of the planned research, the euthanasia of rats was performed with the application of T-61 solution (1ml/kg) iv. (*Intervet International GmbH*®, Germany).

## **Histopathologic evaluation**

At the end of the surgery and orchidectomy, the testicles were individually fixed in 4% formaldehyde. After fixation and dehydration, the tissue was impregnated with xylene after which the samples were transferred to a dish with xylene and paraffin (1:1) (thermostat 15 min; 56°C). Then, every hour, on three occasions, the tissue was placed in pure paraffin, after which it was immersed in an embryo dish. After the paraffin blocks had cooled and hardened, they were dried and shaped. The blocks were stored at +4°C until analysis. The blocks were cut in series with a rotary microtome (thickness - 4µm) and mounted on glass slides, dried, placed in a thermostat at 56°C and incubated for 12h. The preparations were stained with haematoxylin and eosin (H&E). For each group, the 20 most rounded sections were randomly selected. The following values were measured using a microscope (x200 magnification) and ImageJ® (software package developed by the National Institutes of Health) software; mean seminiferous tubule diameter (MSTD) - the diameter of the seminiferous tubule was measured on the larger and smaller axis from which the mean diameter was obtained, mean seminiferous lumen diameter (MSLD) - the diameter of the seminiferous lumen was measured on the larger and smaller axis from which the mean diameter was obtained, epithelial height, tubular area, luminal area and Johnsen score (Fig 1). Depending on the maturity of the germ cells, from the basal to the adluminal compartment, spermatogenesis was quantified at a value of 1 to 10 (20). All measurements were performed by two independent persons.

## **Statistical analysis**

The design of the experiment was analyzed in detail. With 8 animals per group, we obtained equivalent, high-quality data, as if the experiment was done with a larger number of individuals

(for  $\alpha=0.05$ , power = 95% and effect  $\geq 0.9$ , a sample of 32 animals divided into 4 groups of 8 individuals was required). The obtained data were analyzed using the Microsoft Excel® software program (XLSTAT®) for Windows, version 2020.5.1 (Microsoft Corporation, Redmond, Washington, USA). Collected measurements were analyzed for normal distribution using the Shapiro-Wilk test. Data are presented as median (interquartile range). Differences between groups of continuous data were compared by nonparametric (distribution free) Kruskal-Wallis test. The data are presented as follows; chi-square ( $\chi^2$ ) = observed value (critical value), degrees of freedom (DF), p-value. The Mann-Whitney U test with Bonferroni correction was used for pairwise comparisons. A significant overall test, at an alpha 0.05 level of significance, was followed by pair-wise testing using a Mann-Whitney test with a Bonferroni-adjusted alpha level of 0.0083.

## RESULTS

The values of medians and interquartile ranges by groups are shown in table (table 1). A Kruskal-Wallis test shows that there is a statistically significant difference in all observed parameters between the different groups (at a significance level of 5%); MSTD [ $\chi^2 = 55.73$  (7.82), DF = 3,  $p<0.0001$ ], MSLD [ $\chi^2 = 65.69$  (7.82), DF = 3,  $p<0.0001$ ], tubular area [ $\chi^2 = 59.29$  (7.82), DF = 3,  $p<0.0001$ ], luminal area [ $\chi^2 = 67.88$  (7.82), DF = 3,  $p<0.0001$ ], epithelial height [ $\chi^2 = 66.32$  (7.82), DF = 3,  $p<0.0001$ ], Johnsen score [ $\chi^2 = 71.02$  (7.82), DF = 3,  $p<0.0001$ ]. Post-hoc pairwise comparisons yielded the following results; MSTD [ $p<0.0001$  (groups 1 and 2, 1 and 3, 1 and 4, 2 and 4),  $p=0.001$  (groups 2 and 3),  $p=0.038$  (groups 3 and 4)] (graph 1), MSLD [ $p<0.0001$  (groups 1 and 2, 1 and 3, 1 and 4, 2 and 3, 3 and 4),  $p=0.473$  (groups 2 and 4)] (graph 2), tubular area [ $p<0.0001$  (groups 1 and 2, 1 and 3, 1 and 4, 2 and 4),  $p=0.052$  (groups 2 and 3),  $p=0.000$  (groups 3 and 4)] (graph 3), luminal area [ $p<0.0001$  (groups

1 and 2, 1 and 3, 1 and 4, 2 and 3, 3 and 4),  $p=0.028$  (groups 2 and 4)] (graph 4), epithelial height [ $p<0.0001$  (groups 1 and 2, 1 and 3, 1 and 4, 2 and 3, 2 and 4),  $p=0.002$  (groups 3 and 4)] (graph 5), Johnsen score [ $p<0.0001$  (groups 1 and 2, 1 and 3, 1 and 4, 2 and 3, 2 and 4, 3 and 4)] (graph 6). MSTD values increase statistically significantly in ASX groups compared to T/D group (172.38 (11.19)) [MSTD is higher in group 4 (195.62 (21.27)) compared to group 3 (184.05 (7.27))]. The MSLD value was statistically significantly lower in the ASX group 3 (80.81 (7.46)) compared to the T/D group (101.21 (5.68)). Epithelial height was statistically significantly higher in ASX groups compared to the T/D group (35.92 (5.26)) [highest in group 4 (45.18 (4.26))]. The tubular area is statistically significantly higher in ASX group 4 (29910.52 (1658.64)), while the luminal area is statistically significantly lower in the ASX group 3 (5322.76 (1050.15)) compared to the T/D group. The Johnsen score was statistically significantly higher in the ASX groups compared to the T/D group (highest in group 4 (7.00 (0.00)) (Fig 2).

## DISCUSSION

All results of histopathological research indicate that astaxanthin has a favorable effect in ischemic-reperfusion injury of testicular tissue. It is obvious that the variables MSTD, tubular area, MSLD, luminal area, epithelial height and Johnsen score are better in group 3 and group 4 compared to the T/D group. It would be expected that the results of all variables would be better in group 3 compared to group 4 since in group 3 astaxanthin was administered at the time of detorsion, but the results are better in most parameters in group 4 (MSTD, tubular area, epithelial height, Johnsen score). The answer to the possible cause of the obtained results is found in the fact that sluggishness of return blood flow may limit the vascular capacity to deliver

appropriate antioxidant doses to testes during the immediate post-torsion period. Variety of studies have shown that the first 60-90 minutes after initial reperfusion is the critical time in which the toxic burst of oxygen radicals will occur from invading neutrophils, macrophages, or even resident parenchymal cells (21). We can also note the fact that the MSLD variable, and thus the luminal area, do not follow the expected decline in group 4 relative to group 3 and the sham group. This interesting cognition certainly requires further research.

Although so far no one has studied the effect of astaxanthin on ischemic reperfusion testicular injury in rats, the effects of its precursor lycopene have been investigated. Hekimoglu et al. investigated histopathological changes after one-hour ischemia by vascular clamp and twenty-four-hour reperfusion (22). The group that received lycopene showed statistically significantly better results of the Johnsen result ( $p < 0.05$ ), compared to the group where only torsion-detorsion was performed. In preclinical studies, when we observe ischemic reperfusion injury of the testis and the possible favorable effects of certain substances, we consider that ischemia should be performed through torsion rather than ligating the vessels with a vascular clamp, since torsion initially clogs veins but not arteries and thus causes partial ischemia in early period of torsion. Güzel et al. (23) investigated the effect of intraperitoneal lycopene administration. In their model, the  $720^\circ$  torsion lasted for two hours, after which lycopene was administered for 3 and 10 days. MSTD and Johnsen scores were higher in the lycopene group given intraperitoneally for three days compared to the lycopene-free group. Also, when comparing the results of sham groups of the Johnsen score in the Hekimoglu et al. ( $8.9 \pm 0.18$ ) and Güzel et al. ( $9.44 \pm 0.70$ ) studies with our results ( $7.9 \pm 0.30$ ), it is important to note that we investigated the effect of astaxanthin on prepubertal rats for the well-known fact that testicular torsion in humans occurs primarily in adolescence and preadolescence (the prepubertal rat testis, where spermatogenesis has begun, is similar in status to the early adolescent human testis, which commonly experiences the effects of torsion) (24). Given the

results of previous and our research, it would certainly be useful to investigate the possible favorable effects of  $\beta$ -Carotene, zeaxanthin, canthaxanthin and violaxanthin since they are all part of the biosynthetic pathway of astaxanthin (25).

In the last 20 years, astaxanthin has attracted the attention of researchers around the world, and day by day we are witnessing an increasing publication of papers which investigating the effects of astaxanthin. Otsuka et al. (26) conclude that astaxanthin prevented damage caused by retinal ischemia and that its use could be effective in protecting against neurodegeneration during ischemic retinopathy. The effect of astaxanthin was also examined in ischemic-reperfusion injury of the liver and muscles with equally optimistic results in favor of a favorable effect (27,28). Ischemic-reperfusion injury of the myocardium was dealt with by a team of researchers led by Lauver. They concluded that disodium disuccinate astaxanthin has a beneficial effect on harm reduction (29). Astaxanthin has been shown to be effective in preserving renal function and histology by antioxidant activity in a mouse kidney model (30). Tripathi and Jena (31) talk about astaxanthin as a germ cell protector, i.e. a chemoprotector of cyclophosphamide-treated mice. The positive effect of astaxanthin on steroidogenesis in Leydig cells was described by Wang et al. (32).

Natural astaxanthin is sold in the European Union in a range of products in daily doses up to 12 mg and are approved by national authorities worldwide in daily doses up to 24 mg. Studies, involving more than 2,000 participants, found no significant toxicity at any dose for natural astaxanthin. Natural AX has shown an excellent clinical safety profile at short-term daily doses up to 100 mg and long-term daily doses averaging between 8 and 12 mg (33). The safety of astaxanthin has been assessed in rats after receiving daily oral administration of astaxanthin-rich *H. phuvialis* biomass at concentrations up 500 mg/kg/day for 90 days, or synthetic astaxanthin in a range between 880 and 1240 mg/kg/day for 13 weeks (34,35). Katsumata et al. performed a sub-chronic-toxicity evaluation of a natural astaxanthin-rich

carotenoid extract produced from the natural bacteria *Paracoccus carotinifaciens* suspended in olive oil and administered daily to rats by oral gavage at doses of up to 1000 mg/kg/day for 13 weeks. The only result highlighted was the excretion of dark-red colour feces without reporting any considerable adverse effect (36). Some studies have shown limitations after oral administration such as low stability, bioavailability and bioefficacy, revealing a need for the implementation of new biomaterials to act as astaxanthin vehicles in vivo (37). Given that scientists have recently become more and more interested in antioxidants derived from microalgae, it is to be expected that many of them (certainly astaxanthin) will find application in clinical medicine. To date, there are no clinical studies on the effect of astaxanthin on ischemic-reperfusion testicular injury in humans, but the beneficial effects of this potent antioxidant in humans have been investigated (e.g. astaxanthin inhibits LDL oxidation and increases HDL levels, protects against UV radiation, is used in anti-aging treatments, inhibits proliferation of human gastric cancer cell lines, has genoprotective properties etc.) (38-42). Regarding the male reproductive system, Comhaire et al. (43) administered astaxanthin to infertile men and observed positive effects on sperm parameters and fertility. Our study is the first to investigate the potential favorable effect of astaxanthin on ischemic-reperfusion testicular injury in an animal model. If the ethics committee allows, we will certainly extend the research to people as well. For optimal administration, the pharmacokinetics and pharmacodynamics of astaxanthin must be investigated in detail. Research on this topic has not been completed (44,45). Also, the fact of the existence of the blood-testis barrier, as well as its changes due to ischemia, must not be overlooked (46). We believe that one day these powerful antioxidants will be applicable in clinical practice.

## LIMITATIONS OF THE STUDY

Although this is the first study to comprehensively histologically examine the effect of astaxanthin on ischemic-reperfusion testicular injury, we are aware of the fact that in our future research we must focus on biochemical and immunohistochemical methods, which should further strengthen the results and confirm the hypothesis. In our future study, we will measure MDA, SOD, and GPx values from testicular tissue homogenates, while we will immunohistochemically determine the number of apoptotic cleaved caspase-3 positive cells (apoptotic index) from residual tissue embedded in paraffin. It is also important to note that in our study we focused on the acute effect and acute changes after ischemic-reperfusion injury. In a clinical setting, the mean time from torsion to surgical intervention often extends beyond 90 minutes (a number of factors depend on this; distance from the hospital, the child's signalling from the onset of pain, the boy's shyness, etc.). To mimic real life settings, the study would have benefitted from extending the time from torsion to reperfusion. Since this is the first study of the effect of astaxanthin on ischemic-reperfusion testicular injury in rats, we consider this study to be extremely important. In future studies, one can certainly consider extending the time from torsion to reperfusion. Astaxanthin was administered intraperitoneally as it was most appropriate for this model. We are aware that the oral route of administration is more suitable for human administration, but as more detailed pharmacokinetic and pharmacodynamic studies are ongoing, we consider intraperitoneal administration to be more than satisfactory for testing astaxanthin as a potential potent antioxidant in preventing ischemic reperfusion injury. We opted for a dose of 75mg/kg, but we consider that in future studies the dose may be reduced to keep the dose within the range currently recommended for human administration. It will be interesting to see what effect the reduced dose will have then. From our study, it is obvious that sluggishness of blood return affects the effect of the applied antioxidant. From our study, it can be concluded that it is certainly better to administer astaxanthin 45 min after detorsion than at



the time of detorsion. To answer the question of what is the most optimal time for the administration of astaxanthin, several more groups should be added to which astaxanthin would be administered at different times from the moment of detorsion. Given the well-known facts of the effect of ischemic-reperfusion injury of the ipsilateral testis on the contralateral testis, they should certainly be investigated in future research. Clearly, our preclinical results cannot be directly applied to the clinic, but they are certainly a good foundation for future research on this powerful antioxidant.

## **CONCLUSION**

By measuring all histological morphometric parameters (mean seminiferous tubule diameter, mean seminiferous lumen diameter, epithelial height, tubular area, luminal area, Johnsen score) it can be concluded that astaxanthin has a favorable effect comparing the treated groups to untreated group.

## **DECLARATION OF INTEREST STATEMENT**

Financial support and sponsorship: Nil

Conflicts of interest: There are no conflicts of interest

## REFERENCES

1. Ta A, D'Arcy FT, Hoag N, D'Arcy JP, Lawrentschuk N. Testicular torsion and the acute scrotum: current emergency management. *Eur J Emerg Med* 2016;23(3):160–5. <https://doi.org/10.1097/MEJ.0000000000000303>
2. al Mufti RA, Ogedegbe AK, Lafferty K. The use of Doppler ultrasound in the clinical management of acute testicular pain. *Br J Urol* 1995;76(5):625-7. <https://doi.org/10.1111/j.1464-410x.1995.tb07790.x>
3. Watkin NA, Reiger NA, Moisey CU. Is the conservative management of the acute scrotum justified on clinical grounds? *Br J Urol* 1996;78(4):623-7. <https://doi.org/10.1046/j.1464-410x.1996.16321.x>
4. Tajchner L, Larkin JO, Bourke MG, Waldron R, Barry K, Eustace PW. Management of the acute scrotum in a district general hospital: 10-year experience. *ScientificWorldJournal* 2009;9:281-6. <https://doi.org/10.1100/tsw.2009.37>
5. Hegarty PK, Walsh E, Corcoran MO. Exploration of the acute scrotum: a retrospective analysis of 100 consecutive cases. *Ir J Med Sci* 2001;170(3):181-2. <https://doi.org/10.1007/BF03173885>
6. Kar A, Ozden E, Yakupoglu YK, Kefeli M, Sarikaya S, Yilmaz AF. Experimental unilateral spermatic cord torsion: the effect of polypolymerase enzyme inhibitor on histopathological and biochemical changes in the early and late periods in the ipsilateral and contralateral testicles. *Urology* 2010;76(2):507.e1-507.e5075. <https://doi.org/10.1016/j.urology.2010.03.074>
7. Carden DL, Granger DN. Pathophysiology of ischaemia-reperfusion injury. *J Pathol.* 2000;190(3):255-66. [https://doi.org/10.1002/\(SICI\)1096-9896\(200002\)190:3<255::AID-PATH526>3.0.CO;2-6](https://doi.org/10.1002/(SICI)1096-9896(200002)190:3<255::AID-PATH526>3.0.CO;2-6)

8. Grace PA, Mathie RT. Ischemia-reperfusion Injury. London: Blackwell Science; 1999.
9. Kalogeris T, Baines CP, Krenz M, Korthuis RJ. Cell biology of ischemia/reperfusion injury. *Int Rev Cell Mol Biol* 2012;298:229-317. <https://doi.org/10.1016/B978-0-12-394309-5.00006-7>
10. Miguel MG. Antioxidant and anti-inflammatory activities of essential oils: a short review. *Molecules* 2010;15(12):9252-87. <https://doi.org/10.3390/molecules15129252>
11. Tramper J, Battershill C, Brandenburg W, Burgess G, Hill R, Luiten E, et al. What to do in marine biotechnology? *Biomol Eng* 2003;20(4-6):467-71. [https://doi.org/10.1016/s1389-0344\(03\)00077-7](https://doi.org/10.1016/s1389-0344(03)00077-7)
12. Ngo DH, Vo TS, Ngo DN, Wijesekara I, Kim SK. Biological activities and potential health benefits of bioactive peptides derived from marine organisms. *Int J Biol Macromo* 2012;1 51(4):378-83. <https://doi.org/10.1016/j.ijbiomac.2012.06.001>
13. Manivannan K, Karthikai Devi G, Anantharaman P, Balasubramanian T. Antimicrobial potential of selected brown seaweeds from Vedalai coastal waters, Gulf of Mannar. *Asian Pac J Trop Biomed* 2011;1(2):114-20. [https://doi.org/10.1016/S2221-1691\(11\)60007-5](https://doi.org/10.1016/S2221-1691(11)60007-5)
14. Higuera-Ciapara I, Félix-Valenzuela L, Goycoolea FM. Astaxanthin: a review of its chemistry and applications. *Crit Rev Food Sci Nutr* 2006;46(2):185-96. <https://doi.org/10.1080/10408690590957188>
15. Sarada R, Tripathi U, Ravishankar GA. Influence of stress on astaxanthin production in *Haematococcus pluvialis* grown under different culture conditions. *Process Biochem* 2002;37:623-7. [https://doi.org/10.1016/S0032-9592\(01\)00246-1](https://doi.org/10.1016/S0032-9592(01)00246-1)
16. Kidd P. Astaxanthin, cell membrane nutrient with diverse clinical benefits and anti-aging potential. *Altern Med Rev* 2011;16(4):355-64

17. Miki W. Biological functions and activities of animal carotenoids. *Pure Appl Chem* 1991;63:141-6. <https://doi.org/10.1351/pac199163010141>
18. Kamath BS, Srikanta BM, Dharmesh SM, Sarada R, Ravishankar GA. Ulcer preventive and antioxidative properties of astaxanthin from *Haematococcus pluvialis*. *Eur J Pharmacol* 2008;590(1-3):387-95. <https://doi.org/10.1016/j.ejphar.2008.06.042>
19. Ranga Rao A, Baskaran V, Sarada R, Baskaran V. In vivo bioavailability and antioxidant activity of carotenoids from micro algal biomass - A repeated dose study. *Food Res Int* 2013;54:711-7. <https://doi.org/10.1016/j.foodres.2013.07.067>
20. Johnsen SG. Testicular biopsy score count--a method for registration of spermatogenesis in human testes: normal values and results in 335 hypogonadal males. *Hormones* 1970;1(1):2-25. <https://doi.org/10.1159/000178170>
21. Prillaman HM, Turner TT. Rescue of testicular function after acute experimental torsion. *J Urol* 1997;157(1):340-5. [https://doi.org/10.1016/S0022-5347\(01\)65374-6](https://doi.org/10.1016/S0022-5347(01)65374-6)
22. Hekimoglu A, Kurcer Z, Aral F, Baba F, Sahna E, Atessahin A. Lycopene, an antioxidant carotenoid, attenuates testicular injury caused by ischemia/reperfusion in rats. *Tohoku J Exp Med* 2009;218(2):141-7. <https://doi.org/10.1620/tjem.218.141>
23. Güzel M, Sönmez MF, Baştuğ O, Aras NF, Öztürk AB, Küçükaydın M, Turan C. Effectiveness of lycopene on experimental testicular torsion. *J Pediatr Surg* 2016;51(7):1187-91. <https://doi.org/10.1016/j.jpedsurg.2015.11.008>
24. Becker EJ Jr, Turner TT. Endocrine and exocrine effects of testicular torsion in the prepubertal and adult rat. *J Androl* 1995;16(4):342-51. <https://doi.org/10.1002/j.1939-4640.1995.tb00539.x>

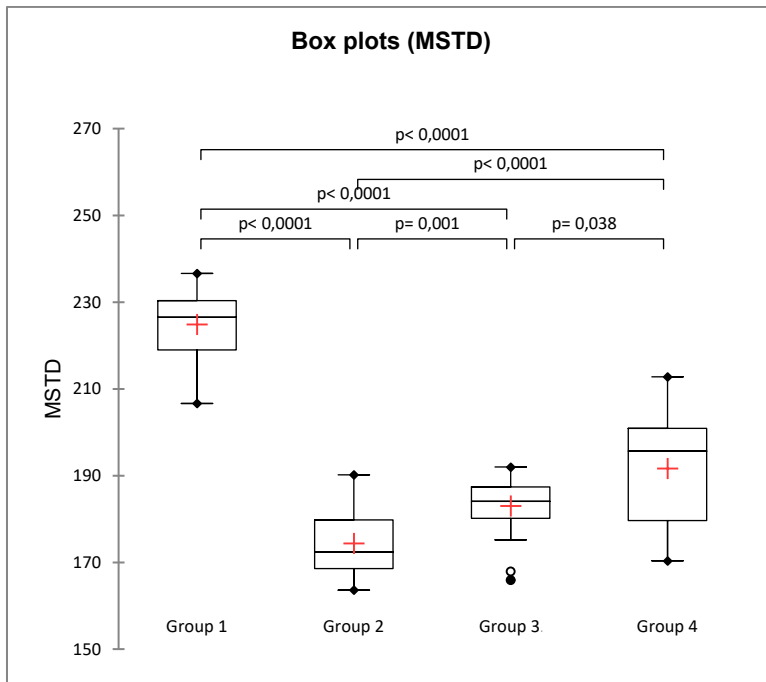
25. Sathasivam R, Ki JS. A Review of the Biological Activities of Microalgal Carotenoids and Their Potential Use in Healthcare and Cosmetic Industries. *Mar Drugs* 2018;16(1):26. <https://doi.org/10.3390/md16010026>
26. Otsuka T, Shimazawa M, Inoue Y, Nakano Y, Ojino K, Izawa H, et al. Astaxanthin Protects Against Retinal Damage: Evidence from In Vivo and In Vitro Retinal Ischemia and Reperfusion Models. *Curr Eye Res* 2016;41(11):1465-72. <https://doi.org/10.3109/02713683.2015.1127392>
27. Curek GD, Cort A, Yucel G, Demir N, Ozturk S, Elpek GO, et al. Effect of astaxanthin on hepatocellular injury following ischemia/reperfusion. *Toxicology* 2010;267(1-3):147-53. <https://doi.org/10.1016/j.tox.2009.11.003>
28. Zuluaga Tamayo M, Choudat L, Aid-Launais R, Thibaudeau O, Louedec L, Letourneur D, et al. Astaxanthin Complexes to Attenuate Muscle Damage after In Vivo Femoral Ischemia-Reperfusion. *Mar Drugs* 2019;17(6):354. <https://doi.org/10.3390/md17060354>
29. Lauver DA, Lockwood SF, Lucchesi BR. Disodium Disuccinate Astaxanthin (Cardax) attenuates complement activation and reduces myocardial injury following ischemia/reperfusion. *J Pharmacol Exp Ther* 2005;314(2):686-92. <https://doi.org/10.1124/jpet.105.087114>
30. Qiu X, Fu K, Zhao X, Zhang Y, Yuan Y, Zhang S, et al. Protective effects of astaxanthin against ischemia/reperfusion induced renal injury in mice. *J Transl Med* 2015;13:28. <https://doi.org/10.1186/s12967-015-0388-1>
31. Tripathi DN, Jena GB. Astaxanthin inhibits cytotoxic and genotoxic effects of cyclophosphamide in mice germ cells. *Toxicology* 2008;248(2-3):96-103. <https://doi.org/10.1016/j.tox.2008.03.015>

32. Wang JY, Lee YJ, Chou MC, Chang R, Chiu CH, Liang Y J, et al. Astaxanthin protects steroidogenesis from hydrogen peroxide-induced oxidative stress in mouse Leydig cells. *Mar Drugs* 2015;13(3):1375-88. <https://doi.org/10.3390/md13031375>
33. Brendler T, Williamson EM. Astaxanthin: How much is too much? A safety review. *Phytother Res* 2019;33(12):3090-111. <https://doi.org/10.1002/ptr.6514>
34. Stewart JS, Lignell A, Pettersson A, Elfving E, Soni MG. Safety assessment of astaxanthin-rich microalgae biomass: Acute and subchronic toxicity studies in rats. *Food Chem Toxicol* 2008;46(9):3030-6. <https://doi.org/10.1016/j.fct.2008.05.038>
35. Vega K, Edwards J, Beilstein P. Subchronic (13-week) toxicity and prenatal developmental toxicity studies of dietary astaxanthin in rats. *Regul Toxicol Pharmacol* 2015;73(3):819-28.  
<https://doi.org/10.1016/j.yrtph.2015.10.013>
36. Katsumata T, Ishibashi T, Kyle D. A sub-chronic toxicity evaluation of a natural astaxanthin-rich carotenoid extract of *Paracoccus carotinifaciens* in rats. *Toxicol Rep* 2014;1:582-8.  
<https://doi.org/10.1016/j.toxrep.2014.08.008>
37. Zuluaga M, Gueguen V, Letourneur D, Pavon-Djavid G. Astaxanthin-antioxidant impact on excessive Reactive Oxygen Species generation induced by ischemia and reperfusion injury. *Chem Biol Interact* 2018;279:145-58.  
<https://doi.org/10.1016/j.cbi.2017.11.012>
38. Kishimoto Y, Yoshida H, Kondo K. Potential Anti-Atherosclerotic Properties of Astaxanthin. *Mar Drugs* 2016;14(2):35. <https://doi.org/10.3390/md14020035>
39. Ito N, Seki S, Ueda F. The Protective Role of Astaxanthin for UV-Induced Skin Deterioration in Healthy People-A Randomized, Double-Blind, Placebo-Controlled Trial. *Nutrients* 2018;10(7):817. <https://doi.org/10.3390/nu10070817>

40. Eren B, Tuncay Tanrıverdi S, Aydın Köse F, Özer Ö. Antioxidant properties evaluation of topical astaxanthin formulations as anti-aging products. *J Cosmet Dermatol* 2019;18(1):242-50. <https://doi.org/10.1111/jocd.12665>
41. Kim JH, Park JJ, Lee BJ, Joo MK, Chun HJ, Lee SW, et al. Astaxanthin Inhibits Proliferation of Human Gastric Cancer Cell Lines by Interrupting Cell Cycle Progression. *Gut Liver* 2016;10(3):369-74. <https://doi.org/10.5009/gnl15208>
42. Pilinska MA, Kurinnyi DA, Rushkovsky SR, Dybska OB. Genoprotective properties of astaxanthin revealed by ionizing radiation exposure in vitro on human peripheral blood lymphocytes. *Probl Radiac Med Radiobiol* 2016;21:141-8.
43. Comhaire FH, El Garem Y, Mahmoud A, Eertmans F, Schoonjans F. Combined conventional/antioxidant "Astaxanthin" treatment for male infertility: a double blind, randomized trial. *Asian J Androl* 2005;7(3):257-62. <https://doi.org/10.1111/j.1745-7262.2005.00047.x>
44. Reboul E. Mechanisms of Carotenoid Intestinal Absorption: Where Do We Stand?. *Nutrients* 2019;11(4):838. <https://doi.org/10.3390/nu11040838>
45. Parker RS. Absorption, metabolism, and transport of carotenoids. *FASEB J* 1996;10(5):542-51. <https://doi.org/10.1096/fasebj.10.5.8621054>
46. Mel'man EP, Gritsulyak BV, Shutka BV. Changes in the ultrastructure of components of the blood-testis barrier in circulatory hypoxia. *Bull Exp Biol Med* 1979;88:928-31. <https://doi.org/10.1007/BF00869238>

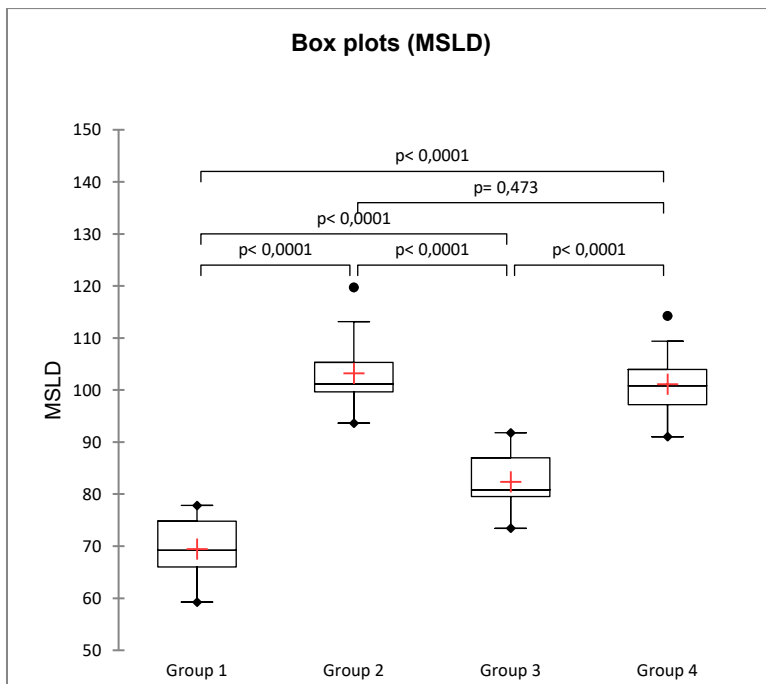
## GRAPHS

### Graph 1



Box plots for MSTD

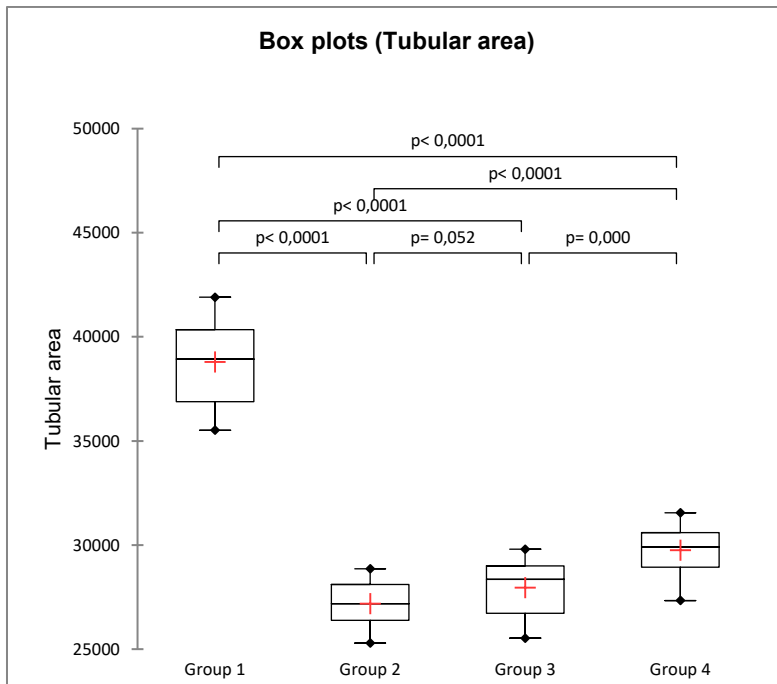
### Graph 2



Box plots for MSLD

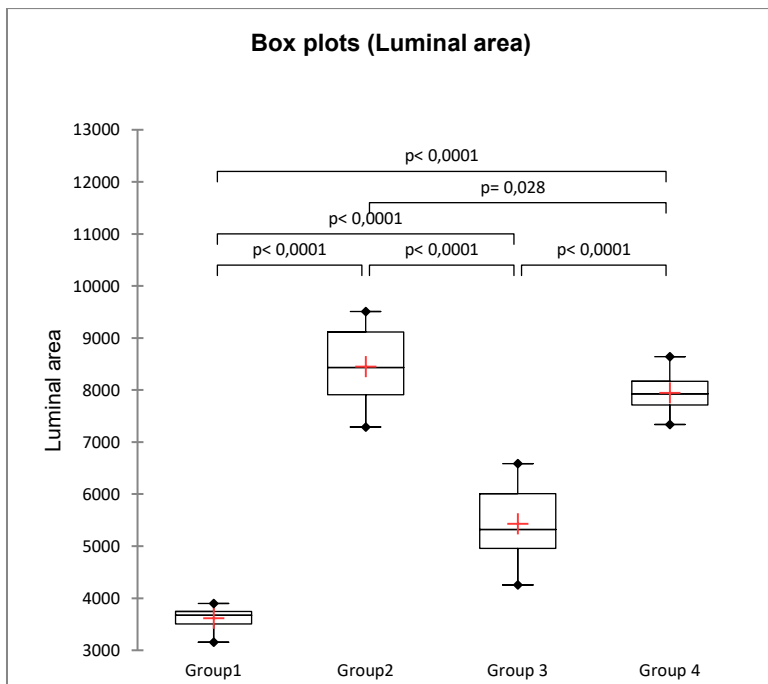


**Graph 3**



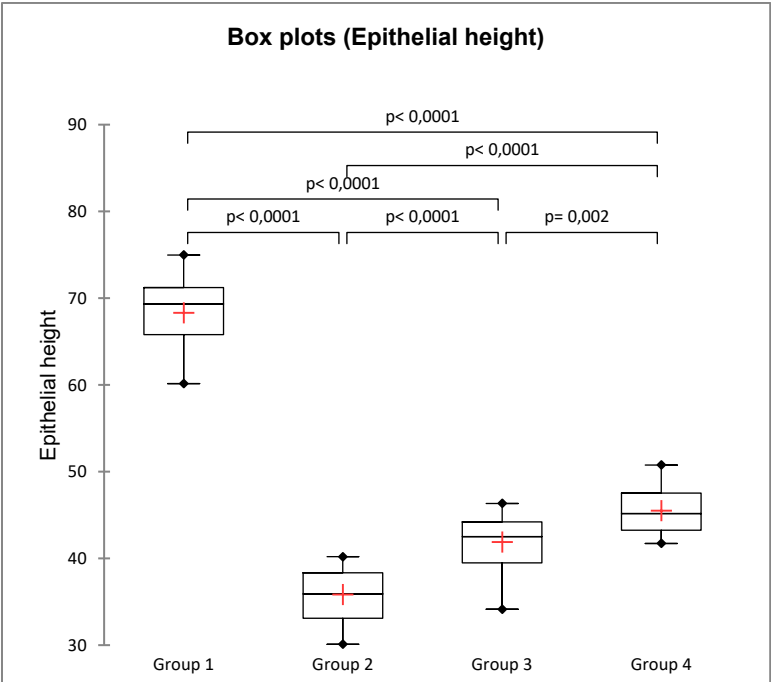
Box plots for tubular area

**Graph 4**



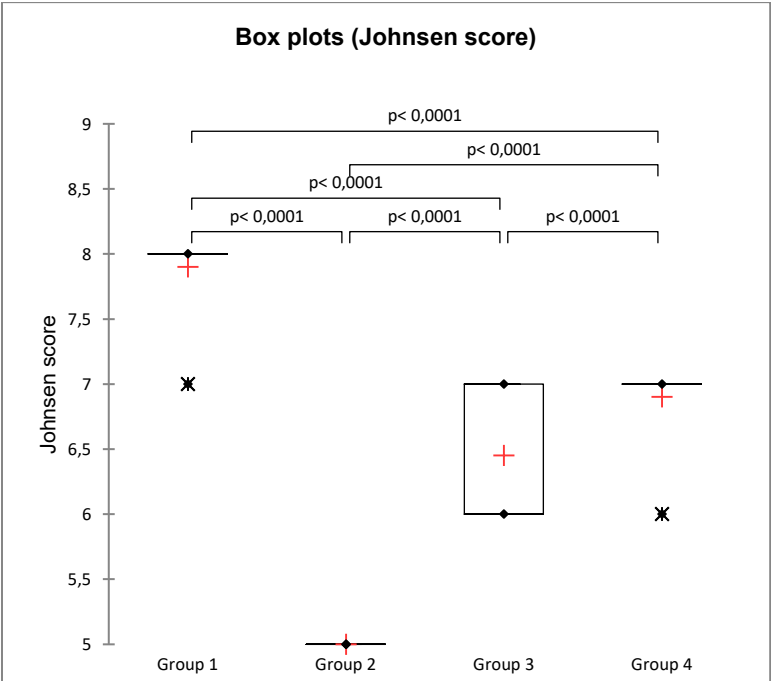
Box plots for luminal area

Graph 5



Box plots for epithelial height

Graph 6



Box plots for Johnsen score

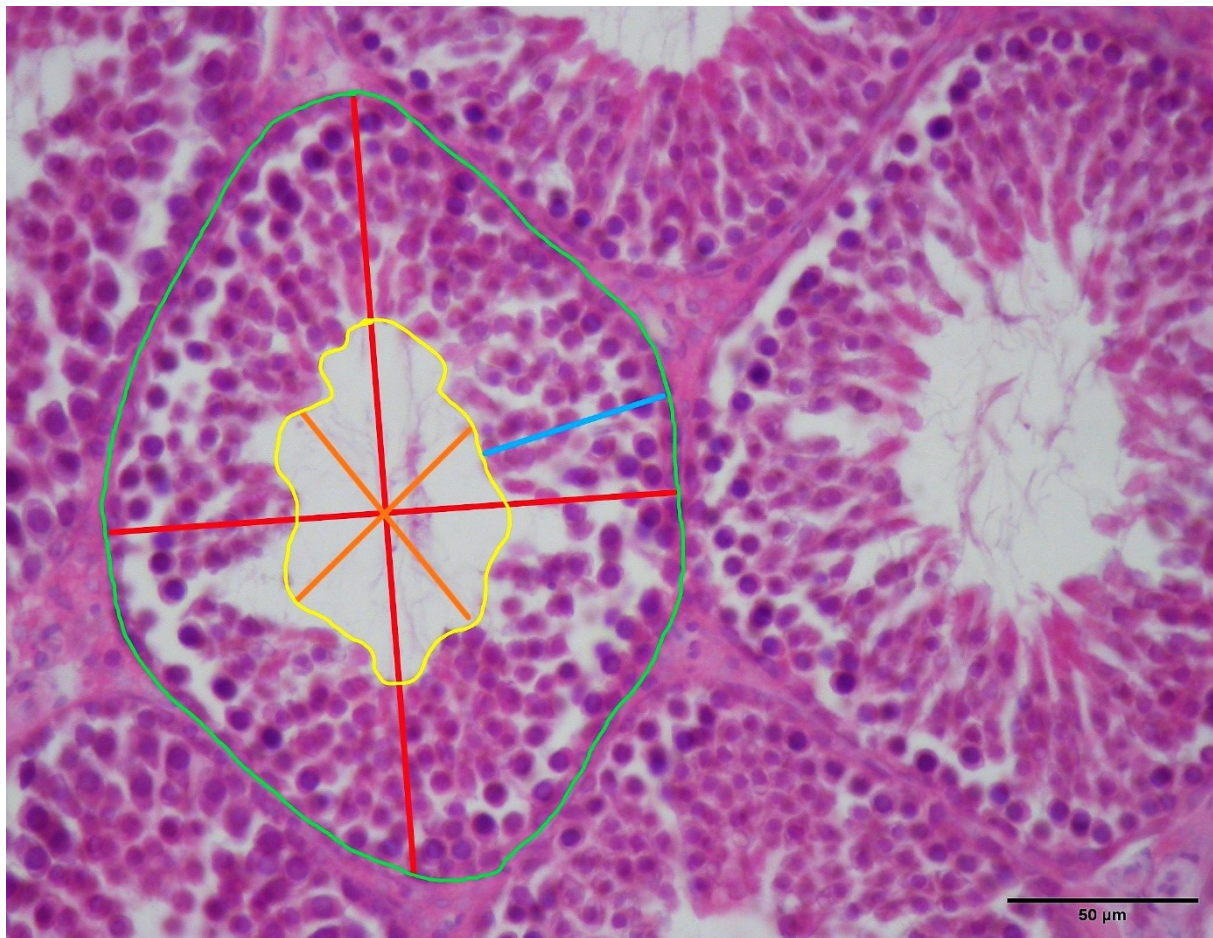
**Table 1**

Values by groups (expressed as the median (Mdn) / Q1 / Q3 / interquartile range (IQR)); MSTD - mean seminiferous tubular diameter, MSLD - mean seminiferous lumen diameter, epithelial height, tubular area, luminal area, Johnsen score. Group 1 – sham (S) / group 2 – torsion-detorsion group (T/D) / group 3 – torsion-detorsion group + ASX at the time of detorsion / group 4 – torsion-detorsion group + ASX 45 minutes from the moment of detorsion.

	MSTD ( $\mu\text{m}$ )				MSLD ( $\mu\text{m}$ )			
	Mdn	Q1	Q3	IQR	Mdn	Q1	Q3	IQR
Group 1	226.50	218.97	230.31	11.34	69.20	66.03	74.81	8.78
Group 2	172.38	168.56	179.75	11.19	101.21	99.64	105.32	5.68
Group 3	184.05	180.14	187.42	7.27	80.81	79.53	87.00	7.46
Group 4	195.62	179.65	200.92	21.27	100.80	97.18	103.98	6.80
	Tubular area ( $\mu\text{m}^2$ )				Luminal area ( $\mu\text{m}^2$ )			
	Mdn	Q1	Q3	IQR	Mdn	Q1	Q3	IQR
Group 1	38923.81	36879.02	40342.85	3463.84	3673.23	3506.63	3745.24	238.61
Group 2	27186.19	26390.51	28104.24	1713.73	8430.01	7912.04	9113.17	1201.13
Group 3	28353.39	26720.56	28994.32	2273.76	5322.76	4955.96	6006.11	1050.15
Group 4	29910.52	28933.63	30592.26	1658.64	7930.28	7712.77	8170.96	458.19
	Epithelial height ( $\mu\text{m}$ )				Johnsen score			
	Mdn	Q1	Q3	IQR	Mdn	Q1	Q3	IQR
Group 1	69.35	65.78	71.22	5.44	8.00	8.00	8.00	0.00
Group 2	35.92	33.10	38.36	5.26	5.00	5.00	5.00	0.00
Group 3	42.50	39.47	44.20	4.73	6.00	6.00	7.00	1.00
Group 4	45.18	43.26	47.52	4.26	7.00	7.00	7.00	0.00

**Figure 1**

Micrograph - measurements of seminiferous tubule parameters; seminiferous tubule diameter (red line), seminiferous luminal diameter (orange line) tubular area (green line), luminal area (yellow line), epithelial height (blue line).



**Figure 2**

One of the randomly selected cross-sections on which measurements were made (a - group 1; b - group 2; c - group 3; d - group 4) (H&E, x200).

