

Management of pelvic area trauma

El Sana, Hanan

Master's thesis / Diplomski rad

2021

Degree Grantor / Ustanova koja je dodijelila akademski / stručni stupanj: **University of Zagreb, School of Medicine / Sveučilište u Zagrebu, Medicinski fakultet**

Permanent link / Trajna poveznica: <https://um.nsk.hr/um:nbn:hr:105:405955>

Rights / Prava: [In copyright](#)/[Zaštićeno autorskim pravom.](#)

Download date / Datum preuzimanja: **2024-07-15**



Repository / Repozitorij:

[Dr Med - University of Zagreb School of Medicine Digital Repository](#)



UNIVERSITY OF ZAGREB
SCHOOL OF MEDICINE

Hanan El Sana

Management of Pelvic Area Trauma

GRADUATE THESIS



Zagreb, 2021.

This graduation paper was made at the Department for Trauma; Department of Surgery, Clinical Hospital "Rebro", School of medicine, University of Zagreb, mentored by assistant professor Ivan Dobrić, MD, PhD and was submitted for evaluation in the academic year of 2020/21.

Mentor of the graduate thesis: Assistant Professor Ivan Dobrić, MD, PhD

ABBREVIATIONS:

- ORIF- Open Reduction Internal Fixation
- PPP- Preperitoneal Pelvic Pack
- CT- Computed tomography
- OR- Operating Room
- SI- Sacroiliac
- DPA - Diagnostic Peritoneal Aspirate
- FAST - Focused Abdominal Sonography for Trauma
- ATLS- Advanced Trauma Life Support
- AP-Anteroposterior
- MRSA- Methicillin Resistant *S.aureus*
- REBOA- Resuscitative Endovascular Balloon Occlusion of the Aorta
- APC- Anteroposterior Compression
- LC- Lateral Compression
- VS- Vertical Shear

Table of contents:

1. Abstract	1
2. Introduction.....	3
2.1 Epidemiology	3
2.2 Pelvic anatomy	4
2.3 Mechanisms and associated injuries	5
3. Types of fractures.....	6
4. History and physical examination	9
5. Initial Evaluation	10
5.1 Diagnostic tests.....	11
6. Management.....	12
6.1 External stabilization	13
6.2 Preperitoneal Pelvic Pack.....	14
6.3 REBOA	15
6.4 Angioembolization	15
6.5 External Fixation	16
6.6 Internal Fixation	16
7. Complications	18
8. Outcomes	19

9. Conclusion.....	20
10. References	21
11. Acknowledgements	27
12. Biography	28

1. Abstract

Key words: trauma, pelvic trauma, pelvic fracture, management, initial evaluation, pelvic binder, PPP, stabilization, external fixation, ORIF

Among the different manifestations of trauma, complex pelvic injuries are some of the most dangerous and deadly trauma related lesions. Pelvic trauma is one of the most complex to manage in trauma care and occurs in 3% of skeletal injuries,, with associated mortality rates of 10-16%. Most pelvis injuries require a significant amount of force. The most common mechanisms of injury include motor vehicle accidents. Due to the high force associated with pelvic fractures, they are commonly associated with other injuries, require transfusions , and prolonged rehabilitation. The most common and worrisome associated injury is hemorrhage. Consequently, the management of trauma aims initially to restore the altered physiology. The main aims of proper pelvic trauma management are thus to control bleeding and stabilize the hemodynamic status. Early proper treatment can decrease the development of disabilities, preventing septic, urogenital, vascular, and sexual function complications. Once the patient with pelvic fracture is resuscitated and stabilized, definitive surgical management and anatomic restoration of the pelvic ring become the goal. Management includes stabilization with pelvic binders, preperitoneal pelvic packing, resuscitative endovascular balloon occlusion of the aorta, angiography for embolization of bleeding pelvic vessels, and operative stabilization of the pelvic fracture either internally (ORIF) or externally.

Sažetak

Ključne riječi: trauma, trauma zdjelice, prijelom zdjelice, upravljanje, početna procjena, vezivo za zdjelicu, PPP, stabilizacija, eksterna fiksacija, ORIF Među različitim manifestacijama traume, složene ozljede zdjelice su neke od najopasnijih i smrtonosnih lezija povezanih s traumom. Zdjelična trauma je jedna od najsloženijih u upravljanju traumom i javlja se u 3% skeletnih ozljeda, s pripadajućim stopama smrtnosti od 10-16%. Većina ozljeda zdjelice zahtijeva značajnu količinu sile. Najčešći mehanizmi ozljede uključuju nezgode motornih vozila. Zbog velike sile povezane s frakturama zdjelice, one su obično povezane s drugim ozljedama, zahtijevaju transfuzije i produljenu rehabilitaciju. Najčešća i zabrinjavajuća ozljeda je krvarenje. Prema tome, upravljanje traumom u svom početku ima za cilj vraćanje izmijenjene fiziologije. Glavni ciljevi pravilnog upravljanja traumom zdjelice stoga kontroliraju krvarenje i stabiliziraju hemodinamski status. Pravilan rani tretman može smanjiti razvoj invaliditeta, sprječavajući septičke, urogenitalne i vaskularne komplikacije te komplikacije seksualnih funkcija. Nakon što je pacijent s prijelomom zdjelice oživljen i stabiliziran, cilj postaju konačno kirurško upravljanje i anatomska obnova zdjelice. Upravljanje uključuje stabilizaciju s vezivima za zdjelicu, preperitonealno pakiranje zdjelice, resuscitativnu endovaskularnu balonsku okluziju aorte, angiografiju za embolizaciju krvarenja zdjelice te operativnu stabilizaciju prijeloma zdjelice, interno (ORIF) ili eksterno.

2. Introduction

Trauma is an important cause of mortality, especially in the younger population. Among the different manifestations of trauma, complex pelvic injuries are some of the most dangerous and deadly trauma related lesions. Pelvic trauma is one of the most complex to manage in trauma care and occurs in 3% of skeletal injuries (1). Blunt pelvic trauma can be associated with injuries to the musculoskeletal, lower genitourinary, and neurovascular structures, which can lead to significant morbidity and mortality. The majority of pelvis injuries are due to powerful blunt trauma, albeit elderly patients may sustain such injuries from a low energy trauma, such as a fall. High energy trauma increases the likelihood of accompanying injuries, likely involving the abdominal and pelvic viscera. Mortality in patients sustaining pelvic fractures has been reported to be 4% to 15% and are usually related to multiple trauma and massive hemorrhage (2). Early treatment that focusing on prevention of haemorrhage and sepsis is critical (3). Hemorrhage as a cause of death has decreased in the last decade possibly as a result of improved management techniques (2). In this paper, literature of current management of trauma to the pelvic area will be analyzed.

2.1 Epidemiology

Pelvic fractures account for approximately 3% of skeletal injuries, with associated mortality rates ranging between 10 and 16% (3). The mortality rates differ more when comparing the type of fracture; The mortality rate from pelvic injuries with acetabular fractures is 3% (4), while open pelvic fractures are associated with a mortality rate of up to 45% (3). Risk factors for pelvic fractures include a decrease

in bone mass, smoking, hysterectomy, older age, and a frequent falls (5). Adult patients who experience open pelvic fractures are usually young males with multiple injuries due to road traffic accidents (3).

2.2 Anatomy of the Pelvis

The pelvic girdle is a ring-like bony structure, located in the lower part of the trunk. It connects the axial skeleton to the lower limbs. The bony pelvis is comprised of 2 pelvic bones (composed of pubis, ischium and iliac bones), the sacrum and the coccyx. The ilium, ischium, and pubis fuse to form the acetabulum. There are three articulations within the pelvis: Inferiorly between the sacrum and the coccyx, posteriorly between the sacrum and each ilium (SI joint), and anteriorly between the pubic bodies (pubic symphysis). There are several strong ligaments connecting the pelvic bones and sacrum that give the pelvis support and provide stability. These ligaments include the anterior and posterior sacroiliac ligaments, sacrospinous, and sacrotuberous. Additionally, there are the symphyseal ligaments and ligaments between the lumbar spine and pelvic ring, such as the iliolumbar and lumbosacral (6). The pelvis and femur articulate via the acetabulum at the hip joint. There are 36 muscles that attach to the sacrum or innominates. The purpose of these muscles is primarily to provide stability to the joint. Within the pelvis there are numerous viscera. The pelvis contains the rectum, anal canal, and bladder. In females, the urethra, uterus, ovaries, and vagina also lie within the pelvis while the prostate is found in males. The pelvis has an extensive vascular supply. The two common iliac arteries divide at the level of the pelvic brim. The external iliac artery follows the pelvic brim to exit the pelvis underneath the inguinal ligament. The internal iliac artery lies more posterior in the

pelvis, particularly the posterior division as it overlies the sacroiliac joint. The posterior branch divides into the superior gluteal, iliolumbar, and lateral sacral arteries. The anterior division include the obturator and internal pudendal arteries and they can be injured in fractures involving the pubic rami. (6) The venous drainage from the pelvis consists of veins that course parallel to the arteries and a venous plexus that is found anterior to the sacrum. This venous plexus is highly susceptible to damage with sacroiliac injuries and is a common source of bleeding. The pelvic innervation, the lumbosacral plexus, originates from the nerve roots of L4 to S3 (6). The sacral nerves exit from the sacral neural foramina and can be injured with sacral fractures. Injuries to these nerves can result in bladder, bowel, and sexual dysfunction. The femoral and obturator nerves also lie within the pelvis and may be injured with pelvic trauma (6).

2.3 Mechanisms and associated injuries

The predominant mechanism of injury are road and traffic related. These include pelvic fractures due to motor vehicle collisions and motorcycle accidents (43-58%) or pedestrians struck by a motor vehicle (20-22%) (7). Falls also account for a substantial number of traumatic injuries to the pelvic region (5-30%) (7). Thus, while most pelvic ring injuries among young adults are caused by blunt trauma encountered after motor vehicle crashes, pelvic injuries in elderly patients more often result from falls (8).

High force trauma to the pelvis is often associated with internal injuries. The associated injuries often include life-threatening hemorrhage, typically due to bleeding from the venous plexus (9). Venous plexus bleeding is the source in up to

90% of cases (9). Arterial bleeding associated with pelvic trauma can be related to injury of the iliac vessels (10). The mechanism of injury is compression of the vessels against the pelvic brim or shearing that disrupts the integrity of the vessel wall (10).

Injuries to nerves are less common than vascular injuries with pelvic trauma, yet they still occur in 10-15% of trauma cases associated with pelvic ring disruptions (11). The most injured nerves in pelvic trauma are those of the lumbosacral plexus, which lies close to the sacroiliac joint and the acetabulum (11). Root avulsion can occur in more severe pelvic trauma. Injury usually occurs from traction or compression from a retroperitoneal bleed (11).

Intraabdominal injuries also occur with trauma to the pelvic area. The incidence of abdominal injuries stands at 16.5%, with the most commonly injured organs being the liver (6.1%) (12). Injuries to the bladder and urethra are also seen with pelvic trauma (5.8%) (12), yet males are 10 times more likely to sustain urethral injuries (13).

3. Types of Fractures

Trauma to the pelvis can result in numerous fractures and the different forces on the pelvis result in different fractures. These fractures include pelvic ring disruptions, sacral fractures, acetabular fractures, and avulsion injuries.

Pelvic fractures can be referred to as open or closed fractures (14). Further categorization of fractures describes them as haemodynamically stable or unstable. The two most commonly used classification systems for pelvic fractures

are the Tile classification (Tile 1988) and the Young-Burgess classification (Burgess et al 1990) (33,34). Both classify pelvic fractures based on the anatomic classification of the injuries (11). More specifically, the Tile classification (table 1) considers the stability of the pelvis, by categorizing injuries according to the stability of the pelvic ring and integrity of the posterior sacroiliac joints (14). The categories are divided into A (stable), B (partially stable) and C (unstable) (14).

Tile classification of pelvic fracture
Type A: Stable
▶ A1: Fractures of the pelvis not involving the ring.
▶ A2: Stable, minimally displaced fractures of the ring.
Type B: Rotationally unstable, vertically stable
▶ B1: Open book.
▶ B2: Lateral compression: ipsilateral.
▶ B3: Lateral compression: contralateral (bucket handle).
Type C: Rotationally and vertically unstable
▶ C1: Unilateral.
▶ C2: Bilateral.
▶ C3: Associated with an acetabular fracture.

Table 1: Tile classification of pelvic fracture (14).

On the other hand, the Young-Burgess classification system (Figure 1) is based on mechanism of injury: anteroposterior compression type I, II and III, lateral compression types I, II and III, and vertical shear, or a combination of forces (14). An anteroposterior compression grade III is a specific kind of pelvic fracture known as “Open book” fracture and it describes a complete disruption where the two halves of the pelvis are separated at the front and the rear, with the front opening

more than the rear (14). Unstable pelvic injuries, such as "open-book" fractures, may be associated with retroperitoneal hemorrhage, which can be severe (14).

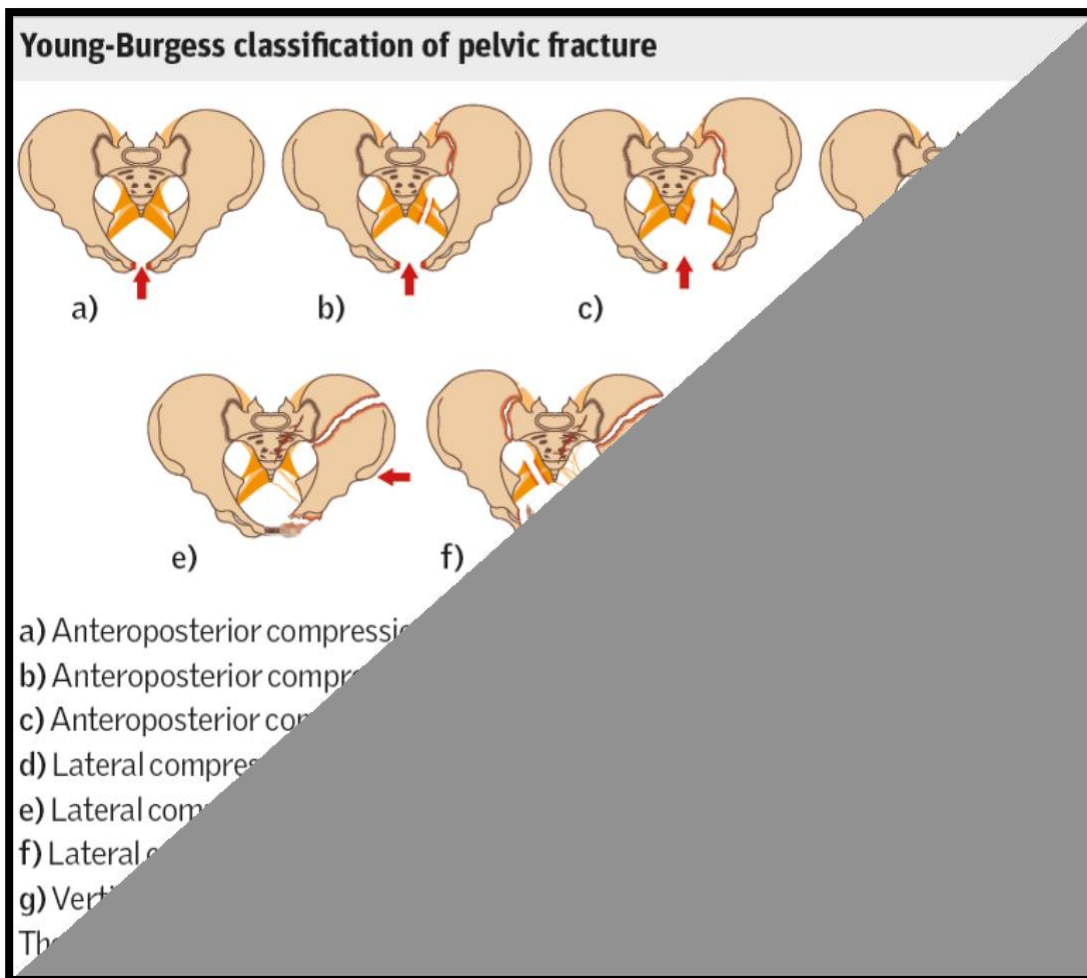


Figure 1: Young-Burgess classification of pelvic fracture (14)

Sacral fractures often go undiagnosed and may result in neurologic deficits to the lower extremities and urinary, rectal, and sexual problems (15). Denis (1998) developed a classification for sacral fractures (Figure 2) to provide a better understanding of associated neurological injuries. This classification is based on the direction, location, and level of sacral fractures (15). Three different sacral zones were identified as having characteristic clinical presentations. Zone I, the region lateral to the sacral neural foramina, was occasionally associated with

partial damage to the fifth lumbar root. Zone II, the region of the sacral neural foramina, is frequently associated with sciatica but rarely with bladder dysfunction. Zone III, the central sacral canal, is frequently associated with saddle anesthesia and loss of sphincter function (15).

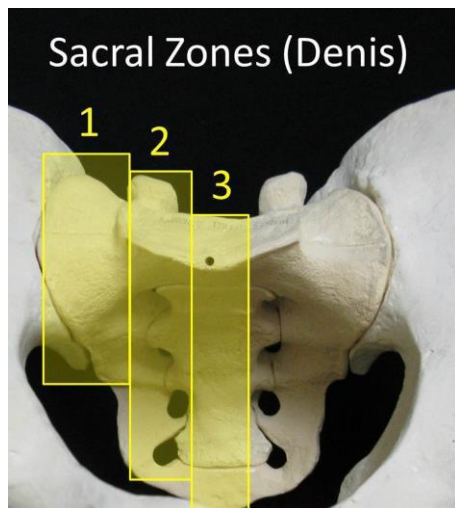


Figure 2: Denis' anatomical sacral zones (27)

4. History and Physical Examination

Any patient presenting with a history of significant blunt trauma should raise suspicion for a pelvic fracture (14). Since pelvic injuries are the result of high force trauma, patients frequently have multiple injuries. Important factors to consider when taking the patient's history are the type of injury, location of pain and where pain radiates to (14). The standard trauma history includes signs and symptoms, allergies, medications (especially anti-coagulants), last meal and event/environment related to the injury. Additional points to look at in the setting of trauma to the pelvis include the mechanism of injury, location of pain, bowel or bladder incontinence, numbness or weakness, bleeding (hematuria, rectal or vaginal bleeding) and last menstrual period (16). An initial detailed history is not essential to begin evaluating a patient with acute injuries. The emergency medical

system personnel bringing the patient to the trauma/resuscitation area of the emergency department will give a brief history of present illness. After the initial evaluation and stabilization of the patient, a detailed history can be obtained (11).

The physical examination of a patient following trauma to the pelvis should look for signs of external bleeding, ecchymosis, blood at the penile meatus, vaginal bleeding, and the position of the lower extremities and iliac crests. It is also important to inspect the back, gluteal region, and pannicular folds. A close neurovascular inspection should be done (17). Palpation of bony landmarks follows the inspection. These landmarks include the iliac crests, pubic symphysis, sacrum, sacroiliac joints, and greater trochanters. If there are no obvious limitations, range of motion is tested (17). Leg length discrepancy or rotational deformity of a lower limb may suggest a fractured femoral neck or migration of an unstable pelvis.(14). In an awake trauma patient, the history and physical exam are highly sensitive for pelvic trauma. (18)

5. Initial Evaluation

The initial evaluation of the trauma patient is the primary survey. The primary survey consists of assessing and stabilizing the airway, breathing/ventilation, and circulation. Disability is then evaluated by basic neurological evaluation. Finally, exposure and environmental control is done (19). A secondary survey follows the primary survey, and it consists of a full head-to-toe physical examination (20).

During the secondary survey, a digital rectal exam should be performed, as gross blood may indicate a gastrointestinal injury (11). Other signs, such as a high riding prostate, blood at the urethral meatus, inability to void, or gross hematuria could

indicate a urethral injury. Perineal hematoma and edema may indicate pelvic content injuries, while any instability indicates a pelvic fracture (11).

5.1 Diagnostic tests

Several imaging modalities can be useful during evaluation pelvic trauma. The first test of choice is a bedside ultrasound called Focused Abdominal Sonography for Trauma (FAST) scan. A FAST exam is used to identify free fluid, yet it can't differentiate between bowel contents and blood (11). Evaluation of the hemoperitoneum in the setting of a pelvic fracture can be difficult, especially in patients that are hemodynamically unstable. A retrospective study of the FAST examination in trauma patients with pelvic fractures showed that the test's sensitivity and specificity were 26% and 96%, respectively (21). Despite the low sensitivity of FAST, it is used frequently due to the high specificity and its bedside accessibility. It is important to keep in mind that in the case of a negative FAST and pelvic fracture, patients should undergo further evaluation (21).

Diagnostic peritoneal aspirate (DPA) is used when patients remain hemodynamically unstable but have negative FAST studies, in order to determine rapidly whether the source of bleeding is peritoneal or retroperitoneal. An aspirate of 10 mL or more of gross blood is considered positive for intraperitoneal bleeding (17). Thus, DPA is an important tool for determining whether intraabdominal free fluid detected by ultrasound is blood or urine (17,22).

A plain radiograph of the pelvis can be performed in hemodynamically unstable patients, but its utility in stable patients and those undergoing CT is questionable. A portable AP pelvis radiograph is recommended by Advanced Trauma Life Support protocol in all trauma patients suspected to have a pelvis injury based on mechanism or physical findings (17,23). The plain AP radiograph is used to check

for significant pelvic fractures, especially displaced fractures, open-book fractures, and injuries to posterior pelvis (17). However, if patients are hemodynamically stable, they should undergo further diagnostic workup with multi phasic CT-scan with intravenous contrast to exclude pelvic hemorrhage (1). Patients who undergo CT scanning during their immediate resuscitation do not need a routine plain pelvic radiograph (23).

The gold standard for diagnosing pelvic injuries is contrast- enhanced CT. CT has high sensitivity and delineates fractures in a detailed manner. CT can determine accompanying injuries, areas of arterial bleeding, and the extent of retroperitoneal hemorrhage (17,24). Additionally, a retrograde urethrogram or/and urethrocytogram with contrast CT-scan is recommended in presence of local perineal clinical hematoma and pelvic disruption at pelvic X-ray.(1)

6. Management

During daily clinical practice the first decisions in management of pelvis trauma are based primarily on the clinical conditions and the concomitant injuries, and less on the pelvic ring lesions. The management of trauma aims first to restore the altered physiology. Thus, the main aims of proper management are bleeding control and stabilization of the hemodynamic status, restoring of the eventual coagulation disorders and the mechanical integrity and stability of the pelvic ring, and preventing complications; then to definitively stabilize the pelvis (1). Hemodynamic stabilization is done by administering massive transfusion protocol as indicated (17,19). Besides the vigorous resuscitation, patients with open pelvic fractures (ie, with exposed bone) require treatment with broad spectrum IV antibiotics. Those include Cefuroxime or Vancomycin if there is concern for MRSA infection.

Patients should also receive prophylaxis against tetanus. Prophylactic treatment should be administered within 6 hours of open trauma and continued for 72 hours (17).

6.1 External Stabilization

Regardless of their grade, pelvic fractures have the potential to become life-threatening. After the initial evaluation that consisted of primary and secondary survey mentioned previously, initial management involves externally stabilizing the pelvis. The pelvis is stabilized by "wrapping" it with either a sheet or a commercial pelvic binder. (11,17). Applying non-invasive external pelvic compression is recommended as an early step to stabilize the pelvic ring and decrease the amount of pelvic haemorrhage in the early resuscitation phase(1). Pelvic binders should be placed when there are signs of pelvic ring disruption in either stable or unstable patients. The binder decreases bleeding in two ways. It compresses the bleeding from the bones, but it also decreases the volume within the pelvis. Pelvic binders are a temporary measure until a more definitive repair can occur. The pelvic binder is only useful if it is applied correctly; The binder must be placed around the greater trochanter and pubic symphysis to adduct the legs and decrease pelvic volume correctly (11,17). It is important to bear in mind not to over-reduce the fracture. Over-reduction can be evaluated clinically by the position of the patient's legs, greater trochanters, and patellae, which should lie in an anatomically neutral position. Radiographs should be obtained after the external stabilization to assess the adequacy of reduction (17,25). It is important to not leave the binder too long, as skin necrosis and pressure ulcerations can occur if

the binder is not removed rapidly and if it is too tight. Thus, pelvic binders should not be kept for more than 24–48 hours. (1).

Following initial pelvic stabilization, further management may include preperitoneal pelvic packing, resuscitative endovascular balloon occlusion of the aorta (REBOA), operative stabilization of the pelvic fracture (internally or externally), and angiography for embolization of bleeding pelvic vessels.(11, 17).

6.2 Preperitoneal Pelvic Pack

Preperitoneal pelvic pack (PPP) is a surgical procedure that involves putting laparotomy sponges into the preperitoneal space to create a tamponade effect. It is less time consuming than angioembolization, thus it is indicated in the hemodynamically unstable patient (25). Packing is performed by a vertical midline incision of 6 to 8 cm or Pfannenstiel incision. Dissection continues down to fascia, and then an incision is made in the midline of the fascia to access the preperitoneal space. Ringed forceps are then used to put six surgical pads into the space, three surgical pads on each side, with the first being pushed all the way to the sacrum. The same is performed on the contralateral side. Six surgical pads are typically enough to complete the packing. The fascia is then quickly closed over the surgical pads, and the skin is closed in a running fashion (11). External fixation of the pelvis can be performed concurrently with preperitoneal pelvic packing (1, 26). In general, if patient is hemodynamically stable, the pelvic fracture can be stabilized using an external fixation device alone, but if there is ongoing hemodynamic instability due to retroperitoneal bleeding from the pelvic fracture, then preperitoneal pelvic packing is performed as well (25).

6.3 Resuscitative Endovascular Balloon Occlusion of the Aorta

In patients with persistent hemodynamic instability (SBP<80mmHg), aortic occlusion should be considered until definitive treatment in the OR can be performed. This is done by a technique called Resuscitative Endovascular Balloon Occlusion of the Aorta (REBOA), which is an alternative to cross clamping the aorta (11). It uses a balloon catheter to occlude the aorta in an attempt to minimize life-threatening hemorrhage. The common femoral artery is used as the access point, by using an 18G needle to access the artery. A guidewire is then placed into the needle and advanced into the vascular system. The needle is removed, and the tract is dilated until a sheath can be inserted into the vessel (11). This is placed in aortic zone III when there is presumed pelvic fracture bleeding, and in aortic zone I if there is intra-abdominal bleeding (25). The catheter position is measured by measuring the distance from the umbilicus to the femoral catheter insertion site and is then inflated until moderate resistance is felt or there is a loss in the contralateral pulse. REBOA inflation time is ideally less than 30 minutes but can be used for up to 60 minutes. If a common femoral access site is not available, then the left brachial or left common carotid artery may be used (11).

6.4 Angioembolization of bleeding pelvic vessels

If CT shows evidence of arterial bleeding, patients should undergo angioembolization. Angioembolization is a technique in which the bleeding site is controlled with intra-arterial catheters that are used in order to place thrombotic agents into branches of the internal iliac arteries that are feeding the area of bleeding (25). Angioembolization is usually performed via a femoral artery

approach, but if the femoral is unavailable, then the left brachial or axillary artery may be used (11).

6.5 External fixation

External pelvic fixation provides rigid temporary pelvic ring stability and serves complementary to early haemorrhage control, by pelvic packing or angiography, in hemodynamically unstable pelvic ring injuries. External fixation can be done using frames, which include anterior external fixator or posterior pelvic C-clamp (25). The indication and technique of pelvic external fixation are based on the the Young & Burgess fracture classification (figure 3) (1). Unstable antero-posterior compression (APC-II/APCIII) and lateral compression injuries (LC-II/LC-III) injuries are fixed with anterior resuscitation frames, using iliac crest or supra-acetabular Schanz pin application. The iliac crest routine is less demanding and allows faster application, the pull-out resistance of Schanz pins in the iliac crest is very low and therefore associated with a higher risk of failure of reduction and fixation. On the other hand, supra-acetabular frames require pins to be placed very carefully, under radiographic control using a C-arm, but these frames have a very high pull-out resistance due to the solid supra-acetabular surgical corridor. In contrast, vertically unstable pelvic ring disruptions are best stabilized by a posterior C-clamp. It is important to note that C-clamps are not used in many trauma centers because due to the learning curve and required experience for safe application, and the fact that C-clamp is contraindicated in comminuted and transforaminal sacral fractures, fractures of the iliac wing, and lateral compression-type injuries

(1, 27). The external frame may serve as definitive fixation for six to eight weeks, or be removed once the fracture is internally stabilized (25).

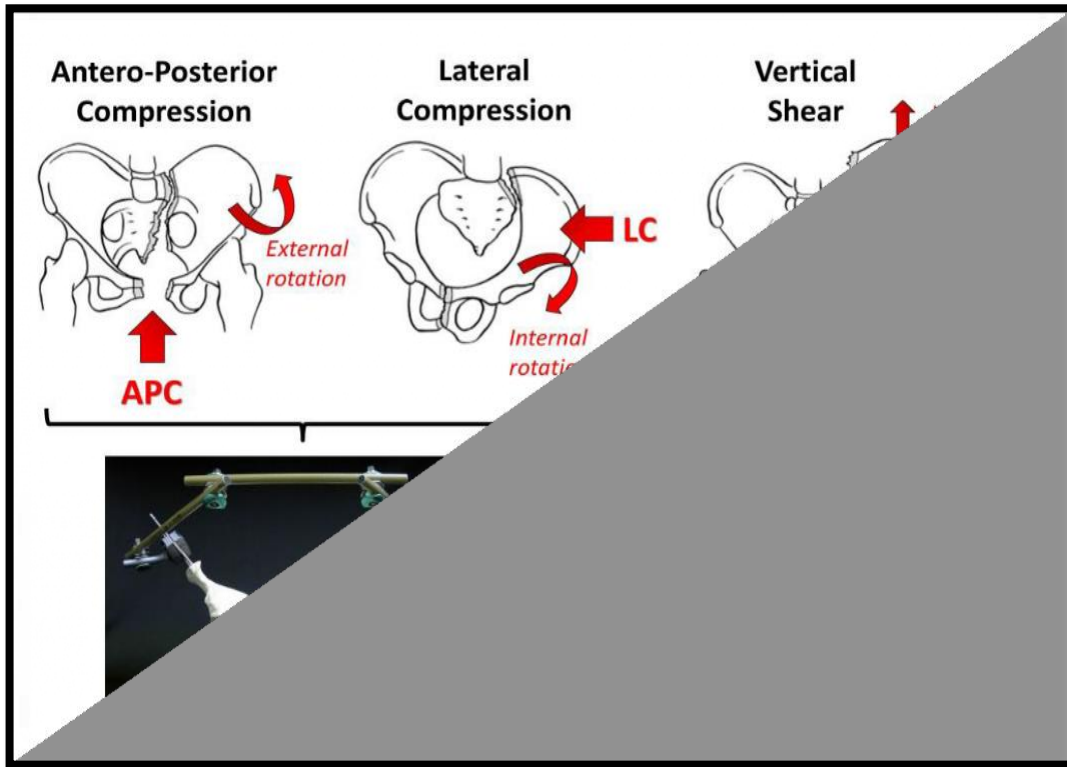


Figure 3 -Decision making for acute external fixation of pelvic ring disruptions guided by the underlying injury mechanism (27).

6.6 Internal fixation

Unstable pelvic fractures require surgical fixation. Definitive repair, if needed, is undertaken once the patient has been adequately resuscitated and stabilized (11). The decision for and timing of internal fixation is highly individualized. It depends on the nature of the pelvic fracture, severity of associated injuries, and the patient's chronic medical comorbidities. Definitive ORIF is often performed within 10 days of injury, after the patient has been properly stabilized. It has been shown that post-injury complication rates are increased if definitive repair is completed within four days of injury in polytrauma patients. Complications

decreased when surgery was delayed until six to eight days post-injury (11, 28). However, for some patients, especially those with concomitant thoracic or abdominal injuries, definitive treatment of the pelvic fracture may be accomplished by external fixation alone (25).

Posterior pelvic ring instability represents a surgical indication for anatomic fracture reduction and stable internal fixation (11). Fixation of posterior ring is done by percutaneous ilio-sacral screws or by open reduction of the sacroiliac joint (29). Other typical injury patterns requiring surgical fixation include rotationally unstable APC-II/APC-III (“open book”) injuries and LC-II fracture patterns, as well as rotationally and vertically unstable LC-III, vertical shear (VS), and combined mechanism fracture patterns require definitive internal fixation (1, 11). APC II is typically managed with anterior symphyseal plating. APC III is treated with anterior symphyseal multihole plating or external fixation with posterior stabilization using sacroiliac screws. LC II is treated with ORIF of the ilium, while LC III and VS require posterior stabilization with sacroiliac screws (11, 29).

7. Complications

Long-term complication after pelvic fracture are common. They include dyspareunia, fecal and urinary incontinence (1). Women with symphyseal disruption were at higher risk for developing sexual and excretory dysfunction. Men are also prone to sexual dysfunction, with 61% of patients reporting limitation in sexual function and 19% continuing on to persistent erectile dysfunction. Specifically, APC-type injuries and increasing age in men appear to be significant risk factors for erectile dysfunction (29). Other complications include residual physical disability, perineal and pelvic abscess, embolism or

thrombosis and chronic pain (1). Chronic pain can be associated with depression and anxiety (11). Infections can occur at the pin site in external fixation or with ORIF, and that can be treated with PO or IV antibiotics and debridement of the area (11). Lateral femoral cutaneous nerve injury can also occur following external fixation (30).

REBOA can lead to many complications, which mainly involve vessel injuries. arterial rupture, perforation, or dissection that can be caused by the balloon. The catheter itself can cause ischemia in the lower extremities and subsequent reperfusion injury and compartment syndrome (32).

8. Outcomes

While survival rate of patients sustaining pelvic fracture has improved significantly within the last decade, mortality rates in patients with high-energy pelvic trauma ranges from 10 to 16% (17,31). The mortality rates vary depending on the associated injuries. Most deaths in patients with pelvic fractures are not caused by the pelvic fracture itself but are linked to associated injuries (31). Overall, less than 50% of patients with pelvis injuries that required surgical repair return to their preinjury level of function (25).

9. Conclusion

Pelvis injuries range from the benign to life threatening. Patients with traumatic injury to the pelvis often concomitant injuries, which may be remote from or directly related to the pelvic fracture. The most common and worrisome associated injury is hemorrhage. Thus, in the management of severely injured and bleeding patients, a cornerstone is represented by the early evaluation and correction of the trauma induced hemodynamic instability. During daily practice, the first decisions are based primarily on the clinical condition of the patient. If patient presents to the ED with major pelvic trauma and hemodynamic instability, their immediate evaluation should include a FAST and they should be started on massive transfusion protocol. If the FAST examination is positive for signs of intra-abdominal fluid, they are sent to the OR to control intra-abdominal and pelvic hemorrhages. On the other hand, in the case of a negative FAST examination in hemodynamically unstable patient, further evaluation is needed. A portable AP pelvis radiograph is also indicated in hemodynamically unstable patients. If patients are hemodynamically stable, they are referred for CT. The management of trauma in fact aims first to restore the altered physiology. The main aims of proper pelvic trauma management are thus bleeding control and stabilization of the hemodynamic status, and preventing septic, urogenital, vascular, and sexual function complications. Hemodynamic instability is managed by PPP, REBOA or angioembolization. Initial pelvic stabilization is performed with pelvic binders that externally stabilize the fractured pelvis and decreases the volume within the pelvis. After hemodynamic stability is achieved and proper imaging is performed, definitive management of the pelvis can be achieved by either external fixation or internal fixation.

10. References:

1. Coccolini, F., Stahel, P. F., Montori, G., Biffl, W., Horer, T. M., Catena, F., ... Ansaloni, L. (2017). *Pelvic trauma: WSES classification and guidelines. World Journal of Emergency Surgery, (2017).*
2. Vaidya, R., Scott, A. N., Tonnos, F., Hudson, I., Martin, A. J., & Sethi, A. *Patients with pelvic fractures from blunt trauma. What is the cause of mortality and when? The American Journal of Surgery, 211(3), 495–500. (2016).*
3. Grotz, M. R. W., Allami, M. K., Harwood, P., Pape, H. C., Krettek, C., & Giannoudis, P. V. *Open pelvic fractures: epidemiology, current concepts of management and outcome. Injury, 36(1), 1–13. (2005).*
4. Costantini, T. W., Coimbra, R., Holcomb, J. B., Podbielski, J. M., Catalano, R., Blackburn, A., Moore, F. O. *Current management of hemorrhage from severe pelvic fractures. Journal of Trauma and Acute Care Surgery, 80(5), 717–725. (2016).*
5. Kelsey, J. L., Prill, M. M., Keegan, T. H. M., Quesenberry, C. P., & Sidney, S. *Risk Factors for Pelvis Fracture in Older Persons. American Journal of Epidemiology, 162(9), 879–886. (2005).*
6. Chaudhry SR, Nahian A, Chaudhry K. *Anatomy, Abdomen and Pelvis, Pelvis.* Treasure Island: StatPearls Publishing. (2020).

7. Balogh, Z., King, K. L., Mackay, P., McDougall, D., Mackenzie, S., Evans, J. A., Deane, S. A. *The Epidemiology of Pelvic Ring Fractures: A Population-Based Study. The Journal of Trauma: Injury, Infection, and Critical Care*, 63(5), 1066–1073. (2007).
8. Giannoudis, P. V., Grotz, M. R. W., Tzioupis, C., Dinopoulos, H., Wells, G. E., Bouamra, O., & Lecky, F. (2007). *Prevalence of Pelvic Fractures, Associated Injuries, and Mortality: The United Kingdom Perspective. The Journal of Trauma: Injury, Infection, and Critical Care*, 63(4), 875–883.
9. Gänsslen, A., Giannoudis, P., & Pape, H.-C. *Hemorrhage in pelvic fracture: who needs angiography? Current Opinion in Critical Care*, 9(6), 515–523. (2003).
10. Carrillo EH, Wohltmann CD, Spain DA, Schmiege RE Jr, Miller FB, Richardson JD. *Common and external iliac artery injuries associated with pelvic fractures. J Orthopedic Trauma*. (Jun-Jul 1999).
11. Tullington JE, Blecker N. *Pelvic Trauma*. Treasure Island (FL): StatPearls Publishing; (2020)
12. Demetriades D, Karaiskakis M, Toutouzas K, Alo K, Velmahos G, Chan L. *Pelvic fractures: epidemiology and predictors of associated abdominal injuries and outcomes. J Am Coll Surg*. (2002).

13. Bjurlin MA, Fantus RJ, Mellett MM, Goble SM. *Genitourinary injuries in pelvic fracture morbidity and mortality using the National Trauma Data Bank*. Journal of Trauma. (2009)
14. Walker, J. Pelvic fractures: classification and nursing management. Nursing Standard, 26(10), 49–57. (2011).
15. Denis F, Davis S, Comfort T. Sacral fractures: an important problem. Retrospective analysis of 236 cases. Clinical Orthopaedics and Related Research. (Feb, 1988).
16. ATLS, 9th Ed, American College of Surgeons, Trauma Committee, p. 14-5. (2012)
17. Fiechtl J. Pelvic trauma: Initial evaluation and management. In: UpToDate. UpToDate, Waltham, MA. (Accessed February, 2021).
18. Shlamovitz GZ, Mower WR, Bergman J, Chuang KR, Crisp J, Hardy D, Sargent M, Shroff SD, Snyder E, Morgan MT. How (un)useful is the pelvic ring stability examination in diagnosing mechanically unstable pelvic fractures in blunt trauma patients? J Trauma. (March 2009)
19. Raja A. , Zane R. Initial management of trauma in adults. In: UpToDate. UpToDate, Waltham, MA. (Accessed February, 2021).
20. Coughenour J. *Initial Evaluation and Management of the Injured Patient*. J. Missouri medicine, 115(5), 429–433. (2018).

21. Friese, R. S., Malekzadeh, S., Shafi, S., Gentilello, L. M., & Starr, A. *Abdominal Ultrasound is an Unreliable Modality for the Detection of Hemoperitoneum in Patients with Pelvic Fracture. The Journal of Trauma: Injury, Infection, and Critical Care*, 63(1), 97-102. (2007).
22. Tayal, V. S., Nielsen, A., Jones, A. E., Thomason, M. H., Kellam, J., & Norton, H. J. *Accuracy of Trauma Ultrasound in Major Pelvic Injury. The Journal of Trauma: Injury, Infection, and Critical Care*, 61(6), 1453–1457. (2006).
23. Guillamondegui OD, Pryor JP, Gracias VH, Gupta R, Reilly PM, Schwab CW. Pelvic radiography in blunt trauma resuscitation: a diminishing role. *J Trauma*. (Dec, 2002).
24. Mohseni S, Talving P, Kobayashi L, Lam L, Inaba K, Branco BC, Oliver M, Demetriades D. The diagnostic accuracy of 64-slice computed tomography in detecting clinically significant arterial bleeding after pelvic fractures. *American Journal of Surgery*. (Sep, 2011).
25. Burlew CC, Moore EE. Severe pelvic fracture in the adult trauma patient. In: UpToDate. UpToDate, Waltham, MA. (Accessed February, 2021).
26. S. Abrassart, R. Stern, R. Peter, Unstable pelvic ring injury with hemodynamic instability: What seems the best procedure choice and sequence in the initial management? *Orthopaedics & Traumatology: Surgery & Research*, Volume 99, Pages 175-182, (2003).

27. Stahel PF, Mauffrey C, Smith WR, et al. External fixation for acute pelvic ring injuries: decision making and technical options. *J Trauma Acute Care Surgery*. 75:882–7. (2013).
28. Pape HC, Griensven MV, Hildebrand FF, Tzioupis CT, Sommer KL, Krettek CC, Giannoudis PV., Epoff Study group. *Systemic inflammatory response after extremity or truncal fracture operations*. *Journal of Trauma*. (Dec, 2008),
29. Langford, J. R., Burgess, A. R., Liporace, F. A., & Haidukewych, G. J. *Pelvic Fractures: Part 2. Contemporary Indications and Techniques for Definitive Surgical Management*. *Journal of the American Academy of Orthopaedic Surgeons*, 21(8), 458–468. (2013).
30. McDonald C, Firoozabadi R, Routt ML, Kleweno C. *Complications Associated with Pelvic External Fixation*. *Orthopedics*. (Nov, 2017).
31. Hauschild O, Strohm PC, Culemann U, Pohlemann T, Suedkamp NP, Koestler W, Schmal H. *Mortality in patients with pelvic fractures: results from the German pelvic injury register*. *Journal of Trauma*. (2008 Feb).
32. Ribeiro Junior MAF, Feng CYD, Nguyen ATM, Rodrigues VC, Bechara GEK, de-Moura RR, Brenner M. *The complications associated with Resuscitative Endovascular Balloon Occlusion of the Aorta (REBOA)*. *World J. Emergency Surgery*. (2018)

33. Tile M. *Pelvic ring fractures: should they be fixed?* J Bone Joint Surg Br. (Jan, 1988).
34. Burgess AR, Eastridge BJ, Young JW, Ellison TS, Ellison PS Jr, Poka A, Bathon GH, Brumback RJ. *Pelvic ring disruptions: effective classification system and treatment protocols.* J Trauma. (July, 1990).

11. Acknowledgments

I wish to thank all the people whose assistance was a milestone in the completion of this project.

I wish to express my deepest gratitude to my mentor, assistant professor Ivan Dobrić MD, PhD, for giving me the opportunity to write this paper. It is wholeheartedly appreciated that your great advice and patience proved monumental towards my success.

I would also like to thank the University of Zagreb, School of Medicine in Croatia for giving me the opportunity to pursue my medical career.

I would like to pay my special regards to my family, without whom I wouldn't have been able to come so far.

12. Bibliography

Hanan El-Sana was born in Lakiya, Israel on December 7th, 1994 as the second of three children to an architect father and a special education teacher mother. She completed high school in 2013, where she majored in physics for three years. In 2013, she spent a year learning German in the city of Hannover, Germany. After returning to Israel in 2016, she studied at the Pre-Academic Preparatory Course for Medical Studies abroad in Tel-Aviv, Israel for three months and then applied for Medical Studies in English at Zagreb Medical School. She got accepted and began her studies in the academic year 2015-2016.