

Anterior cruciate ligament graft types

Elkabetz, Stav

Master's thesis / Diplomski rad

2021

Degree Grantor / Ustanova koja je dodijelila akademski / stručni stupanj: **University of Zagreb, School of Medicine / Sveučilište u Zagrebu, Medicinski fakultet**

Permanent link / Trajna poveznica: <https://um.nsk.hr/um:nbn:hr:105:456874>

Rights / Prava: [In copyright](#)/[Zaštićeno autorskim pravom.](#)

Download date / Datum preuzimanja: **2025-02-01**



Repository / Repozitorij:

[Dr Med - University of Zagreb School of Medicine Digital Repository](#)



**UNIVERSITY OF ZAGREB
SCHOOL OF MEDICINE**

Stav Elkabetz

**ANTERIOR CRUCIATE LIGAMENT GRAFT
TYPES**

Graduate thesis



Zagreb, 2021

This graduate thesis was done at the Department of Orthopaedic, University Hospital Center Zagreb, School of Medicine, Zagreb University, mentored by Associate Professor Mislav Jelic, MD, Ph.D. and was submitted for evaluation in the academic year 2020/2021.

LIST OF ABBREVIATIONS

ACL – anterior cruciate ligament

ALB – anterolateral bundle

AMB – anteromedial bundle

BTB – bone-patellar tendon-bone

FL – fascia lata

LAD – ligament augmentation device

LARS – ligament advanced reinforcement system

LCL – lateral collateral ligament

MBT – medial border of the tibia

MCL – medial collateral ligament

MRI – magnetic resonance imaging

PCL – posterior cruciate ligament

PLB – posterolateral bundle

PMB – posteromedial bundle

QT – quadriceps tendon

ROM – range of motion

SCT – subcutaneous tissue

ST-G – semitendinosus gracilis

TT – tibial tubercle

Table of Contents

1.	Summary	1
2.	Sažetak	2
3.	Introduction	3
3.1.	General information about Anterior cruciate ligament.....	3
3.2.	Anterior cruciate ligament injury	5
3.3.	Evaluation for Anterior cruciate ligament reconstruction	7
4.	Tunnel drilling techniques	8
4.1.	Femoral tunnel drilling	8
4.2.	Tibial tunnel drilling	9
5.	Autograft	9
5.1.	Bone – patellar tendon – bone graft	9
5.2.	Hamstring tendon graft.....	12
5.3.	Quadriceps tendon graft.....	14
5.4.	Fascia Lata graft	15
6.	Allograft tendon	17
7.	Synthetic Ligaments	18
8.	ACL graft selection	19
9.	Conclusion	20
10.	Acknowledgments	21
11.	References	22
12.	Biography	25

1. Summary

Anterior cruciate ligament (ACL) has an essential role in knee joint stabilization, as it prevents anterior tibial translation and medial tibial displacement. The ACL is the most frequent knee structure to be injured and the most common ligament injury due to sports activities. The ACL has little biological healing ability when injured, the treatment options can be physical therapy, and the standard treatment will be reconstruction surgery. The graft for ACL reconstruction needs similar properties as the native ACL, such as similar structural and mechanical qualities. There are several options of grafts for ACL; there are autografts which are grafts that are harvested from the patient's own tissues, allografts which are grafts that are harvested from a donor, and synthetic grafts which are made of artificial materials. There is as well variety of tissue origins from where the graft is taken; there are tendon grafts, bone-tendon-bone grafts, and bone-tendon grafts.

This thesis paper aims to give a review on the different types of ACL reconstruction grafts, the surgical technique of each type of graft, and the advantages and disadvantages of each graft.

2. Sažetak

Prednji križni ligament (ACL) ima osobito važnu ulogu u stabilizaciji zgloba koljena budući da sprečava prednju translaciju koljenskog zgloba i medijalno iščašenje goljenice. Ozljede prednjeg križnog ligamenta najčešće su ozljede koljena, posebice uslijed bavljenja sportom. Prednji križni ligament ima vrlo ograničenu mogućnost zacjeljivanja stoga je moguće liječenje fizikalnom terapijom ili rekonstrukcijski operativni zahvat. Presadak za rekonstrukciju prednjeg križnog ligamenta zahtijeva slična svojstva kao prednji križni ligament, poput strukturnih i mehaničkih kvaliteta. Pri rekonstrukciji prednjeg križnog ligamenta postoji nekoliko mogućnosti presatka; postoje autotransplantati odnosno presatci koji se uzimaju iz tkiva pacijenta, zatim alotransplantati koji se uzimaju od davatelja te sintetički presatci izrađeni od umjetnih materijala. Nadalje, podrijetlo presatka može biti različito. Postoje tetivni presatci, koštano-tetivno-koštani presatci i koštano-tetivni presatci. Cilj je ovoga rada pružiti pregled različitih vrsta presadaka pri rekonstrukciji prednjeg križnog ligamenta, kiruršku tehniku svake pojedine vrste te njihove prednosti i nedostake.

3. Introduction

3.1. General information about Anterior cruciate ligament

The knee joint is the largest and the most complex hinge joint in the human body. The knee joint consists of the following structures, the main knee joint is formed by the meeting of the femur and the tibia bones, the patella bone which set in the quadriceps's tendon, located anteriorly to the knee in the intercondylar of the femur, and the meeting point of the femur and the patella which form the patellofemoral joint. The knee joint is surrounded by a joint capsule consisting of two layers, an external fibrous layer, and an internal synovial membrane. The joint capsule is attached to the femoral condyles, tibial condyles, and the fibula. The joint capsule is also attached to the patella and the quadriceps tendon (QT) anteriorly and the popliteus and gastrocnemius muscles on the posterior side.

Ligaments are structures made of collagen fibers and aim to provide knee stability and strength. The ligaments can be divided into the ligaments surrounding the knee joint from the outside, which are collateral ligaments – medial collateral (MCL) and lateral collateral (LCL) ligaments. And to the ligaments that locate within the knee joint, the cruciate ligaments – are anterior cruciate (ACL) and posterior cruciate (PCL) ligaments. Each cruciate ligament consists of two bundles that extend from the femoral intercondylar fossa to the tibial intercondylar surfaces, anteriorly and posteriorly. The ACL bundles are the anteromedial bundle (AMB) and the posterolateral bundle (PLB). The PCL bundles are anterolateral bundle (ALB) and posteromedial bundle (PMB) (Figure 1). ACL has an essential role in stabilizing the knee by preventing the knee from sliding anteriorly, is doing so by binding between the anterior aspect of the tibia to the posterior aspect of the femur. PCL has a role in preventing the knee from sliding posteriorly by connecting the posterior surface of the tibia to the femur's medial surface. There are two menisci, medial and lateral menisci; menisci are cartilaginous pad structures that use as shock absorption and decrease the load applied on the knee. They are attached to the joint capsule and located between the femoral and tibial condyles¹. The

bursa is a structure of a sac filled with synovial fluid which surrounds the joint. The bursa functioning as a protecting surface for the knee from frictions of the tendons.

The Knee joint range of motion (ROM) is between 0 degrees when the knee fully extended to 135 degrees when the knee fully flexed. The muscle responsible for knee extension is the quadriceps muscle, the muscle responsible for knee flexion is the hamstring muscle.

The adult ACL length is about 3.5cm. The attachment of ACL found at the medial portion of the lateral condyle of the femur, ACL lies in a position that creates a spiral and inserts near the medial tibial plateau. ACL is crucial in stabilizing inward and outward angulations (varus and valgus) and internal and external rotation. Additionally, ACL functions as a stabilizer and controls the movement of anterior tibial translation and medial tibial displacement².

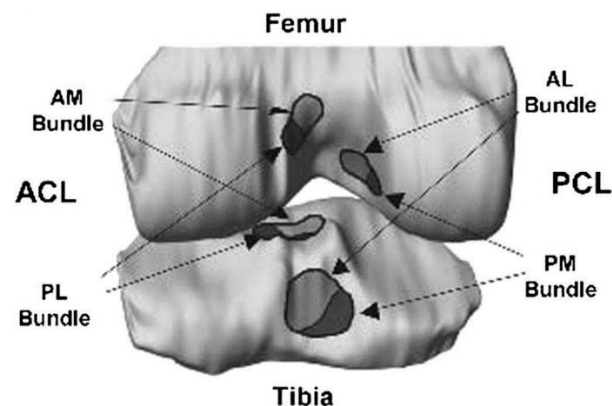


Figure 1. Knee model with anterior cruciate ligament (ACL) and posterior cruciate ligament (PCL) bundles insertion sites. ACL is divided into anteromedial (AM) bundle and posterolateral (PL) bundle. The PCL is divided into anterolateral (AL) bundle and posteromedial (PM) bundle³.

3.2. Anterior cruciate ligament injury

Knee injury widespread injury among athletes, particularly ACL injury, is the knee's most common ligament injury. In the United States, annually, ACL injuries are around 200,000 incidences^{4,5}. The highest risk athletes for ACL injuries are the football players with 53% of the total, basketball players, skiers, and gymnasts also have a high risk for ACL injuries⁶.

Studies have described differences in the susceptibility to ACL injuries among males and females. ACL injuries are more common among females, who have a 2.1-3.4-fold increased risk compared to males^{7,8}. A possible explanation for this difference between the sex given in the study was the claim that the ACL strength is a consequence of the strength and size of the quadriceps muscles, which is more prominent in male athletes than in females athletes⁹.

ACL injury mechanisms can be contact or non-contact mechanism, the majority of ACL injuries are by non-contact mechanisms¹⁰. Injury due to contact mechanism can be a consequence of direct trauma such as traffic accident or sports accident, non-contact mechanism of injury can be a consequence of landing, sidestep or plant-and-cut maneuvers which are the most common sporting tasks conduct this injury mechanism. Plant-and-cut or sidestep maneuvers correlated to an increase in the varus-valgus and internal rotation. In these two maneuvers, the ACL positioned at high risk for injuries. The classical ACL injury occurs while the knee is flexed and externally rotated, and the athlete changes the direction quickly and suddenly while the foot is planted^{11,12}.

In order to diagnose ACL injuries, there is a need for an entire detailed history and physical examination of the patient. A typical injury history will include a contact injury to the knee like trauma or a non-contact injury as jumping, cutting rotational action maneuvers, or lateral bending¹³. A typical patient complaint will be the feeling of the knee temporarily "popped out of its socket" or hearing a "pop" sound, swelling of the knee, and instability of the knee. In most ACL

injuries, physical examination is sufficient to confirm ACL injury. In order to assess anterior knee stability, the Lachman test is done, which has a sensitivity of 85% and specificity of 94% for ACL injuries. The Lachman test (Figure 2) is performed while the knee is flexed at 20 to 30 degrees while stabilizing the distal femur with one hand. With the other hand, apply force to the proximal tibia, and anterior laxity is assessed in the degree of anterior movement of the tibia relative to the femur^{14,15,16}. The gold standard examination is magnetic resonance imaging (MRI), which has a specificity of 95% and a sensitivity of 86% for diagnosing ACL injuries¹⁷. ACL injuries are commonly classified according to the severity of the injury and graded between 1 to 3. GRADE 1 is a mild injury that leads to microscopic tears in the ACL, which do not affect the knee joint function. GRADE 2 is a moderate injury in which the ACL is partially torn and affects the knee's stability. GRADE 3 is a severe injury in which the ACL is completely torn, which profoundly affects the knee function, the knee is highly unstable.

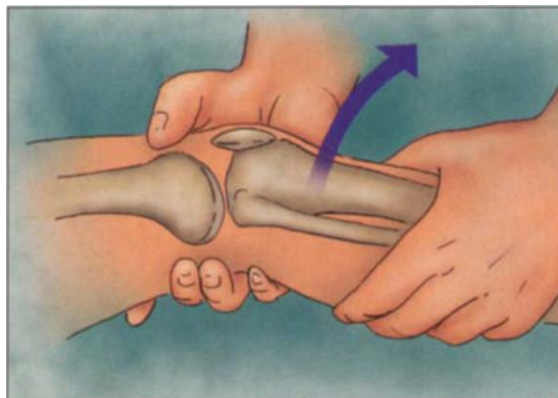


Figure 2. Lachman test - physical examination for anterior cruciate ligament (ACL) injuries. The arrow indicates direction of movement².

3.3. Evaluation for Anterior cruciate ligament reconstruction

A patient with a suspected ACL injury first needed to be evaluated clinically with history and physical examination, which will assess injury to the ACL. If ACL is suspected by the orthopedic, to have sufficient information regarding the injury and decide whether the patient needs a conservative treatment or surgical reconstruction, further investigation is needed. Using plain radiograph can provide information regarding fractures, loose bodies, degenerative disease, osteophyte formation, and other associated injuries¹⁸. Using arthroscopy as the gold standard, MRI is able to visualize both bundles of the native ACL, important information for surgical reconstruction.

Not all patients with ACL injuries are candidates for ACL reconstruction due to comorbidities diseases as severe cardiac, renal, or hepatic disease. Other patients may not be ACL reconstruction candidates, such as patients that are no longer interested in practicing sport and strenuous physical activities. The conservative treatment recommended for these patients is physical therapy, with the purpose of strengthening the knee muscles. Although, patients who are not operated, are suffering from unstable knees with prone to injuries¹⁹. Because of the failure results of the conservative approach to ACL injuries, the treatment of choice for ACL injuries is reconstruction surgery in athletes who desire to continue with strenuous physical activities²⁰.

In order to achieve a successful operation, we need to consider some factors that can influence the surgery outcome. General anesthesia can influence the final surgery result. It can be influenced by the patient's age and patient's medical conditions. As with any surgery, there is a possible risk of getting infected by hospital-acquired infection. ACL reconstruction aims to restore stability of the knee with a good fixation, with a standard function that has a full ROM.

4. Tunnel drilling techniques

The most common technical mistake that will lead to ACL reconstruction surgery failure is wrong tunnel placement, with higher percentages of incorrect placement femoral tunnel²¹. It is enough to have slight tunnel misplacement to have a significant effect on knee functions as an outcome of ACL reconstruction²².

4.1. Femoral tunnel drilling

For femoral tunnel drilling, there are two standard techniques, all-inside femoral tunnel and outside-in femoral tunnel.

For all-inside femoral tunnel drilling, there is a need to use an accessory anteromedial portal, which is a portal that lies medially to the patellar tendon. This portal use as a guide for positioning the femoral tunnel in the ACL footprint. By entering through the accessory anteromedial portal, the center of the tunnel is marked, the center is located between the lateral intercondylar ridge to the posterior articular border. Next, a beath pin is inserted into the marked center through the accessory portal. A cannulated drill of 4.5mm is used to drill through the far lateral cortex, the femoral tunnel is drilled to the desired diameter, the femoral tunnel drilled according to the measures of the planned graft, and to these measures, it is essential to add to the drilling depth 10mm extra to allow enough space for the suspensory fixation device.

In the Outside-in femoral tunnel drilling technique, the special guidance system for femoral drilling is inserted through the anterolateral portal, which is located close to the lateral border of the patella, to mark the femoral tunnel. A skin incision of 1.5cm is made, a guide pin is inserted in a lateral to the medial direction and placing the pin on the accurate location. The femoral tunnel is drilled in a diameter size between 6.5mm to 7mm, the diameter at the end of the tunnel is between 8.5mm to 9.5mm²³.

4.2. Tibial tunnel drilling

The tibial footprints are visualized, and the center of the tibial tunnel is marked. The tunnel center is found in line with the posterior border of the lateral meniscus, 15mm anteriorly to the PCL. A tibial drilling guidance system is inserted to the center of the planned ACL tunnel, which locates medially to the tibial tubercle (TT). Once the guide sets appropriately, the tibial tunnel is then drilled in size between 8.5mm to 9.5mm²³.

5. Autograft

5.1. Bone – patellar tendon – bone graft

ACL reconstruction was first done with a bone – patellar tendon – bone (BTB) autograft. This procedure has great results and has regained the opportunity for physically demanding patients to return to participate in physical activities²⁴. Compared to other ACL reconstruction graft outcomes, BTB autograft is the "gold standard²⁵." BTB autograft procedure can be divided into few steps: preoperative preparations, BTB harvest, ACL notch preparation, BTB graft preparation, femoral and tibial tunnels preparation, graft passage and fixation, and bone grafting and closure.

Pre-operation, a well-padded tourniquet placed on the injured leg on the upper thigh, a line of 9cm in length marked medially to the central portion of the tendon, which is superior to halfway up the patella, this line demarcates the planned incision.

The harvest is performed while the knee flexes to maintain tension on the patellar tendon. First, an incision is done over the 9cm mark, which exposes the patella and TT. With a scalpel cutting over to the retinaculum level, a small incision is made in the center part of the retinaculum to isolate the tendon. Once the tendon is isolated, its central one-third, which is the 10mm central portion of the tendon

marked. By using a 10mm wide saw, the cuts are performed, first to cut is the tibial part in order to prevent the bone harvest from bleeding into the tibial site, and then cut into the patellar part by using a curved osteotome harvesting the bone plugs (Figure 3). The surgeon moves the BTB autograft very gently to prevent it from slipping.

Notchplasty is performed on both anterior and posterior sides by widening the lateral wall in 1 to 2 mm of lateral wall and cartilage, using a curved osteotome, to achieve that more bone graft can be harvested in order to use it for grafting the patellar defect.

BTB graft preparation is done by fitting the bone plugs into trapezoids, measuring 25mm in the length of each bone plugs and a 10 mm cylindrical size so that the bone plugs will be able to pass without difficulties. After that, the BTB graft is placed in saline sank sponge.

Femoral tunnel preparation is done by a transtibial technique, and the tibial tunnel technique is done by standard techniques. Both femoral and tibial drilling tunnel techniques are explained in detail in chapter 4.

The following step is graft passage and fixation. The BTB autograft passed into the joint in a retrograde fashion by pulling the graft with the sutures that attached through the femoral bone plug. The graft is positioned in the femoral tunnel and in the notch. To prevent a graft injury, there is a need to set the tibial plug in the tunnel before passing the bone plug in the femur. The tibial plug can be injured if the graft is pulled too strong into the joint. Once the graft is located in the femur, there is a need to examine the graft and see if there is any graft construct mismatch. While the knee is fully extended, if there is a protuberant longer than 10mm of the bone plug out of the tibial tunnel, the graft construct is a mismatch, and there is a need to adjust the graft.

Once the graft locates appropriately in its place, a titanium screw is placed over the notch of the femoral plug, and once the screw is halfway in, the wire is removed to prevent wire retention. The tibial plug after placing the graft and orient it affixed with a titanium screw as well. An important part is grafting the patella donor site

carefully with a bone graft. Following that, the surgeon is suturing all the layers one by one.

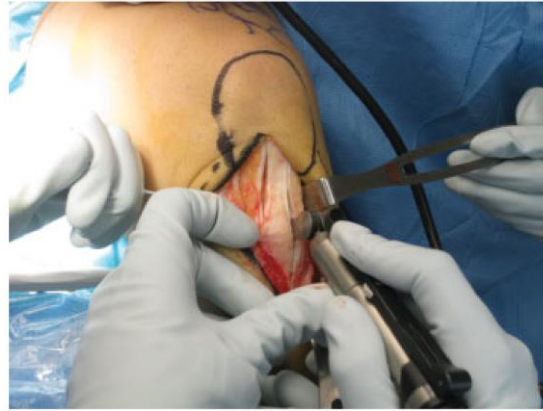

Figure 3. 10-mm sagittal saw is utilized to harvest the bone plugs²⁶.

Postoperative patients with BTB autograft reconstruction need to have a rehabilitation plan. The patient should be aware of the postoperative pain he might suffer from, local effusion, and need to protect the patellar harvest site for 4 to 6 weeks. The surgeon must stress out to the patient the importance of physiotherapy. Physiotherapy has been shown to correlate with better results after ACL reconstruction²⁶.

As with every surgery, BTB has advantages and disadvantages. The advantages are that BTB graft is improving knee stability- enabling the patient to regain participation in physical activities and decrease early rupture compared with other graft types. The bone at the end of the graft is placed in the bone's tunnel, making it a bone – to – bone healing process, which is a powerful healing method. There are also few disadvantages as anterior knee pain, which is a widespread complaint, the incidence is about 42%²⁷. The 9cm incision has theoretically increased the risk for infections. Not a particularly common complication, but the patient is at risk for patella fracture and patellar tendon rupture.

5.2. Hamstring tendon graft

The hamstring tendon autograft is a frequently used graft due to its qualities as comparable strength of native ACL, easy to access and easy to harvest the graft, and the graft length can be individualized customized²⁸.

Preoperatively the surgeon marks the incision line over the knee while the knee is in a 90 degrees flexion position. The two important landmarks for hamstring tendon harvest are the TT and the medial border of the tibia (MBT). Once TT and MBT are marked, a horizontal line is marked to connect the tip of each mark. This horizontal mark is divided into three equal parts, and a 15mm to 20mm vertical incision is marked. The incision is made first through the subcutaneous tissue (SCT), and then the sartorial fascia can be observed. Once the sartorial fascia is observed, it is important to keep the knee in a 90 degrees flexion position in order to maintain high tension of the hamstring tendons and identify the gracilis tendon pathway. A horizontal incision in the sartorial fascia is done to expose the semitendinosus gracilis (ST-G) tendons.

After the ST-G is exposed, the semitendinosus graft harvesting began. The tendon is grasped and rolling into a clamp to increase the tension to release it and prevent retraction. One hand of the surgeon is applying tension on the tendon, the other hand of the surgeon is releasing the tendon. Once the tendon released is passed to the preparation table²⁹. Once the semitendinosus graft harvesting is done, the gracilis tendon harvesting began. The surgeon pushes the tendon stripper in the direction along the gracilis tendon direction to release it from its muscle belly³⁰ (Figure 4). After the harvest of the graft, the graft needs to be prepared by extracting muscle fibers that are attached to the tendon. Next, the surgeon is placing a stitch on the proximal end of the graft. The graft's diameter is measured, the average graft size is between 8mm to 9mm in diameter.

After the graft is prepared, tunnel drilling is performed. The tibial tunnel drilling starts between the TT and the posteromedial edge of the tibia by using the native ACL footprint for a proper tunnel placing to have an anatomical position for the graft. The tibial tunnel length must match with the graft size. Next, the intercondylar

notch is prepared in a manner that once the patient's leg is in full extension, the ACL graft will be prevented from impingement and is done by resection of the bone along the inner aspect of the lateral femoral condyle.

The femoral tunnel drilling is done while the knee is flexed in 90 degrees to have the best access for drilling the tunnel. Once both of the tunnels are drilled, the graft placed in the femoral tunnel, and the end of the graft screwed in the femoral tunnel. With the graft is under tension, the graft is fixed at the tibial tunnel. Once the graft fixed from both sides, the incision is closed by suturing the ST, placed above it a gauze and elastic bandage, and above a brace and locks it zero-degree flexion. A rehabilitation postoperatively is done by using brace locks at zero degrees for two weeks. Physical therapy is recommended, the patient should meet with a physical therapist to guide him through the rehabilitation process. Early quadriceps muscle strengthening exercises are highly recommended to start at the first two weeks postoperative and will be directed by the physical therapist².

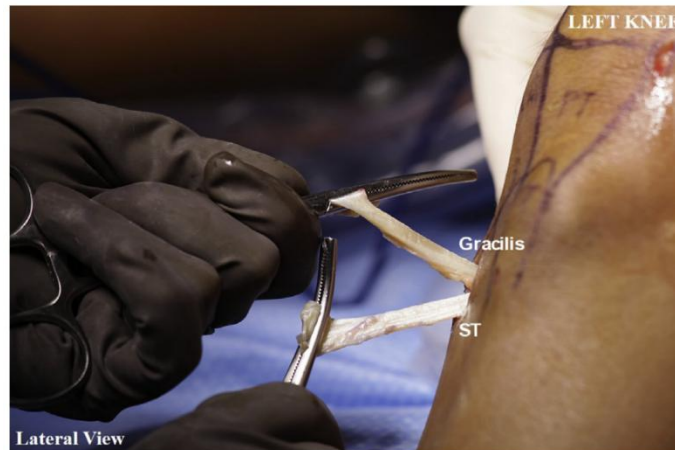

Figure 4. Semitendinosus (ST) and gracilis tendons harvesting²⁸.

5.3. Quadriceps tendon graft

QT autograft is infrequently used as a graft for ACL reconstruction surgeries, although it has good clinical results and low donor site complications. The QT has a unique quality that gives the ability to harvest a single bundle graft, reducing the interference of the native anatomy. This quality of the QT graft makes it a good choice for all inside techniques.

Preoperatively, the patient is prepared by nerve block procedure to the sciatic nerve and the adductor canal nerve. Once the patient is under generalized anesthesia, a tourniquet is placed on the upper thigh of the operated leg.

The graft harvest is performed as a minimally invasive QT graft harvest. During the harvest, the knee is in a 90 degrees flexion position to increase tension on the quadriceps and facilitate harvesting. Saline and epinephrine are injected into the area of the harvest to distend the tissue from the tendon. Incision of 2cm is done vertically at the apex of the patella, SCT is removed to have a better visualization. By using an arthroscope to have a better visualization of the tendon, marked a 7cm line on the anterior thigh from the upper border of the patella. The marked line is using as a guideline for harvest the graft carefully. Approximately 7cm tendon is harvested using tendon graft cutting guide. Next, the graft is taking carefully for preparation and adjustments. Notchplasty is performed after inspection of the native ACL insertion on the tibia and the femoral origin, the remnants of the ACL on the tibia are kept in their places to have a reference. Tunnels on both the femoral side and tibial side are drilled. The femoral tunnel is prepared by drilling a tunnel of 25mm, and the footprint femoral ACL guide is placed at 110 degrees. The tibial tunnel preparation is done through a 2cm skin incision at the anteromedial tibia, a tunnel of 30mm is drilled at the native footprint, and the tibial guide is placed at 60 degrees. The goal of QT graft fixation is 20mm of graft in each tunnel. The graft is first passed through the femoral tunnel, and the graft is pulled through the far medial portal, is pulled all the way up to the proximal end of the QT graft placed in the intraarticular femoral tunnel area. Then, the distal portion of the QT graft is

placed in the tibial tunnel. After the graft is placed correctly, the surgeon ensures no graft restriction by examining for negative Lachman test and pivot shift test.

The wound area is washed and cleaned of debris. The closure of the wound is done by suturing the subcutaneous and the skin in a standard fashion.

Postoperative rehabilitation consists of 6 phases and starts 3 to 4 days after the surgery. The first phase includes wearing a hinged brace locked in full extension for the first six weeks postoperative, and the brace kept locked in extension position for the first two to four weeks. In order to regain quadriceps function, during the first week after the operation, ROM exercises are initiated. In the second phase, the patient exercises focus on improve ROM. The goal is 90 degrees by week 4. The third phase goals are to regain full ROM, return the muscular strength and regain a good knee balance. The goals of phases 4 and 5 are to strengthen and endurance of the knee. Phase 6 includes a return to run, which can start only four months post-operation³¹.

5.4. Fascia Lata graft

Fascia Lata (FL) graft has few advantages over the other graft mentioned above, it has high biomechanical resistance, and the fixation of the graft at the tibial side does not need a mechanical fixation, which is a natural fixation.

The FL graft technique started by marking the incision position over the thigh. The incision starts across from the lateral femoral epicondyle, continuing to the posterior part of the lateral side of the thigh for 6 cm. After the incision is done, the ST is separated from the FL. After the FL has been exposed, the place where the graft harvest point should start exposed as well, precisely 16cm above the TT. The FL harvest graft should be in a length of 18 cm to 20cm, with 2cm width in the distal portion, which is also the thickest portion of the FL graft, and 4cm at the proximal portion, which is the thinner portion of the graft. While the FL graft is harvesting, there is a need to be very cautious in the incision depth to prevent damage to the underneath organs such as vastus lateralis, the joint capsule, and the lateral

collateral ligament (LCL). The FL is carefully harvested from the joint capsule, its proximal portion is stitched to enable easy passage in the tunnels. Next, the vastus externus muscle is separated from the lateral intramuscular septum, which separates the anterior compartment from the posterior compartment of the thigh. The septum is opened all the way longitudinally to the proximal end of the FL harvesting location. The next phase is the tunnel drilling phase, the femoral tunnel is drilled, its intraarticular exit locates on the posterior side of the lateral condyle, the tunnel diameter is 9mm. The tibial tunnel diameter is about 8mm, and its intraarticular exit locates between the tibial eminences. Insertion of a guidewire to the graft location is done in a retrograde fashion, from the outside to the inside. After the guidewire is inserted, the pull-through stitches are inserted in the same manner as the guidewire, from the outside to the inside, first through the femoral tunnel and then to the tibial tunnel. After the FL graft is placed correctly at the donor site, the graft is fixated to its place. On the tibial side, the graft is attached at 30 degrees flexion with an interference screw. On the femoral side, there is no need for a mechanical fixation.

The closing of the wound starts with suturing the harvest location. The intramuscular septum shifted to the lateral and closed, the skin is closed lastly. Postoperative rehabilitation should be done in a very progressive way at the first month postop, the leg is supposed to keep in a complete extension and flexion limited to 70 degrees, and crutches should aid the patient for the first month³².

6. Allograft tendon

For the last decade, there is an increase in allograft use for ACL reconstruction procedures. In a study that performed in the United States, over 16,000 ACL reconstructions, in 42.4% of the incidents allograft used for primary ACL reconstruction surgeries³³.

Types ACL reconstruction allografts can be divided into two groups, soft tissue allografts, and bone-tendon-bone allografts. Description of subtypes of these two groups found in figure 3.

Each allograft is harvested from a different site of the body, hence each allograft has different qualities as strength and stiffness. Before ACL reconstruction, the graft size should be prepared according to the patient's native anatomy. In allograft ACL reconstruction, a bigger graft diameter has a better effect on the graft's mechanical properties³⁵.

Allograft has both advantages and disadvantages. The disadvantages of the allograft are that it has a high cost, has a higher failure rate than the autograft, the graft mechanical strength can be negatively affected due to the sterilization techniques and use of irradiation, and the patients are at a higher risk for infections transmission and immunogenic reaction. The advantages of allograft are the fact that the patient is not having morbidities on the harvested site neither during the surgery and neither afterward during rehabilitation, reduced operating time, more minor scars, less arthrofibrosis, and availability of adequately sized graft^{36,37}.

A patient who is considering an allograft for ACL reconstruction should take into consideration all the advantages and disadvantages of allograft very seriously before making a decision.

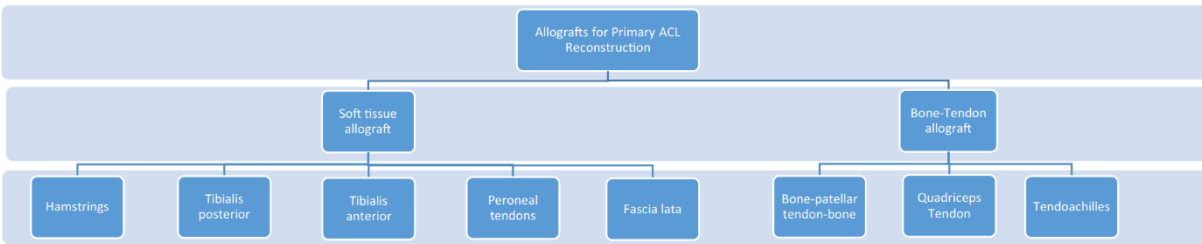


Figure 3. Types of allografts for primary anterior cruciate ligament (ACL) reconstruction³⁴.

7. Synthetic Ligaments

Synthetic ligament grafts for ACL reconstruction are a solution that started at the beginning of the 20th century. The aim of developing artificial materials for ACL reconstruction grafts was to improve the strength and stability of the ACL graft and to reduce the reconstruction site morbidity³⁸. Synthetic grafts are more available, simplifying the surgery and, very importantly, are preventing graft harvesting and its complications.

The synthetic grafts for ACL reconstruction have been used as a prosthesis, stents, and scaffolds. Prostheses grafts have few types as Gore-Tex-graft, Stryker Dacron graft, and ABC graft. The most known synthetic stent is the Kennedy Ligament augmentation device (LAD). A type of synthetic scaffold is the carbon fiber scaffold ligament, which aims to stimulate fibrous tissue ingrowth and strengthen the new ligament³⁹.

One type of artificial ligament graft is the ligament advanced reinforcement system (LARS). The LARS is a non-absorbable artificial ligament that consists of terephthalic polyethylene polyester fibers. The LARS consists of 2 portions, the extra-articular part, and the intra-articular part, which are designed as a replication of the ACL.

The patients with an ACL reconstruction using LARS graft have been followed and evaluated for ten years post-operation. The short-term results were satisfying⁴⁰. A follow up of 2.5 years postop have shown encouraging results⁴¹. A follow up of 8 years postop have shown satisfying results without postoperative complication, except for

one case of LARS rupture⁴². A follow-up of 10 years postop has shown a lack of satisfaction in half of the patients. Therefore, there is a suggestion not to include the LARS as a potential treatment for ACL reconstruction⁴³.

8. ACL graft selection

There are few considerations to keep in mind in selecting ACL graft, whether to use autograft versus allograft or synthetic ligament and grafts with a bone plug or soft tissue grafts. ACL graft reconstruction must meet some characteristics in order to achieve the best ACL reconstruction results. The graft must have structural and mechanical qualities similar to those of the native ACL, and the graft must have low antigenicity. The age of the patients and their physical activity must be considered- if the patients are young or highly physically active, if the patients are moderately physically active or recreational athletes, or if the patients are older or are less physically active. For the first category of patients, athletes who are practicing strenuous physical activities, and young patients who are highly physically active, the graft of choice is BTB autograft. In recent years QT autograft has also become a viable option for this group of patients. Hamstring autograft and allograft are common grafts choice for ACL reconstruction, since it has shown higher failure rates and increased postop laxity, and these two options are not highly recommended for this group of patients. For the second category of patients, patients who are moderately physically active and recreational athletes, the graft of choice is hamstring autograft. Hamstring autograft, compared to hamstring allograft, has a lower failure rate, and compared to BTB, in hamstring autograft, there is no donor site morbidity. For the third category of patients, older or patients who are less physically active, first, it is recommended to start with nonoperative treatment. If that option fails, the graft of choice is hamstring autograft as well as for the second category⁴⁴.

9. Conclusion

In this thesis paper, the different graft options for ACL reconstruction are mentioned, each graft's surgical technique reviewed, and the advantages and disadvantages discussed according to the results of the conducted studies.

According to studies, factors that affect the most on surgery results are the appropriate tunnel drilling, graft placement in the correct location, and the graft type.

We could learn from the conducted studies that the most commonly used ACL reconstruction grafts are autograft Hamstring tendon and autograft bone – patellar tendon – bone, the latter showed to have better outcomes. Quadriceps and fascia lata grafts have become more common graft sources in the last years but still are not used very frequently. Allografts are recently more common as well but have a higher failure rate compared to autografts. Synthetics grafts are an option for ACL reconstruction as well, but they are still not the best graft options. Synthetic grafts are in the development process and getting better and more sophisticated with time.

When the surgeon decides on graft for ACL reconstruction, he needs to consider the evidence behind each graft, the patient's physicals needs, and expectations, and based on these factors and his experience, he should decide on the most appropriate graft option for the patient. These days the technology is developing very fast, and there are many researches that are done in the medical field, so it will be reasonable to assume that with time there will be more options for treating ACL injuries, and they might be even better than the options that are available these days.

10. Acknowledgments

I would like to thank my mentor Associate Professor Mislav Jelic, MD, Ph.D., with whom I had the pleasure to work with and receive professional guidance and support along the way.

I would like to thank the University of Zagreb for allowing me to accomplish my dream of becoming a medical doctor.

A very special thank you is to my parents and my entire family for their endless and unconditional love and support throughout this journey.

Furthermore, I would like to thank my boyfriend, for being my support system during difficult times and for sharing this journey with me.

11. References

- 1 Alexander EL, Meeker MH, Rothrock JC. *Alexander's care of the patient in surgery*. St. Louis: Mosby; 1999.
- 2 Boni DM, Herriott GE. Hamstring tendon graft for anterior cruciate ligament reconstruction. *AORN J*. 2002;76(4):610–24.
- 3 Siegel L, Vandenakker-Albanese C, Siegel D. Anterior cruciate ligament injuries: Anatomy, physiology, biomechanics, and management. *Clin J Sport Med*. 2012;22(4):349–55.
- 4 Buoncristiani AM, Tjoumakaris FP, Starman JS, Ferretti M, Fu FH. Anatomic double-bundle anterior cruciate ligament reconstruction. *Arthroscopy*. 2006;22(9):1000–6.
- 5 Freedman KB, D'Amato MJ, Nedeff DD, Kaz A, Bach BR Jr. Arthroscopic anterior cruciate ligament reconstruction: a metaanalysis comparing patellar tendon and hamstring tendon autografts. *Am J Sports Med*. 2003;31(1):2–11.
- 6 Hootman JM, Dick R, Agel J. Epidemiology of collegiate injuries for 15 sports: summary and recommendations for injury prevention initiatives. *J Athl Train*. 2007;42(2):311–9.
- 7 Joseph AM, Collins CL, Henke NM, Yard EE, Fields SK, Comstock RD. A multisport epidemiologic comparison of anterior cruciate ligament injuries in high school athletics. *J Athl Train*. 2013;48(6):810–7.
- 8 Beynon BD, Vacek PM, Newell MK, Tourville TW, Smith HC, Shultz SJ, et al. The effects of level of competition, sport, and sex on the incidence of first-time noncontact anterior cruciate ligament injury. *Am J Sports Med*. 2014;42(8):1806–12.
- 9 Anderson AF, Dome DC, Gautam S, Awh MH, Rennirt GW. Correlation of anthropometric measurements, strength, anterior cruciate ligament size, and intercondylar notch characteristics to sex differences in anterior cruciate ligament tear rates. *Am J Sports Med*. 2001;29(1):58–66.
- 10 Boden BP, Dean GS, Feagin JA Jr, Garrett WE Jr. Mechanisms of anterior cruciate ligament injury. *Orthopedics*. 2000;23(6):573–8.
- 11 Griffin LY. Non-contact anterior cruciate ligament injuries: Risk factors and prevention strategies. *J Am Acad Orthop Surg*. 2000;8:141–150.
- 12 Olsen O-E, Myklebust G, Engebretsen L, Bahr R. Injury mechanisms for anterior cruciate ligament injuries in team handball: a systematic video analysis: A systematic video analysis. *Am J Sports Med*. 2004;32(4):1002–12.
- 13 Krosshaug T, Nakamae A, Boden BP, Engebretsen L, Smith G, Slauterbeck JR, et al. Mechanisms of anterior cruciate ligament injury in basketball: video analysis of 39 cases: Video analysis of 39 cases. *Am J Sports Med*. 2007;35(3):359–67.
- 14 Benjaminse A, Gokeler A, van der Schans CP. Clinical diagnosis of an anterior cruciate ligament rupture: a meta-analysis. *J Orthop Sports Phys Ther*. 2006;36(5):267–88.
- 15 Dh, Dk S, Dw B. The rational clinical examination. Does this patient have a torn meniscus or ligament of the knee? Value of the physical examination. *JAMA*. 2001;286:1610–1620.
- 16 Ostrowski JA. Accuracy of 3 diagnostic tests for anterior cruciate ligament tears. *J Athl Train*. 2006;41(1):120–1.
- 17 Spindler KP, Wright RW. Clinical practice. Anterior cruciate ligament tear. *N Engl J Med*. 2008;359(20):2135–42.
- 18 Sherman MF, Warren RF, Marshall J, Savatsky GJ. A clinical and radiographical analysis of 127 anterior cruciate insufficient knees. *Clin Orthop Relat Res*. 1988;NA;(227):229-237.
- 19 Levy BA. Is early reconstruction necessary for all anterior cruciate ligament tears? *N Engl J Med*. 2010;363(4):386–8.
- 20 Li G, DeFrate LE, Sun H, Gill TJ. In vivo elongation of the anterior cruciate ligament and posterior cruciate ligament during knee flexion. *Am J Sports Med*. 2004;32(6):1415–20.

- ²¹ Ahn JH, Jeong HJ, Ko CS, Ko TS, Kim JH. Threedimensional reconstruction computed tomography evaluation of tunnel location during single-bundle anterior cruciate ligament reconstruction: A comparison of transtibial and 2-incision tibial tunnel-independent techniques. *Clin Orthop Surg*. 2013;5:26–35.
- ²² Herbort M, Domnick C, Raschke MJ, Lenschow S, Förster T, Petersen W, et al. Comparison of knee kinematics after single-bundle anterior cruciate ligament reconstruction via the medial portal technique with a central femoral tunnel and an eccentric femoral tunnel and after anatomic double-bundle reconstruction: A human cadaveric study. *Am J Sports Med*. 2016;44(1):126–32.
- ²³ Burnham JM, Malempati CS, Carpiaux A, Ireland ML, Johnson DL. Anatomic femoral and tibial tunnel placement during anterior cruciate ligament reconstruction: Anteromedial portal all-inside and outside-in techniques. *Arthrosc Tech*. 2017;6(2):e275–82.
- ²⁴ Gobbi A, Francisco R. Factors affecting return to sports after anterior cruciate ligament reconstruction with patellar tendon and hamstring graft: a prospective clinical investigation. *Knee Surg Sports Traumatol Arthrosc*. 2006;14(10):1021–8.
- ²⁵ Reinhardt KR, Hetsroni I, Marx RG. Graft selection for anterior cruciate ligament reconstruction: a level I systematic review comparing failure rates and functional outcomes. *Orthop Clin North Am*. 2010;41(2):249–62.
- ²⁶ Provencher CM, Ryu J, Gaston T, Dewing LC. Technique: Bone-patellar tendon-bone autograft ACL reconstruction in the young, active patient. *J Knee Surg*. 2011;24(02):083–92.
- ²⁷ Leys T, Salmon L, Waller A, Linklater J, Pinczewski L. Clinical results and risk factors for reinjury 15 years after anterior cruciate ligament reconstruction: a prospective study of hamstring and patellar tendon grafts. *Am J Sports Med*. 2012;40(3):595–605.
- ²⁸ Park K, Brusalis CM, Ganley TJ. The 8-strand hamstring autograft in anterior cruciate ligament reconstruction. *Arthrosc Tech*. 2016;5(5):e1105–9.
- ²⁹ Olivos-Meza A, Suarez-Ahedo C, Jiménez-Aroche CA. Anatomic Considerations in Hamstring Tendon Harvesting for Ligament Reconstruction. *Arthrosc Tech*. 2020;2020;9(1):e191-e198:09 021.
- ³⁰ Brown CH Jr, Steiner ME, Carson EW. The use of hamstring tendons for anterior cruciate ligament reconstruction. Technique and results. *Clin Sports Med*. 1993;12(4):723–56.
- ³¹ Saper MG. Quadriceps tendon autograft anterior cruciate ligament reconstruction with independent suture tape reinforcement. *Arthrosc Tech*. 2018;7(11):e1221–9.
- ³² Khiami F, Wajsfisz A, Meyer A, Rolland E, Catonné Y, Sariali E. Anterior cruciate ligament reconstruction with fascia lata using a minimally invasive arthroscopic harvesting technique. *Orthop Traumatol Surg Res*. 2013;99(1):99–105.
- ³³ Maletis GB, Inacio MCS, Funahashi TT. Analysis of 16,192 anterior cruciate ligament reconstructions from a community-based registry. *Am J Sports Med*. 2013;41(9):2090–8.
- ³⁴ Hulet C, Sonnery-Cottet B, Stevenson C, Samuelsson K, Laver L, Zdanowicz U, et al. The use of allograft tendons in primary ACL reconstruction. *Knee Surg Sports Traumatol Arthrosc* [Internet]. 2019; Available from: <http://dx.doi.org/10.1007/s00167-019-05440-3>.
- ³⁵ Boniello MR, Schwingler PM, Bonner JM, Robinson SP, Cotter A, Bonner KF. Impact of hamstring graft diameter on tendon strength: A biomechanical study. *Arthroscopy*. 2015;31(6):1084–90.
- ³⁶ Bottoni CR, Smith EL, Shaha J, Shaha SS, Raybin SG, Tokish JM, et al. Autograft versus allograft anterior cruciate ligament reconstruction: A prospective, randomized clinical study with a minimum 10-year follow-up. *Am J Sports Med*. 2015;43(10):2501–9.
- ³⁷ Vyas D, Rabuck SJ, Harner CD. Allograft anterior cruciate ligament reconstruction: indications, techniques, and outcomes. *J Orthop Sports Phys Ther*. 2012;42(3):196–207.

- ³⁸ Johnson D. Why synthetic grafts failed, in the anterior cruciate ligament: Reconstruction and basic science. Prodrimos C, C, editors. Saunders Elsevier: Philadelphia; 2008.
- ³⁹ Zoltan DJ, Reinecke C, Indelicato PA. Synthetic and allograft anterior cruciate ligament reconstruction. *Clin Sports Med.* 1988;7(4):773–84.
- ⁴⁰ Krupa S, Królikowska A, Reichert P. Postoperative knee joint stability following anterior cruciate ligament reconstruction using the Ligament Advanced Reinforcement System. *Polim Med.* 2016;46(2):155–61.
- ⁴¹ Dericks G. Ligament advanced reinforcement system anterior cruciate ligament reconstruction. *Operative Techniques in Sports Medicine.* 1995;3(3).
- ⁴² Parchi PD, Gianluca C, Dolfi L, Baluganti A, Nicola P, Chiellini F, et al. Anterior cruciate ligament reconstruction with LARS™ artificial ligament results at a mean follow-up of eight years. *Int Orthop.* 2013;37(8):1567–74.
- ⁴³ Tm. Clinical and functional outcome after anterior cruciate ligament reconstruction using the LARS system at a minimum follow-up of 10 years. *Knee.* 2015;22(6).
- ⁴⁴ Lin KM, Boyle C, Marom N, Marx RG. Graft selection in anterior cruciate ligament reconstruction. *Sports Med Arthrosc.* 2020;28(2):41–8.

12. Biography

Stav Elkabetz is soon to be a medical doctor who is studying in the sixth and final year in the international medical program in the faculty of medicine, University of Zagreb, Croatia.

Stav was born in 08/06/1993, in Be'er Sheva, Israel. During high school, her majors were Biology and Physics. After completing her 2-year obligatory military service in the Israeli defense force (IDF) as a commander of officer training course in the intelligence corps, she traveled around the world for one year, and at that point in time she decided to become a medical doctor.

After living for six years in Croatia and passing all her exams, she is ready to begin a new chapter in her medical future.