

Expression of adipokine ghrelin and ghrelin receptor in human colorectal adenoma and correlation with the grade of dysplasia

Stojsavljević-Shapeski, Sanja; Virović-Jukić, Lucija; Tomas, Davor; Duvnjak, Marko; Tomašić, Vedran; Hrabar, Davor; Kralj, Dominik; Budimir, Ivan; Baršić, Neven; Ljubičić, Neven

Source / Izvornik: **World Journal of Gastrointestinal Surgery, 2021, 13, 1708 - 1720**

Journal article, Published version

Rad u časopisu, Objavljena verzija rada (izdavačev PDF)

<https://doi.org/10.4240/wjgs.v13.i12.1708>

Permanent link / Trajna poveznica: <https://um.nsk.hr/um:nbn:hr:105:644594>

Rights / Prava: [Attribution-NonCommercial 4.0 International/Imenovanje-Nekomercijalno 4.0 međunarodna](#)

Download date / Datum preuzimanja: **2025-01-21**




Repository / Repozitorij:

[Dr Med - University of Zagreb School of Medicine Digital Repository](#)



World Journal of *Gastrointestinal Surgery*

World J Gastrointest Surg 2021 December 27; 13(12): 1523-1769



FRONTIER

- 1523 Photodynamic therapy: A next alternative treatment strategy for hepatocellular carcinoma?
Zhu F, Wang BR, Zhu ZF, Wang SQ, Chai CX, Shang D, Li M

REVIEW

- 1536 Role of mesenteric component in Crohn's disease: A friend or foe?
Yin Y, Zhu ZX, Li Z, Chen YS, Zhu WM
- 1550 Neoadjuvant treatment strategies for hepatocellular carcinoma
Xu L, Chen L, Zhang W
- 1567 Mucinous adenocarcinoma: A unique clinicopathological subtype in colorectal cancer
Huang A, Yang Y, Shi JY, Li YK, Xu JX, Cheng Y, Gu J

MINIREVIEWS

- 1584 Endoscopic therapy of weight regain after bariatric surgery
Bulajic M, Vadalà di Prampero SF, Bošković I, Costamagna G
- 1597 Patient-centered developments in colon- and rectal cancer with a multidisciplinary international team: From translational research to national guidelines
Link KH, Kornmann M, Staib L, Kreuser ED, Gaus W, Röttinger E, Suhr P, Maulbecker-Armstrong C, Danenberg P, Danenberg K, Schatz M, Sander S, Ji ZL, Li JT, Peng SY, Bittner R, Beger HG, Traub B
- 1615 Advances in liver transplantation for unresectable colon cancer liver metastasis
Cui X, Geng XP, Zhou DC, Yang MH, Hou H

ORIGINAL ARTICLE**Retrospective Study**

- 1628 Pediatric T-tube in adult liver transplantation: Technical refinements of insertion and removal
Spoletini G, Bianco G, Franco A, Frongillo F, Nure E, Giovinozzo F, Galiandro F, Tringali A, Perri V, Costamagna G, Avolio AW, Agnes S
- 1638 Preoperative calculation of angles of vision and working area in laparoscopic surgery to treat a giant hiatal hernia
Lara FJP, Zubizarreta Jimenez R, Moya Donoso FJ, Hernández Gonzalez JM, Prieto-Puga Arjona T, del Rey Moreno A, Pitarich Martinez M
- 1651 Effect of aluminum phosphate gel on prevention of early rebleeding after ligation of esophageal variceal hemorrhage
Zhang ZL, Peng MS, Chen ZM, Long T, Wang LS, Xu ZL

- 1660** Postoperative complications after robotic resection of colorectal cancer: An analysis based on 5-year experience at a large-scale center

Huang ZX, Zhou Z, Shi HR, Li TY, Ye SP

- 1673** 'Short' pancreaticojejunostomy might be a valid option for treatment of chronic pancreatitis in many cases

Murruste M, Kirsimägi Ü, Kase K, Veršinina T, Talving P, Lepner U

- 1685** Risk factors for perioperative complications in laparoscopic surgeries of retrorectal cystic lesions

Wang PP, Lin C, Zhou JL, Xu KW, Qiu HZ, Wu B

- 1696** Liver resection *vs* radiofrequency ablation in single hepatocellular carcinoma of posterosuperior segments in elderly patients

Delvecchio A, Inchingolo R, Laforgia R, Ratti F, Gelli M, Anelli MF, Laurent A, Vitali G, Magistri P, Assirati G, Felli E, Wakabayashi T, Pessaux P, Piardi T, di Benedetto F, de'Angelis N, Briceño J, Rampoldi A, Adam R, Cherqui D, Aldrighetti LA, Memeo R

Observational Study

- 1708** Expression of adipokine ghrelin and ghrelin receptor in human colorectal adenoma and correlation with the grade of dysplasia

Stojavljevic-Shapeski S, Virovic-Jukic L, Tomas D, Duvnjak M, Tomasic V, Hrabar D, Kralj D, Budimir I, Barsic N, Ljubcic N

SYSTEMATIC REVIEWS

- 1721** Right sided diverticulitis in western countries: A review

Epifani AG, Cassini D, Ciocchi R, Accardo C, Di Candido F, Ardu M, Baldazzi G

- 1736** Platelet rich plasma effectiveness in bowel anastomoses: A systematic review

Geropoulos G, Psarras K, Giannis D, Martzivanou EC, Papaioannou M, Kakos CD, Pavlidis ET, Symeonidis N, Koliakos G, Pavlidis TE

- 1754** Current and future role of three-dimensional modelling technology in rectal cancer surgery: A systematic review

Przedlacka A, Pellino G, Fletcher J, Bello F, Tekkis PP, Kontovounisios C

ABOUT COVER

Editorial Board Member of *World Journal of Gastrointestinal Surgery*, Marcello Donati, FACS, MD, PhD, Professor, Department of Surgery and Medical-Surgical specialties, University of Catania, Catania 95125, Italy. mdonati@unict.it

AIMS AND SCOPE

The primary aim of *World Journal of Gastrointestinal Surgery* (*WJGS, World J Gastrointest Surg*) is to provide scholars and readers from various fields of gastrointestinal surgery with a platform to publish high-quality basic and clinical research articles and communicate their research findings online.

WJGS mainly publishes articles reporting research results and findings obtained in the field of gastrointestinal surgery and covering a wide range of topics including biliary tract surgical procedures, biliopancreatic diversion, colectomy, esophagectomy, esophagostomy, pancreas transplantation, and pancreatectomy, etc.

INDEXING/ABSTRACTING

The *WJGS* is now abstracted and indexed in Science Citation Index Expanded (SCIE, also known as SciSearch®), Current Contents/Clinical Medicine, Journal Citation Reports/Science Edition, PubMed, and PubMed Central. The 2021 edition of Journal Citation Reports® cites the 2020 impact factor (IF) for *WJGS* as 2.582; IF without journal self cites: 2.564; 5-year IF: 3.378; Journal Citation Indicator: 0.53; Ranking: 97 among 212 journals in surgery; Quartile category: Q2; Ranking: 73 among 92 journals in gastroenterology and hepatology; and Quartile category: Q4.

RESPONSIBLE EDITORS FOR THIS ISSUE

Production Editor: Rui-Rui Wu, Production Department Director: Xiang Li, Editorial Office Director: Ya-Juan Ma.

NAME OF JOURNAL

World Journal of Gastrointestinal Surgery

ISSN

ISSN 1948-9366 (online)

LAUNCH DATE

November 30, 2009

FREQUENCY

Monthly

EDITORS-IN-CHIEF

Shu-You Peng, Varut Lohsirivat

EDITORIAL BOARD MEMBERS

<https://www.wjgnet.com/1948-9366/editorialboard.htm>

PUBLICATION DATE

December 27, 2021

COPYRIGHT

© 2021 Baishideng Publishing Group Inc

INSTRUCTIONS TO AUTHORS

<https://www.wjgnet.com/bpg/gerinfo/204>

GUIDELINES FOR ETHICS DOCUMENTS

<https://www.wjgnet.com/bpg/GerInfo/287>

GUIDELINES FOR NON-NATIVE SPEAKERS OF ENGLISH

<https://www.wjgnet.com/bpg/gerinfo/240>

PUBLICATION ETHICS

<https://www.wjgnet.com/bpg/GerInfo/288>

PUBLICATION MISCONDUCT

<https://www.wjgnet.com/bpg/gerinfo/208>

ARTICLE PROCESSING CHARGE

<https://www.wjgnet.com/bpg/gerinfo/242>

STEPS FOR SUBMITTING MANUSCRIPTS

<https://www.wjgnet.com/bpg/GerInfo/239>

ONLINE SUBMISSION

<https://www.f6publishing.com>

Observational Study

Expression of adipokine ghrelin and ghrelin receptor in human colorectal adenoma and correlation with the grade of dysplasia

Sanja Stojsavljevic-Shapeski, Lucija Virovic-Jukic, Davor Tomas, Marko Duvnjak, Vedran Tomasic, Davor Hrabar, Dominik Kralj, Ivan Budimir, Neven Barsic, Neven Ljubicic

ORCID number: Sanja Stojsavljevic-Shapeski 0000-0002-1626-3003; Lucija Virovic-Jukic 0000-0002-6350-317X; Davor Tomas 0000-0003-3390-8683; Marko Duvnjak 0000-0001-9649-9456; Vedran Tomasic 0000-0001-8211-3487; Davor Hrabar 0000-0001-9129-3897; Dominik Kralj 0000-0001-6503-6870; Ivan Budimir 0000-0003-4198-8329; Neven Barsic 0000-0002-4416-4520; Neven Ljubicic 0000-0002-5207-4357.

Author contributions: Stojsavljevic-Shapeski S, Virovic-Jukic L and Tomas D designed the study; Stojsavljevic-Shapeski S, Tomasic V, Kralj D, Barsic N, Budimir I and Hrabar D participated in the acquisition of data; Stojsavljevic-Shapeski S, Virovic-Jukic L and Tomas D participated in the analysis and interpretation of the data; Stojsavljevic-Shapeski S and Virovic-Jukic L drafted the initial manuscript; Hrabar D, Duvnjak M and Ljubicic N revised the article critically for important intellectual content.

Institutional review board

statement: The study and all its documents as well as the informed consent form were reviewed and approved by the Ethical committee of «Sestre Milosrdnice» University Hospital Center, 10000 Zagreb, Croatia in December 2013.

Sanja Stojsavljevic-Shapeski, Lucija Virovic-Jukic, Vedran Tomasic, Davor Hrabar, Dominik Kralj, Ivan Budimir, Neven Barsic, Neven Ljubicic, Division of Gastroenterology, Department of Internal Medicine, «Sestre Milosrdnice» University Hospital Center, Zagreb 10000, Croatia

Lucija Virovic-Jukic, Marko Duvnjak, Davor Hrabar, Neven Barsic, Neven Ljubicic, Department of Internal Medicine, School of Medicine, University of Zagreb, Zagreb 10000, Croatia

Davor Tomas, Ljudevit Jurak Department of Pathology, «Sestre Milosrdnice» University Hospital Center, Zagreb 10000, Croatia

Davor Tomas, Department of Pathology, School of Medicine, University of Zagreb, Zagreb 10000, Croatia

Corresponding author: Sanja Stojsavljevic-Shapeski, MD, PhD, Senior Research Fellow, Division of Gastroenterology, Department of Internal Medicine, «Sestre Milosrdnice» University Hospital Center, Vinogradska ul. 29, Zagreb 10000, Croatia.

sanja.stojsavljevic@kbcsm.hr

Abstract

BACKGROUND

Ghrelin is an adipokine that plays an important role in energy balance. Expression of ghrelin and ghrelin receptor has been investigated in different tissues and tumors. Studies regarding expression of ghrelin and ghrelin receptor in colorectal tumors are scarce and no data on expression of ghrelin and its receptor in colorectal adenomas has been published. Ghrelin and ghrelin receptor were highly expressed in colon carcinoma cells while expression was decreased in less differentiated tumors, presuming that ghrelin might be important in early phases of tumorigenesis.

AIM

To investigate the expression of ghrelin and ghrelin receptor in human colorectal adenomas and adjacent colorectal tissue.

METHODS

In this prospective study (conducted from June 2015 until May 2019) we included 92 patients (64 male and 28 female) who underwent polypectomy for colorectal adenomas in the Department of Gastroenterology and Hepatology, "Sestre

Informed consent statement: All study participants, or their legal guardian, provided after extensive written and communicated information an informed written consent prior to study enrollment.

Conflict-of-interest statement: There are no conflicts of interest to report.

Data sharing statement: No additional data are available.

STROBE statement: The authors have read the STROBE Statement-checklist of items, and the manuscript was prepared and revised according to the STROBE Statement-checklist of items.

Country/Territory of origin: Croatia

Specialty type: Gastroenterology and hepatology

Provenance and peer review: Invited article; Externally peer reviewed.

Peer-review report's scientific quality classification

Grade A (Excellent): 0
Grade B (Very good): B
Grade C (Good): C
Grade D (Fair): D
Grade E (Poor): 0

Open-Access: This article is an open-access article that was selected by an in-house editor and fully peer-reviewed by external reviewers. It is distributed in accordance with the Creative Commons Attribution NonCommercial (CC BY-NC 4.0) license, which permits others to distribute, remix, adapt, build upon this work non-commercially, and license their derivative works on different terms, provided the original work is properly cited and the use is non-commercial. See: <http://creativecommons.org/licenses/by-nc/4.0/>

Received: June 28, 2021

Peer-review started: June 28, 2021

First decision: July 27, 2021

Revised: August 20, 2021

Accepted: November 3, 2021

Article in press: November 3, 2021

milosrdnice" Clinical Hospital Center in Zagreb, Croatia. After endoscopic removal of colorectal adenoma, an additional sample of colon mucosa in the proximity of the adenoma was collected for pathohistological analysis. Adenomas were graded according to the stage of dysplasia, and ghrelin and ghrelin receptor expression were determined immunohistochemically in both adenoma and adjacent colon tissue using the polyclonal antibody for ghrelin (ab150514, ABCAM Inc, Cambridge, United States) and ghrelin receptor (ab48285, ABCAM Inc, Cambridge, United States). Categorical and nominal variables were described through frequencies and proportions and the difference between specific groups were analyzed with Fisher's and Fisher-Freeman-Halton's method respectively. Spearman's rank correlation coefficient was determined for correlation of expression of ghrelin and ghrelin receptor in adenoma and adjacent colon tissue with the grade of adenoma dysplasia.

RESULTS

Among 92 patients with colorectal adenoma 43 had adenomas with high-grade dysplasia (46.7%). High expression of ghrelin was 7 times more common in high-grade adenoma compared to low-grade adenomas (13.95% to 2.04%, $P = 0.048$), while the expression of ghrelin in adjacent colon tissue was low. We found no correlation between ghrelin receptor expression in adenoma and adjacent colon tissue and the grade of colorectal adenoma dysplasia. The most significant correlation was found between ghrelin and ghrelin receptor expression in adenomas with high-grade dysplasia ($\rho = 0.519$, $P < 0.001$).

CONCLUSION

Ghrelin and ghrelin receptor are expressed in colorectal adenoma and adjacent tissue with ghrelin expression being more pronounced in high grade dysplasia as a possible consequence of increased local synthesis.

Key Words: Ghrelin; Ghrelin receptor; Adipokines; Colorectal adenoma; Colorectal adenoma dysplasia; Large intestine

©The Author(s) 2021. Published by Baishideng Publishing Group Inc. All rights reserved.

Core Tip: Colorectal adenomas are benign, but premalignant lesions of the large intestine, as dysplasia may progress over time and result in the occurrence of colorectal carcinoma. The risk of progression is increased in adenomas with high-grade dysplasia. There are several risk factors for adenomas with high-grade dysplasia, of which energy imbalance and metabolic syndrome are increasing in importance because of their rising prevalence. Ghrelin is an adipokine important in energy balance and its expression was investigated in different tumors and tissues. With this prospective observational study we gained new insight on the expression and role of ghrelin and ghrelin receptor in colorectal adenomas.

Citation: Stojsavljevic-Shapeski S, Virovic-Jukic L, Tomas D, Duvnjak M, Tomasic V, Hrabar D, Kralj D, Budimir I, Barsic N, Ljubcic N. Expression of adipokine ghrelin and ghrelin receptor in human colorectal adenoma and correlation with the grade of dysplasia. *World J Gastrointest Surg* 2021; 13(12): 1708-1720

URL: <https://www.wjgnet.com/1948-9366/full/v13/i12/1708.htm>

DOI: <https://dx.doi.org/10.4240/wjgs.v13.i12.1708>

INTRODUCTION

Ghrelin is an adipokine, an endogenous ligand of growth hormone (GH) secretagogue receptor (GHS-R), which was first isolated in 1999 by Kojima *et al*[1] from rat gastric cells. Ghrelin stimulates the release of GH through activation of its receptors and for some time it was thought that its main and only function was the regulation of energy and appetite[1]. However, ghrelin stimulates the release of other pituitary hormones,

Published online: December 27, 2021

P-Reviewer: Abdalla MMI, Mori H, Tan X

S-Editor: Gao CC

L-Editor: A

P-Editor: Gao CC



influences gastric motility and secretion of gastric acid, modulates pancreatic endocrine function and influences glucose metabolism, insulin resistance and cell proliferation[2]. Apart from its production by gastric cells, it is expressed and produced in almost all tissues of the gastrointestinal tract and body in general[3,4]. Serum concentrations of total ghrelin were found to be lower in obese individuals on the account of decreased levels of deacylated ghrelin, while acylated ghrelin levels were mostly constant[5]. Ghrelin receptor was found to be highly expressed in adipose tissue where its activation induced the differentiation and proliferation of adipocytes and decreased their apoptosis which is mediated through MAP/PIP 3/Akt pathway [6]. Since ghrelin influences the release of GH and is a regulator of the GH/insulin like GH (IGF)-1 pathway, it has been also linked to tumor progression[7]. Gastric carcinoma cells exposed to ghrelin showed increased migratory and invasion abilities while their apoptosis was reduced[8]. This was shown to be also mediated through the PI3K/Akt pathway[8].

Ghrelin receptor expression varies among different types of tumors. Two types of ghrelin receptor forms have been described, type GHS-R1a and GHS-R1b, with GHS-R1a recognized as predominant and therefore responsible for ghrelin activity[9]. However, one study found GHS-R1b more expressed in tumor cells with advancing colorectal carcinoma stage while GHS-R1a expression was decreased[10]. Ghrelin has been investigated in different tumor tissues and although not all results concurred, most were consistent in tumor expression of ghrelin and in favor of its proliferative and anti-apoptotic role[11-16].

Colorectal adenomas are premalignant lesions that are differentiated among other characteristics on the grade of dysplasia in high and low-grade dysplasia adenomas [17]. With time, progression of dysplasia leads to a well-known adenoma-carcinoma sequence. Various risk factors have been associated with high-grade dysplasia adenoma, including genetic predisposition, inflammatory bowel diseases, age, male sex, smoking, poor dietary habits, obesity and metabolic syndrome[18,19]. Since metabolic syndrome is experiencing a worldwide epidemic-like rise in incidence, its clinical consequences such as tumors, with colorectal adenomas and carcinomas among others, are also experiencing a dramatic rise[20,21]. Although the influence of insulin resistance and hyperinsulinemia in colorectal carcinoma formation and progression has been well established, the role of adipokines connected to the metabolic syndrome such as ghrelin has still not been completely clarified[22]. Researching the published data regarding influence of ghrelin and its receptor in colorectal carcinoma and colorectal adenoma progression, we realized that there is a need for further insight on this subject. Current data are not sufficient for complete understanding of all ghrelin effects, and there are missing data from large cohort studies, tissue expression, genetic and plasma level studies which was also emphasized in a recently published review on ghrelin role in gastrointestinal tract tumors[23]. In this study we aimed to investigate the expression of ghrelin and ghrelin receptor in colorectal adenoma and adjacent healthy tissue, and to our knowledge this is the first study dealing with this issue. New information on this subject could influence the current recommendations for colorectal adenoma and carcinoma screening, giving more attention to patients burdened with metabolic syndrome features as well as influence postpolypectomy surveillance guidelines. Current guidelines rely on conventional adenoma characteristics such as number, size, histology and presence of dysplasia, but the burden imposed on patients and health services by surveillance colonoscopies encourages research of novel genomic and immunohistochemical markers for identifying risk of metachronous polyp development[24]. Understanding the complex involvement of adipokines in the pathways responsible in adenoma to carcinoma progression could influence potential management strategies[25]. Ghrelin as an important adipokine is in this respect still insufficiently investigated and further studies are needed.

MATERIALS AND METHODS

Patients

In this prospective observational study we included 92 patients who underwent endoscopic polypectomy for colorectal adenoma at the Department of Gastroenterology, "Sestre milosrdnice" University Hospital Center in Zagreb, Croatia. The participants were included in the study in the period from June 2015 until May 2019. All participants were prior to recruitment informed of the nature of the study and gave their informed consent for participation. Exclusion criteria were an active or prior

malignant disease, history of inflammatory bowel disease or any abdominal surgical procedure, prior removal of colorectal adenoma and a lack of informed consent.

All patients underwent a total colonoscopy with the removal of colorectal adenoma or adenomas. During the procedure, an additional biopsy of adjacent, "healthy" tissue was taken 5 cm proximally or distally from the removed adenoma. In cases where more adenomas were removed, only the largest adenoma and the tissue adjacent to it were used in further immunohistochemical analysis. Adenoma sample and the adjacent tissue sample underwent pathohistological analysis for dysplasia that was graded either high or low, and immunohistochemical analysis for expression of ghrelin and ghrelin receptor. We used tissue fixation technique with solution of 40 g/L formaldehyde (10% neutral buffered formalin) and the samples were embedded in paraffin blocks and cut into 5 µm slices. A power analysis was done in a pilot study to determine the number of participants needed to reach statistical significance.

Immunohistochemical analysis

For immunohistochemical analysis we used a polyclonal antibody for the ghrelin receptor (ab150514, ABCAM Inc, Cambridge, United States) and a polyclonal antibody for ghrelin (ab48285 ABCAM Inc, Cambridge, United States), both in concentrations of 5 mg/mL. The analysis for both antibodies was performed on a Dako Autostainer automated slide processing system (Dako, Copenhagen, Denmark) by EnVision FLEX-PTL method. The results of the immunohistochemical analysis were expressed semi-quantitatively by determination of the immunohistochemical staining index (ISI), taking in account the intensity of the reaction (IR) and the percentage of the immunoreactive cells (PC). Two experienced pathologists independently performed the interpretation of the IR and the percentage of immunoreactive cells. In cases of discordant results a third pathologist was consulted to reach an agreement. Intensity of the staining was classified as 0 for no reaction, 1 for a poor cytoplasmic reaction, 2 for a moderate one and 3 for an intense cytoplasmic reaction. The percentage of immunoreactive cells was classified as 0 for no reaction, 1 for reaction in ≤ 33 percent of cells, 2 for reaction in more than 33 percent and ≤ 66 percent, and 3 for a reaction in more than 66 percent of cells. Each sample was in that way assigned a grade for the percentage of immunoreactive cells and a grade for the intensity of staining. ISI was determined as a multiplication of the IR and the percentage of reactive cells. We distinguished two groups of specimens: those with the ISI value of 9, which represents the strong reaction and the group with ISI values less than 9 representing no, poor or slight reaction.

Statistical analysis

Categorical and nominal variables were described through frequencies and proportions and the difference between specific groups were analyzed with Fisher's and Fisher-Freeman-Halton's method respectively. Spearman's rank correlation coefficient was determined for correlation of expression of ghrelin and ghrelin receptor in adenoma and adjacent colon tissue with the grade of adenoma dysplasia. *P* values less than 0.05 were considered significant and in the analysis we used the licensed program support IBM SPSS Statistics, version 25.0 (<https://www.ibm.com/analytics/spss-statistics-software>).

RESULTS

From 123 screened, 92 patients were included in the study (due to later drop out), 64 male (69.9%) and 28 female (30.4%). The youngest patient was 29 and the oldest 83 years old, age median was 66. Forty-nine patients (53.3%) had a low-grade dysplasia adenoma and 43 patients (46.7%) high-grade dysplasia adenoma. Adenomas were categorized according to size in larger than 5 mm and smaller than 5 mm, and adenomas larger than 5 mm were according to type categorized in sessile, subpeduncular, peduncular and flat. The descriptive statistics regarding the localization, size and type of adenomas is presented in [Table 1](#).

All adenomas as well as adjacent tissue were immunohistochemically stained to evaluate ghrelin and ghrelin receptor expression. [Figure 1](#) shows different intensities of immunohistochemical staining for ghrelin in adenoma and adjacent tissue ([Figure 1A-C](#)). [Figure 2](#) shows different intensities of immunohistochemical staining for ghrelin receptor in adenoma and adjacent tissue ([Figure 2A-C](#)). [Figure 3](#) shows the statistical distribution of ISI values for ghrelin and ghrelin receptor among adenomas depending on dysplasia grade, and [Figure 4](#) the statistical distribution of ISI values for

Table 1 Descriptive statistics regarding adenoma size, localization and type (sessile, peduncular, subpeduncular, flat)

	<i>n</i>	%
Adenoma < 5 mm in ascending colon		
Not found	65	70.7
Found	27	29.3
Adenoma > 5 mm in ascending colon		
Not found	62	67.4
Found	30	32.6
Type of adenoma > 5 mm in ascending colon		
Sessile	24	54.6
Peduncular	3	6.8
Subpeduncular	7	15.9
Flat	10	22.7
Adenoma < 5 mm in transverse and descending colon		
Not found	75	81.5
Found	17	18.5
Adenoma > 5 mm in transverse and descending colon		
Not found	69	75.0
Found	23	25.0
Type of adenoma > 5 mm in transverse and descending colon		
Sessile	15	51.7
Peduncular	7	24.1
Subpeduncular	4	13.8
Flat	3	10.4
Adenoma < 5 mm in sigmoid colon		
Not found	68	73.9
Found	24	26.1
Adenoma > 5 mm in sigmoid colon		
Not found	43	46.7
Found	49	53.3
Type of adenoma > 5 mm in sigmoid colon		
Sessile	18	31.1
Peduncular	26	44.8
Subpeduncular	12	20.7
Flat	2	3.4
Adenoma < 5 mm in rectum		
Not found	75	81.5
Found	17	18.5
Adenoma > 5 mm in rectum		
Not found	73	79.3
Found	19	20.7
Type of adenoma > 5 mm in rectum		
Sessile	14	73.7

Peduncular	4	21.1
Subpeduncular	1	5.2
Flat	0	0.0

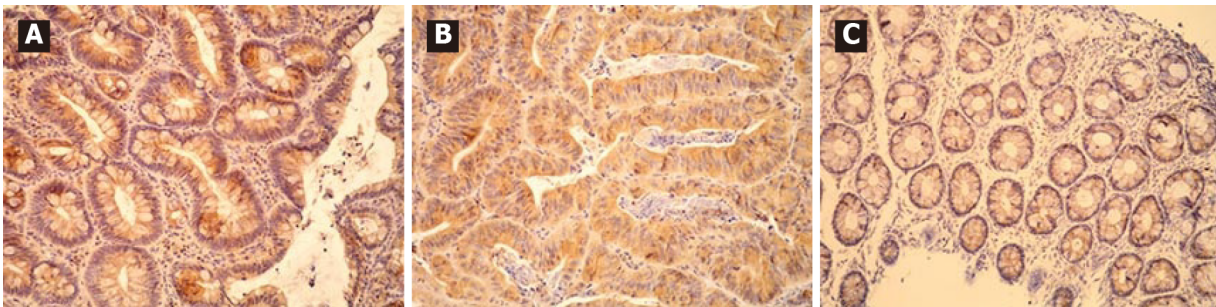


Figure 1 Immunohistochemical expression of ghrelin in adenoma and adjacent tissue. A: Representative image of strong immunohistochemical expression of ghrelin in adenoma with low grade dysplasia (200 × magnification); B: Representative image of strong immunohistochemical expression of ghrelin in adenoma with high grade dysplasia (200 × magnification); C: Representative image of moderate immunohistochemical expression of ghrelin in adjacent tissue (200 × magnification).

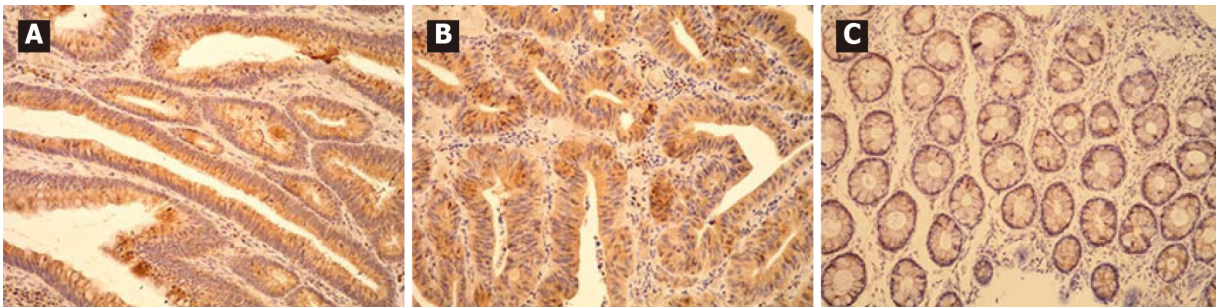


Figure 2 Immunohistochemical expression of ghrelin receptor in adenoma and adjacent tissue. A: Representative image of strong immunohistochemical expression of ghrelin receptor in adenoma with low grade dysplasia (200 × magnification); B: Representative image of strong immunohistochemical expression of ghrelin receptor in adenoma with high grade dysplasia (200 × magnification); C: Representative image of moderate immunohistochemical expression of ghrelin receptor in adjacent tissue (200 × magnification).

ghrelin and ghrelin receptor in adjacent tissue (Figures 3 and 4).

We found that ghrelin was in different intensities expressed in 98.8% of all adenomas, and 79.3% of adjacent tissue samples, while ghrelin receptor was expressed in 98.9% of adenoma and 94.6% of adjacent tissue samples.

In Table 2 we showed the correlation of immunohistochemical expression of ghrelin and ghrelin receptor based on two groups of ISI values in adenoma and adjacent tissue to the stage of adenoma dysplasia (Table 2). In adenomas with high-grade dysplasia strong expression of ghrelin was 7 times more frequent than in adenomas with low-grade dysplasia ($P = 0.048$). We found no correlation between immunohistochemical expression of ghrelin receptor in adenoma and adjacent tissue to the stage of adenoma dysplasia ($P > 0.05$).

The results of Spearman's rank correlation coefficient (ρ) analysis for correlation between immunohistochemical expression (value of ISI index) of ghrelin and ghrelin receptor in adenoma (and adjacent colon tissue) and grade of adenoma dysplasia are shown in Table 3.

In adenomas with high-grade dysplasia there is a positive correlation between immunohistochemical expression of ghrelin in adenoma and the immunohistochemical expression of ghrelin receptor in adenoma ($\rho = 0.519$; $P < 0.001$) and expression of ghrelin in adjacent tissue ($\rho = 0.467$; $P = 0.002$). In adenomas with low-grade dysplasia we have not found a positive correlation between immunohistochemical expression of ghrelin and the ghrelin receptor but we found a positive correlation between expression of ghrelin receptor in adenoma and the expression of ghrelin receptor in adjacent tissue ($\rho = 0.567$; $P < 0.001$). Regardless of the stage of adenoma dysplasia in adjacent colon tissue we found a positive correlation between

Table 2 Correlation of immunohistochemical expression of ghrelin and ghrelin receptor based on two groups of immunohistochemical staining index value in adenoma and adjacent tissue to the stage of adenoma dysplasia

	Dysplasia grade				P value
	Low dysplasia		High dysplasia		
	n	%	n	%	
ISI for ghrelin in adenoma					0.048 ^a
ISI < 9	48	98.0	37	86.0	
ISI 9-strong reaction	1	2.0	6	14.0	
ISI for ghrelin in adjacent tissue					1.000
ISI 0 < 6	42	85.7	37	86.0	
ISI 6-moderate reaction	7	14.3	6	14.0	
ISI for ghrelin receptor in adenoma					0.114
ISI < 9	43	87.8	32	74.4	
ISI 9-strong reaction	6	12.2	11	25.6	
ISI for ghrelin receptor in adjacent tissue					0.664
ISI < 9	30	61.2	29	67.4	
ISI 9-strong reaction	19	38.8	14	32.6	

^aP = 0.048 for strong ghrelin expression in adenoma with high *vs* low grade dysplasia.
ISI: Immunohistochemical staining index.

expression of ghrelin and ghrelin receptor ($\rho = 0.367$; $P = 0.009$ in low dysplasia group and $\rho = 0.409$; $P = 0.002$ for high-grade dysplasia group respectively). For interpretation of this correlation it is important to note that regardless of the dysplasia grade in adenoma we have not found in any obtained sample of adjacent colon tissue a high expression of ghrelin, and in more than 75% of adjacent tissue samples ISI index was ≤ 3 which marked poor to none ghrelin expression.

DISCUSSION

To our knowledge there have been no studies regarding the expression of ghrelin and ghrelin receptor in human colorectal adenomas. We wanted to investigate the expression of ghrelin and ghrelin receptor in colorectal adenoma and in adenoma adjacent normal colorectal tissue. In our study we found that in adenomas ghrelin was in different intensity expressed in 98.8% of samples and ghrelin receptor in 98.9% respectively. In adjacent tissue ghrelin was in different intensity expressed in 79.3% of samples and ghrelin receptor in 94.6% respectively. Although ghrelin and ghrelin receptor are expressed in adenomas with low and high-grade dysplasia, in high-grade dysplasia there is a stronger expression of ghrelin, which could suggest that adenomas with high grade dysplasia produce locally more ghrelin. Waseem *et al*[10] in their study on 110 patients with colorectal carcinoma found that tumor cells as well as normal cells express ghrelin and ghrelin receptor, but the cells of well and moderately differentiated tumors produce more ghrelin in comparison with normal large intestine cells. The intensity of the immunohistochemical reaction for ghrelin was graded 0 to 4 and well differentiated tumors had a 1.92 ± 0.4 higher expression of ghrelin than normal cells, and moderately differentiated tumors had 2.25 ± 0.5 higher ghrelin expression than normal cells[10]. Interestingly, they also found that as the tumor cells lose its potential to differentiate, they also lose their ability to express ghrelin and ghrelin receptor ($P < 0.05$)[10]. Their results imply that ghrelin and ghrelin receptor could have a role in early tumor progression and that their importance is lost in poorly differentiated tumors. Ghrelin in an *in vitro* study acted proliferative on normal large intestine cells and tumor cells since it promoted the shift from G1 to S cell phase and influenced cell cycle progression ($P < 0.05$)[26]. This was mediated through activation of the adenylate cyclase independent epidermal growth factor receptor (EGFR) trans-activation and PI3K-Akt phosphorylation. Both these pathways converge to stimulate

Table 3 Spearman's rank correlation for immunohistochemical expression of ghrelin and ghrelin receptor in adenoma and adjacent tissue with the grade of adenoma dysplasia

	ISI for ghrelin in adenoma	ISI for ghrelin in adjacent tissue	ISI for ghrelin receptor in adenoma	ISI for ghrelin receptor in adjacent tissue
Low grade dysplasia				
ISI for ghrelin in adenoma				
Rho	1.000	0.173	-0.108	-0.096
P value		0.235	0.459	0.511
n	49	49	49	49
ISI for ghrelin in adjacent tissue				
Rho	0.173	1.000	0.159	0.367
P value	0.235		0.276	0.009 ^a
n	49	49	49	49
ISI for ghrelin receptor in adenoma				
Rho	-0.108	0.159	1.000	0.576
P value	0.459	0.276		< 0.001 ^b
n	49	49	49	49
ISI for ghrelin receptor in adjacent tissue				
Rho	-0.096	0.367	0.576	1.000
P value	0.511	0.009	0.000	
n	49	49	49	49
High grade dysplasia				
ISI for ghrelin in adenoma				
Rho	1.000	0.347	0.519	0.077
P value		0.023 ^d	< 0.001 ^c	0.622
n	43	43	43	43
ISI for ghrelin in adjacent tissue				
Rho	0.347	1.000	0.230	0.409
P value	0.023 ^d		0.138	0.007 ^e
n	43	43	43	43
ISI for ghrelin receptor in adenoma				
Rho	0.519	0.230	1.000	0.467
P value	< 0.001 ^c	0.138		0.002 ^f
n	43	43	43	43
ISI for ghrelin receptor in adjacent tissue				
Rho	0.077	0.409	0.467	1.000
P value	0.622	0.007 ^e	0.002 ^f	
n	43	43	43	43

^aP = 0.009 positive correlation between expression of ghrelin and ghrelin receptor in adjacent tissue for low grade dysplasia adenoma.

^bP < 0.001 positive correlation between expression of ghrelin receptor in adenoma and adjacent tissue for low grade dysplasia adenoma.

^c*P* < 0.001 positive correlation between expression of ghrelin and ghrelin receptor in adenoma for high grade dysplasia adenoma.
^d*P* = 0.023 positive correlation between expression of ghrelin in adenoma and adjacent tissue for high grade dysplasia adenoma.
^e*P* = 0.007 positive correlation between expression of ghrelin and ghrelin receptor in adjacent tissue for high grade dysplasia adenoma.
^f*P* = 0.002 positive correlation between expression of ghrelin and ghrelin receptor in adjacent tissue for low grade dysplasia adenoma.
 ISI: Immunohistochemical staining index; Rho: Spearman correlation coefficient.

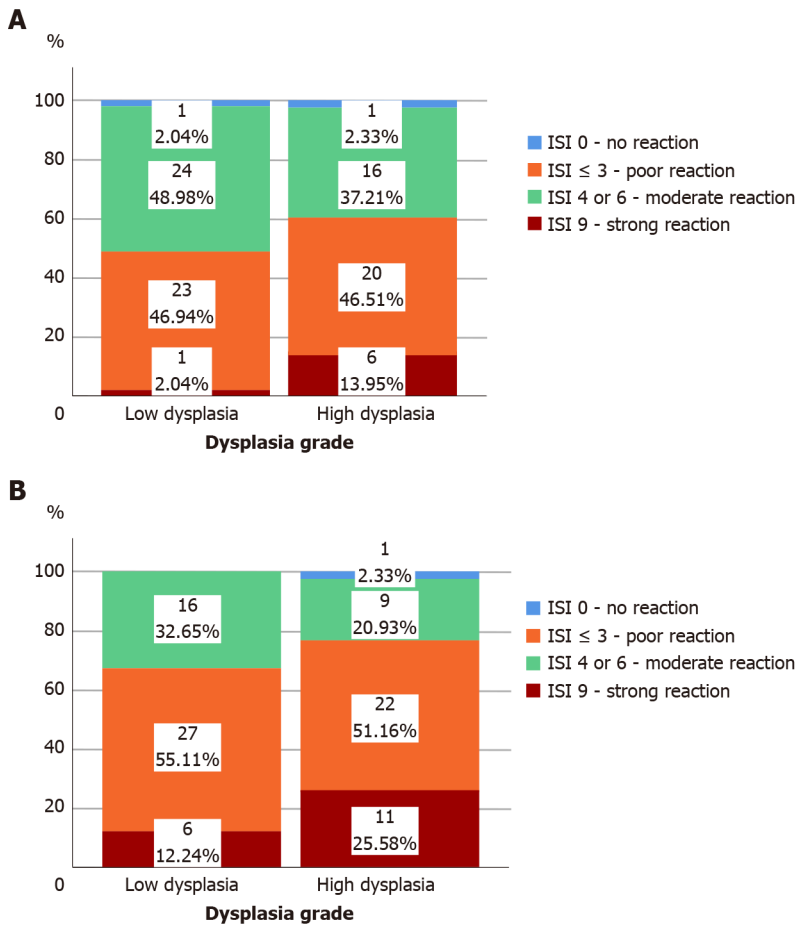


Figure 3 Immunohistochemical expression of ghrelin and ghrelin receptor in adenoma depending on the grade of adenoma dysplasia. A: Immunohistochemical staining index (ISI) of ghrelin in adenoma depending on grade of dysplasia in adenoma; B: ISI of ghrelin receptor in adenoma depending on grade of dysplasia in adenoma. ISI: Immunohistochemical staining index.

MAPK, ERK 1/2 signaling[26]. A genomic study on intra-tumor heterogeneity analyzing clonal origins and subclonal composition of adenomas and colorectal tumors detected several signaling pathways important in colorectal cancer evolution [27]. Accumulation of mutations in the PI3K-Akt pathway was found, among others, to be of vital importance[27]. A study assessing the expression of EGFR in normal colon tissue and colorectal adenoma tissue found that adenomas with high-grade dysplasia and tubule-villous features overexpress EGFR, while only 10 percent of adenomas with low-grade dysplasia expressed EGFR[28]. Another *in vitro* study found that ghrelin acts proliferative on colorectal carcinoma cells activating Ras, PI3K, Akt and mTOR signaling pathway[29]. Study on gastric adenocarcinoma and normal gastric cells found that gastric cells express ghrelin but adenocarcinoma cells lose its potential to express ghrelin[30]. Although we are moving away from the alimentary system, well differentiated breast tumors have a great potential for expression of ghrelin while less differentiated ones lose this ability[31]. In patients with serous ovarian tumors expression of ghrelin was increased in malignant compared to benign tumors[13].

We have not found a significant difference in ghrelin receptor expression between high and low-grade adenomas or adjacent normal colorectal tissue. Although our results point out that, based on ISI values, strong expression of ghrelin receptor was two times more frequent in adenomas with high grade dysplasia than in low grade dysplasia, it was not significant. A study by Liu *et al*[9], found that ghrelin and its

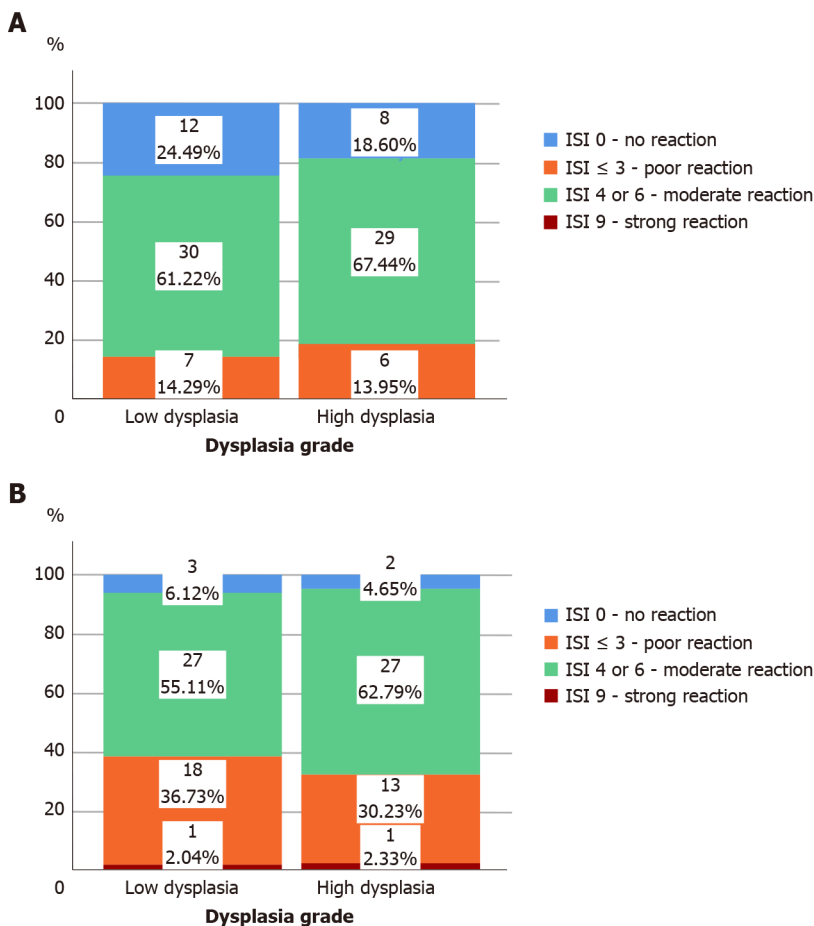


Figure 4 Immunohistochemical expression of ghrelin and ghrelin receptor in adjacent tissue depending on the grade of dysplasia in the corresponding adenoma. A: Immunohistochemical staining index (ISI) of ghrelin in adjacent tissue depending on grade of dysplasia in corresponding adenoma; B: ISI of ghrelin receptor in adjacent tissue depending on grade of dysplasia in corresponding adenoma. ISI: Immunohistochemical staining index.

receptor are markedly expressed in colorectal tumors and cell lines. They also report that after ghrelin receptor activation the probable mechanism of downstream regulation is through inhibiting phosphatase and tensin homolog, activating Akt and inhibiting p53[9]. In their mouse model, the expression of ghrelin receptor significantly correlated with colorectal cancer cell growth and tumor burden[9]. Similar results were reported in a mouse model of endometrial carcinoma[32]. Although our results don't concur with the previous studies we could hypothesize that the expression and importance of ghrelin receptor is more pronounced further down the dysplasia progression pathway. Ghrelin receptor role in colorectal adenoma dysplasia progression should be investigated in further studies.

Our results showed a positive correlation between immunohistochemical expression of ghrelin and ghrelin receptor in adjacent normal colorectal tissue independently of the fact whether the corresponding removed adenoma had high or low-grade dysplasia ($P = 0.009$ for low grade dysplasia, $P = 0.023$ for high grade dysplasia). We have to emphasize that in adjacent tissue samples we didn't find a great intensity of ghrelin expression, and in more than 75% of those samples ISI index was ≤ 3 which marked poor to none ghrelin expression. Our results didn't show a positive correlation between ghrelin and ghrelin receptor in adenomas with low-grade dysplasia ($P < 0.05$). Since similar studies concerning ghrelin and ghrelin receptor expression in adenoma with low and high-grade dysplasia as well as adjacent tissue are lacking we cannot compare our results with other studies, but are looking forward to future studies. The lack of our study is that the immunohistochemical staining used in our study did not differentiate the two types of ghrelin receptor (types GHS-R1a and GHS-R1b) in colorectal adenoma and adjacent tissue so this could be a subject for new studies. Although this was a relatively simple study our strongest point is that we are the first to address ghrelin and ghrelin receptor expression in colorectal adenomas since there has been no published data on this issue.

Our results point out to the conclusion that although ghrelin and ghrelin receptor are expressed in normal and adenoma tissue, in high-grade adenomas there is a higher expression of ghrelin due to its higher production, which promotes further proliferation.

CONCLUSION

Our study shows that ghrelin and ghrelin receptor are expressed in colorectal adenomas and adjacent tissue. We found that ghrelin expression was more pronounced in adenomas with high-grade dysplasia compared to those with low-grade dysplasia and that here is a positive correlation between ghrelin and ghrelin receptor expression in colorectal adenomas with high-grade dysplasia. Our results indicate the important role of ghrelin in dysplasia progression. Further studies on expression of specific ghrelin receptor types in colorectal adenomas are needed to ensure better understanding of the role of ghrelin receptors in promotion of cell proliferation and malignant transformation.

ARTICLE HIGHLIGHTS

Research background

Ghrelin is an adipokine that influences energy expenditure and appetite, modulates gastric motility, secretion of gastric acid, pancreatic endocrine function and has an important role in glucose metabolism, insulin resistance and metabolic syndrome. Metabolic syndrome is one of the known risk factors for colorectal carcinoma development, and both diseases have had a significant rise in prevalence. Colorectal adenomas are premalignant lesions that can with time progress to colorectal carcinoma, and have also been linked to metabolic syndrome. Ghrelin, as one of the links between metabolic syndrome and tumor progression, has been investigated in several tissues and tumors but current data are not sufficient for complete understanding of all ghrelin effects.

Research motivation

Researching the published data regarding influence of ghrelin and its receptor in colorectal carcinoma and colorectal adenoma progression, we realized that there is a need for further insight on the subject since data on this topic is lacking. Current guidelines on colorectal adenoma and carcinoma screening and postpolypectomy surveillance do not focus on the presence of metabolic syndrome or any of its components. Obtaining more insight into the link between metabolic syndrome and colorectal adenoma and carcinoma occurrence could possibly in future influence new guidelines.

Research objectives

We aimed to investigate the expression of ghrelin and ghrelin receptor in colorectal adenomas and adjacent colorectal tissue to give a new perspective on this problem.

Research methods

We conducted a prospective study (from June 2015 until May 2019) that included 92 patients who underwent polypectomy for colorectal adenomas in the Department of Gastroenterology and Hepatology, "Sestre milosrdnice" Clinical Hospital Center in Zagreb, Croatia. An additional sample of colon mucosa was collected in the proximity of the removed colorectal adenoma for further pathohistological analysis. Adenomas were graded according to the stage of dysplasia, and ghrelin and ghrelin receptor expression were determined immunohistochemically in both adenoma and adjacent colon tissue using the polyclonal antibody for ghrelin and ghrelin receptor.

Research results

High expression of ghrelin was 7 times more common in high-grade adenoma compared to low-grade adenomas (13.95% to 2.04%, $P = 0.048$), while the expression of ghrelin in adjacent colon tissue was low. We found no correlation between ghrelin receptor expression in adenoma and adjacent colon tissue and the grade of colorectal adenoma dysplasia. The most significant correlation was found between ghrelin and

ghrelin receptor expression in adenomas with high-grade dysplasia ($\rho = 0.519$, $P < 0.001$).

Research conclusions

Our study is the first to show that ghrelin and ghrelin receptor are expressed in colorectal adenomas and adjacent tissue. We found that ghrelin expression was more pronounced in adenomas with high-grade dysplasia compared to those with low-grade dysplasia. The results of this study underline the importance of ghrelin in progression of dysplasia in colorectal adenoma but there is a need for further studies to determine the expression of different subtypes of ghrelin receptors in colorectal adenomas and exact ghrelin receptors role.

Research perspectives

Ghrelin and metabolic syndrome role in general need to be adequately investigated in colorectal adenoma progression since we are experiencing an epidemic of colorectal carcinoma intertwined with an epidemic of obesity. We believe that obtaining more insight into this problem could help us to better understand the dysplasia progression pathways, influence the surveillance programs and guidelines, and in that way ensure early recognition of patients in greater risk for colorectal carcinoma development.

REFERENCES

- 1 **Kojima M**, Hosoda H, Date Y, Nakazato M, Matsuo H, Kangawa K. Ghrelin is a growth-hormone-releasing acylated peptide from stomach. *Nature* 1999; **402**: 656-660 [PMID: [10604470](#) DOI: [10.1038/45230](#)]
- 2 **Gahete MD**, Rincón-Fernández D, Villa-Osaba A, Hormaechea-Agulla D, Ibáñez-Costa A, Martínez-Fuentes AJ, Gracia-Navarro F, Castaño JP, Luque RM. Ghrelin gene products, receptors, and GOAT enzyme: biological and pathophysiological insight. *J Endocrinol* 2014; **220**: R1-24 [PMID: [24194510](#) DOI: [10.1530/JOE-13-0391](#)]
- 3 **Ghelardoni S**, Carnicelli V, Frascarelli S, Ronca-Testoni S, Zucchi R. Ghrelin tissue distribution: comparison between gene and protein expression. *J Endocrinol Invest* 2006; **29**: 115-121 [PMID: [16610236](#) DOI: [10.1007/BF03344083](#)]
- 4 **Gnanapavan S**, Kola B, Bustin SA, Morris DG, McGee P, Fairclough P, Bhattacharya S, Carpenter R, Grossman AB, Korbonits M. The tissue distribution of the mRNA of ghrelin and subtypes of its receptor, GHS-R, in humans. *J Clin Endocrinol Metab* 2002; **87**: 2988 [PMID: [12050285](#) DOI: [10.1210/jcem.87.6.8739](#)]
- 5 **Barazzoni R**, Zanetti M, Nagliati C, Cattin MR, Ferreira C, Giuricin M, Palmisano S, Edalucci E, Dore F, Guarnieri G, de Manzini N. Gastric bypass does not normalize obesity-related changes in ghrelin profile and leads to higher acylated ghrelin fraction. *Obesity (Silver Spring)* 2013; **21**: 718-722 [PMID: [23712974](#) DOI: [10.1002/oby.20272](#)]
- 6 **Kim MS**, Yoon CY, Jang PG, Park YJ, Shin CS, Park HS, Ryu JW, Pak YK, Park JY, Lee KU, Kim SY, Lee HK, Kim YB, Park KS. The mitogenic and antiapoptotic actions of ghrelin in 3T3-L1 adipocytes. *Mol Endocrinol* 2004; **18**: 2291-2301 [PMID: [15178745](#) DOI: [10.1210/me.2003-0459](#)]
- 7 **Bustin SA**, Jenkins PJ. The growth hormone-insulin-like growth factor-I axis and colorectal cancer. *Trends Mol Med* 2001; **7**: 447-454 [PMID: [11597519](#) DOI: [10.1016/s1471-4914\(01\)02104-9](#)]
- 8 **Li H**, Zhang X, Feng L. Ghrelin Regulates Cyclooxygenase-2 Expression and Promotes Gastric Cancer Cell Progression. *Comput Math Methods Med* 2021; **2021**: 5576808 [PMID: [34122616](#) DOI: [10.1155/2021/5576808](#)]
- 9 **Liu A**, Huang C, Xu J, Cai X. Lentivirus-mediated shRNA interference of ghrelin receptor blocks proliferation in the colorectal cancer cells. *Cancer Med* 2016; **5**: 2417-2426 [PMID: [27464938](#) DOI: [10.1002/cam4.723](#)]
- 10 **Waseem T**, Javaid-Ur-Rehman, Ahmad F, Azam M, Qureshi MA. Role of ghrelin axis in colorectal cancer: a novel association. *Peptides* 2008; **29**: 1369-1376 [PMID: [18471933](#) DOI: [10.1016/j.peptides.2008.03.020](#)]
- 11 **Volante M**, Allia E, Gugliotta P, Funaro A, Broglio F, Deghenghi R, Muccioli G, Ghigo E, Papotti M. Expression of ghrelin and of the GH secretagogue receptor by pancreatic islet cells and related endocrine tumors. *J Clin Endocrinol Metab* 2002; **87**: 1300-1308 [PMID: [11889202](#) DOI: [10.1210/jcem.87.3.8279](#)]
- 12 **Dagli AF**, Aydin S, Karaoglu A, Akpolat N, Ozercan IH, Ozercan MR. Ghrelin expression in normal kidney tissue and renal carcinomas. *Pathol Res Pract* 2009; **205**: 165-173 [PMID: [19054628](#) DOI: [10.1016/j.prp.2008.10.002](#)]
- 13 **Nurkalem C**, Celik H, Dagli F, Gurates B, Kavak B, Dogan Z, Baykus Y, Aydin S. Ghrelin and obestatin expression in serous ovarian tumours. *Gynecol Endocrinol* 2012; **28**: 941-944 [PMID: [22954236](#) DOI: [10.3109/09513590.2011.650753](#)]
- 14 **Dagli AF**, Aydin S, Kocdor H, Gurates B, Sahin I, Catak Z, Ozercan MR, Ozercan IH. Ghrelin expression of endometrium hyperplasia and endometrioid carcinoma. *Gynecol Endocrinol* 2011; **27**:

- 199-204 [PMID: [20712427](#) DOI: [10.3109/09513590.2010.488772](#)]
- 15 **Nikolopoulos D**, Theocharis S, Kouraklis G. Ghrelin's role on gastrointestinal tract cancer. *Surg Oncol* 2010; **19**: e2-e10 [PMID: [19328680](#) DOI: [10.1016/j.suronc.2009.02.011](#)]
 - 16 **Andrusiewicz M**, Komarowska H, Skibińska I, Chmielewska M, Jaskuła-Świtek M, Liebert W, Waśko R, Kotwicka M. Expression of ghrelin and ghrelin functional receptor GHSR1a in human pituitary adenomas. *Pol Arch Intern Med* 2017; **127**: 163-169 [PMID: [28377557](#) DOI: [10.20452/pamw.3967](#)]
 - 17 **Konishi F**, Morson BC. Pathology of colorectal adenomas: a colonoscopic survey. *J Clin Pathol* 1982; **35**: 830-841 [PMID: [7107955](#) DOI: [10.1136/jcp.35.8.830](#)]
 - 18 **Anderson JC**, Calderwood AH, Christensen BC, Robinson CM, Amos CI, Butterly L. Smoking and Other Risk Factors in Individuals With Synchronous Conventional High-Risk Adenomas and Clinically Significant Serrated Polyps. *Am J Gastroenterol* 2018; **113**: 1828-1835 [PMID: [30385834](#) DOI: [10.1038/s41395-018-0393-0](#)]
 - 19 **Peipins LA**, Sandler RS. Epidemiology of colorectal adenomas. *Epidemiol Rev* 1994; **16**: 273-297 [PMID: [7713180](#) DOI: [10.1093/oxfordjournals.epirev.a036154](#)]
 - 20 **Saklayen MG**. The Global Epidemic of the Metabolic Syndrome. *Curr Hypertens Rep* 2018; **20**: 12 [PMID: [29480368](#) DOI: [10.1007/s11906-018-0812-z](#)]
 - 21 **Esposito K**, Chiodini P, Colao A, Lenzi A, Giugliano D. Metabolic syndrome and risk of cancer: a systematic review and meta-analysis. *Diabetes Care* 2012; **35**: 2402-2411 [PMID: [23093685](#) DOI: [10.2337/dc12-0336](#)]
 - 22 **Guraya SY**. Association of type 2 diabetes mellitus and the risk of colorectal cancer: A meta-analysis and systematic review. *World J Gastroenterol* 2015; **21**: 6026-6031 [PMID: [26019469](#) DOI: [10.3748/wjg.v21.i19.6026](#)]
 - 23 **Spiridon IA**, Ciobanu DGA, Giuscă SE, Căruntu ID. Ghrelin and its role in gastrointestinal tract tumors (Review). *Mol Med Rep* 2021; **24** [PMID: [34296307](#) DOI: [10.3892/mmr.2021.12302](#)]
 - 24 **Johnstone MS**, Lynch G, Park J, McSorley S, Edwards J. Novel Methods of Risk Stratifying Patients for Metachronous, Pre-Malignant Colorectal Polyps: A Systematic Review. *Crit Rev Oncol Hematol* 2021; **164**: 103421 [PMID: [34246774](#) DOI: [10.1016/j.critrevonc.2021.103421](#)]
 - 25 **Khan AA**. Exploring polyps to colon carcinoma voyage: can blocking the crossroad halt the sequence? *J Cancer Res Clin Oncol* 2021; **147**: 2199-2207 [PMID: [34115239](#) DOI: [10.1007/s00432-021-03685-5](#)]
 - 26 **Waseem T**, Duxbury M, Ashley SW, Robinson MK. Ghrelin promotes intestinal epithelial cell proliferation through PI3K/Akt pathway and EGFR trans-activation both converging to ERK 1/2 phosphorylation. *Peptides* 2014; **52**: 113-121 [PMID: [24365237](#) DOI: [10.1016/j.peptides.2013.11.021](#)]
 - 27 **Wu H**, Zhang XY, Hu Z, Hou Q, Zhang H, Li Y, Li S, Yue J, Jiang Z, Weissman SM, Pan X, Ju BG, Wu S. Evolution and heterogeneity of non-hereditary colorectal cancer revealed by single-cell exome sequencing. *Oncogene* 2017; **36**: 2857-2867 [PMID: [27941887](#) DOI: [10.1038/onc.2016.438](#)]
 - 28 **Williet N**, Petcu CA, Rinaldi L, Cottier M, Del Tedesco E, Clavel L, Dumas O, Jarlot C, Bouarioua N, Roblin X, Peoc'h M, Phelip JM. The level of epidermal growth factor receptors expression is correlated with the advancement of colorectal adenoma: validation of a surface biomarker. *Oncotarget* 2017; **8**: 16507-16517 [PMID: [28157706](#) DOI: [10.18632/oncotarget.14961](#)]
 - 29 **Lien GS**, Lin CH, Yang YL, Wu MS, Chen BC. Ghrelin induces colon cancer cell proliferation through the GHS-R, Ras, PI3K, Akt, and mTOR signaling pathways. *Eur J Pharmacol* 2016; **776**: 124-131 [PMID: [26879868](#) DOI: [10.1016/j.ejphar.2016.02.044](#)]
 - 30 **Mottershead M**, Karteris E, Barclay JY, Suortamo S, Newbold M, Randevara H, Nwokolo CU. Immunohistochemical and quantitative mRNA assessment of ghrelin expression in gastric and oesophageal adenocarcinoma. *J Clin Pathol* 2007; **60**: 405-409 [PMID: [16751299](#) DOI: [10.1136/jcp.2006.038356](#)]
 - 31 **Cassoni P**, Papotti M, Ghè C, Catapano F, Sapino A, Graziani A, Deghenghi R, Reissmann T, Ghigo E, Muccioli G. Identification, characterization, and biological activity of specific receptors for natural (ghrelin) and synthetic growth hormone secretagogues and analogs in human breast carcinomas and cell lines. *J Clin Endocrinol Metab* 2001; **86**: 1738-1745 [PMID: [11297611](#) DOI: [10.1210/jcem.86.4.7402](#)]
 - 32 **Fung JN**, Jeffery PL, Lee JD, Seim I, Roche D, Obermair A, Chopin LK, Chen C. Silencing of ghrelin receptor expression inhibits endometrial cancer cell growth *in vitro* and *in vivo*. *Am J Physiol Endocrinol Metab* 2013; **305**: E305-E313 [PMID: [23736537](#) DOI: [10.1152/ajpendo.00156.2013](#)]



Published by **Baishideng Publishing Group Inc**
7041 Koll Center Parkway, Suite 160, Pleasanton, CA 94566, USA
Telephone: +1-925-3991568
E-mail: bpgoffice@wjgnet.com
Help Desk: <https://www.f6publishing.com/helpdesk>
<https://www.wjgnet.com>

