

Treatment of severe acne

Koželj, Marko

Master's thesis / Diplomski rad

2021

Degree Grantor / Ustanova koja je dodijelila akademski / stručni stupanj: **University of Zagreb, School of Medicine / Sveučilište u Zagrebu, Medicinski fakultet**

Permanent link / Trajna poveznica: <https://um.nsk.hr/um:nbn:hr:105:076331>

Rights / Prava: [In copyright](#)/[Zaštićeno autorskim pravom.](#)

Download date / Datum preuzimanja: **2025-01-01**



Repository / Repozitorij:

[Dr Med - University of Zagreb School of Medicine Digital Repository](#)



UNIVERSITY OF ZAGREB

SCHOOL OF MEDICINE

Marko Koželj

Treatment of severe acne

GRADUATE THESIS



Zagreb, 2022

This graduate thesis was made at the Department of Dermatology and Venerology, School of Medicine, University of Zagreb, mentored by Professor Zrinka Bukvić Mokos, MD, PhD, and was submitted for evaluation in the academic year 2021/2022.

ABBREVIATIONS

- AF-SS - Acne fulminans with systemic symptoms
- AF-WOSS - Acne fulminans without systemic symptoms
- BPO - Benzoyl peroxide
- CRP - C-reactive protein
- DHEA - Dehydroepiandrosterone
- DHT - Dihydrotestosterone
- EMA - European Medicines Agency
- ESR - Erythrocyte sedimentation rate
- FADS 2 - Fatty acid delta-6 desaturase 2
- FDA - Food and Drug Administration
- HSP - Heat shock proteins
- IIAF-SS - Isotretinoin-induced acne fulminans with systemic symptoms
- IIAF-WOSS - Isotretinoin-induced acne fulminans without systemic symptoms
- IL - Interleukin
- INF - Interferon
- LPS - Lipopolysaccharide
- LTB₄ - Leukotriene B₄
- MMP - Matrix metalloproteinase
- PARs - Protease activated receptors
- PMN - Polymorphonuclear
- PGN - Peptidoglycan
- RAR - Retinoic acid receptor
- RARE - Retinoic acid response element
- RXR - Retinoid X receptors

- SAPHO syndrome: synovitis, acne, pustolosis, hyperostosis and osteitis syndrome
- TGF - Transforming growth factor
- TLR - Toll-like receptor
- TNF - Tumor necrosis factor

TABLE OF CONTENTS

SUMMARY

SAŽETAK

1. Introduction	1
2. Etiopathogenesis of acne	4
2.1 Overview of acne pathogenesis	5
2.2 The role of <i>Cutibacterium acnes</i>	8
2.3 The role of androgens	9
2.4 The role of inflammatory mediators	10
3. Classification of acne according to the European guideline group	13
3.1 Comedonal acne	13
3.2 Mild to moderate papulopustular acne	14
3.3 Severe papulopustular / mild nodular acne	14
3.4 Severe nodular / conglobate acne	14
3.5 Other acne variants	15
4. Therapeutic approach to severe acne	16
4.1 Treatment of severe papulopustular acne to moderate nodular acne	16
4.1.1 Oral isotretinoin	17
4.1.1.1 Mechanism of action	17
4.1.1.2 Dosing	18
4.1.1.3 Adverse effects	19
4.1.1.4 Contraindications	21
4.1.2 Oral antibiotics	21
4.1.3 Oral antiandrogens	22
4.2 Treatment of severe nodular and conglobate acne	23
4.3 Acne fulminans	25
4.3.1 Epidemiology of acne fulminans	25
4.3.2 Pathogenesis of acne fulminans	25
4.3.3 Clinical presentation	27

4.3.4	Treatment of acne fulminans.....	29
5.	Maintenance therapy.....	32
6.	Conclusion.....	33
7.	Acknowledgements.....	34
8.	References.....	35
9.	Biography.....	45

SUMMARY

Title: Treatment of severe acne

Author: Marko Koželj

Acne vulgaris is a chronic inflammatory condition of the pilosebaceous unit, typically starting at puberty. The prevalence rate of 85% has been estimated among persons aged 12-24 years.

Acne formation is influenced by four major factors: androgen-induced increased sebum production, altered keratinization within the follicle, increased colonization of the pilosebaceous duct *Cutibacterium acnes*, and release of inflammatory mediators. Clinical features include non-inflammatory lesions (open and closed comedones), inflammatory lesions (papules, pustules, nodules), and various degrees of scarring. Acne may present as a mild (comedonal acne), moderate (mild to moderate papulopustular acne), or severe disease (severe papulopustular/moderate nodular acne, severe nodular/conglobate acne, and acne fulminans).

All severe acne vulgaris require systemic treatment with oral isotretinoin as the first-line treatment. Isotretinoin decreases the proliferation of sebocytes and sebum production, reduces the colonization of *Cutibacterium acnes* secondarily, normalizes the keratinization process within the follicle, and inhibits inflammation.

Oral hormonal antiandrogens and oral antibiotics may be used as an alternative therapy.

Acne fulminans is a rare and severe form of inflammatory acne, presenting with an abrupt onset of painful, hemorrhagic pustules and ulceration, usually accompanied by systemic symptoms (fever, polyarthritis, and laboratory abnormalities). Systemic corticosteroids are recommended as the initial treatment due to their anti-inflammatory effect. After 2-4 weeks, isotretinoin can be added with the corticosteroid/isotretinoin overlap for at least four weeks.

Key words: acne vulgaris, severe acne, acne fulminans, inflammation, isotretinoin

SAŽETAK

Naslov: Terapija teških oblika akne

Autor: Marko Koželj

Acne vulgaris je kronična upalna bolest pilosebacealne jedinice, a tipično se javlja u pubertetu. Procjenjuje se da je prevalencija akne među osobama u dobi od 12 do 24 godine oko 85%.

Nastanak akne pod utjecajem je četiri glavna čimbenika: pojačanog lučenja loja pod utjecajem androgena, poremećene keratinizacije folikula, povećane kolonizacije pilosebacealnog kanala bakterijom *Cutibacterium acnes* i otpuštanja proupalnih medijatora.

Klinička obilježja uključuju neupalne lezije (otvorene i zatvorene komedone), upalne lezije (papule, pustule, nodusi) i ožiljke različitog intenziteta.

Akne se može prezentirati kao blaga (acne comedonica), umjereno teška (blaga do umjerena acne papulopustulosa) i teška bolest (teška acne papulopustuloda/umjerena acne nodularis, teška acne nodularis/acne conglobata i acne fulminans).

Svi teški oblici vulgarne akne zahtijevaju sustavno liječenje oralnim izotretinoinom kao prvom linijom liječenja. Izotretinoin smanjuje proliferaciju sebocita i sintezu loja te sekundarno smanjuje kolonizaciju *Cutibacterium acnes*, normalizira keratinizaciju u folikulu i inhibira upalu. Alternativno se mogu oralni hormonski antiandrogeni i oralni antibiotici.

Acne fulminans je rijedak i težak oblik upalne akne, a pojavljuje se naglo, u vidu bolnih hemoragičnih pustula i ulceracija, koji su obično praćeni sustavnim simptomima (vrućica, poliartritis i poremećaji u laboratorijskim testovima). Sustavni kortikosteroidi se preporučuju kao početno liječenje zbog njihovog protuupalnog učinka. Nakon 2-4 tjedna, dodatno se uvodi izotretinoin koji se tijekom najmanje 4 tjedna primjenjuje zajedno s kortikosteroidima.

Ključne riječi: acne vulgaris, teški oblici akne, acne fulminans, upala, izotretinoin

1. Introduction

Acne vulgaris is a chronic inflammatory condition of the pilosebaceous unit (defined as a hair follicle associated with a sebaceous gland) that commonly occurs on the face, chest, and back. Acne is a term that the ancient Greeks have coined. It is a condition that has been known for millennia in human history and has already been described in ancient Egyptian pharaohs. It was described in the Egyptian Ebers Papyrus Pharmacopeia (3400 before the Common Era (BCE) - 1500 BCE) as *Aku-t*, a condition described as a skin disorder with inflamed skin that contained boils, pustules, and sores. Hippocrates associated acne with puberty, and Aristotle gave further descriptions of this disease in ancient Greek medicine (1).

Acne is known today as a condition typically starting at puberty; however, it may occur in prepubertal children and adults. Typical clinical features include non-inflammatory lesions (open and closed comedones), inflammatory lesions (papules, pustules, nodules), and various degrees of scarring (2).

Acne usually presents in areas of the body with the highest density of pilosebaceous units, such as the face, neck, upper chest, shoulders, and back. It is considered a chronic and relapsing inflammatory condition of varying severity and which may require long-term treatment (1).

Acne may present as a mild disease (comedonal acne), a disease of moderate severity (mild to moderate papulopustular acne), or severe disease (severe papulopustular/moderate nodular acne, severe nodular/conglobate acne, and acne fulminans) (3).

Prevalence rates of acne by age have been determined, and it has been estimated that 40-50 million U.S. individuals have acne, with an 85% prevalence rate in those

aged 12-24 years. Among those patients, 15-20% suffered from moderate to severe disease types. Prevalence of severe acne is virtually nil in the first decade of life but increases linearly from 11 years (1.7%) to 17 years of age. A study on the German population found that 64% of people aged 20-29 years and 43% of those aged 30-39 years had visible acne, and another study found that 3% of men and 5% of women aged 40-49 years still had a degree of acne. Acne is more common in Caucasians than in other ethnic groups at ages 14-15, girls aged 12-14, and people with higher socioeconomic standards (4). As acne is known to be mainly a disease of adolescence, the prevalence is highest at the age of 14 years in females and 16 years in males which also marks the peak occurrence of puberty (5).

A study conducted on 1002 highschool pupils concluded that pupils with a family history of acne exhibited a significantly higher prevalence of moderate/severe acne (19.9%) than those with no family history (9.8%) (6).

Around 20% of neonates have an acneiform eruption but this usually resolves spontaneously within 1 to 3 months. This form is more commonly present in boys than girls (7). After the teenaged years, women are more often affected by acne than men. The overall prevalence of acne does decline with age in both sexes, but significant number of individuals experience either a worsening of acne symptoms or fail to experience improvement after the teenaged years (8).

A study conducted among the U.S. population showed that severe acne might be associated with a higher prevalence of sinopulmonary disorders (sinus infection, non-streptococcal pharyngitis, non-asthmatic lung disease, hay fever, and respiratory allergy), gastrointestinal comorbidities (reflux or heartburn, abdominal pain, nausea and vomiting, and food or digestive allergy) and psychological comorbidities

(depression, anxiety, attention deficit hyperactivity disorder, and insomnia) (9).

However, further studies are needed to evaluate these associations.

2. Etiopathogenesis of acne

Acne is a multifactorial disease affecting the pilosebaceous unit. Acne formation is a consequence of the interaction of four main pathogenic factors, including (I) increased production of sebum; (II) disturbed keratinization within the follicle; (III) increased colonization of the pilosebaceous duct by the *Cutibacterium acnes* (*C. acnes*); and (IV) release of inflammatory mediators (10). Figure 1 illustrates those four main pathogenic factors in acne formation.

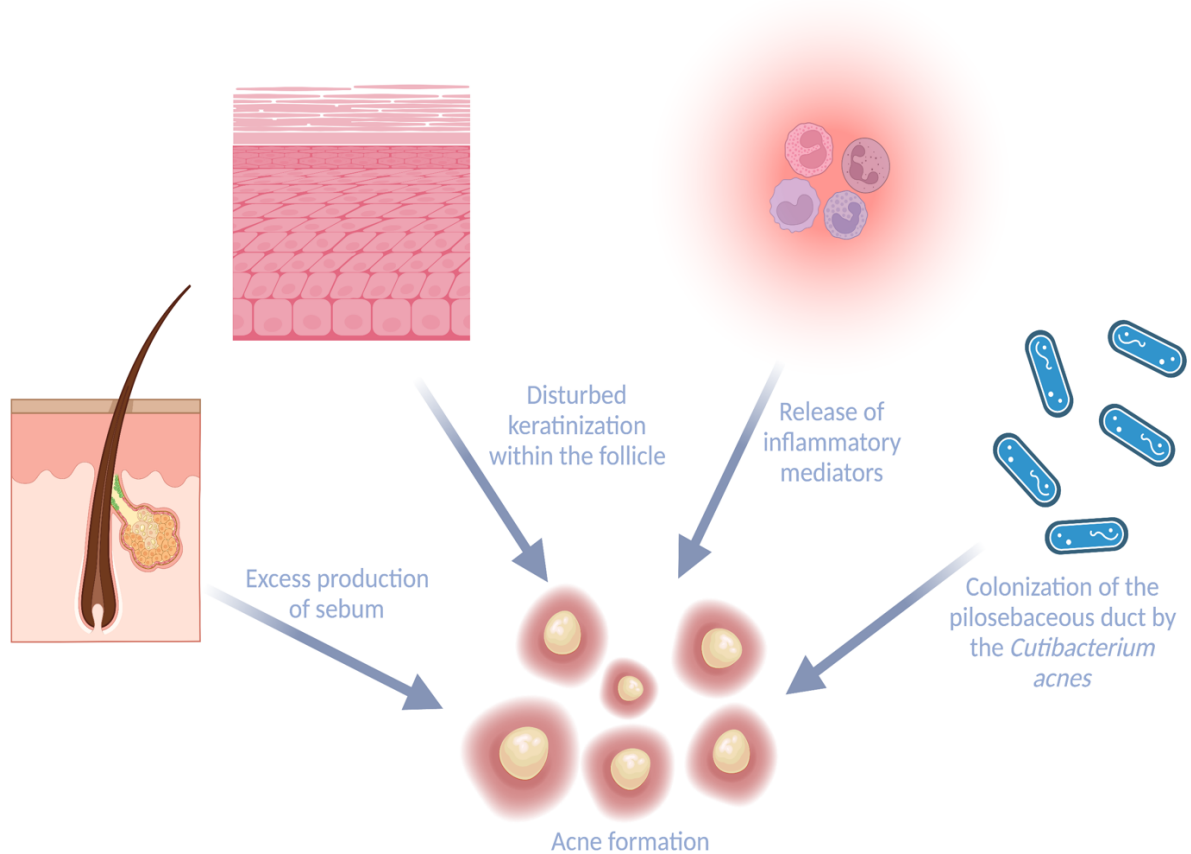


Figure 1: Four main pathogenic factors in acne formation (created with BioRender.com)

2.1 Overview of acne pathogenesis

In acne pathogenesis, the first step is the formation of microcomedone (10), which occurs mainly due to increased sebum production and altered follicular keratinization. Both processes are stimulated by androgens (dihydrotestosterone (DHT) and testosterone), usually at the time around puberty. It has been shown that androgens induce the proliferation of sebocytes of mainly facial skin (11). In addition, the differentiation and maturation of sebocytes are also under the influence of other hormones and cellular pathways such as peroxisome proliferator-activated receptors, substance P receptors, α -melanocyte-stimulating hormone, insulin-like growth factor, corticotropin-releasing hormone, vitamin D and ectopeptidases (12, 13). An increase in keratinocyte number within the pilosebaceous unit combined with their decreased shedding leads to mechanical obstruction of the duct (14). The accumulation of sebum and debris within the initial microcomedone results in clinically visible open and closed comedones. Thus, the environment of infra-infundibulum and follicles becomes favorable for the colonization of lipophilic commensal bacterium *C. acnes*.

C. acnes stimulate inflammation by releasing the inflammatory mediators into the surrounding perifollicular dermis. Released mediators are chemoattractants for immune cells, thus drawing them into the area where they induce the formation of inflammatory lesions. *C. acnes* contributes to inflammation by releasing lipases, proteases, and chemotactic factors (15). Released lipases degrade triglycerides, proteases damage the pilosebaceous unit, and chemotactic factors recruit CD4⁺-lymphocytes, neutrophils, and monocytes to the area of inflammation. Increased colonization of the pilosebaceous unit by *C. acnes* also causes activation of Toll-like receptor (TLR)-2 on monocytes, leading to the release of pro-inflammatory cytokine interleukin (IL)-8. IL-8, in turn, causes the attraction of neutrophils to the area (16, 17).

Other noteworthy processes contributing to the overall pathology include *C. acnes*-induced upregulation of other pro-inflammatory cytokines, namely IL-1 alpha, IL-1 beta, and IL-17. In addition, *C. acnes* induces activation of inflammasome on peripheral neutrophils by acting as a superantigen and activation of TLR-2 on keratinocytes which influences the keratinocyte differentiation and thus contribute to comedone formation (15, 18, 19).

In addition to these events, there is also a significant genetic component to acne formation. Recent research has identified six gene loci associated with the development of severe acne: 11q13.1, 5q11.2, 11p11.2, 1q41, 1q24.2, and 8q24. They are involved in androgen metabolism, inflammation processes, and scar formation. In addition, they contain genes that are linked to the transforming growth factor (TGF)- β cell signaling pathway, overexpression of which leads to hypertrophic scars and keloid formation (20-22).

Genetic influences are found particularly in neonatal acne, nodulocystic acne, and conglobate acne. Additionally, acne developing after the adolescent years correlates with having a first-degree relative with acne in 50% of cases (23).

Comedones develop after the initial formation of the microcomedo, which is the primary non-inflammatory lesion that can be observed. Comedones can be either open, named blackheads, or closed, named whiteheads. Finally, due to the stimulation mentioned above of inflammatory mediators, inflammatory lesions (papules, pustules, and inflammatory nodules) develop (1).

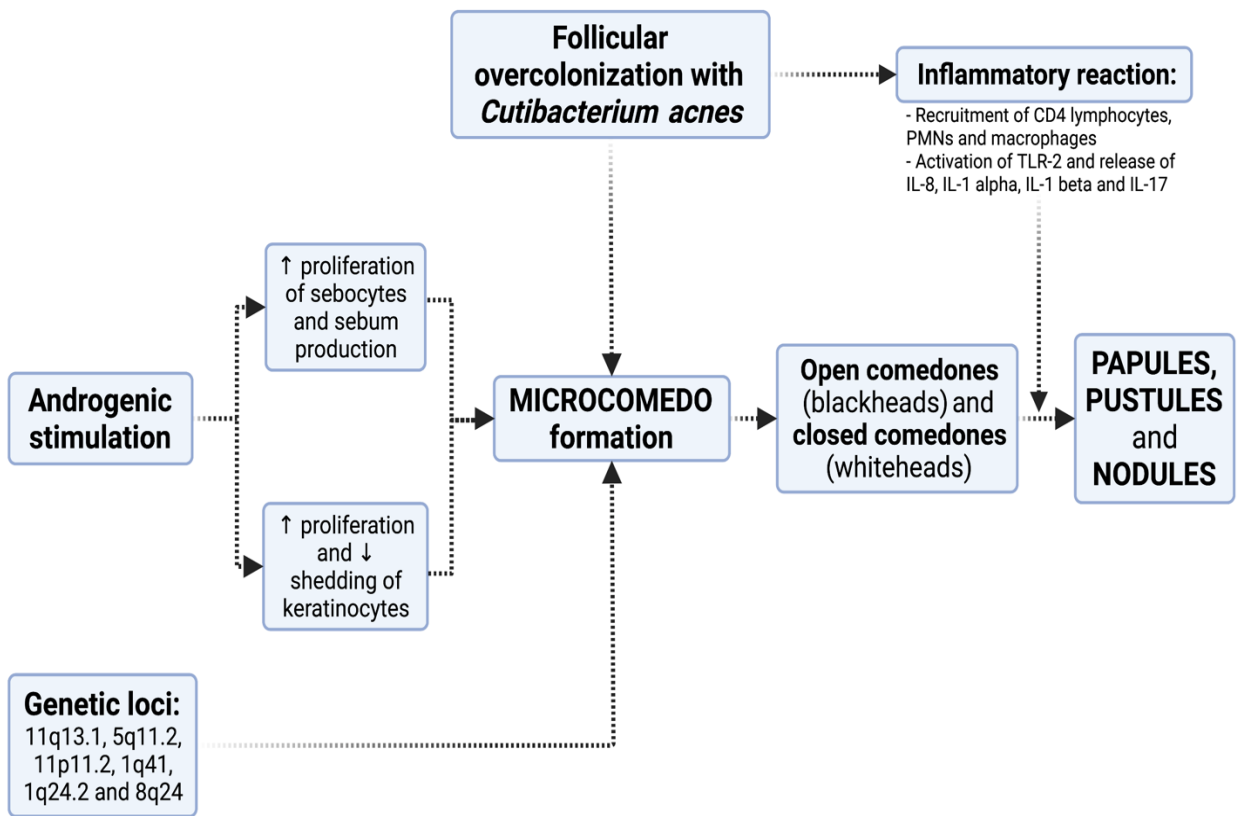


Figure 2: Pathogenesis of acne. (created with BioRender.com)

Abbreviations: ↑: increased; ↓: decreased; IL: interleukin; PMN: polymorphonuclear cells; TLR: toll-like receptor.

2.2 The role of *Cutibacterium acnes*

Skin microbiome, specifically *C. acnes*, has been linked to acne pathogenesis and formation. It is a gram-positive, anaerobic, lipophilic diphtheroid, commensal in human skin, and essential for acne development. These bacteria colonize the pilosebaceous unit and induce inflammation, as previously mentioned, by converting triglycerides to free fatty acids and producing mediators and chemotactic factors. Other bacteria, such as *Staphylococcus epidermidis*, and yeast *Mallasezia spp.*, have also been postulated to be potentially part of this process (1). Biopsy and culture of early non-inflamed lesions have shown that 30% of these are without bacteria, suggesting that ductal bacteria are not needed for the initial development of comedones. However, they are likely involved later in comedogenesis (24). Recent research showed that *C. acnes* is the most abundant and predominant bacterium in the microbiota of pilosebaceous follicles both in acne patients and in individuals with unaffected skin; however, they differentiate in specific genetic and phenotypic characteristics. Therefore, it is hypothesized that certain strains contribute to healthy skin (phylotype IA2, IB, and II), whereas others can contribute to acne formation (phylotype IA1) (25, 26). The most important virulence factors recognized in *C. acnes* contributing to acne formation are neuraminidase, lipase, polyunsaturated fatty acid isomerase, the iron acquisition protein HtaA (a highly immunoreactive cell surface antigen), and heat shock proteins (HSP) (HSP 20, DnaK, DnaJ, GrpE, and GroEL). They activate innate immunity via the expression of protease-activated receptors (PARs), tumor necrosis factor (TNF)- α and toll-like receptors (TLRs), and the production of interferon (INF) - γ , interleukins (IL-8, IL12, IL- 1), TNF, and matrix metalloproteinases (MMPs) (27). Additionally, *C. acnes* may promote comedo formation via the production of IL-1 α and possibly induce comedogenesis via the insulin-like growth factor -1/IGF-1 receptor (IGF-1/IGF-1R)

pathway (28). Studies have also shown that several genes on the *C. acnes* genome are potentially involved in forming a biofilm, which contributes to the forming of an “adhesive glue” leading to the binding of corneocytes resulting in microcomedones (29). The biofilm formed might also make cells more resistant to antimicrobial agents hence providing an insight into reasoning behind failed antibiotic therapies in acne patients (30).

Cutibacterium species are naturally resistant to 5-nitroimidazole agents (metronidazole, tinidazole, and ornidazole), aminoglycosides, sulfonamides, and mupirocin but are generally susceptible to erythromycin (macrolides), clindamycin (lincosamides) and tetracyclines. However, resistance to those has emerged over the years (31, 32).

2.3 The role of androgens

Increased circulating androgens are critical to the multifactorial pathogenesis of acne. It is well established that increased androgens exert a stimulatory effect on skin sebocytes which causes them to increase sebum production. The onset of acne correlates with the increase in androgens in adolescence (33).

A key component is the rising plasma testosterone in young teenagers, which involves converting testosterone to dihydrotestosterone by 5- α -reductase in the skin. It has been shown that the activity of 5- α -reductase is greater in acne-prone locations, such as the face than in non-acne-prone skin (1, 34). Additionally, levels of 5- α -reductase were greater in the sebaceous glands of patients with acne than in those without acne (35).

Androgen receptors (AR) are present in basal and differentiating sebocytes as well as in pilosebaceous duct keratinocytes, suggesting an androgenic influence on

pilosebaceous duct keratinization (36). Estrogen can inhibit the sebaceous gland stimulation, and these influences on acne can be seen in girls with estrogen level changes that can be observed during the menstrual cycle (1).

The earliest lesions, microcomedones, begin to appear at adrenarche (around age 8). During that time, adrenal androgens stimulate follicular hyperkeratosis and sebaceous hyperplasia in pilosebaceous units on the face. Around two years later, gonadal androgens are produced. The combined effect of colonization with *C. acnes* and adrenal effect cause the formation of comedones. Recent evidence suggests that androgens might also directly contribute to inflammation in the sebaceous gland due to the stimulation of androgen receptors on sebocytes. Besides increased sebum production, this can lead to the production of pro-inflammatory cytokines by sebocytes themselves (33).

2.4 The role of inflammatory mediators

Many factors contribute to inflammation of the pilosebaceous unit in acne formation. It has been shown that *C. acnes* plays a role in inflammation; however, several studies reported that *C. acnes* has not been present in all inflamed acne lesions. (37). However, it has been shown that keratinocytes and sebocytes may be activated by *C. acnes* via Toll-like receptors (TLR), CD1, and CD14 molecules, leading to the release of inflammatory cytokines and increasing the inflammation of the pilosebaceous unit (38).

C. acnes induces monocytes' IL-8 and IL-12 protein production via a TLR-2 pathway (17). TLR-2 and TLR-4 are expressed on keratinocytes and are primarily responsible for sensing peptidoglycan (PGN) and lipopolysaccharide (LPS), respectively (39). TLR-2 and TLR-4 expression is increased in the epidermis of acne lesions. *C. acnes*

induces TLR-2 and TLR-4 expression and the expression and secretion by the keratinocytes of matrix metalloproteinase (MMP)-9 (19).

Human SZ95 sebocytes express constitutively TLR-2, TLR-4, CD14, IL-1 α , IL-1 β , IL-6, and IL-8. Proinflammatory cytokine production is dependent on exposure to LPS of Gram-negative bacteria or lipoteichoic acid of Gram-positive bacteria (40).

Matrix metalloproteinases (collagenases, gelatinases, stromelysins, matrilysins) are zinc-dependent endopeptidases produced by keratinocytes and sebocytes. They are implemented in the process of inflammation in remodeling, neovascularization, wound healing, and malignant transformation (41). Due to their nature, MMPs are able to break down the components of the extracellular matrix. Hence, MMP can facilitate the rupture of the pilosebaceous follicle and enhance the ongoing inflammation (42).

Additionally, a decreased concentration of linoleic acid in skin surface lipids of acne patients may be recognized by keratinocytes and sebocytes, leading to the production of inflammatory cytokines (43, 44). The primary peroxidation product in human skin surface lipids is squalene monohydroperoxide which might lead to increased keratinocyte proliferation and upregulation and release of inflammatory mediators, which indicate a pro-inflammatory activity of by-products of squalene oxidation (45). Fatty acid delta-6 desaturase 2 (FADS2) might also contribute to inflammation by converting the essential fatty acid linoleic acid to arachidonic acid, which is a pro-inflammatory ω -6 polyunsaturated acid and an essential component of membrane phospholipids. Arachidonic acid is the precursor of many pro-inflammatory lipids and leukotriene B₄ (LTB₄) (46). It is also known to stimulate IL-6 and IL-8 synthesis in sebocytes and enhance the synthesis of sebaceous lipids (47, 48). This might contribute to the reasoning that increasing the intake of ω -3 fatty acids through a diet

rich in fish and seafood may result in lower rates of acne due to their inhibitory activity on the pro-inflammatory cytokines secretion and the LTB₄ synthesis (49).

LTB₄ plays significant roles in acne comedogenesis and inflammation. It is the most potent leukocyte chemotactic mediator; it induces superoxide radicals, activates complement, induces IL-8 production by neutrophils, and stimulates DNA synthesis and subsequent proliferation of keratinocytes. (50). In addition, LTB₄ binds and activates PPAR α , which can modulate inflammatory response in sebocytes by inhibiting the expression of pro-inflammatory genes that regulate the production of cytokines, metalloproteinases, and acute-phase proteins (50, 51).

3. Classification of acne according to the European guideline group

Acne is a multifactorial inflammatory disease with typical distribution mostly to the face; however, other sites, including the back and chest, are commonly affected in moderate and severe subtypes of acne. Acne is not a single disease but a collection of multiple subtypes with specific clinical features and presentations ranging from mild acne to severe fulminant illness. Thus, the clinical approach varies depending on the subtype of acne. According to the *European Evidence-based (S3) Guidelines for the Treatment of Acne*, several acne subtypes have been recognized, varying in severity. These include comedonal acne, mild to moderate papulopustular acne, severe papulopustular/moderate nodular acne, severe nodular/conglobate acne, and other acne variants and acneiform eruptions such as acne fulminans, rosacea fulminans, vasculitis, mechanical acne, oil/tar acne, chloracne, acne in neonates and infants and late-onset, persistent acne. It is important to note that in all subtypes of acne, the development of a microcomedo is an initial acne lesion from which all other subtypes further develop (3, 52).

3.1 Comedonal acne

Comedonal acne is the mildest form of the disease, including non-inflamed lesions that develop from a microcomedo. In clinical presentation, open comedones (blackheads) and closed comedones (whiteheads) are predominant. Occasional papules or pustules are also present (53).

They have a midfacial distribution in childhood, and when shown early in the course of the disease, they harbor a poor prognosis (3, 52).

3.2 Mild to moderate papulopustular acne

Mild to moderate papulopustular acne comprises both non-inflammatory and inflammatory lesions. Red, painful papules are present, some of which develop into papulopustules (53). The superficial inflammatory lesions can progress into deep pustules or nodules, leaving reddish macules and, occasionally, scars as they regress (3, 52).

3.3 Severe papulopustular / mild nodular acne

Severe papulopustular/mild nodular acne is characterized by numerous papules, pustules, and some inflamed nodules. They are more frequently seen also on the back and sternum (53).

3.4 Severe nodular / conglobate acne

Nodular/conglobate acne is the most severe form of acne. It is characterized by numerous nodules and cysts on the patient's skin, with comedones, papules, and pustules. Nodules are painful inflammatory lesions. We can differentiate between small nodules, which are ≤ 5 mm in size, and large nodules which are > 1 cm in size. They can cover large areas and extend deeply, forming painful sinus tracts with extensive tissue destruction. Conglobate acne is a rare severe form presenting most commonly in adult males in their twenties to thirties. In contrast to ordinary acne, where lesions most commonly target the facial area, these usually extend over the trunk, lower limb, and buttocks. Characteristic lesions for conglobate acne are multiple grouped comedones among multiple inflammatory papules and painful, suppurative nodules. After healing, extensive scarring is frequent (3, 52).

This thesis focuses on severe forms of acne, which will be described in detail in later sections.

3.5 Other acne variants

As already mentioned before, many unusual variants of acne and other acneiform eruptions mimic acne but are their own entities with different etiology and pathophysiology. These include acne fulminans, gram-negative folliculitis, rosacea fulminans, vasculitis, mechanical acne, oil/tar acne, chloracne, acne in neonates and infants, and late-onset acne that can be connected to different genetic or iatrogenic endocrinopathies. (3, 52, 54)

Acne fulminans (AF) is a rare and severe form of inflammatory acne. It clinically presents with an abrupt outburst of painful, hemorrhagic pustules and ulcerations, which may or may not be associated with systemic symptoms like fever, polyarthrititis, and laboratory abnormalities. Typically, it affects male teenagers with pre-existing acne, and the treatment significantly differs from severe acne according to the severity of clinical presentation and possible systemic involvement. Acne fulminans will be described in more detail in the separate section of this thesis (55).

4. Therapeutic approach to severe acne

Severe forms of acne can be classified into three distinct groups: severe papulopustular acne to moderate nodular acne, severe nodular/conglobate acne, and acne fulminans.

The severity of acne in adolescence is associated with several factors, such as the positive history of severe acne in first-grade relatives, especially the mother, occurrence in early puberty, and occurrence in girls with notably elevated dehydroepiandrosterone (DHEA) sulfate serum levels during the adrenarche.

Severe acne is, in most cases, chronic disease and is often a component of systemic diseases or syndromes.

Treatment options for severe acne are different from those in mild and moderate subtypes since all forms of severe acne require systemic treatment. These include oral isotretinoin, oral antibiotics, oral hormonal antiandrogens, and systemic corticosteroids combined with oral isotretinoin (56).

4.1 Treatment of severe papulopustular acne to moderate nodular acne

Severe papulopustular acne presents with superficial inflammatory papules and pustules (5mm or less in diameter) that evolve into deep pustules or nodules. After the regression, inflammatory macules persisting for many weeks can also be observed. Typical for nodular acne are nodules which 5mm or less in diameter, inflamed lesions painful on palpation.

Oral isotretinoin monotherapy is the first-line treatment for this type of acne. Moderate strength of recommendation is given for treatment with systemic antibiotics in combination with adapalene, a fixed dose combination of adapalene and benzoyl

peroxide (BPO), or azelaic acid. Low strength of recommendation for the combination of oral antiandrogens with oral antibiotics or topical treatment. Treatment with single or combined topical monotherapy is not advised in the treatment of severe papulopustular and moderate nodular acne (3).

4.1.1 Oral isotretinoin

Isotretinoin or 13-cis-retinoic acid is an oral retinoid approved for use in the U.S. by Food and Drug Administration (FDA) in 1982 for patients suffering from severe, resistant, nodular acne that is unresponsive to conventional therapy, including systemic antibiotics (57).

4.1.1.1 Mechanism of action

Isotretinoin targets all four main pathogenetic factors in acne. It decreases the proliferation of sebocytes and sebum production and normalizes the keratinization process within the follicle. Since it reduces sebum production, it indirectly leads to the decreased colonization of lipophilic bacteria *C. acnes*.

Isotretinoin works through influence on cellular growth, differentiation, morphogenesis, and apoptosis, inhibition of tumor promotion and malignant cell growth, immunomodulatory actions, and alteration of cellular cohesiveness. It acts on RAR (retinoic acid receptors) and RXR (retinoid X receptors) in the cellular nucleus. Additionally, it directly binds to a specific retinoic acid response element (RARE) in the promoter region of the target genes.

Anti-proliferative and anti-inflammatory actions of isotretinoin are proposed to be mediated by a negative, indirect regulatory mechanism by downregulation of genes that do not contain RARE in their promoter region. It antagonizes other transcription

factors, such as activator protein-1 and nuclear factor-IL 6 through competition for co-activator proteins. Isotretinoin has also been shown to regulate the expression and activation of Toll-like receptors (58, 59).

4.1.1.2 Dosing

Dosing recommendation of systemic isotretinoin for severe papulopustular acne and moderate nodular acne is 0.3-0.5 mg per kilogram of the patient's body weight. Therapy should last at least six months, with the possibility of prolongation of treatment in case of insufficient response (3).

Some studies suggest starting the daily dosing at 0.1mg/kg per day since this significantly reduces the frequency and severity of side effects (60).

Additionally, intermittent isotretinoin therapy can also be used to lower the incidence of the side effects while still providing similar clinical results associated with conventional treatment. Intermittent isotretinoin therapy includes taking isotretinoin for a specific period of time within a month while stopping its use for the rest of the month and repeating the process for a few months, e.g. taking isotretinoin daily for one week out of every four weeks (61, 62).

A single 10-20 mg daily dose of isotretinoin for over six months was shown to reduce inflammatory lesions by 87-94%, non-inflammatory lesions by 81-88%, sebaceous gland size was reduced by 35-58%, sebum production by 90-95%, follicular keratinization by 55-70% and *C. acnes* by 33-73% (63).

Isotretinoin is a lipophilic molecule with low bioavailability that can be maximized by taking it with meals (64).

Lidose is a novel technology that enhances intestinal absorption of poorly soluble agents, such as isotretinoin. Lidose uses lipid agents to encase lipophilic drugs and

create an optimal environment for absorption. Isotretinoin-Lidose is a novel isotretinoin formulation that can be taken without regard to the meals while still providing consistent absorption (64, 65).

4.1.1.3 Adverse effects

The severity and range of side effects depend on dose and personal factors, although all treated patients suffer from some side effects. The side-effect profile qualitatively resembles the toxic effects of vitamin A or hypervitaminosis A syndrome (66).

The most common dose-dependent adverse effect is cheilitis (dry lips), seen in up to 98% of patients. Others include xerosis (dry skin) with pruritus, acral desquamation, facial erythema, eczema, skin fragility, paronychia, pyogenic granulomas, bruising, eruptive xanthomas, photosensitivity, paronychia, onycholysis, nail plate fragility, and alopecia. Besides mucocutaneous reactions, other noteworthy side effects are lipid abnormalities. It is estimated that 20–45% of patients develop hypertriglyceridemia, while 30% develop elevated total cholesterol and low-density lipoprotein levels. In some cases, there may be a decrease in high-density lipoprotein levels, especially in people with risk factors such as truncal obesity (increased waist-to-hip ratio), hyperinsulinemia, presence of apoE gene, and a parent with hypertriglyceridemia. However, these abnormalities are rarely severe enough to require discontinuation of therapy, and they normalize to baseline after discontinuation of treatment (59).

Mild-to-moderate transitory elevations of liver enzymes have been observed in approximately 20% of individuals treated with isotretinoin. Circulating alkaline phosphatase levels, lactic dehydrogenase, and bilirubin levels may also become elevated during retinoid therapy. Liver function abnormalities are mostly mild and

usually occur 2–8 weeks after starting treatment, returning to normal within another 2–4 weeks, despite continued therapy.

Arthralgias and myalgias may occur in up to 2–5% of individuals receiving oral isotretinoin in doses higher than 0.5 mg/kg/day, more commonly in adolescents and young adults (66).

There have also been reports of isotretinoin being connected to skeletal abnormalities such as diffuse idiopathic skeletal hyperostosis syndrome, calcification of ligaments, osteoporosis, premature fusion of epiphyses, and long bone modeling abnormalities. However, the recent study has shown no clinically significant radiographic bony abnormalities (67).

A number of cases have been reported in the literature of mental symptoms associated with isotretinoin, including depression and suicidal behaviour (68). However, several systematic reviews came to different conclusions (3). Although recent meta-analyses have not shown an association between isotretinoin and depression (68, 69), it is recommended to evaluate prior symptoms of depression before isotretinoin initiation and during the treatment (3). Also, patients should be informed for a possible risk of depression (3).

Furthermore, the association between isotretinoin treatment and inflammatory bowel disease is controversial (69, 70).

Isotretinoin can worsen acne in the initial phase of treatment. Usually, the flare-up lasts only 2–3 weeks, although sometimes they can persist for several months.

All skin resurfacing procedures (waxing, laser therapy, dermabrasion) should be avoided during and at least six months after treatment to prevent irritation and scarring (71).

4.1.1.4 Contraindications

Isotretinoin is classified as a pregnancy category X drug under the FDA, meaning it is contraindicated during pregnancy due to its well-known teratogenic potential. It is estimated that 18–22% of pregnancies exposed to isotretinoin result in spontaneous abortion. Of those fetuses that survive, 20–30% will develop malformation, including craniofacial defects (cleft lip, anotia, small/absent auditory canals, microphthalmia), cardiac abnormalities (septal defects), central nervous system abnormalities (microcephaly, hydrocephalus), thymic hypoplasia, and limb reduction or duplication (59).

A pregnancy prevention program for each female patient of childbearing age is required according to the European Medicines Agency (EMA) and FDA (iPledge program). Two pregnancy tests are needed before isotretinoin treatment, one before initiation of contraception and the other up to two weeks before treatment. Two forms of contraception are required for at least one month before the treatment, two negative pregnancy tests are required before the start of therapy, contraception is necessary during the treatment, and five weeks after the therapy discontinuation (59, 66).

Other absolute contraindications are breastfeeding and noncompliance with contraception, while relative contraindications are leukopenia, moderate-to-severe hypercholesterolemia or triglyceridemia, hepatic or renal dysfunction, and hypothyroidism (66).

4.1.2 Oral antibiotics

The most commonly used oral antibiotics in the treatment of *acne vulgaris* are tetracyclines. Doxycycline and lymecycline are the antibiotics of choice. They work as bacteriostatic agents by inhibiting protein synthesis through binding to the 30S subunit

of the bacterial ribosomes. This causes a decrease in bacterial lipases and consequent reduction in free fatty acids in the sebum. Additionally, they also have an anti-inflammatory effect due to their ability to suppress neutrophil chemotaxis, inhibit MMPs and reactive oxygen species formation, and upregulate the anti-inflammatory cytokines and downregulate the pro-inflammatory cytokines. Doxycycline and minocycline have also shown antiangiogenic property (34).

The most frequent adverse reactions of doxycycline are photosensitivity and esophagitis, whereas, in treatment with minocycline hepatic dysfunction, hypersensitivity reactions and lupus-like syndrome have been described. Tetracycline has a decreased absorption when taken with dairy products. It also induces increased photosensitivity in comparison with doxycycline and lymecycline. Lymecycline is comparable to tetracycline, with lower phototoxicity than doxycycline (56).

The maximum duration of treatment with doxycycline and lymecycline should not be longer than three months (3). They can also be combined with other treatment options such as topical azelaic acid due to its anti-inflammatory properties (72).

4.1.3 Oral antiandrogens

Hormonal antiandrogens such as cyproterone acetate, chlormadinone acetate, dienogest, desogestrel, and drospirenone, are effective in female patients with severe acne. They are indicated for use in female patients with peripheral hyperandrogenism, hyperandrogenemia, female patients with *acne tarda* (late-onset acne), and those with acne refractory to treatment with other treatment modalities (73). The ideal duration of therapy should be between 6 and 12 months for sufficient efficacy. They exhibit their effect by binding to androgenic receptors and blocking them (73, 74). Additionally, there is evidence that they act by inhibiting 3 β -hydroxysteroid dehydrogenase/ Δ^{5-4} -

isomerase in the skin, adrenal and sebaceous glands. This prevents the conversion of dehydroepiandrosterone (DHEA) to testosterone and androstenedione (75, 76).

Another drug that can also be used due to its androgen receptor blocking action is spironolactone, an aldosterone antagonist. It can be combined with other oral antiandrogens to treat hormone-related acne (77).

Adverse effects of antiandrogenic treatment are edema, enhanced risk of thrombosis, breast tenderness, increased appetite, weight gain, and a decreased libido (78).

4.2 Treatment of severe nodular and conglobate acne

As already mentioned, nodular acne is characterized by highly inflammatory painful nodules, comedones, papules or pustules, and nodulocystic lesions. In its severe form, it may extend deeply and over large areas, forming exudative sinus tracts and tissue destruction. The likelihood of scarring is greater in this type of acne than in papulopustular acne due to its delayed and specific inflammatory response. Papulopustular acne is caused by a more immediate, nonspecific reaction (79).

Acne conglobata is not very common, and it is more commonly present in adult males and may be associated with the use of anabolic steroids. It causes few or no systemic symptoms. The lesions are present on the face, the trunk, and upper limbs and frequently extend to the buttocks. Inflammatory nodules progress into deep burrowing abscesses interconnecting together, forming sinus tracts. Cysts contain purulent material pushing into adjacent tissues and being discharged on the skin surface. Scar formation and disfigurement are common with this type of acne (3, 80).

As with severe papulopustular acne and moderate nodular acne, there is a strong recommendation to treat severe nodular and conglobate acne with monotherapy of oral isotretinoin. Second-line or medium strength of recommendation is given for

systemic antibiotics and oral antiandrogens. These treatments are already described in detail in the previous section on moderate to severe papulopustular acne. Those treatments can be combined with adapalene-BPO fixed-dose combination or with azelaic acid, with low strength of recommendation of the treatment with oral antiandrogens in combination with a topical treatment. Monotherapy with oral antibiotics and oral antiandrogens, artificial UV radiation sources, and visible light monotherapy are not recommended for the treatment of conglobate acne. In addition, topical monotherapy is not recommended for the treatment of this type of acne.

The dosage recommendation for systemic isotretinoin in the case of severe nodular acne and conglobate acne is 0.5-1.0 mg per kilogram of the patient's body weight. As in the case of severe papulopustular acne and moderate nodular acne, therapy should also last at least six months, with the possibility of treatment prolongation in case of insufficient response (3).

There have also been reports of adalimumab use to treat severe refractory cases of acne conglobata. Adalimumab is a tumor necrosis factor (TNF)-alpha inhibitor, which has been used successfully for the treatment of multiple chronic inflammatory disorders such as psoriasis, hidradenitis suppurativa, psoriatic arthritis, rheumatoid arthritis, ankylosing spondylitis, juvenile idiopathic arthritis, Crohn disease, and ulcerative colitis. TNF alpha is one of the inflammatory cytokines involved in the pathogenesis of acne formation (81).

4.3 Acne fulminans

As already mentioned before, acne fulminans is a rare and severe form of inflammatory acne. It presents with an abrupt onset of painful, hemorrhagic pustules and ulceration, usually accompanied by systemic symptoms (fever, polyarthritis, and laboratory abnormalities) (55).

4.3.1 Epidemiology of acne fulminans

Acne fulminans accounts for less than 1% of total acne cases; however, its incidence appears to be decreasing, possibly due to better and earlier treatment of acne (55, 82).

Acne fulminans mainly affects male adolescents aged 13 to 22 years (82). Several risk factors have been recognized, including the use of anabolic steroids, high dose testosterone, and high initial doses of systemic isotretinoin in the treatment of pre-existing acne vulgaris (83).

4.3.2 Pathogenesis of acne fulminans

The etiology of acne fulminans is still not completely understood; however, different etiologic factors have been proposed, including altered immune response, genetic factors, infectious agents, and hormonal factors.

One theory suggests that acne fulminans develops as an immunologically mediated type III and/or type IV hypersensitivity reaction to *C. acnes* antigens (84).

It has been shown that isotretinoin used in treating severe acne may paradoxically induce acne fulminans. Isotretinoin increases skin fragility ("isotretinoin-induced fragility") by reducing the number of tonofilaments and desmosomal attachments in the epidermis. It can also inhibit collagenase and gelatinase activity in stimulated

fibroblasts *in vitro*. Furthermore, isotretinoin can induce the fragility of pilosebaceous duct epithelium, which can cause profound contact of *C. acnes* antigens and/or its attractants with the immune system (85).

Another theory suggests a genetically determined change in neutrophil activity that causes hyperreactivity to chemoattractants, resulting in decreased phagocytosis of *C. acnes* (86).

Elevated blood levels of testosterone may also play an important role in the pathogenesis of acne fulminans (87). We can see those examples in patients treated with testosterone due to excessively tall stature, bodybuilders self-medicating with high doses of testosterone and anabolic steroids, and patients with Marfan syndrome receiving testosterone therapy (88-90). A physiological increase of testosterone in males during puberty might explain why this condition mainly affects male adolescents. Large doses of androgenic and anabolic steroids increase sebum secretion, leading to increased colonization of *C. acnes*. Consequently, *C. acnes* may, in some patients, induce an immunological reaction to its antigens (90).

There is evidence that acne fulminans may be considered a complex autoimmune disease since circulating immune complexes (arthus reaction) might be detected with platelet aggregation test in some patients with acne fulminans, predominantly those with musculoskeletal symptoms (91-93). This hypothesis is supported by a rapid response of patients with acne fulminans to systemic steroids, an increase in gamma globulins, and a decrease in C3 complement levels in several patients.

The association of acne fulminans with SAPHO (synovitis, acne, pustulosis, hyperostosis, and osteitis) syndrome also suggests the involvement of tumor necrosis factor- α (TNF- α). This theory is supported by the beneficial effects of the anti-TNF- α agent, infliximab, in the treatment of acne fulminans (93).

Due to the report of acne fulminans appearance two weeks after a measles infection, there is a probability of infectious etiology of acne fulminans. In addition, measles can trigger a transient release of inflammatory cytokines, which could trigger acne fulminans in vulnerable individuals (94).

Alongside mentioned theories, genetic and hereditary factors might also play an important role since acne fulminans has been reported in identical monozygotic twins. The age of presentation and severity of the disease was similar in identical monozygotic twins, which might be due to the associated HLA α 6 gene (95-97).

4.3.3 Clinical presentation

Acne fulminans is a syndrome comprised of 5 features: (I) sudden onset; (II) severe ulceration without cyst formation; (III) systemic symptoms such as fever and polyarthralgia; (IV) failure to respond to usual antibiotic therapy; and lastly (V) good response to systemic steroid therapy after 4-6 weeks with the addition of oral isotretinoin (93, 98). The lesions are described as hemorrhagic, tender, crusted nodules of the face, upper chest, back and shoulders. Apart from fever and polyarthralgia, systemic symptoms are malaise and myalgias (99). Arthralgia and joint swellings occur mainly in large joints such as the iliosacral, iliac, and knee joints. Additionally, aseptic osteolytic bone lesions and increased technetium uptake on bone scans have been reported in acne fulminans, with various histological appearances of benign reactive changes being reported. Preferred sites of bone involvement are the anterior chest, including the sternum and clavicles, but hips, ankles and humerus can also be involved (82).

Bacterial cultures from blood, joint fluid, and skin are usually sterile with sporadic isolation of *C. acnes* from bone lesions (100). Usually, the patient's laboratory findings

include accelerated erythrocyte sedimentation rate (ESR), increased C-reactive protein levels (CRP) and leukocytosis with a leukemoid reaction up to 30 000/mm² (101). Usually, there is an increased percentage of polymorphonuclear leukocytes, elevated levels of liver enzymes, thrombocytosis, and normochromic normocytic anemia. Sometimes there is also the presence of microscopic hematuria, proteinuria, and other kidney abnormalities. Serum proteins are usually normal but may show decreased albumin or increased α -globulin and γ -globulin. Circulating immune complexes have been found in some patients with both acne fulminans and erythema nodosum (91, 92).

Acne fulminans can be involved as part of the SAPHO (synovitis, acne, pustulosis, hyperostosis, and osteitis) syndrome spectrum. SAPHO syndrome is a clinical condition in which there is an association between musculoskeletal disorders such as synovitis, hyperostosis, osteitis, and various dermatological conditions (102). The diagnostic criteria of SAPHO syndrome include: (I) osteoarticular manifestations of palmoplantar pustulosis, severe acne (acne fulminans or acne conglobata) or hidradenitis suppurativa; (II) hyperostosis of the anterior chest wall, spine, pelvis or limb, with or without dermatosis; and (III) chronic recurrent multiple osteomyelitis with or without dermatosis (103).

Depending on the presence of severe symptoms and causative factors there has been a proposed classification of acne fulminans into four categories: (I) acne fulminans with systemic symptoms (AF-SS); (II) acne fulminans without systemic symptoms (AF-WOSS); (III) isotretinoin-induced acne fulminans with systemic symptoms (IIAF-SS); and (IV) isotretinoin-induced acne fulminans without systemic symptoms (IIAFF-WOSS) (83).

Table 1: Acne fulminans classification according to symptoms and causative factors.

Acne fulminans form	Abbreviation	Description
Acne fulminans with systemic symptoms	AF-SS	Sudden flare of inflammatory acne, with erosions and crusts, ulcers, hemorrhagic nodules/plaques + systemic symptoms: fever, malaise, bone pain, arthralgias, erythema nodosum, and leukocytosis + laboratory abnormalities: anemia, leukocytosis, elevated ESR and CRP
Acne fulminans without systemic symptoms	AF-WOSS	A sudden flare of inflammatory acne, with erosions and crusts, ulcers, hemorrhagic nodules/plaques without systemic symptoms
Isotretinoin-induced acne fulminans with systemic symptoms	IIF-SS	Same as AF-SS, induced by isotretinoin
Isotretinoin-induced acne fulminans without systemic symptoms	IIF-WOSS	Same as AF-WOSS, induced isotretinoin

Abbreviations: AF, acne fulminans; AF-SS, acne fulminans with systemic symptoms; AF-WOSS, acne fulminans without systemic symptoms; IIF-SS, isotretinoin-induced AF with systemic symptoms; IIF-WOSS, isotretinoin-induced acne fulminans without systemic symptoms.

4.3.4 Treatment of acne fulminans

The treatment of acne fulminans is challenging. In almost all cases, systemic corticosteroids are recommended at the immediate onset of acne fulminans to quickly control the severity of inflammation. Initially, treatment with 0.5 mg/kg/day to 1 mg/kg/day of prednisone is recommended for at least four weeks for AF-SS and at

least two weeks for AF-WOSS, and it should be continued until the crusted lesions have healed. Afterward, low dose isotretinoin (0.1 mg/kg/day) can be added with the corticosteroid/isotretinoin overlap for at least four weeks. After that, isotretinoin can be gradually increased with a slow taper (4 to 8 weeks) of corticosteroids (83). Patients usually have a favorable response, but there is a high relapse rate if the dosage of corticosteroids is reduced too quickly. In those cases the relapse usually occurs 2-8 weeks after the acute attack when the corticosteroid dosage is reduced or stopped, with worsening of arthralgia and sometimes fever, but usually not with worsening of the cutaneous nodules (82).

As isotretinoin can precipitate acne fulminans, it is not the initial treatment of choice. When used in the treatment of acne fulminans, a minimum total dose of at least 120 mg/kg is recommended. Tetracyclines are not recommended as a first-line treatment for acne fulminans since it showed a poor clinical response rate to antibiotics alone (82, 83).

In case of refractory acne fulminans in which combination therapy of corticosteroids and isotretinoin proves unsuccessful, other treatment modalities have been described in the literature. Diaminodiphenylsulfone has been used due to its possible effect on neutrophils by attacking the O_2 -dependent cytotoxic system of neutrophils by reducing the concentration of toxic O_2 intermediate and preventing the migration of neutrophils into the tissue by inhibition of integrin-mediated adhesion to the vessel walls (104). Cyclosporine A selectively suppresses the activation of T cells via suppression of calcineurin and leads to the inhibition of IL-2 production. Additionally, it affects innate immunity, inhibits monocyte and neutrophil phagocytosis, and prolongs NK cell survival (105).

The biologic agents etanercept (TNF inhibitor) and infliximab (chimeric monoclonal antibody against TNF-alpha) have been successfully used to treat isotretinoin-resistant acne conglobata (106, 107).

Isotretinoin therapy appears to predispose patients to the development of both hyperplastic granulation tissue and pyogenic granulomas, particularly at sites of trauma. Treatment of such lesions consists of high-potency topical steroids, topical protein coagulants such as silver nitrate, electrocautery, excision, or pulse-dye laser (108).

5. Maintenance therapy

According to the European Evidence-based (S3) Guideline for the treatment of acne (2016), the fixed-dose combination of adapalene and benzoyl peroxide (BPO) can be considered for the maintenance treatment of severe papulopustular/ moderate nodular acne and severe nodular/ conglobate acne. Azelaic acid, BPO alone, or topical retinoid alone (preferable adapalene over tretinoin) can also be considered.

As systemic maintenance therapy for severe papulopustular/moderate nodular acne and severe nodular/conglobate acne, low dose systemic isotretinoin (max. 0.3 mg/kg/day) can also be considered.

In females, continued hormonal antiandrogens and topical treatment (apart from antibiotics) can also be considered. (3)

6. Conclusion

Acne vulgaris is an illness affecting a large proportion of adolescents and sometimes even persisting into adulthood. Severity of acne vulgaris varies from mild comedonal and papulopustular to severe papulopustular, nodular and conglobate acne. There are four main pathogenetic factors in acne, including an excess in sebum production, disturbed keratinization within the follicle, increased colonization of the pilosebaceous duct by the *C. acnes*, and lastly release of inflammatory mediators. All the severe forms of acne vulgaris can be treated with oral isotretinoin. Isotretinoin is a systemic retinoid successfully used to treat severe acne since it inhibits sebaceous gland activity and normalizes the keratinization process within the follicle. However, it's important to note the dose-related relationship with frequency and severity of side effects and contraindication of isotretinoin use in pregnancy due to its highly teratogenic potential.

Acne fulminans is a rare form of acne differentiated from other severe forms of acne vulgaris in pathogenesis and treatment regimen. Initial treatment, in this case, consists of systemic steroids, whereas oral isotretinoin is administered after 2-4 weeks with the corticosteroid/isotretinoin overlap for at least four weeks.

While all forms of acne vulgaris can have a negative effect on patients' well-being, confidence, and self-esteem, severe forms can have a profoundly debilitating effect on patients' quality of life, mental health, and self-esteem beyond just a cosmetic concern. Although extensive research has been done on pathogenesis and treatment of acne, much about pathogenesis and treatment response remains unknown and is a field of ongoing research.

7. Acknowledgements

First, I would like to express my deepest gratitude to my mentor Professor Zrinka Bukvić Mokos, MD, PhD, for her invaluable guidance, feedback, and excellent mentorship throughout the process of writing this thesis.

Secondly, I would also like to thank Professor Branka Marinović, MD, PhD, and Professor Romana Čeović, MD, PhD, for reviewing the thesis and providing valuable feedback.

I would also like to express my deep gratitude to my family and close friends for all the support throughout the study years and life, without whom none of this would be possible.

Lastly, I would like to thank University of Zagreb, School of Medicine for giving me high quality medical education and the opportunity to pursue my lifelong dream to become a medical doctor.

8. References

1. Greydanus DE, Azmeh R, Cabral MD, Dickson CA, Patel DR. Acne in the first three decades of life: An update of a disorder with profound implications for all decades of life. *Dis Mon.* 2021;67(4):101103.
2. Williams HC, Dellavalle RP, Garner S. Acne vulgaris. *Lancet.* 2012;379(9813):361-72.
3. Nast A, Bettoli V, Bukvic Mokos Z, Degitz K, Dressler C, Finlay AY, et al. European Evidence-based (S3) Guideline for the Treatment of Acne, Update 2016, Long version. Available at: https://www.edf.one/dam/jcr:549b31dd-90dc-4122-b73a-baa73523e765/Acne_2016_GL.pdf Last accessed: 6th June 2022.
4. Bhate K, Williams HC. Epidemiology of acne vulgaris. *Br J Dermatol.* 2013;168(3):474-85.
5. Stathakis V, Kilkenny M, Marks R. Descriptive epidemiology of acne vulgaris in the community. *Australas J Dermatol.* 1997;38(3):115-23.
6. Ghodsi SZ, Orawa H, Zouboulis CC. Prevalence, severity, and severity risk factors of acne in high school pupils: a community-based study. *J Invest Dermatol.* 2009;129(9):2136-41.
7. Mancini AJ, Baldwin HE, Eichenfield LF, Friedlander SF, Yan AC. Acne life cycle: the spectrum of pediatric disease. *Semin Cutan Med Surg.* 2011;30(3 Suppl):S2-5.
8. Collier CN, Harper JC, Cafardi JA, Cantrell WC, Wang W, Foster KW, et al. The prevalence of acne in adults 20 years and older. *J Am Acad Dermatol.* 2008;58(1):56-9.
9. Silverberg JI, Silverberg NB. Epidemiology and extracutaneous comorbidities of severe acne in adolescence: a U.S. population-based study. *Br J Dermatol.* 2014;170(5):1136-42.
10. Thiboutot D, Gollnick H, Bettoli V, Dréno B, Kang S, Leyden JJ, et al. New insights into the management of acne: an update from the Global Alliance to Improve Outcomes in Acne group. *J Am Acad Dermatol.* 2009;60(5 Suppl):S1-50.

11. Akamatsu H, Zouboulis CC, Orfanos CE. Control of human sebocyte proliferation in vitro by testosterone and 5-alpha-dihydrotestosterone is dependent on the localization of the sebaceous glands. *J Invest Dermatol.* 1992;99(4):509-11.
12. Deplewski D, Rosenfield RL. Role of hormones in pilosebaceous unit development. *Endocr Rev.* 2000;21(4):363-92.
13. Schneider MR, Paus R. Sebocytes, multifaceted epithelial cells: lipid production and holocrine secretion. *Int J Biochem Cell Biol.* 2010;42(2):181-5.
14. Cunliffe WJ, Holland DB, Clark SM, Stables GI. Comedogenesis: some new aetiological, clinical and therapeutic strategies. *Br J Dermatol.* 2000;142(6):1084-91.
15. Beylot C, Auffret N, Poli F, Claudel JP, Leccia MT, Del Giudice P, et al. *Propionibacterium acnes*: an update on its role in the pathogenesis of acne. *J Eur Acad Dermatol Venereol.* 2014;28(3):271-8.
16. Valins W, Amini S, Berman B. The Expression of Toll-like Receptors in Dermatological Diseases and the Therapeutic Effect of Current and Newer Topical Toll-like Receptor Modulators. *J Clin Aesthet Dermatol.* 2010;3(9):20-9.
17. Kim J, Ochoa MT, Krutzik SR, Takeuchi O, Uematsu S, Legaspi AJ, et al. Activation of toll-like receptor 2 in acne triggers inflammatory cytokine responses. *J Immunol.* 2002;169(3):1535-41.
18. Pawin H, Beylot C, Chivot M, Faure M, Poli F, Revuz J, et al. Physiopathology of acne vulgaris: recent data, new understanding of the treatments. *Eur J Dermatol.* 2004;14(1):4-12.
19. Jugeau S, Tenaud I, Knol AC, Jarrousse V, Quereux G, Khammari A, et al. Induction of toll-like receptors by *Propionibacterium acnes*. *Br J Dermatol.* 2005;153(6):1105-13.
20. Navarini AA, Simpson MA, Weale M, Knight J, Carlavan I, Reiniche P, et al. Genome-wide association study identifies three novel susceptibility loci for severe Acne vulgaris. *Nat Commun.* 2014;5:4020.
21. He L, Wu WJ, Yang JK, Cheng H, Zuo XB, Lai W, et al. Two new susceptibility loci 1q24.2 and 11p11.2 confer risk to severe acne. *Nat Commun.* 2014;5:2870.
22. Zhang M, Qureshi AA, Hunter DJ, Han J. A genome-wide association study of severe teenage acne in European Americans. *Hum Genet.* 2014;133(3):259-64.

23. Herane MI, Ando I. Acne in infancy and acne genetics. *Dermatology*. 2003;206(1):24-8.
24. Cunliffe WJ, Holland DB, Jeremy A. Comedone formation: etiology, clinical presentation, and treatment. *Clin Dermatol*. 2004;22(5):367-74.
25. Fitz-Gibbon S, Tomida S, Chiu BH, Nguyen L, Du C, Liu M, et al. Propionibacterium acnes strain populations in the human skin microbiome associated with acne. *J Invest Dermatol*. 2013;133(9):2152-60.
26. Barnard E, Shi B, Kang D, Craft N, Li H. The balance of metagenomic elements shapes the skin microbiome in acne and health. *Scientific Reports*. 2016;6(1):39491.
27. Dréno B, Pécastaings S, Corvec S, Veraldi S, Khammari A, Roques C. Cutibacterium acnes (Propionibacterium acnes) and acne vulgaris: a brief look at the latest updates. *J Eur Acad Dermatol Venereol*. 2018;32 Suppl 2:5-14.
28. Isard O, Knol AC, Ariès MF, Nguyen JM, Khammari A, Castex-Rizzi N, et al. Propionibacterium acnes activates the IGF-1/IGF-1R system in the epidermis and induces keratinocyte proliferation. *J Invest Dermatol*. 2011;131(1):59-66.
29. Burkhart CG, Burkhart CN. Expanding the microcomedone theory and acne therapeutics: Propionibacterium acnes biofilm produces biological glue that holds corneocytes together to form plug. *J Am Acad Dermatol*. 2007;57(4):722-4.
30. Coenye T, Peeters E, Nelis HJ. Biofilm formation by Propionibacterium acnes is associated with increased resistance to antimicrobial agents and increased production of putative virulence factors. *Res Microbiol*. 2007;158(4):386-92.
31. Dessinioti C, Katsambas A. Propionibacterium acnes and antimicrobial resistance in acne. *Clin Dermatol*. 2017;35(2):163-7.
32. Dréno B. Bacteriological resistance in acne: A call to action. *Eur J Dermatol*. 2016;26(2):127-32.
33. Kircik LH. Androgens and acne: perspectives on clascoterone, the first topical androgen receptor antagonist. *Expert Opin Pharmacother*. 2021;22(13):1801-6.
34. David J. Goldberg ALB. Acne and Rosacea: Epidemiology, Diagnosis and Treatment. London WC1E 7DP, UK: Manson Publishing Ltd; 2012.

35. Lee WJ, Jung HD, Chi SG, Kim BS, Lee SJ, Kim DW, et al. Effect of dihydrotestosterone on the upregulation of inflammatory cytokines in cultured sebocytes. *Arch Dermatol Res.* 2010;302(6):429-33.
36. Choudhry R, Hodgins MB, Van der Kwast TH, Brinkmann AO, Boersma WJ. Localization of androgen receptors in human skin by immunohistochemistry: implications for the hormonal regulation of hair growth, sebaceous glands and sweat glands. *J Endocrinol.* 1992;133(3):467-75.
37. Till AE, Goulden V, Cunliffe WJ, Holland KT. The cutaneous microflora of adolescent, persistent and late-onset acne patients does not differ. *Br J Dermatol.* 2000;142(5):885-92.
38. Kurokawa I, Danby FW, Ju Q, Wang X, Xiang LF, Xia L, et al. New developments in our understanding of acne pathogenesis and treatment. *Exp Dermatol.* 2009;18(10):821-32.
39. Pivarcsi A, Bodai L, Réthi B, Kenderessy-Szabó A, Koreck A, Széll M, et al. Expression and function of Toll-like receptors 2 and 4 in human keratinocytes. *Int Immunol.* 2003;15(6):721-30.
40. Oeff MK, Seltmann H, Hiroi N, Nastos A, Makrantonaki E, Bornstein SR, et al. Differential regulation of Toll-like receptor and CD14 pathways by retinoids and corticosteroids in human sebocytes. *Dermatology.* 2006;213(3):266.
41. Papakonstantinou E, Aletras AJ, Glass E, Tsogas P, Dionyssopoulos A, Adjaye J, et al. Matrix metalloproteinases of epithelial origin in facial sebum of patients with acne and their regulation by isotretinoin. *J Invest Dermatol.* 2005;125(4):673-84.
42. Dessinioti C, Katsambas AD. The role of *Propionibacterium acnes* in acne pathogenesis: facts and controversies. *Clin Dermatol.* 2010;28(1):2-7.
43. Picardo M, Ottaviani M, Camera E, Mastrofrancesco A. Sebaceous gland lipids. *Dermato-Endocrinology.* 2009;1(2):68-71.
44. Letawe C, Boone M, Piérard GE. Digital image analysis of the effect of topically applied linoleic acid on acne microcomedones. *Clin Exp Dermatol.* 1998;23(2):56-8.
45. Ottaviani M, Alestas T, Flori E, Mastrofrancesco A, Zouboulis CC, Picardo M. Peroxidated squalene induces the production of inflammatory mediators in HaCaT keratinocytes: a possible role in acne vulgaris. *J Invest Dermatol.* 2006;126(11):2430-7.

46. Zouboulis CC, Angres S, Seltmann H. Regulation of stearoyl-coenzyme A desaturase and fatty acid delta-6 desaturase-2 expression by linoleic acid and arachidonic acid in human sebocytes leads to enhancement of proinflammatory activity but does not affect lipogenesis. *Br J Dermatol*. 2011;165(2):269-76.
47. Zouboulis CC, Schagen S, Alestas T. The sebocyte culture: a model to study the pathophysiology of the sebaceous gland in seborrhea, seborrhoea and acne. *Arch Dermatol Res*. 2008;300(8):397-413.
48. Trivedi NR, Gilliland KL, Zhao W, Liu W, Thiboutot DM. Gene array expression profiling in acne lesions reveals marked upregulation of genes involved in inflammation and matrix remodeling. *J Invest Dermatol*. 2006;126(5):1071-9.
49. Balić A, Vlašić D, Žužul K, Marinović B, Bukvić Mokos Z. Omega-3 Versus Omega-6 Polyunsaturated Fatty Acids in the Prevention and Treatment of Inflammatory Skin Diseases. *Int J Mol Sci*. 2020;21(3).
50. Alestas T, Ganceviciene R, Fimmel S, Müller-Decker K, Zouboulis CC. Enzymes involved in the biosynthesis of leukotriene B4 and prostaglandin E2 are active in sebaceous glands. *J Mol Med (Berl)*. 2006;84(1):75-87.
51. Zouboulis CC. Propionibacterium acnes and sebaceous lipogenesis: a love-hate relationship? *J Invest Dermatol*. 2009;129(9):2093-6.
52. Zouboulis CC, Katsambas AD, Klingman AM. Pathogenesis and Treatment of Acne and Rosacea. Zouboulis CC, Katsambas AD, Klingman AM, editors: Springer-Verlag Berlin Heidelberg 2014; 2014.
53. Basta-Juzbašić A. Bolest lojnica; akne i srodne bolesti. In Basta-Juzbašić A, ed. *Dermatovenerologija*. Zagreb: Medicinska naklada; 2014, p. 455-94.
54. Dessinioti C, Antoniou C, Katsambas A. Acneiform eruptions. *Clin Dermatol*. 2014;32(1):24-34.
55. Dall'oglio F, Puglisi DF, Nasca MR, Micali G. Acne fulminans. *G Ital Dermatol Venereol*. 2020;155(6):711-8.
56. Zouboulis CC, Bettoli V. Management of severe acne. *Br J Dermatol*. 2015;172 Suppl 1:27-36.

57. Zaenglein AL, Pathy AL, Schlosser BJ, Alikhan A, Baldwin HE, Berson DS, et al. Guidelines of care for the management of acne vulgaris. *J Am Acad Dermatol*. 2016;74(5):945-73.e33.
58. Rademaker M. Isotretinoin: dose, duration and relapse. What does 30 years of usage tell us? *Australas J Dermatol*. 2013;54(3):157-62.
59. On SC, Zeichner J. Isotretinoin updates. *Dermatol Ther*. 2013;26(5):377-89.
60. Rademaker M. Adverse effects of isotretinoin: A retrospective review of 1743 patients started on isotretinoin. *Australas J Dermatol*. 2010;51(4):248-53.
61. Kaymak Y, Ilter N. The effectiveness of intermittent isotretinoin treatment in mild or moderate acne. *J Eur Acad Dermatol Venereol*. 2006;20(10):1256-60.
62. Akman A, Durusoy C, Senturk M, Koc CK, Soy Turk D, Alpsoy E. Treatment of acne with intermittent and conventional isotretinoin: a randomized, controlled multicenter study. *Arch Dermatol Res*. 2007;299(10):467-73.
63. Plewig G, Dressel H, Pflieger M, Michelsen S, Kligman AM. Low dose isotretinoin combined with tretinoin is effective to correct abnormalities of acne. *J Dtsch Dermatol Ges*. 2004;2(1):31-45.
64. Colburn WA, Gibson DM, Wiens RE, Hanigan JJ. Food increases the bioavailability of isotretinoin. *J Clin Pharmacol*. 1983;23(11-12):534-9.
65. Webster GF, Leyden JJ, Gross JA. Comparative pharmacokinetic profiles of a novel isotretinoin formulation (isotretinoin-Lidose) and the innovator isotretinoin formulation: a randomized, 4-treatment, crossover study. *J Am Acad Dermatol*. 2013;69(5):762-7.
66. Ganceviciene R, Zouboulis CC. Isotretinoin: state of the art treatment for acne vulgaris. *J Dtsch Dermatol Ges*. 2010;8 Suppl 1:S47-59.
67. Ling TC, Parkin G, Islam J, Seukeran DC, Cunliffe WJ. What is the cumulative effect of long-term, low-dose isotretinoin on the development of DISH? *Br J Dermatol*. 2001;144(3):630-2.
68. Bremner JD, Shearer KD, McCaffery PJ. Retinoic acid and affective disorders: the evidence for an association. *J Clin Psychiatry*. 2012;73(1):37-50.

69. Huang YC, Cheng YC. Isotretinoin treatment for acne and risk of depression: A systematic review and meta-analysis. *J Am Acad Dermatol*. 2017;76(6):1068-76.e9.
70. Lee SY, Jamal MM, Nguyen ET, Bechtold ML, Nguyen DL. Does exposure to isotretinoin increase the risk for the development of inflammatory bowel disease? A meta-analysis. *Eur J Gastroenterol Hepatol*. 2016;28(2):210-6.
71. Strauss JS, Krowchuk DP, Leyden JJ, Lucky AW, Shalita AR, Siegfried EC, et al. Guidelines of care for acne vulgaris management. *J Am Acad Dermatol*. 2007;56(4):651-63.
72. Sieber MA, Hegel JK. Azelaic acid: Properties and mode of action. *Skin Pharmacol Physiol*. 2014;27 Suppl 1:9-17.
73. Zouboulis CC, Rabe T. [Hormonal antiandrogens in acne treatment]. *J Dtsch Dermatol Ges*. 2010;8 Suppl 1:S60-74.
74. Gollnick H, Albring M, Brill K. [The effectiveness of oral cyproterone acetate in combination with ethinylestradiol in acne tarda of the facial type]. *Ann Endocrinol (Paris)*. 1999;60(3):157-66.
75. Fritsch M, Orfanos CE, Zouboulis CC. Sebocytes are the key regulators of androgen homeostasis in human skin. *J Invest Dermatol*. 2001;116(5):793-800.
76. Seiffert K, Seltmann H, Fritsch M, Zouboulis CC. Inhibition of 5alpha-reductase activity in SZ95 sebocytes and HaCaT keratinocytes in vitro. *Horm Metab Res*. 2007;39(2):141-8.
77. Fox L, Csongradi C, Aucamp M, du Plessis J, Gerber M. Treatment Modalities for Acne. *Molecules*. 2016;21(8).
78. Raudrant D, Rabe T. Progestogens with antiandrogenic properties. *Drugs*. 2003;63(5):463-92.
79. Newman MD, Bowe WP, Heughebaert C, Shalita AR. Therapeutic considerations for severe nodular acne. *Am J Clin Dermatol*. 2011;12(1):7-14.
80. Hafsi W, Badri T. Acne Conglobata. *StatPearls*. Treasure Island (FL)2022.
81. Sand FL, Thomsen SF. Adalimumab for the treatment of refractory acne conglobata. *JAMA Dermatol*. 2013;149(11):1306-7.

82. Zaba R, Schwartz R, Jarmuda S, Czarnecka-Operacz M, Silny W. Acne fulminans: explosive systemic form of acne. *J Eur Acad Dermatol Venereol*. 2011;25(5):501-7.
83. Greywal T, Zaenglein AL, Baldwin HE, Bhatia N, Chernoff KA, Del Rosso JQ, et al. Evidence-based recommendations for the management of acne fulminans and its variants. *J Am Acad Dermatol*. 2017;77(1):109-17.
84. Karvonen SL, Räsänen L, Cunliffe WJ, Holland KT, Karvonen J, Reunala T. Delayed hypersensitivity to *Propionibacterium acnes* in patients with severe nodular acne and acne fulminans. *Dermatology*. 1994;189(4):344-9.
85. Blanc D, Zultak M, Wendling D, Lonchamp F. Eruptive pyogenic granulomas and acne fulminans in two siblings treated with isotretinoin. A possible common pathogenesis. *Dermatologica*. 1988;177(1):16-8.
86. Perkins W, Crockett KV, Hodgins MB, Mackie RM, Lackie JM. The effect of treatment with 13-cis-retinoic acid on the metabolic burst of peripheral blood neutrophils from patients with acne. *Br J Dermatol*. 1991;124(5):429-32.
87. Fyrand O, Fiskaadal HJ, Trygstad O. Acne in pubertal boys undergoing treatment with androgens. *Acta Derm Venereol*. 1992;72(2):148-9.
88. Traupe H, von Mühlendahl KE, Brämwig J, Happle R. Acne of the fulminans type following testosterone therapy in three excessively tall boys. *Arch Dermatol*. 1988;124(3):414-7.
89. Heydenreich G. Testosterone and anabolic steroids and acne fulminans. *Arch Dermatol*. 1989;125(4):571-2.
90. Wollina U, Gesina H, Koch A, Köstler E. Case reports: acne fulminans in Marfan syndrome. *J Drugs Dermatol*. 2005;4(4):501-5.
91. Williamson DM, Cunliffe WJ, Gatecliff M, Scott DG. Acute ulcerative acne conglobata (acne fulminans) with erythema nodosum. *Clin Exp Dermatol*. 1977;2(4):351-4.
92. Kellett JK, Beck MH, Chalmers RJ. Erythema nodosum and circulating immune complexes in acne fulminans after treatment with isotretinoin. *Br Med J (Clin Res Ed)*. 1985;290(6471):820.

93. Iqbal M, Kolodney MS. Acne fulminans with synovitis-acne-pustulosis-hyperostosis-osteitis (SAPHO) syndrome treated with infliximab. *J Am Acad Dermatol*. 2005;52(5 Suppl 1):S118-20.
94. Honma M, Murakami M, Iinuma S, Fujii M, Komatsu S, Sato K, et al. Acne fulminans following measles infection. *J Dermatol*. 2009;36(8):471-3.
95. Darley CR, Currey HL, Baker H. Acne fulminans with arthritis in identical twins treated with isotretinoin. *J R Soc Med*. 1984;77(4):328-30.
96. Gonzalez T, Gantes M, Bustabad S, Diaz-Flores L. Acne fulminans associated with arthritis in monozygotic twins. *J Rheumatol*. 1985;12(2):389-91.
97. Wong SS, Pritchard MH, Holt PJ. Familial acne fulminans. *Clin Exp Dermatol*. 1992;17(5):351-3.
98. Windom RE, Sanford JP, Ziff M. Acne conglobata and arthritis. *Arthritis Rheum*. 1961;4:632-5.
99. Mehrany K, Kist JM, Weenig RH, Witman PM. Acne fulminans. *Int J Dermatol*. 2005;44(2):132-3.
100. Nault P, Lassonde M, St-Antoine P. Acne fulminans with osteolytic lesions. *Arch Dermatol*. 1985;121(5):662-4.
101. Karvonen SL. Acne fulminans: report of clinical findings and treatment of twenty-four patients. *J Am Acad Dermatol*. 1993;28(4):572-9.
102. Chua SL, Angus JE, Ravenscroft J, Perkins W. Synovitis, acne, pustulosis, hyperostosis, osteitis (SAPHO) syndrome and acne fulminans: are they part of the same disease spectrum? *Clin Exp Dermatol*. 2009;34(7):e241-3.
103. Moll C, Hernández MV, Cañete JD, Gómez-Puerta JA, Soriano A, Collado A, et al. Ilium osteitis as the main manifestation of the SAPHO syndrome: response to infliximab therapy and review of the literature. *Semin Arthritis Rheum*. 2008;37(5):299-306.
104. Wakabayashi M, Fujimoto N, Uenishi T, Danno K, Tanaka T. A case of acne fulminans in a patient with ulcerative colitis successfully treated with prednisolone and diaminodiphenylsulfone: a literature review of acne fulminans, rosacea fulminans and neutrophilic dermatoses occurring in the setting of inflammatory bowel disease. *Dermatology*. 2011;222(3):231-5.

105. Tago O, Nagai Y, Matsushima Y, Ishikawa O. A case of acne fulminans successfully treated with cyclosporin a and prednisolone. *Acta Derm Venereol.* 2011;91(3):337-8.
106. Campione E, Mazzotta AM, Bianchi L, Chimenti S. Severe acne successfully treated with etanercept. *Acta Derm Venereol.* 2006;86(3):256-7.
107. Shirakawa M, Uramoto K, Harada FA. Treatment of acne conglobata with infliximab. *J Am Acad Dermatol.* 2006;55(2):344-6.
108. Friedlander SF. Effective treatment of acne fulminans-associated granulation tissue with the pulsed dye laser. *Pediatr Dermatol.* 1998;15(5):396-8.

9. Biography

I was born on December 21st, 1994 in Ljubljana, Slovenia. After graduating from vocational highschool and gaining the title of pharmaceutical technician, my interest for medicine deepened. Due to the desire to study abroad and study in English I enrolled to a program Medical studies in English at School of Medicine, University of Zagreb in Zagreb, Croatia to fulfill my lifelong wish of becoming a medical doctor. Throughout my years of studying at School of Medicine, my love and passion for medicine developed even further, finding a profound interest in the field of dermatology and venerology. My other field of interest in medicine is also in plastic and reconstructive surgery. In academic year 2019/2020 I was awarded Dean's commendation for a distinguished academic record as the best fourth year student in my generation. I speak English, Slovenian and Croatian fluently. I am very skillful in computer knowledge, MS office and modern technology. Other than my professional interests, my other interests are in the field of kinesiology, sports (tennis, badminton, swimming and fitness), nutrition, cooking, meditation, psychotherapy and skincare.