

# Acneiform eruptions

---

Parać, Ena

Master's thesis / Diplomski rad

2021

Degree Grantor / Ustanova koja je dodijelila akademski / stručni stupanj: **University of Zagreb, School of Medicine / Sveučilište u Zagrebu, Medicinski fakultet**

Permanent link / Trajna poveznica: <https://um.nsk.hr/um:nbn:hr:105:662849>

Rights / Prava: [In copyright](#)/[Zaštićeno autorskim pravom.](#)

Download date / Datum preuzimanja: **2024-07-23**



Repository / Repozitorij:

[Dr Med - University of Zagreb School of Medicine Digital Repository](#)



**UNIVERSITY OF ZAGREB  
SCHOOL OF MEDICINE**

**Ena Parać**

# **Acneiform eruptions**

**GRADUATE THESIS**



**Zagreb, 2022.**

This graduate thesis was made at the Department of Dermatology and Venerology, School of Medicine, University of Zagreb, under the supervision of Professor Zrinka Bukvić Mokos, MD, PhD, and was submitted for evaluation in the academic year 2021./2022.

## ABBREVIATIONS

<b>5-HT<sub>1A</sub></b>	5-Hydroxytryptamine (serotonin) receptor subtype 1A
<b>5-HT<sub>2A</sub></b>	5-Hydroxytryptamine (serotonin) receptor subtype 2A
<b>AAS</b>	Anabolic-androgenic steroids
<b>BT</b>	Brimonidine tartrate
<b>CsA</b>	Cyclosporine
<b>D<sub>2</sub></b>	Dopamine receptor subtype 2
<b>DHEA</b>	Dehydroepiandrosterone
<b>EGF</b>	Epidermal growth factor
<b>EGFR</b>	Epidermal growth factor receptor
<b>EGFRI</b>	Epidermal growth factor receptor inhibitors
<b>EPF</b>	Eosinophilic pustular folliculitis
<b>ETN</b>	Erythema toxicum neonatorum
<b>FACE</b>	Facial Afro-Caribbean childhood eruption
<b>FDA</b>	The United States Food and Drug Administration
<b>FFA</b>	Free fatty acids
<b>GA</b>	Granuloma annulare
<b>GBD</b>	Global Burden of Disease
<b>HIV</b>	Human immunodeficiency virus
<b>HS</b>	Hidradenitis suppurativa
<b>I-EPF</b>	Infancy-associated eosinophilic pustular folliculitis
<b>IFAG</b>	Idiopathic facial aseptic granuloma
<b>INH</b>	Isoniazid
<b>IS-EPF</b>	Immunosuppression-associated eosinophilic pustular folliculitis
<b>IV</b>	Intravenous
<b>KOH</b>	Potassium hydroxide
<b>LH</b>	Luteinizing hormone
<b>LNG-IUD</b>	Levonorgestrel-releasing intrauterine device

<b>MF</b>	Malassezia folliculitis
<b>NC</b>	Nevus comedonicus
<b>NCI</b>	National Cancer Institute
<b>NCP</b>	Neonatal cephalic pustulosis
<b>PD</b>	Perioral/ Periorificial dermatitis
<b>PFB</b>	Pseudofolliculitis barbae
<b>PGD</b>	Periorificial granulomatous dermatitis
<b>PLE</b>	Polymorphous light eruption
<b>PUVA</b>	Psoralen and UVA
<b>SCC</b>	Squamous cell carcinoma
<b>SSRI</b>	Selective serotonin reuptake inhibitors
<b>TB</b>	Tuberculosis
<b>TCA</b>	Tricyclic antidepressants
<b>TCDD</b>	Tetrachlorodibenzo-p-dioxin
<b>TNF</b>	Tumor necrosis factor
<b>TNPM</b>	Transient neonatal pustular melanosis
<b>UV</b>	Ultraviolet radiation
<b>UVA</b>	Ultraviolet A

## TABLE OF CONTENTS

1. SUMMARY .....	
2. SAŽETAK.....	
3. INTRODUCTION .....	1
4. ACNEIFORM ERUPTIONS IN THE PEDIATRIC POPULATION .....	2
4.1. <b>NEONATAL ACNEIFORM ERUPTIONS</b> .....	2
4.1.1. Neonatal cephalic pustulosis .....	2
4.1.2. Transient neonatal pustular melanosis .....	3
4.2. <b>NEVUS COMEDONICUS</b> .....	3
4.3. <b>PERIORIFICIAL GRANULOMATOUS DERMATITIS</b> .....	4
4.4. <b>PAPULAR GRANULOMA ANNULARE</b> .....	5
4.5. <b>PSEUDOACNE OF THE NASAL CREASE</b> .....	5
4.6. <b>CHILDHOOD PERIORAL DERMATITIS</b> .....	5
4.7. <b>CHILDHOOD ROSACEA</b> .....	6
4.8. <b>IDIOPATHIC FACIAL ASEPTIC GRANULOMA</b> .....	8
5. ACNEIFORM ERUPTIONS IN THE ADULT POPULATION .....	9
5.1. <b>ROSACEA</b> .....	9
5.2. <b>DEMODICOSIS</b> .....	11
5.3. <b>PERIORAL DERMATITIS</b> .....	12
5.4. <b>HIDRADENITIS SUPPURATIVA</b> .....	14
5.5. <b>PSEUDOFOLLICULITIS BARBAE</b> .....	15
5.6. <b>EOSINOPHILIC PUSTULAR FOLLICULITIS</b> .....	16
6. INFECTIOUS DISEASES RESEMBLING ACNE.....	17
6.1. <b>BACTERIAL FOLLICULITIS</b> .....	17
6.2. <b>GRAM-NEGATIVE FOLLICULITIS</b> .....	17
6.3. <b>MALASSEZIA FOLLICULITIS</b> .....	18
6.4. <b>HOT-TUB FOLLICULITIS</b> .....	19

6.5. SPOROTRICHOSIS .....	20
6.6. CUTANEOUS COCCIDIOIDOMYCOSIS.....	20
6.7. SECONDARY SYPHILIS .....	21
7. OCCUPATIONAL AND ENVIRONMENTAL ACNEIFORM ERUPTIONS .....	22
7.1. ACNE AESTIVALIS.....	22
7.2. TROPICAL ACNE .....	22
7.3. ACNE MECHANICA.....	23
7.4. ACNE COSMETICA .....	23
7.5. RADIATION ACNE.....	24
7.6. CHLORACNE .....	24
7.7. OIL ACNE.....	25
7.8. COAL-TAR ACNE .....	25
8. DRUG-INDUCED ACNEIFORM ERUPTIONS .....	26
8.1. HORMONES.....	27
8.1.1. Anabolic steroids and androgens .....	27
8.1.2. Corticosteroids .....	28
8.1.3. Other hormones .....	28
8.2. NEUROPSYCHOTROPIC AGENTS .....	29
8.2.1. Lithium .....	29
8.2.2. Antiepileptics .....	29
8.2.3. Antipsychotics .....	30
8.2.4. Antidepressants .....	30
8.3. TARGETED THERAPIES.....	30
8.3.1. Epidermal Growth Factor Receptor Inhibitors .....	30
8.3.2. Inhibitors of Tumor Necrosis Factor .....	33
8.4. IMMUNOSUPPRESSIVE AGENTS .....	33
8.4.1. Cyclosporine .....	33
8.4.2. Sirolimus .....	33
8.4.3. Tacrolimus.....	34
8.5. HALOGENS.....	34
8.5.1. Chlorine.....	34
8.5.2. Iodine .....	35
8.5.3. Bromine.....	36
8.6. VITAMINS B6 / B12.....	36
8.7. ANTITUBERCULOUS DRUGS.....	37

8.7.1. Rifampin (Rifampicin).....	37
8.7.2. Isoniazid.....	37
8.7.3. Ethionamide.....	37
<b>8.8. MISCELLANEOUS DRUGS.....</b>	<b>38</b>
8.8.1. Dantrolene.....	38
9. CONCLUSION.....	39
10. ACKNOWLEDGEMENTS.....	40
11. REFERENCES.....	41
12. BIOGRAPHY.....	51



## 1. SUMMARY

### Acneiform eruptions

Ena Parać

'Acneiform eruptions' is an umbrella term that encompasses a number of skin disorders resembling acne vulgaris. Although both acne and acne-like dermatoses are frequently encountered in clinical practice, making a distinction might be challenging. As with acne, the follicular lesions of acneiform eruptions may present with papules, pustules, nodules, or cysts. However, clinical examination of acneiform eruptions fails to detect comedones, the absence of which serves as the key distinctive feature when identifying these lesions. Furthermore, acneiform eruptions can be separated from acne by their abrupt onset, occurrence in any age group, distributions beyond the seborrheic areas, and the monomorphic morphology of lesions. There is no sole mechanism that explains the development of acneiform eruptions; nevertheless, patients' age, occupation, habits, infections, cosmetics, medications, and various other factors may be implicated. The presenting lesions may be resistant to conventional acne therapy, and the treatment should be tailored according to the recognized offending agents. In the case of drug-induced acneiform eruptions, lesions usually resolve upon discontinuation of the culprit medication. This review article aims to present different entities of acneiform eruptions and provide insight into the differences between them and true acne. Acneiform eruptions in the pediatric and the adult population, infectious diseases resembling acne, occupational and environmental acneiform eruptions, and drug-induced acneiform eruptions are addressed in this paper. Knowledge about the epidemiology, pathophysiology, and clinical presentation of this group of dermatoses is fundamental for making an accurate diagnosis and providing comprehensive care.

**Keywords:** acne; acneiform eruptions; inflammatory reaction; drug eruption

## 2. SAŽETAK

### Akneiformne erupcije

Ena Parać

Izraz 'akneiformne erupcije' obuhvaća niz kožnih poremećaja koji nalikuju vulgarnoj akni. Iako se akne i dermatoze slične akni često susreću u kliničkoj praksi, njihovo razlikovanje može biti zahtjevno. Kao i kod akne, folikularne lezije akneiformnih erupcija obuhvaćaju papule, pustule, noduli i ciste. Međutim, kliničkim pregledom se ne pronalaze komedoni, čiji je nedostatak ključna razlikovna značajka pri prepoznavanju ovih lezija. Nadalje, akneiformne erupcije mogu se razlikovati od akne zbog naglog početka, pojave u bilo kojoj dobnoj skupini, rasprostranjenosti i izvan seborejičnih područja, te monomorfnog izgleda lezija. Nastanak akneiformnih erupcija ne može se objasniti jednim, univerzalnim mehanizmom; ali dob pacijenata, zanimanje, navike, prisutnost infekcija, kozmetika, lijekovi i razni drugi čimbenici mogu igrati ulogu. Lezije mogu biti otporne na uobičajenu terapiju za akne, te bi liječenje trebalo biti prilagođeno prepoznatim uzročnicima. U slučaju akneiformnih erupcija uzrokovanih lijekovima, lezije se obično povlače nakon prestanka uzimanja lijeka koji ih je uzrokovao. Cilj ovog preglednog članka je predstaviti različite entitete akneiformnih erupcija i pružiti uvid u razlike između njih i prave akne. U ovom radu prikazane su akneiformne erupcije karakteristične za dječju i odraslu dob, zarazne bolesti nalik akni, profesionalne i ekološke akneiformne erupcije, te akneiformne erupcije uzrokovane lijekovima. Poznavanje epidemiologije, patofiziologije i kliničke prezentacije temeljno je za postavljanje točne dijagnoze i pružanje sveobuhvatne skrbi.

**Ključne riječi:** akne; akneiformne erupcije; upalna reakcija; medikamentozni egzantem

### 3. INTRODUCTION

Acne is the most prevalent dermatological condition worldwide. This chronic inflammatory disorder affects the pilosebaceous unit, most often confined to areas containing a higher concentration of sebaceous glands, such as the face, neck, upper chest, and back. Its etiopathogenesis is multifactorial; however, four etiopathogenetic factors have been recognized as crucial for acne development: – sebum overproduction, occlusion of the pilosebaceous duct, increased colonization of *Cutibacterium acnes* (*C. acnes*, formerly *Propionibacterium acnes*), and dermal inflammation. Other factors, such as diet and an individual's genetic profile, may play a role in its risk rate and severity. An interplay of different factors results in the formation of characteristic lesions of acne, including comedones, papules, pustules, nodules, cysts, and scars (1). Although a wide age range can get affected, the highest prevalence of acne is among adolescents, affecting approximately 85% (2). Acne can be found among males and females of all races and ethnicities. It involves both genders equally, but boys seem to be struck by more severe forms of acne (3). According to the Global Burden of Disease (GBD) Study 2010, acne affects 9.4% of the world population (4) and is the eighth most prevalent disease worldwide (5). Following its significant presence, other skin conditions that resemble acne may easily be mistaken for it. Such dermatoses that are unassociated with true *acne vulgaris* are termed "acneiform eruptions". This review article aims to present different entities of acneiform eruptions and provide insight into the differences between them and true acne.

## 4. ACNEIFORM ERUPTIONS IN THE PEDIATRIC POPULATION

Acne is one of the most often encountered skin conditions in dermatology. Although acne is commonly associated with adolescence, it can also be seen during the newborn, infantile, middle childhood, and prepubertal periods. While the disease typically heals on its own, therapy may be required in some situations of extensive scar formation. However, treatment of acne in these age ranges is a source of contention due to the potential side effects of medications. Pediatric acne can have a broad range of differential diagnoses and may be linked to underlying systemic diseases (6–8).

### 4.1. NEONATAL ACNEIFORM ERUPTIONS

Lesions appearing in the first four weeks of life can be challenging to diagnose, and the list of possible entities is extensive. Up to 20% of newborns are believed to experience acneiform eruptions (8). Pustular dermatoses ranging from infectious to non-infectious, such as neonatal cephalic pustulosis, neonatal acne, and transient neonatal pustular melanosis, can present in that period (9).

#### 4.1.1. Neonatal cephalic pustulosis

Neonatal cephalic pustulosis (NCP), sometimes referred to as neonatal acne, is a papulopustular eruption appearing at birth or in the following few weeks after birth. It mainly affects the facial areas of a newborn; cheeks, chin, forehead, and eyelids, but it may also localize to the scalp, neck, and truncal regions (6). Although the term NCP has been used interchangeably with neonatal acne (10), there is still an ongoing debate whether NCP and neonatal acne are the same conditions (6,11). Clinically, the absence of open and closed comedones may be a distinctive feature in NCP. In addition, there is evidence that *Malassezia* species play a role in the formation of NCP (12,13). This yeast has been demonstrated in the smears of pustules from afflicted newborns; however, it is of note that *Malassezia* has not been isolated in all NCP patients. Furthermore, neonates with positive cultures may not display NCP lesions at all (6). Since there is an incomplete correlation between *Malassezia* yeast species and NCP, other mechanisms are investigated. It is suggested that endocrine changes are implicated in neonatal acne formation. Although the exact pathophysiology is not

determined, two primary hypotheses exist. One would stem from the findings that maternal androgens can stimulate the sebaceous glands in newborns by transplacental transmission. The other hypothesis suggests that the activation of an enlarged zona reticularis in the neonatal adrenal gland leads to a rise in neonatal dehydroepiandrosterone (DHEA), stimulating the sebaceous glands (14). Besides the contribution from the androgen-producing zone, boys exhibit rising levels of luteinizing hormone (LH) and consequently testosterone, which may explain why boys are more likely to suffer from neonatal acne (8).

To date, it is challenging to separate NCP from neonatal acne completely, as the association between these two entities is uncertain. Further studies are required to characterize their features precisely (14).

Treatment of NCP or neonatal acne treatment is usually not required. The clinical presentation is mild, and the lesions usually heal within a few weeks (8). In some cases, topical antifungals such as ketoconazole can be prescribed to reduce *Malassezia* colonization (15).

#### 4.1.2. Transient neonatal pustular melanosis

Transient neonatal pustular melanosis (TNPM) is another pustular condition in newborns. This idiopathic eruption is more commonly seen in African Americans. In affected neonates, TNPM is always present at birth with tiny pustules appearing on a non-erythematous base. The lesions commonly localize to the chin, forehead, neck, and trunk, but other areas may also be involved. The pustules eventually rupture and form hyperpigmented macules with a collarette of scale.

It has been proposed that TNPM is a variant of erythema toxicum neonatorum (ETN). Treatment is usually not warranted, as spontaneous healing occurs without any remaining pigmentation (9).

## 4.2. NEVUS COMEDONICUS

Nevus comedonicus (NC) is an organoid epidermal nevus that forms along the Blaschko lines due to cutaneous mosaicism. It is also known as nevus acneiformis unilateralis. NC is a relatively uncommon developmental anomaly, and it is most commonly diagnosed at birth. It is distinguished by the presence of comedones of

varying sizes, which may be linked with cutaneous atrophy and scarring and are distributed in the same pattern as the Blaschko lines. The majority of NC cases are unilateral. Although it can affect any part of the body, NC primarily affects the head and neck region. NC should be distinguished from segmental acne. This acne type is particular because it forms in segmental patterns usually exclusively seen in cutaneous mosaicism (16).

### **4.3. PERIORIFICIAL GRANULOMATOUS DERMATITIS**

Periorifacial granulomatous dermatitis (PGD) is synonymous with Gianotti-type perioral dermatitis, facial Afro-Caribbean childhood eruption (FACE), and childhood granulomatous periorifacial dermatitis. This condition is quite rare, and its etiology is unknown. Many assume that PGD is a less frequent and a granulomatous variation of perioral/periorifacial dermatitis (PD), and that PD and PGD have common etiologic causes. PGD is characterized by isolated 1–3 mm asymptomatic monomorphous dome-shaped papules ranging in hue from yellow-brown to flesh-colored to pink-red. PGD invariably affects the face, with lesions primarily centered in the perioral, perinasal, and periorbital regions. PGD is separated from other illnesses by encompassing the lip's vermillion border, which aids in distinguishing it from PD (17). In addition, PGD is distinct from acne because of its perioral placement of lesions, monomorphous papules, lack of pustules or comedones, the self-limiting nature of the disease, and its distinctive histology. On histologic examination of PGD, non-caseating granulomatous infiltrates are situated around the hair follicles. This condition usually has a fairly benign course and resolves spontaneously within a few months or years. It has never been linked to systemic involvement. Treatment is often not indicated. Oral and topical antibiotics and topical calcineurin inhibitors may speed up the resolution process; however, the adverse effects of these medications need to be weighed against the benefits (16).

#### **4.4. PAPULAR GRANULOMA ANNULARE**

Granuloma annulare (GA) is a prevalent cutaneous condition that often manifests as annular plaques comprised of intradermal papules. The type that is most often encountered is the localized type of GA, and most often, it is characterized by a ringed lesion (18). Nevertheless, the less frequent papular presentation of GA is not ringed and hence may resemble an acneiform eruption. However, acne can be ruled out due to the absence of comedones and pustules, no epidermal changes, different affected sites, and a monomorphous pattern of GA lesions as opposed to acne (19). GA can develop at all ages; however, it is most typically identified in children and young adults. Females are twice as likely as males to be impacted. The lesions are most commonly observed on the extremities. Although the etiology is uncertain, GA has been associated with viral infections, trauma, malignancies, tuberculin skin test, solar radiation, and insect bites. In most cases, the eruption is asymptomatic and resolves on its own. Due to the chronic relapsing nature of the disease, intralesional injections of triamcinolone or topical steroids may be utilized (18).

#### **4.5. PSEUDOACNE OF THE NASAL CREASE**

The nasal crease appears as a transverse line in the lower third of the nose, and it demarcates the place where the alar cartilage and the triangular cartilage connect. The term 'pseudoacne of the nasal crease' has been recently coined for a newly characterized entity that resembles acne vulgaris but differs in pathophysiology and clinical course. The disorder presents in a chronic fashion with erythematous papules and milia that develop along the nasal crease. These acneiform eruptions occur in prepubertal patients and, therefore, do not seem to be hormonally sensitive. Topical anti-inflammatory drugs may be attempted; however, excision is the treatment of choice for long-standing papules (20).

#### **4.6. CHILDHOOD PERIORAL DERMATITIS**

Perioral dermatitis (PD) can occur in both children and adults. It may appear as an adverse effect of topical or inhaled corticosteroids, or it may be idiopathic. Additionally,

a history of atopy seems to predispose to PD development due to an impaired skin barrier function. The mechanism through which corticosteroids induce skin changes is by modifying the epidermal structure and increasing transepidermal water loss. That manifests clinically as erythema, telangiectasia, dryness, and scaling. PD features multiple small papules and vesicles on an erythematous background in the perioral area, with a distinctive peri-vermillion sparing. Some minor scaling is possible. Involvement of other facial regions, such as the periocular and the perinasal regions, is prevalent in youngsters. When corticosteroids are abruptly stopped, PD flares up with intense erythema, itching, burning, and stinging. Pediatric perioral dermatitis is treated in the same way as in adults, with oral antibiotics (excluding tetracyclines under the age of eight), topical metronidazole, or azelaic acid (16).

#### **4.7. CHILDHOOD ROSACEA**

Although rosacea is a highly prevalent condition in adulthood, it is rarely reported in the pediatric population. Childhood rosacea poses a diagnostic challenge since it needs to be distinguished from various papulopustular disorders, and there is a lack of diagnostic criteria for that age group. It is believed that this condition is underrecognized. As opposed to adult rosacea, children do not exhibit the phymatous form of the disease (21). Another distinctive feature of childhood rosacea is eye involvement, which may be the sole finding. Ocular symptoms may present with blepharitis, conjunctival hyperemia, keratitis, and, rarely, corneal ulcerations. It should be kept in mind that even if no external evidence of rosacea is evident, that still does not exclude the disease. The skin changes may be subtle in children, and ocular findings may precede facial erythema, telangiectasias, flushing, and papulopustules typical of the disease. Other conditions that present similarly are acne, PGD, PD, sarcoidosis, and demodicosis. Table 1 compares acne and the before-mentioned acneiform eruptions.



**Table 1.** Comparison of certain acneiform eruptions with acne vulgaris.

Condition	Common feature	Distinguishing feature
<b>Rosacea</b>	Common and chronic inflammatory disorder, presents with inflammatory papules and pustules that affect the face	No comedone formation, centofacial involvement, presence of ocular symptoms, episodic occurrence, flushing, telangiectasias, triggers cause flare-ups
<b>Periorificial granulomatous dermatitis</b>	Erythematous or flesh-colored papular eruption that involves the face, can involve the vermilion border, no systemic involvement	Mainly affects African Americans, lesions concentrated around the mouth, nose, eyes, presence of monomorphic papules, absence of comedones and pustules, lesions may become confluent
<b>Periorificial dermatitis</b>	Common skin eruption, erythematous papules and pustules affect the face	No comedones present, no extrafacial eruptions, spares the vermilion border, spares the jawline, cheeks, forehead, itching or burning sensation often reported, most common in young women, may be triggered by steroid use
<b>Sarcoidosis</b>	Erythematous or flesh-colored papules, may affect the face and the neck	Multisystem involvement, presence of systemic symptoms, onset usually after puberty, more common in African Americans and Scandinavians, presence of monomorphic papules; may coalesce into annular lesions or plaques, absence of comedones and pustules, papules may be accompanied by other specific and non-specific lesions of cutaneous sarcoidosis
<b>Demodicosis</b>	Erythematous facial papules and pustules	Immunocompromised host, acaricidal therapies effective, sandpaper-like appearance, scaling, itching, <i>Demodex</i> infestation of eyelash hair follicles results in blepharitis, madarosis and ocular irritation

There are no FDA-approved therapies for rosacea in children. Treatment is usually similar to the one for adult rosacea; as mentioned above, tetracyclines are contraindicated under the age of eight (22).

#### **4.8. IDIOPATHIC FACIAL ASEPTIC GRANULOMA**

Idiopathic facial aseptic granuloma (IFAG) is a disorder that manifests with asymptomatic nodules situated on the cheeks or eyelids of young children. The nodules are mostly solitary and erythematous-violaceous (23). The pathogenesis of IFAG has yet to be elucidated, but it has been postulated that IFAG is a form of granulomatous childhood rosacea. It has been observed that more than 40% of patients have at least two clinical signs of rosacea, such as facial flushing, papulopustules, telangiectasias, chalazia, and conjunctivitis. Children with IFAG have a higher chance of developing rosacea and should undergo an annual ophthalmological examination to detect ocular rosacea early (22). On average, the nodules regress spontaneously over 11 months. The use of local or oral antibiotics is typically unsuccessful (23).

## 5. ACNEIFORM ERUPTIONS IN THE ADULT POPULATION

### 5.1. ROSACEA

Rosacea is a common, chronic, and relapsing inflammatory skin disorder. It mainly involves the convex surfaces of the central face, such as the nose, cheeks, chin, and centre of the forehead. It affects both genders; however, on average, women are more commonly affected, while a severe clinical presentation is more often found in men. In most cases, it develops after the age of 40. The majority of individuals suffering from rosacea are fair-skinned (24).

The pathophysiology has been extensively studied but has not been fully understood. According to recent studies, an individual's genetic profile, environmental factors, alterations in immune response, neurogenic inflammation, and vascular hyperreactivity all seem to play a role (Figure 1).

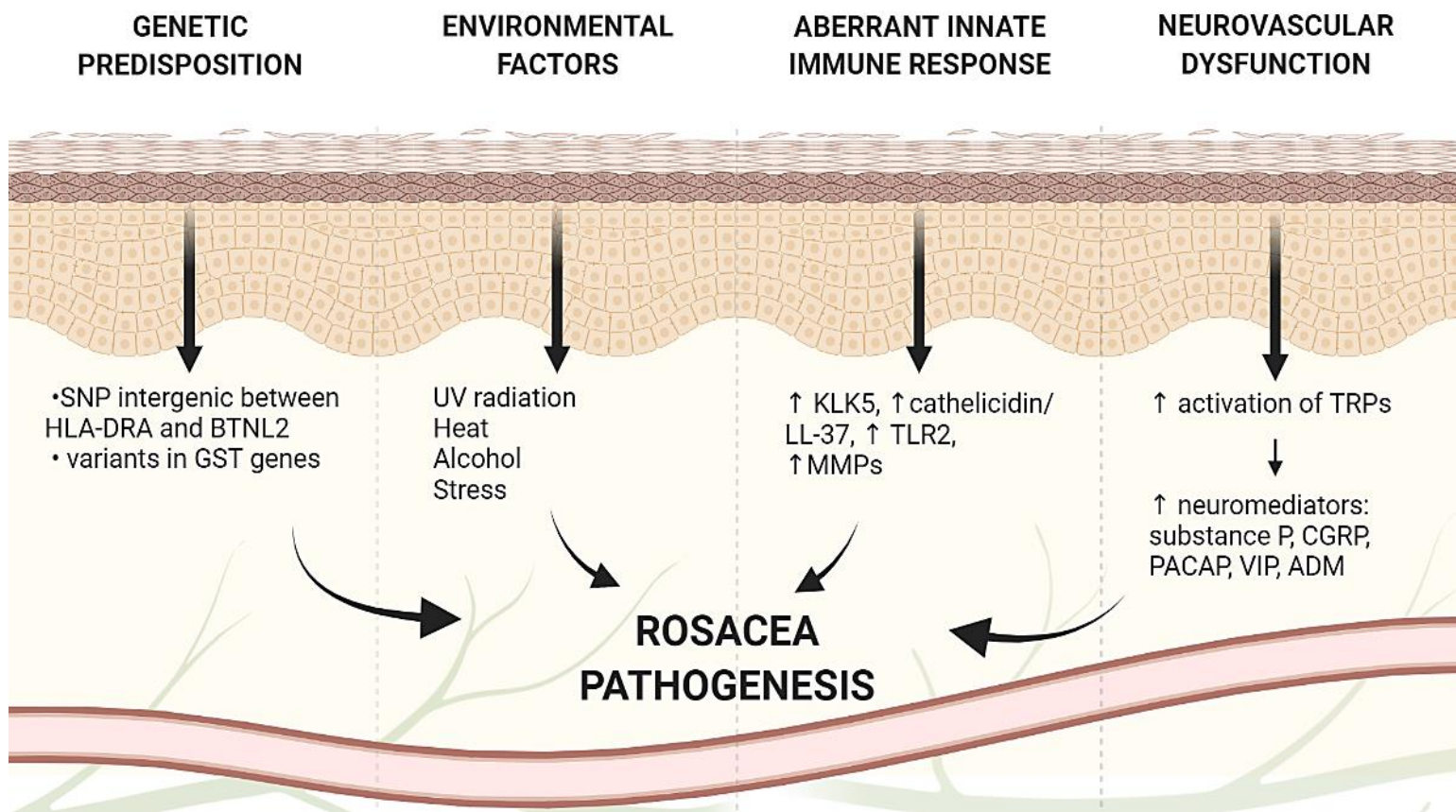
In addition, many studies imply an association between rosacea and the skin and gut microbiota. Both symbiotic organisms (*Demodex folliculorum* and *Staphylococcus epidermidis*) and potentially pathogenic bacteria (*Helicobacter pylori*, *Bacillus oleronius*, and *Chlamydia pneumoniae*) have been linked to rosacea. Nevertheless, the significance of such microorganisms in disease pathogenesis remains unknown. Due to a lack of evidence, it is unclear whether dysbiosis and altered microbiota are the precipitating factors of inflammation or secondary effects of alterations in the skin microenvironment (25,26).

Rosacea can manifest in tremendous differences in severity. However, the typical appearance is a central facial distribution of acneiform papules and pustules, with erythema and telangiectases. Based on the morphological features, rosacea is classified into four major types: erythematotelangiectatic, papulopustular, phymatous, and ocular (1).

Unlike acne vulgaris, rosacea has no comedones or seborrhea. It is symmetrical and has a more confined facial distribution than acne. Although both acne and rosacea are chronic skin conditions, acne is self-limiting, while rosacea is a relapsing disorder. The age range also differs for the two conditions. Besides the primary features of rosacea (such as flushing, persistent erythema, inflammatory papules and pustules, and telangiectasia), this condition may be accompanied by secondary features. These

features are typically unassociated with acne vulgaris and include stinging, burning, dryness, edema, and ocular manifestations (27).

To date, there is no curative treatment for rosacea. The suggested therapeutic techniques aim to control its signs and symptoms. That includes creating a skin care regimen that maintains the barrier function and skin hydration, photoprotection, topical and systemic medications, and laser and light-based modalities. Treatment options appear to be determined by various factors, including the type of lesions, medical history, and therapeutic preferences. Both topical and systemic medications are available for the treatment of rosacea. Among topical agents, brimonidine tartrate (BT) is routinely used for persistent erythema due to its agonistic activity at the  $\alpha_2$ -adrenergic receptors that results in vasoconstriction. Topical metronidazole and azelaic acid are effective in mild to moderate papulopustular rosacea; however, in more severe presentations, a systemic antibiotic from the tetracycline group is added to the regimen. In order to treat vascular and phymatous abnormalities that are not responsive to pharmacologic treatment, vascular lasers and light-based therapies are increasingly being used. It is critical to inform patients about the relapsing nature of rosacea and the possibility of exacerbations. Considering that triggers have the potential to exacerbate the condition, therapy should focus on recognizing and avoiding them as much as possible (1,16).



**Figure 1.** Factors involved in the pathogenesis of rosacea

Abbreviations: ADM, Adrenomedullin; BTNL2, Butyrophilin-like 2; CGRP, Calcitonin Gene-Related Peptide; GST, Glutathione-S-transferase; HLA-DRA, Human Leukocyte Antigen-DRA; KLK5, Kallikrein 5; LL-37, Cathelicidin Antimicrobial Peptide; MMPs, Matrix metalloproteinases; PACAP, Pituitary Adenylate cyclase-activating polypeptide; SNP, single nucleotide polymorphisms; TRPs, Transient Receptor Potential (TRP) cation channels; VIP, vasoactive intestinal peptide; ↑, increased; ↓, decreased

Created with Biorender.com

## 5.2. DEMODICOSIS

*Demodex* mites are obligate ectoparasites that reside in or near hair follicles. Humans are typically infested with two species belonging to the *Demodex* genus; *Demodex folliculorum* (*D. folliculorum*) and *Demodex brevis* (*D. brevis*).

*D. folliculorum* is generally located in the infundibulum of hair follicles, whereas *D. brevis* is found in sebaceous ducts, Meibomian glands, and the deeper segments of

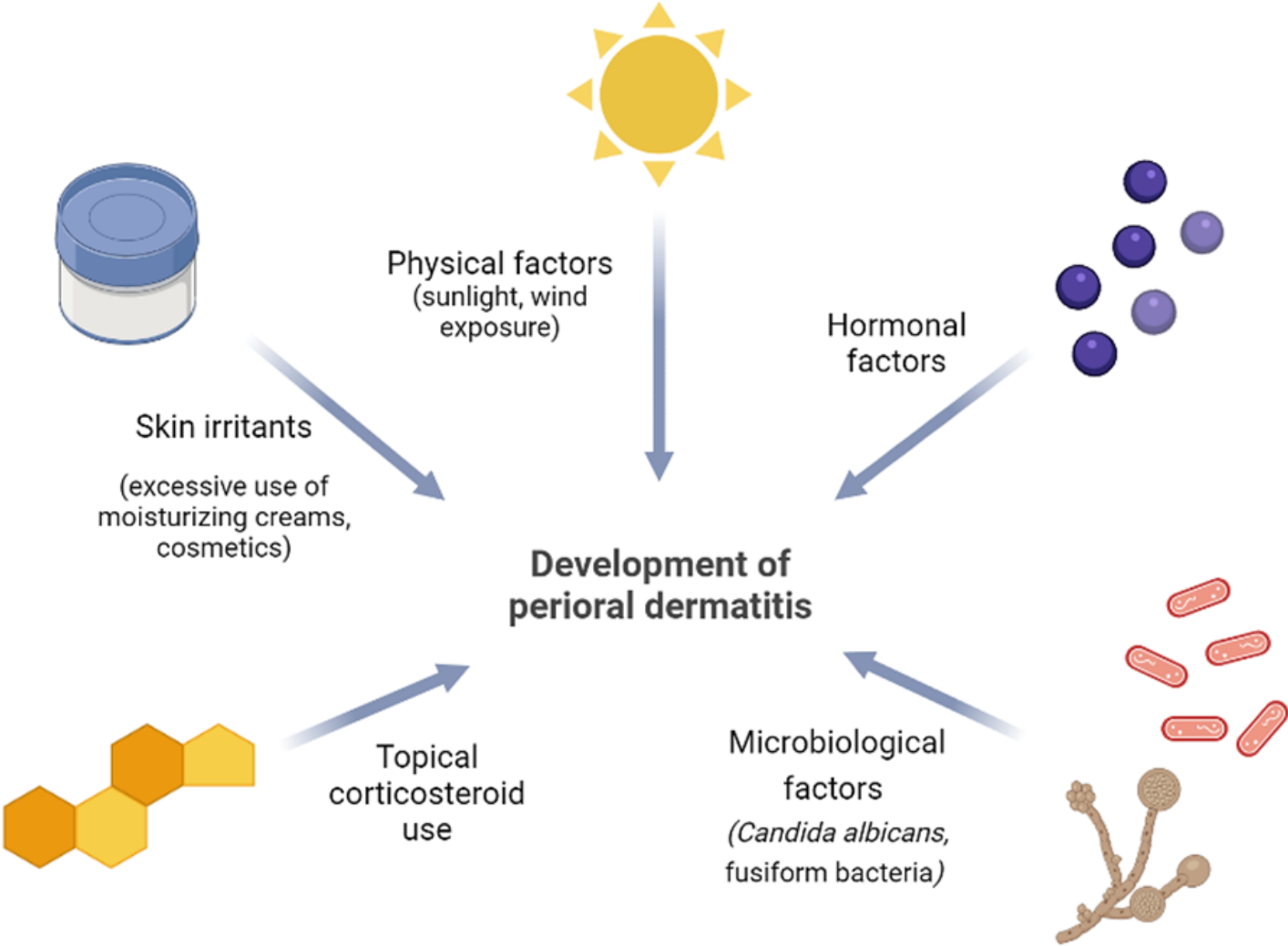
hair follicles. Their skin settlement generally does not produce any symptoms, but when in large numbers, they may become harmful (28,29). An increased mite density that causes human demodicosis can result from different conditions, such as immunodeficiencies, end-stage renal diseases, diabetes mellitus, and obesity. Moreover, increased numbers of these parasitic mites have been shown after a long-term application of topical corticosteroids. In an appropriate setting, *Demodex* mites can reproduce rapidly, resulting in the emergence of pathogenic conditions. Demodicosis can mimic other dermatoses, and is often underdiagnosed and misdiagnosed (30). Four clinical forms of demodicosis were identified: pityriasis folliculorum, rosacea type, acne type, and perioral type. The types are named after the dermatological conditions they resemble. The mite density is determined using standardized skin biopsy or direct microscopy using potassium hydroxide (KOH) (28). Treatment of demodicosis aims to lower the prevalence of *Demodex* in the skin and alleviate patients' symptoms. The medications used include topical permethrin, metronidazole, oral ivermectin, oral tetracycline, or oral metronidazole (16).

### **5.3. PERIORAL DERMATITIS**

Perioral dermatitis (PD), also referred to as periorificial dermatitis, is a common acneiform facial dermatosis. Individuals with fair complexion are most commonly afflicted, particularly women aged 15 to 45. The etiopathogenesis of this condition remains uncertain. However, a link between topical corticosteroids and PD has been extensively documented. Additionally, skin irritants, hormones, UV light, and microbiological agents are being studied due to their potential role in PD lesion formation (31) (Figure 2). The classic perioral dermatitis presents with many papules and pustules on a distinct erythematous background. The lesions measure 1 to 2 mm in diameter and are primarily situated in the perioral region (31).

Perinasal and periorbital areas may be affected, although the characteristic distribution is around the mouth. The distinctive sparing of the narrow zone surrounding the vermilion border is a clinical hallmark of PD. Patients do not report systemic symptoms, but symptoms like stinging, burning, and itching are frequently described (32). Treatment options are determined individually with regard to the severity of the condition and the willingness to comply with therapy. In the case of minor perioral

dermatitis, 'zero therapy' may be adequate. This treatment step focuses on the complete withdrawal of offending agents, including cosmetics and topical medications, most notably corticosteroids. It should be addressed that the initial period after steroid cessation may present with an exacerbation of lesions known as the 'rebound phenomenon'. In moderate forms of PD and when 'zero therapy' has been insufficient, topical agents are indicated. Medications administered are erythromycin, metronidazole, azelaic acid, and pimecrolimus. In severe forms of the disease, oral tetracyclines are the treatment of choice (31).



**Figure 2.** Proposed etiopathogenic factors in the development of perioral dermatitis  
Created with BioRender.com

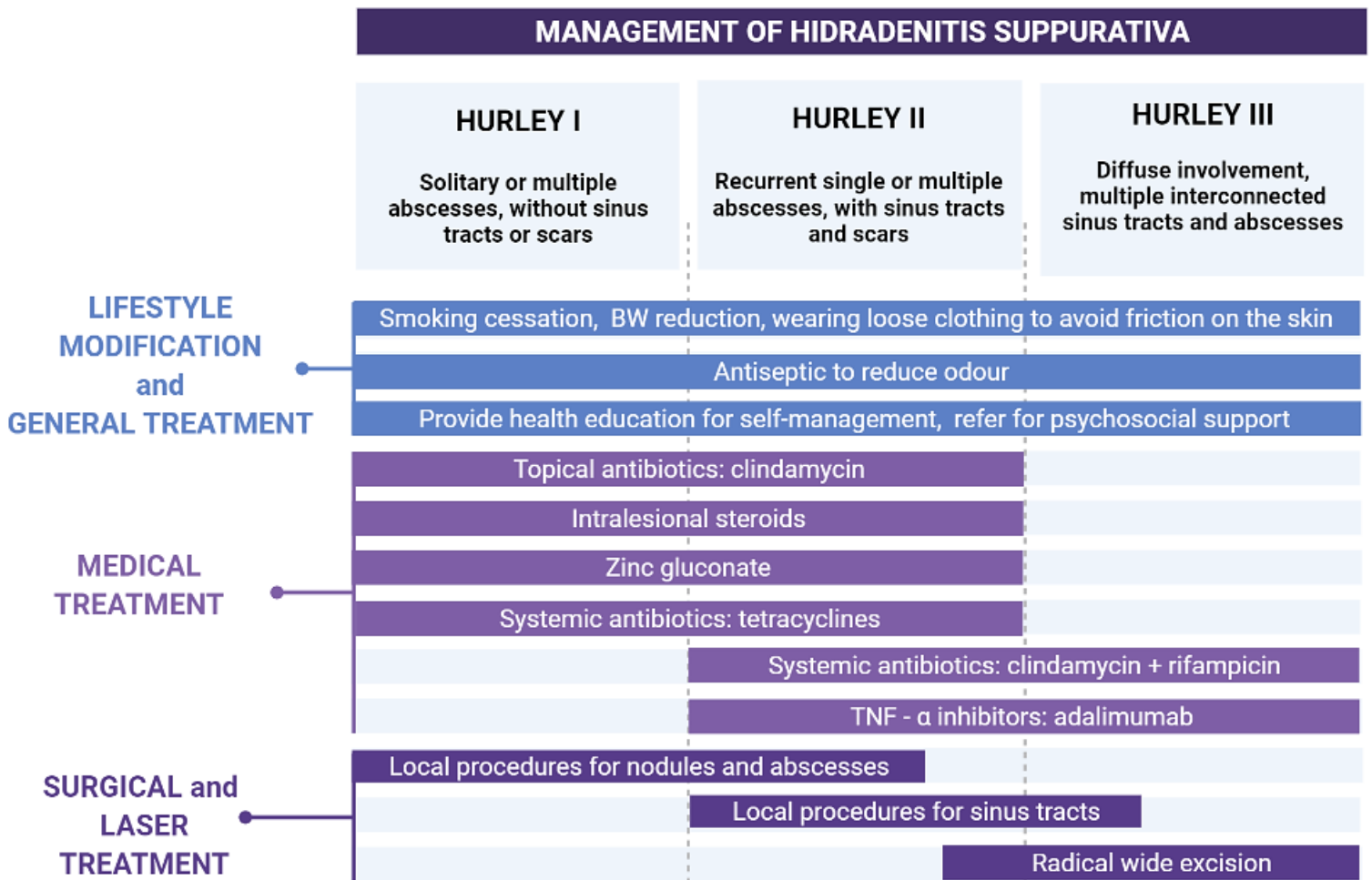
## 5.4. HIDRADENITIS SUPPURATIVA

Hidradenitis suppurativa (HS) is a chronic and debilitating inflammatory condition originating from the pilosebaceous unit and mainly involving intertriginous areas. It presents with deep and tender papules, pustules, nodules, or abscesses that may culminate in purulent discharge, recurrences, and scarring. The condition is also referred to as 'acne inversa', but contrary to acne, HS primarily affects the anogenital, axillary, and inframammary regions. HS typically arises in early adulthood, and has been linked to various genetic and environmental factors. The most significant risk factors for HS are obesity and smoking. HS may be associated with several comorbidities, including inflammatory bowel disease, autoinflammatory syndromes, metabolic syndrome, and other disorders of follicular occlusion (33,34).

Patients suffering from HS often report a poor quality of life and psychological issues. The psychosocial distress stems from the characteristic painful and odorous lesions, which are additionally situated in bothersome locations and may even lead to impaired mobility (35).

In order to grade the severity of the disease, the Hurley stage system was developed. Hurley I, II and III correspond to the mild, moderate, and severe forms of HS, respectively. This grading system aids in treatment-decision making (Figure 3) (36,37).





**Figure 3.** Treatment recommendations for hidradenitis suppurativa based on the Hurley staging system (according to Seyed Jafari SM et al. 2020)

Abbreviation: BW, body weight.

Created with BioRender.com

### 5.5. PSEUDOFOLLICULITIS BARBAE

Pseudofolliculitis barbae (PFB), also known as barber's itch or razor bumps, is a common inflammatory condition of the hair follicle. It predominantly occurs on the face due to shaving, but any other site where hair is plucked or shaved can present with PFB. It primarily afflicts men, especially those of African American descent, with tight and curly hair. The morphology of this type of hair may render it to curve back into the dermis and epidermis, forming intrafollicular or extrafollicular lesions, respectively. This

skin-piercing by ingrown hairs results in erythematous papules and pustules that may be painful or pruritic. The lesions follow the distribution of the shaved areas of the face and neck, although the moustache area is typically unaffected (38,39). The eruptions closely resemble acne vulgaris, but the crucial separating feature is the lack of comedones in PFB (40).

The prime management of this condition focuses on the discontinuation of all hair removal techniques to allow the inflammatory response to cease. Nonetheless, in the acute phase of PFB, patients might have significant pain and itching; hence, medical attention is required. Topical clindamycin and benzoyl peroxide have proven to be effective in decreasing inflammation. In addition, they also prevent the development of bacterial superinfection. Low potency topical steroids can also be utilized in PFB. In the case of advanced lesions, more potent topical steroids or triamcinolone injections should be used. (38,41).

## **5.6. EOSINOPHILIC PUSTULAR FOLLICULITIS**

Eosinophilic pustular folliculitis (EPF), also referred to as Ofuji disease, was first described as a clinical entity in Japan in 1970 (42). It is a non-infectious dermatosis characterized by papulopustules. The underlying pathophysiology is unknown, but the distinctive feature of EPF is a histological finding of eosinophilic infiltration around pilosebaceous units. Three disease variants have been described: classic EPF, immunosuppression-associated EPF (IS-EPF), and infancy-associated EPF (I-EPF). The classic variant was first described by Ofuji, and it is still primarily observed in Japanese patients. It occurs in seborrheic areas of healthy patients, with papules and pustules that coalesce into plaques and may be pruritic (43).

On the other hand, the majority of EPF eruptions are IS-EPF. HIV-infected patients are most commonly affected by this variant. A distinguishing characteristic of IS-EPF is persistent and extreme pruritus associated with lesions. Therefore, the presenting erythematous perifollicular papules and pustules are frequently severely excoriated (44). Since EPF is a recurrent disorder and the pathogenesis is unknown, there is no straightforward, successful treatment plan. Topical corticosteroids are recommended as the first-line therapy for all EPF variants. Other treatment strategies are adjusted according to the EPF variant in question (43,44).

## 6. INFECTIOUS DISEASES RESEMBLING ACNE

### 6.1. BACTERIAL FOLLICULITIS

Folliculitis is a frequent condition defined by an inflammatory reaction in the hair follicle, involving either the follicular opening or the perifollicular region. Its main causative agent is *Staphylococcus aureus*. The condition affects all age groups and both genders. Many predisposing factors enhance bacterial colonization on the skin, such as nasal carriage of *Staphylococcus aureus*, occlusion, and exposure to oils and chemicals. The tropical climate and follicular unit manipulation by shaving, waxing, or plucking serve as additional risk factors. The actual incidence of this disease is difficult to estimate since many afflicted patients do not seek medical help.

There can be two clinical types of bacterial folliculitis depending on the extent of hair follicle involvement. The superficial bacterial folliculitis, also known as Bockhart impetigo, is the most common form of folliculitis. It involves the superficial part of the follicle and presents with tiny folliculocentric pustules surrounded by erythema that progress to crusted papules over time. Pain or pruritus are commonly associated symptoms. On the contrary, deep folliculitis occurs when the entire follicle is involved. It manifests with furuncles, essentially skin abscesses, that start as painful inflammatory nodules and progress into necrotic ones in a few days. Furuncles are more often seen in young adult males, diabetic, and immunocompromised patients (45,46).

Treatment of bacterial folliculitis should focus on the most prevalent causal pathogen or the pathogen identified by bacterial culture (46).

### 6.2. GRAM-NEGATIVE FOLLICULITIS

Gram-negative folliculitis is a follicular pyoderma that develops as a complication of long-term oral antibiotic therapy for acne or rosacea. Most commonly, the antibiotics in question are tetracyclines (47). Normal skin microflora gets altered as oral antibiotics are used, and the quantity of the resident gram-positive microorganisms, such as *Staphylococcus aureus* and diphtheroid, decreases. On the other hand, the number of gram-negative rods, such as Enterobacteriaceae, increases in the mucous

membranes of the nose and the surrounding skin (48). Depending on the culprit organisms, that can result in either papulopustular lesions (type I) or deep cystic lesions (type II). The lesions are located in the infranasal region and extend to the chin and cheeks. Although gram-negative folliculitis is not frequently observed, it is likely underreported since it might be misinterpreted as an acne flare-up. Therefore, it should be suspected in acne patients who have an exacerbation of pustular or cystic lesions while on antibiotics and in individuals whose acne lesions have not improved significantly after 3 to 6 months of antibiotic treatment (49). The treatment of choice for gram-negative folliculitis is isotretinoin. It decreases sebum production and thus makes an unfavorable media for the survival of gram-negative organisms (47).

### 6.3. MALASSEZIA FOLLICULITIS

*Malassezia* folliculitis (MF) is an infectious folliculitis that typically presents with a follicular papulopustular eruption on the trunk and upper extremities of adolescents and young adults. It is caused by normal skin commensal organisms, yeasts that belong to the *Malassezia* species. They are lipophilic, so they thrive in the hair follicle's sebaceous-rich environment. That translates into 90% of people harboring the yeast in their *stratum corneum* and hair follicles (50). The *Malassezia* genus has been linked to other common skin illnesses such as seborrheic dermatitis and pityriasis versicolor (51). MF, previously referred to as *Pityrosporum* folliculitis, commonly occurs in the young population due to increased sebum production, in immunocompromised patients and in those who have taken broad-spectrum antibiotics due to changes in the skin flora. In such cases, there is an overgrowth of the commensal yeast *Malassezia furfur*, which becomes pathogenic. MF is an acneiform eruption frequently mistaken as acne vulgaris, so although it is prevalent, it is generally underdiagnosed. Unlike true acne, lesions seen in MF are pruritic and monomorphic, do not contain comedones, and respond to empiric antifungal treatment rather than antibiotics (Figure 4). The condition is diagnosed clinically but can be confirmed by microscopic identification using KOH or skin biopsy (52). Treatment with oral antifungal drugs remains the basis of therapy, and occasional topical therapy may be necessary to avoid recurrences (50,53).

	Acne vulgaris	Malassezia folliculitis
<b>Etiology</b>	Increased sebum production and follicular hyperkeratinization	Overgrowth of skin commensal <i>Malassezia furfur</i>
<b>Lesion Characteristics</b>	Polymorphic lesions with open and closed comedones, inflammatory papules and pustules, as well as nodules and cysts	Monomorphic papular and pustular lesions that lack comedones, frequently pruritic
<b>Localization</b>	Face, neck, upper chest, back	Back, chest, upper arms
<b>Treatment</b>	Benzoyl peroxide, topical retinoids, topical antibiotics, oral antibiotics, isotretinoin, hormonal therapy	Unresponsive to or aggravated by acne treatment Treated with oral antifungal medications

**Figure 4.** Differences between Acne vulgaris and Pityrosporum folliculitis

Created with BioRender.com

#### 6.4. HOT-TUB FOLLICULITIS

Hot-tub folliculitis, also termed *Pseudomonas* folliculitis, is an infection of the hair follicles caused by exposure to a gram-negative bacterium *Pseudomonas aeruginosa* (*P. aeruginosa*). It is a widespread organism found in soil and freshwater that enters the body through hair follicles or skin breaks. Water contamination with *P. aeruginosa* is more common if the water is hot, alkaline, or inadequately chlorinated. Once it reaches the skin, showering does not appear to protect against *Pseudomonas* folliculitis. Most lesions appear one to four days after exposure to contaminated hot tubs, swimming pools, or whirlpools. The typical rash is pruritic, starting with follicular

macules that develop into papules and pustules. The central area of the lesion contains a pinpoint vesicle. Because contaminated water is compressed in such locations, the rash is more common in intertriginous areas or under bathing suits. Other minor symptoms may be reported, such as fever, malaise, earache, and sore throat, but systemic infections are uncommon. Without treatment, the rash resolves spontaneously in 7-14 days (54,55).

## **6.5. SPOROTRICHOSIS**

Sporotrichosis is a skin infection brought on by the saprophytic fungus *Sporothrix schenckii* (*S. schenckii*) that resides on plants. Gardeners and agricultural workers are most often afflicted, usually due to slight trauma from contaminated material. Small wounds and abrasions in the skin allow *S. schenckii* to enter the body. In most cases, this produces a lymphocutaneous infection (56). However, a fixed cutaneous form is a possible presentation. When the eruption is papulonodular, it may be mistaken for acne. The mainstay of diagnosis is by culturing the tissue. The condition is treated with antifungals, such as itraconazole (57,58).

## **6.6. CUTANEOUS COCCIDIOIDOMYCOSIS**

Coccidioidomycosis is a fungal infection caused by two different soil-borne Coccidioides species, *Coccidioides immitis* and *Coccidioides posadaeii*. The disease can have a broad spectrum of clinical presentations, ranging from asymptomatic to severe and disseminated disease. The most common symptomatic manifestation is primary pulmonary coccidioidomycosis. Cutaneous involvement is one of the most prevalent extrapulmonary signs of coccidioidomycosis. It may occur in three different ways: as an exanthem associated with pulmonary coccidioidomycosis, as a secondary cutaneous infection in disseminated disease, or rarely, as a primary cutaneous infection due to direct inoculation of the fungus. Cutaneous coccidioidomycosis may be placed in the category of "great imitators" because of the enormous diversity of clinical manifestations (59). Skin lesions may include solitary or numerous papulonodules, pustules, abscesses, ulcers, or scars. In patients that live in the

endemic regions of Coccidioides, the aforementioned lesions should raise a suspicion of coccidioidomycosis. The gold standard method for diagnosis confirmation is histological identification or isolation of the fungus (60). Treatment is achieved with antifungals (59).

## **6.7. SECONDARY SYPHILIS**

Secondary syphilis is a systemic disease caused by the hematogenous spread of *Treponema pallidum*. It mostly appears from 2 to 8 weeks after the primary chancre. Among different cutaneous manifestations, acne-like eruptions may be evident as well. Nodules and crusted papulopustules have been described on the face, trunk, and extremities. Of note, other symptoms of a systemic infection, such as fever, fatigue, and lymphadenopathy, are frequent in people with secondary syphilis. Since syphilis has been termed "the great mimicker", any generalized skin eruption should be evaluated in the differential diagnosis for secondary syphilis. The diagnosis is reached by serologic tests and demonstration of spirochetes on darkfield microscopy. Penicillin is the treatment of choice (61,62).

## **7. OCCUPATIONAL AND ENVIRONMENTAL ACNEIFORM ERUPTIONS**

### **7.1. ACNE AESTIVALIS**

Acne aestivalis or Mallorca acne is a term used to describe a seasonal, monomorphous eruption that develops after sun exposure. The appellation 'Mallorca acne' stems from the 1970s (63), when such lesions were described in Scandinavians who had spent their vacations in the Mediterranean, mainly on the island of Mallorca. After a period of long, sun-scarce winter, exposure to intense ultraviolet (UV) radiation provoked an eruption. Subsequently, the roles of UV radiation, primarily ultraviolet A (UVA), and the genetic predisposition have been apparent in the pathogenesis of acne aestivalis. The acne erupts in the spring, peaks in summer, and abates in autumn. It is believed that Mallorca acne represents an acneiform (papular) variant of polymorphous light eruption (PLE). The lesions distribute along the chest, back, upper arms, and neck, but may spare the face. They are uniform, small keratotic nodules, whereas comedones are lacking. On histology, a high resemblance to steroid acne is demonstrated as lesions show focal follicular destruction with neutrophilic infiltrates (47). Presentations similar to Mallorca acne occur as a rare adverse effect of PUVA treatment (64). Mallorca acne is challenging to treat, and oral antibiotics do not assist. There is generally spontaneous improvement within several months. However, like in PLE, patients flare on reexposure to UV radiation. Topical retinoids and benzoyl peroxide may alleviate the condition (47).

### **7.2. TROPICAL ACNE**

In extremely hot and humid environments, severe acneiform folliculitis may form. Cases of tropical acne had been documented in military personnel serving in tropical areas during World War II. The skin changes resembled acne conglobata and were characterized by pustules, nodules, and large, painful cysts, often leading to abscesses and scarring. The regions mainly affected were the trunk and the buttocks (65). The pathogenesis of tropical acne is obscure, although secondary staphylococcal infections occur in almost every case. Relief can be attempted with systemic



antibiotics, but the only feasible solution is to evacuate the patient to a cooler climate (66).

### **7.3. ACNE MECHANICA**

As the term suggests, acne mechanica pertains to inflammatory papules and pustules that occur due to mechanical force. The repetitive friction acting upon the skin, together with heat, occlusion, and pressure, results in chronic irritation of the pilosebaceous unit, which forms acne. The clinical presentation of acne mechanica is similar to acne vulgaris; however, personal history and lifestyle factors can aid in their differentiation. The mechanical obstruction underlying acne mechanica is reported in various settings and activities. A high-yield example is in contact sports, such as American football. In fact, acne mechanica has been termed 'football acne' and 'sports-induced acne' since it appears in players wearing chinstraps, shoulder pads, and helmets (67,68). Likewise, this type of acne has been reported in equestrians wearing chinstraps (67) and in violin players who rub their skin against the chin rest, known as the fiddler's neck (69). Nevertheless, skin changes in regions that have been in contact with the equipment cannot always be attributed to 'sports-induced acne'. Allergic contact dermatitis needs to be taken into consideration as the differential diagnosis (67). Treatment for acne mechanica aims to identify and eliminate the provoking factors, which by itself may lead to spontaneous resolution. In instances where further treatment is needed, topical agents like benzoyl peroxide, topical retinoids and oral antibiotics may be used (67,68).

### **7.4. ACNE COSMETICA**

The term 'acne cosmetica' refers to eruptions of multiple comedones resulting from the application of cosmetic products. Although infrequent today, this type of acne used to be highly prevalent in the 1970s and 1980s, when comedogenic ingredients prevailed in cosmetics. The follicle-occluding nature of heavy products resulted in comedones that papules and pustules would sometimes accompany (70). Nowadays, constituents in skincare products are tested heavily, and most cosmetics are branded as 'non-comedogenic' (16). However, a subtype of acne cosmetica known as pomade acne (acne venenata) is still common. This entity develops in individuals using pomades or

scented ointments for the hair. Since pomades are commonly used on the scalp and the hair, they may affect the skin regions in contact with it, such as the temples and the forehead (70,71).

## **7.5. RADIATION ACNE**

Postradiation acneiform eruptions may appear in response to both ionizing and UV radiation. Skin areas irradiated with therapeutic ionizing radiation may show comedo-like papules between two weeks and six months after exposure. Although radiation-induced dermatitis is a substantially more frequent adverse effect of radiotherapy, acne-like lesions may develop in a small number of treated patients amid the resolution of dermatitis. Among those who present with radiation acne, most acquire it on the neck, face, or scalp. The mechanism of its formation remains to be fully understood. It is postulated that ionizing radiation changes sebum composition, lowers sebum production, and induces hyperproliferation in pilosebaceous ducts (72).

On the other hand, UV radiation damage may produce a condition known as Favre-Racouchot syndrome (FRS). It is believed that excessive UV exposure, smoking, and previous radiotherapy are the most significant risk factors for its development (73). The most typical presentation of FRS is malar and periorbital area involvement in middle-aged Caucasian men. It is a common dermatosis, affecting approximately 6% of adults older than 50. The disease is also known as 'nodular elastosis with cysts and comedones', which describes the clinical and histological appearance of the lesions. The most successful treatment approach is a combination of protective measures, medical therapy (topical or oral retinoids), and extraction (74).

## **7.6. CHLORACNE**

This uncommon but severe skin condition is caused by exposure to halogenated aromatic compounds. The condition will be discussed in more detail in the chapter on drug-induced acneiform eruptions under halogens (6.5.), namely chlorine (6.5.1.)

## **7.7. OIL ACNE**

In the group of occupational acne, oil acne is the most prevalent type of acne. It is caused by mineral oil found in substantial amounts in greases and solvents. Different professions, such as machine operators, automotive industry workers, and marine engineers, may be affected due to their contact with mineral oils that often soak their working clothes. This exposure mechanically obstructs the pilosebaceous glands and manifests with oil acne. The eruptions consisting of comedones and inflammatory components usually involve the dorsal surface of the hands, forearms, and thighs. This condition can be prevented by avoiding contact with mineral oils, changing clothing, and maintaining personal hygiene. Treatments with oral retinoids and tetracyclines have shown favorable results (75).

## **7.8. COAL-TAR ACNE**

Coal tar is a thick black liquid obtained as a byproduct of the coal distillation process. Although it serves its purpose in medical treatments, the industrial use of coal tar is much more significant. It is frequently used in the steel and aluminum industry, road construction, and roofing (76). Coal tar acne has been detected in almost a quarter of workers exposed to coal tar (77). Its possible entry routes are the gastrointestinal system, the respiratory system, and the skin. When coal tar fluid accumulates in the skin, together with keratin products, it leads to an obstruction of sebaceous glands. The resulting coal-tar acne is situated on the malar regions of the face and consists of open comedones. There are no inflammatory papules or yellow cysts, which serves as a distinguishing feature from chloracne and oil acne. Furthermore, coal-tar acne responds better to treatment than chloracne. Industry workers should avoid hazardous doses of coal tar and adhere to preventive measures in order to reduce the incidence of acne (75).

## 8. DRUG-INDUCED ACNEIFORM ERUPTIONS

Various medications may lead to so-called *acne medicamentosa*, i.e., acneiform eruptions in response to drugs (78). The exact pathogenesis of acneiform dermatoses associated with medications is, to date, insufficiently understood. It cannot be attributed to a single mechanism (47). Some characteristics are common to all drug-induced acneiform eruptions, and the diagnosis should be considered when they are present. The inflammatory lesions occurring are monomorphous in appearance and are in the same stage. They are widespread and often appear in areas uncommon for acne, such as on the upper arms and lower back. The age at which the patients present is unusual for conventional acne. The onset of these acne mimickers is abrupt and is related to a recent drug introduction.

Additionally, these cutaneous eruptions may show resistance to regular acne therapy (47,79). Although introducing a new drug regimen can lead to acneiform eruptions, an exacerbation of pre-existing acne is also possible. Susceptible individuals can thus show a mixture of these lesions (47). No specific diagnostic criteria have been set, and patch testing has not been proven helpful since the lesions cannot be attributed to allergies. Therefore, the diagnosis is made based on the before-mentioned clinical features and patient history (47,80).

Table 2 summarizes the main differences between acne vulgaris and drug-induced acneiform eruptions.

**Table 2.** Key clinical features in differentiating acneiform drug eruptions from acne

<b><i>Type of lesion</i></b>	<b>Acneiform Drug Eruption</b>	<b>Acne</b>
<b><i>Lesion localization</i></b>	Unusual distribution, extension beyond the seborrheic area, such as the arms, lower back, and genitalia	Areas highly dense in sebaceous glands: face, upper chest, and upper back
<b><i>Lesion appearance</i></b>	Monomorphic lesions, devoid of comedones and cysts	Polymorphic lesions, collections of comedones, papules, pustules, and inflamed subcutaneous nodules
<b><i>Time association</i></b>	Lesions emerge soon after drug introduction, improve after drug discontinuation, and recur after the culprit drug is reintroduced	No relationship with drugs
<b><i>Age group</i></b>	Unusual age for acne vulgaris onset; after early adulthood (aged >30 years)	Adolescents or young adults

The following chapter subdivisions will present the associations between different types of medications and acneiform eruptions.

## **8.1. HORMONES**

### **8.1.1. Anabolic steroids and androgens**

Since endogenous androgens are the critical stimulants of sebum secretion in the formation of adolescent acne, any hormone with androgenic potential can lead to the same outcomes. Therefore, synthetic counterparts of testosterone - anabolic-

androgenic steroids (AAS) can mimic its effects. Androgen injections may induce acne, notably more severe forms, and affect a more significant skin area (81). 'Bodybuilding acne', also known as 'doping acne' and 'power athlete acne', is a variant a clinician should suspect in young athletic males (82,83). Severe and extensive skin changes could indicate AAS abuse, as acne fulminans and acne conglobata can appear in around 50% of AAS abusers (84). Clinical diagnosis can often be made alongside other symptoms and signs related to the intake of anabolic steroids, such as hirsutism, androgenic alopecia, striae, an increment in sexual drive, and aggressive behaviour (85,86). A concomitant vitamin B complex abuse should be explored (84).

### 8.1.2. Corticosteroids

Although pathogenesis has been incompletely understood, acne that develops due to corticosteroids has been reported for the past 70 years (87). 'Steroid acne' has been described mainly after a high dosage of either systemic (88), topical (89), or inhaled (90) corticosteroids. The corticosteroid-induced lesions tend to be uniform in appearance, manifesting as inflammatory skin-to-pink coloured papules and pustules. They may be situated on seborrheic areas of the face and trunk areas and extend to the shoulders' regions (91). Perioral dermatitis is a clinical entity commonly affecting patients who apply corticosteroids topically in more significant amounts (92). Generally, patients' susceptibility to steroid-induced acneiform eruptions depends on the amount and length of drug administration, as well as on the individual patient's characteristics. The onset time can vary widely, ranging from almost immediately after the drug administration to a few months after (79,91). The underlying mechanism may be due to the direct effect of steroids on epithelial degeneration and inflammation (91) or an increase in free fatty acids (FFA) in skin lipids, raising bacterial levels (93).

### 8.1.3. Other hormones

Hormonal contraceptives have a varied effect on acne, either alleviating or worsening it (94). The drugs containing progestogens with androgenic activity or low-dose estrogens could present with cases of acne *de novo* or aggravation of pre-existing

acne. Inflammatory papules have been reported along the jawline and the back 1 to 3 months after placement of levonorgestrel-releasing intrauterine device (LNG-IUD) (95). Danazol, a synthetic steroid with antigonadotropin activity used in the treatment of endometriosis, may lead to acne development. Since this agent is a derivative of 17-alpha-ethinyl testosterone, its weak androgenic properties may be responsible (96). Other reports of hormonally induced acne have been linked to gonadotrophins and thyroid hormones (80).

## **8.2. NEUROPSYCHOTROPIC AGENTS**

### **8.2.1. Lithium**

Lithium is a commonly prescribed psychotropic drug for bipolar disorder. It has been associated with many cutaneous side effects, particularly common being psoriasiform and acneiform eruptions. Such cutaneous adverse effects vary in prevalence across different studies but may affect up to 45% of patients taking lithium. Predisposing factors for lithium-induced lesions are male gender and a history of atopy (97). The time frame for lesion development is variable, and no clear dose-effect relationship is established. The extremities, i.e., the forearms and legs, tend to be most commonly affected with acneiform lesions due to lithium treatment (98), and such areas show high local levels of the drug (79).

### **8.2.2. Antiepileptics**

Anticonvulsant drugs are commonly used to treat seizures and epilepsy, and many present with notable cutaneous adverse effects (99). In terms of acneiform eruptions, the most commonly implicated drugs are hydantoin (phenytoin), phenobarbital and lamotrigine (99–101). A link between acne and anticonvulsants has been scrutinized (102), and many studies suggest that anticonvulsants indeed cause acne. The papulopustular inflammatory acne related to this group of drugs seems to subside upon discontinuation of therapy (103).

### 8.2.3. Antipsychotics

Aripiprazole is an antipsychotic agent that acts as a partial agonist at the dopamine D<sub>2</sub> and serotonin 5-HT<sub>1A</sub> receptors and an antagonist at the 5-HT<sub>2A</sub> receptors (104). In aripiprazole-treated patients, papulopustular eruptions have been noted in the forehead region. The lesions were evident ten days after drug introduction and, upon discontinuation, resolved within ten days (105).

### 8.2.4. Antidepressants

All selective serotonin reuptake inhibitors (SSRI) may lead to folliculocentric pustules, with lesions affecting the face, chest, and upper back (106).

Among tricyclic antidepressants (TCA), amineptine has been related to the most severe form of acneiform eruptions. This drug was withdrawn from the French market in 1999 due to its notorious adverse effects. The patients had presented with non-inflammatory confluent, micro- and macrocystic lesions. Such eruptions predominantly affected the face and auricles; however, extensions to other regions were possible (107). In addition, the rare involvement of eccrine sweat glands was termed the 'adnexal toxic drug eruption' (108). Although rare, other cases of TCA-induced acne have been reported with maprotiline (109) and imipramine (110).

## 8.3. TARGETED THERAPIES

Targeted therapies represent the mainstay of precision medicine. These drugs are specifically designed to target a molecule associated with an underlying tumour or inflammatory disease.

### 8.3.1. Epidermal Growth Factor Receptor Inhibitors

Epidermal growth factor receptor (EGFR) activation offsets signalling pathways that may induce cellular differentiation and proliferation. The disruption of its regulation is a culprit in many diseases. Since EGFR mutations and overexpression have been noted



in different cancers, such as carcinoma of the lung, colorectal tract, breast, pancreas, and squamous cell carcinoma (SCC) of the head and neck, epidermal growth factor receptor inhibitors (EGFRI) are used in their treatment (16). EGFRI encompass monoclonal antibodies targeted against the extracellular EGFR domains (such as cetuximab (111) and panitumumab) and intracellular EGFR tyrosine kinase inhibitors (such as erlotinib and gefitinib) (79).

Cutaneous adverse effects such as acneiform eruptions have become a distinctive feature of EGFRI chemotherapy. Across various published studies, their incidence in the treated patient population ranges from 53% to 100% (112). The severity of such cutaneous manifestations is related to the dose exposure. Although there is a resemblance in the lesions, the monoclonal antibody group may be responsible for them more repeatedly than the tyrosine kinase inhibitor group. Pruritus may be present, and the term 'acneiform rash' alludes to this most frequent EGFRI-induced skin toxicity. The papules and pustules often involve seborrheic areas of the face and upper trunk but may spread to the extremities. However, palms and soles are typically unaffected. Sweet syndrome-like, hemorrhagic, and crusted lesions have been described in extreme cases. The acne-like rash already develops after the first treatment cycle, and the peak incidence is attained between weeks three and four (79,113).

There seems to be a positive correlation between treatment success and rash, possibly serving as an outcome marker (114). However, patients may opt for EGFRI therapy discontinuation due to the dermatological adverse effects. For better treatment and prevention, the pathophysiological mechanism remains to be fully understood. EGFRI may perpetuate cell division in the infundibular segment of a hair follicle, leading to its plugging and acne-like formation (112).

Acneiform rash has been graded according to the National Cancer Institute (NCI) Common Terminology Criteria for Adverse Events into five grades (Table 3).

Treatment of EGFRI-induced acneiform eruptions depends on the severity of the disease. Grade 1 is successfully treated by topical agents, including benzoyl peroxide, metronidazole, and clindamycin. Grade 2 management includes the aforementioned topical treatment, but oral minocycline or doxycycline may be prescribed. Treatment of grade 3 is identical to grade 2 treatment (i.e., by using systemic agents such as minocycline or doxycycline). In addition, in therapy-resistant EGFRI rash, systemic

isotretinoin and EGFRi dose reduction may be considered. Grade 4 acneiform rash requires withdrawal of EGFRi therapy.

In case of pruritus at any grade, oral antihistamines can be administered.

Patients experiencing cutaneous adverse effects of EGFRi should be re-assessed every two weeks. Although some studies point to advantages in prophylactic tetracycline treatment in ameliorating cutaneous symptoms, their regular use is still debated. A multidisciplinary team should collaborate to tackle challenges in therapy adherence (16).

**Table 3.** Grading of acneiform rash associated with EGFR inhibitors

NCI grade	Definition
Grade 1	Papules and/or pustules covering <10% of body surface area, may or may not be associated with pruritus/tenderness
Grade 2	Papules and/or pustules covering 10 – 30% of body surface area, may or may not be associated with pruritus/tenderness; limiting instrumental activities of daily living; associated with psychosocial impact
Grade 3	Papules and/or pustules covering >30% of body surface area, may or may not be associated with pruritus/tenderness; limiting activities associated with self-care; associated with local superinfection that indicates oral antibiotics
Grade 4	Papules and/or pustules covering any % of body surface area, , may or may not be associated with pruritus/tenderness; are associated with extensive superinfection that indicates IV antibiotics; consequences are life-threatening
Grade 5	Death

Abbreviations: IV, intravenous.

### 8.3.2. Inhibitors of Tumor Necrosis Factor

Tumor necrosis factor (TNF) inhibitors comprise a group of biological agents that target a cytokine overexpressed in inflammatory and autoimmune diseases. The immunosuppressive features of TNF inhibitors prove advantageous in managing various immune-mediated conditions, such as inflammatory bowel disease and inflammatory arthritides (115). Most TNF inhibition is achieved by monoclonal antibodies, among which infliximab is the most common culprit of acneiform eruptions (116). Moreover, compounds with anti-TNF activity, like thalidomide derivative lenalidomide, induced eruptions in treated patients (117).

## 8.4. IMMUNOSUPPRESSIVE AGENTS

### 8.4.1. Cyclosporine

Cyclosporine (CsA) is a calcineurin inhibitor that contains immunomodulatory properties. This immunosuppressant aids in preventing organ transplant rejection and is used in different inflammatory and autoimmune conditions. Due to its high efficacy and a side-effect profile that differs from other immunosuppressive agents, it helps in the treatment of entities such as atopic dermatitis and psoriasis (118). CsA therapy has been associated with acneiform eruptions in about 15% of patients. The mechanism through which the eruptions occur is by involving the pilosebaceous unit. CsA, a lipophilic drug, may be eliminated through the sebum of the sebaceous gland, resulting in various lesions involving the pilosebaceous apparatus. Hypertrichosis, epidermal cysts, and pilar keratosis are frequently reported (119), and in terms of acne, acne conglobata and acne keloidalis. The cessation of the drug serves as a therapeutic option for their resolution in isotretinoin-resistant cases (120).

### 8.4.2. Sirolimus

Sirolimus is a macrolide antibiotic with immunosuppressive activity frequently used after organ transplantation. It predisposes to acne by altering epidermal growth factor (EGF) activity, suppressing testosterone production, affecting the follicles, and

chemically modifying the sebum (79). Although sirolimus-induced acne involves sebaceous regions, its distribution to the arm, scalp, and cervical area and its clinical, histologic, and bacteriologic features differentiates it from acne vulgaris (121). Lesions mainly affect the male gender, especially those who experienced severe acne vulgaris in the past (80).

#### 8.4.3. Tacrolimus

Tacrolimus is an immunosuppressive macrolide that acts by blocking the calcineurin-dependent signal transduction pathway inside T cells. The subsequent inhibition of cytokine release makes it a valuable treatment option in inflammatory conditions. Tacrolimus is used in the management of atopic dermatitis, psoriasis, and vitiligo. To date, no cases of acneiform eruptions have been described in connection with its oral formulation. Focal acne (122) and rosaceiform dermatitis (123) have been reported with topical application of tacrolimus. Pimecrolimus, an agent of the same drug class as tacrolimus, has elicited similar cutaneous manifestations (124,125).

### 8.5. HALOGENS

Exposure to this group of highly reactive, non-metallic elements can lead to the development of halogenoderma. The umbrella term 'halogenoderma' includes skin eruptions linked to halogen-containing chemicals or substances, most notably iodine, bromine, and chlorine. The underlying mechanism is thought to be a delayed-type hypersensitivity reaction. Continuous exposure to halogenic elements is necessary for skin manifestations. However, halogenoderma can also develop acutely within days. There are various possible cutaneous manifestations (126).

#### 8.5.1. Chlorine

Acne forming in response to polyhalogenated aromatic hydrocarbons is termed chloracne. Chloracnegens such as polychlorinated dibenzodioxins can be encountered in industrial and occupational settings, as well as in polluted

environments. Since their presence is possible in foods and industrial waste material, they can enter the human system by ingestion, inhalation, and percutaneous absorption (127,128). Chloracne has gained considerable media attention since it is associated with one of the worst man-made environmental disasters in history. The notorious chemical factory explosion near Seveso, Italy, resulted in dioxin exposure in the general population. In the so-called "ICMESA plant explosion", two kilograms of 2,3,7,8-Tetrachlorodibenzo-p-dioxin (TCDD) were released, resulting in severe health consequences (129). Another significant exposure to polychlorinated hydrocarbons occurred in Japan in one of the largest food poisonings to date. The "Yusho" incident was caused by the mass contamination of rice bran oil with polychlorinated hydrocarbons (130). The harmful effects of chloracne agents, such as TCDD, stem from their carcinogenicity, immune suppression, and endocrine disruption (129,131). In severe cases, hepatic dysfunction, ophthalmopathy, and neuropathy may ensue. Regarding skin changes, an acneiform reaction represents the most identifying feature of dioxin exposure. The eruptions differ from acne vulgaris and other halogenodermas. Comedones are a hallmark of chloracne and can be so large in number that they involve every follicle. They form in specific locations: the postauricular regions and the malar crescents, as well as on the penis, scrotum, face, and axilla. The nose is typically spared and reminds of an "island in a sea of lesions", as described by Tindall in 1985 (75,132). As opposed to acne vulgaris, pustules are not a feature of chloracne (127). Besides chloracne, other dermatological findings may include hypertrichosis, brownish discoloration of the nails, and grayish skin discoloration. Chloracne is extremely difficult to treat, and therapy results are usually unsatisfactory. A trial of retinoic acid and oral antibiotics may yield some success. Unfortunately, chloracne does not subside with the cessation of exposure and can persist for a long time, up to 15-30 years thereafter (75).

### 8.5.2. Iodine

Iododerma is a term used to describe halogenoderma arising in response to iodine. This halogen can be found in topical preparations such as antiseptics, oral preparations serving thyroid-disease treatment, some expectorants, multivitamins, amiodarone, foods high in iodine, and in intravenous (IV) radiocontrast. The kidneys

can normally excrete iodine; however, in patients with renal insufficiency and in prolonged or excessive use of iodine, iododerma ensues. The eruptions may be vesicular and pustular, as well as ulcerative, suppurative, bullous, and hemorrhagic, and they generally involve the seborrheic areas, such as the face and neck (80,126). Satellite lesions accompanying the primary lesions can occur on the extremities, typically affecting the hands (133). Extracutaneous manifestations such as salivary gland swelling, conjunctivitis, and pulmonary insufficiency have also been reported in some patients (134). Although the underlying pathophysiological mechanism of iododerma remains uncertain, it is believed that delayed-type hypersensitivity occurs when iodine binds to serum proteins and elicits an immune response. In addition, neutrophil degranulation is observed (135). Urine and serum iodine levels are above the normal range. The mainstay of therapy is the cessation of iodine exposure and, in severe cases, systemic corticosteroids, cyclosporine, and hemodialysis (136).

### 8.5.3. Bromine

Bromoderma is an acneiform eruption caused by products containing bromides. Although uncommon today, bromides can still be contained in sedatives, antiepileptics, chemotherapy, expectorants, and spasmolytics. The clinical presentation of bromoderma is similar to iododerma (80). The absence of an elevation in serum bromide levels does not exclude the diagnosis; bromism is not frequently present (137). Lesions typically regress after bromide discontinuation (80).

## 8.6. VITAMINS B6 / B12

Intramuscular or oral supplementations with high doses of vitamins B6 and B12 induce acneiform eruptions and worsen pre-existing acne. This effect occurs more commonly in females and has an abrupt onset. The vitamin-associated monomorphous papules and pustules appear on the face, particularly on the chin and the forehead (138,139). No comedones or cysts are evident. The pathogenesis is unknown, and the dose-response effect is uncertain (140). The acneiform effect of vitamins has primarily been described by case reports; therefore, further investigations are necessary (141).

However, since many adults take them, physicians should inquire about vitamin supplementation in patients with inflammatory acne (139,142).

## **8.7. ANTITUBERCULOUS DRUGS**

### **8.7.1. Rifampin (Rifampicin)**

Rifampin is a rifamycin antibacterial drug that is commonly used in the treatment of tuberculosis (TB). Chronic papular acneiform eruptions were noted in a case series of African patients treated for urinary tuberculosis. They appeared around five weeks after the introduction of rifampin and were located in the face, neck, and shoulders regions. Withdrawal of the drug resulted in their resolution (143).

### **8.7.2. Isoniazid**

Isoniazid (INH) is the first-line drug in prophylaxis and treatment of TB. Acne occurred in a subset of treated patients, out of which the majority had a slow acetylating phenotype, i.e., their metabolic inactivation of INH was delayed (79,144). The affected patients were between 40 and 70 years old, exceeding the expected age range of acne vulgaris presentation. The INH-associated acne is widespread and inflammatory. Their emergence may occur even up to 18 months after drug initiation (80).

### **8.7.3. Ethionamide**

Ethionamide is a third-line agent for TB, for which drug-induced acneiform eruptions have been reported (145).

## 8.8. MISCELLANEOUS DRUGS

### 8.8.1. Dantrolene

Dantrolene is a direct-acting myorelaxant used to terminate malignant hyperthermia, a rare, life-endangering disorder provoked by general anesthesia. Besides its use in anesthesiology, dantrolene has been FDA-approved in a number of neurologic conditions (146). Acneiform eruptions in patients on dantrolene therapy tend to present variably, ranging from blackheads and comedones to cysts, pustules, and abscesses. A specific feature of dantrolene-induced lesions is their characteristic localization. Favorable sites are those subjected to pressure, friction, or chronic trauma. Neurological patients who are bedridden and patients who use wheelchairs often acquire eruptions on the contact surfaces. The mechanism of dantrolene-induced acne has not been well defined; however, a similarity with phenytoin might play a role. Furthermore, no dose-effect pattern has been established; lesions occur within months or years after the treatment. The most successful and proposed treatment strategy is switching to another treatment option or lowering the prescribed dose (80).



## 9. CONCLUSION

Although acne is regarded as a skin condition for which identification is straightforward, acneiform eruptions may present a challenge for clinical diagnosis. This group of dermatoses encompasses a vast array of dermatological conditions, among which entities differ considerably in disease severity and prevalence. Nevertheless, they all may present similarly. The follicular lesions of acneiform eruptions can be characterized by papules, pustules, nodules, or cysts. In contrast to acne, these lesions can have a predilection for any age group and are not necessarily restricted to seborrheic areas. They can present with an abrupt onset and a monomorphic appearance. Furthermore, the main distinguishing feature of acneiform eruptions is the clinical absence of open and closed comedones. It is crucial to take a complete medical history and perform a detailed clinical examination when assessing these lesions. Knowledge about the epidemiology, pathophysiology, and clinical presentation of acneiform eruptions is fundamental to providing comprehensive care and making an accurate diagnosis.

## 10. ACKNOWLEDGEMENTS

*I would like to express my sincere gratitude to my mentor Professor Zrinka Bukvić Mokos, MD, PhD, for her academic guidance throughout this process. She helped me tremendously with her immense knowledge, and I am grateful to have had her as a mentor.*

*My thanks and appreciations also go to my colleagues and friends, who have been a constant source of motivation and have enriched my student life.*

*Fundamentally, I am beyond grateful to my family. The completion of my studies could not have been possible without their unwavering support, love and encouragement.*

## 11. REFERENCES

1. Sebaceous and Sweat Gland Disorders. In: Weller RPJB, Hunter HJA, Mann MW, editors. *Clinical dermatology*. 5th edition. Chichester, West Sussex; Hoboken, NJ: John Wiley & Sons Inc; 2015, p. 156-170.
2. Knutsen-Larson S, Dawson AL, Dunnick CA, Dellavalle RP. Acne vulgaris: pathogenesis, treatment, and needs assessment. *Dermatol Clin*. 2012;30(1):99–106, viii–ix.
3. Tan JKL, Bhate K. A global perspective on the epidemiology of acne. *Br J Dermatol*. 2015;172 Suppl 1:3–12.
4. Vos T, Flaxman AD, Naghavi M, Lozano R, Michaud C, Ezzati M, et al. Years lived with disability (YLDs) for 1160 sequelae of 289 diseases and injuries 1990-2010: a systematic analysis for the Global Burden of Disease Study 2010. *Lancet*. 2012;380(9859):2163–96.
5. Hay RJ, Johns NE, Williams HC, Bolliger IW, Dellavalle RP, Margolis DJ, et al. The global burden of skin disease in 2010: an analysis of the prevalence and impact of skin conditions. *J Invest Dermatol*. 2014;134(6):1527–34.
6. Maroñas-Jiménez L, Krakowski AC. Pediatric Acne: Clinical Patterns and Pearls. *Dermatol Clin*. 2016;34(2):195–202.
7. Herane MI, Ando I. Acne in infancy and acne genetics. *Dermatology*. 2003;206(1):24–8.
8. Jansen T, Burgdorf WH, Plewig G. Pathogenesis and treatment of acne in childhood. *Pediatr Dermatol*. 1997;14(1):17–21.
9. Ghosh S. Neonatal Pustular Dermatitis: An Overview. *Indian J Dermatol*. 2015;60(2):211.
10. Cantatore-Francis JL, Glick SA. Childhood acne: evaluation and management. *Dermatol Ther*. 2006;19(4):202–9.
11. Tom WL, Friedlander SF. Acne through the ages: case-based observations through childhood and adolescence. *Clin Pediatr (Phila)*. 2008;47(7):639–51.
12. Niamba P, Weill FX, Sarlangue J, Labrèze C, Couprie B, Taïeh A. Is common neonatal cephalic pustulosis (neonatal acne) triggered by *Malassezia sympodialis*? *Arch Dermatol*. 1998;134(8):995–8.
13. Rapelanoro R. Neonatal *Malassezia furfur* Pustulosis. *Arch Dermatol*. 1996;132(2):190.
14. Antoniou C, Dessinioti C, Stratigos AJ, Katsambas AD. Clinical and therapeutic approach to childhood acne: an update. *Pediatr Dermatol*. 2009;26(4):373–80.

15. Sancak B, Ayhan M, Karaduman A, Arikan S. [In vitro activity of ketoconazole, itraconazole and terbinafine against *Malassezia* strains isolated from neonates]. *Mikrobiyol Bul.* 2005;39(3):301–8.
16. Dessinioti C, Antoniou C, Katsambas A. Acneiform eruptions. *Clin Dermatol.* 2014;32(1):24–34.
17. Tarm K, Creel NB, Krivda SJ, Turiansky GW. Granulomatous periorificial dermatitis. *Cutis.* 2004;73(6):399–402.
18. Patrizi A, Gurioli C, Neri I. Childhood granuloma annulare: a review. *G Ital Dermatol Venereol.* 2014;149(6):663–74.
19. Smith R. Papular Granuloma Annulare. In: Zeichner J, editor. *Acneiform Eruptions in Dermatology.* New York, NY: Springer New York; 2014, p. 375–9.
20. Risma KA, Lucky AW. Pseudoacne of the nasal crease: a new entity? *Pediatr Dermatol.* 2004;21(4):427–31.
21. Ooi XT, Tan KB, Chandran N. A case of pediatric rosacea-Skin and ocular involvement. *Clin Case Rep.* 2019;7(12):2414–6.
22. Dessinioti C, Katsambas A. Childhood Rosacea. In: Hoeger P, Kinsler V, Yan A, Harper J, Oranje A, Bodemer C, et al., editors. *Harper's Textbook of Pediatric Dermatology.* 4th edition. Wiley: Hoboken, NJ, USA; 2019, p. 821–4.
23. Boralevi F, Léauté-Labrèze C, Lepreux S, Barbarot S, Mazereeuw-Hautier J, Eschard C, et al. Idiopathic facial aseptic granuloma: a multicentre prospective study of 30 cases. *Br J Dermatol.* 2007;156(4):705–8.
24. Feldman SR, Hollar CB, Gupta AK, Fleischer AB. Women commonly seek care for rosacea: dermatologists frequently provide the care. *Cutis.* 2001;68(2):156–60.
25. Ahn CS, Huang WW. Rosacea Pathogenesis. *Dermatol Clin.* 2018;36(2):81–6.
26. Kim HS. Microbiota in Rosacea. *Am J Clin Dermatol.* 2020;21(Suppl 1):25–35.
27. Picardo M, Eichenfield LF, Tan J. Acne and Rosacea. *Dermatol Ther (Heidelb).* 2017;7(S1):43–52.
28. Yun CH, Yun JH, Baek JO, Roh JY, Lee JR. Demodex Mite Density Determinations by Standardized Skin Surface Biopsy and Direct Microscopic Examination and Their Relations with Clinical Types and Distribution Patterns. *Ann Dermatol.* 2017;29(2):137–42.
29. Rather PA, Hassan I. Human demodex mite: the versatile mite of dermatological importance. *Indian J Dermatol.* 2014;59(1):60–6.
30. Paichitrojjana A. Demodicosis Imitating Acne Vulgaris: A Case Report. *Clin Cosmet Investig Dermatol.* 2022;15:497–501.

31. Mokos ZB, Kummer A, Mosler EL, Čeović R, Basta-Juzbašić A. Perioral dermatitis: still a therapeutic challenge. *Acta Clin Croat*. 2015;54(2):179–85.
32. Kuflik JH, Janniger CK, Piela Z. Perioral dermatitis: an acneiform eruption. *Cutis*. 2001;67(1):21–2.
33. Nikolakis G, Kokolakis G, Kaleta K, Wolk K, Hunger R, Sabat R, et al. [Pathogenesis of hidradenitis suppurativa/acne inversa]. *Hautarzt*. 2021;72(8):658–65.
34. Goldberg SR, Strober BE, Payette MJ. Hidradenitis suppurativa: Epidemiology, clinical presentation, and pathogenesis. *J Am Acad Dermatol*. 2020;82(5):1045–58.
35. Matusiak L, Bieniek A, Szepietowski JC. Psychophysical aspects of hidradenitis suppurativa. *Acta Derm Venereol*. 2010;90(3):264–8.
36. Wieczorek M, Walecka I. Hidradenitis suppurativa – known and unknown disease. *Reumatologia*. 2018;56(6):337–9.
37. Seyed Jafari SM, Hunger RE, Schlapbach C. Hidradenitis Suppurativa: Current Understanding of Pathogenic Mechanisms and Suggestion for Treatment Algorithm. *Front Med (Lausanne)*. 2020;7:68.
38. Ogunbiyi A. Pseudofolliculitis barbae; current treatment options. *Clin Cosmet Investig Dermatol*. 2019;12:241–7.
39. Goldstein BG, Goldstein AO. Pseudofolliculitis barbae. In: Post Ted W, editor. *UpToDate*. Waltham MA: UpToDate; 2022. Last accessed: June 9, 2022.
40. Kelly AP. Pseudofolliculitis barbae and acne keloidalis nuchae. *Dermatol Clin*. 2003;21(4):645–53.
41. Garcia-Zuazaga J. Pseudofolliculitis barbae: review and update on new treatment modalities. *Mil Med*. 2003;168(7):561–4.
42. Ofuji S. Eosinophilic Pustular Folliculitis. *Dermatologica*. 1987;174(2):53–6.
43. Katoh M, Nomura T, Miyachi Y, Kabashima K. Eosinophilic pustular folliculitis: a review of the Japanese published works. *J Dermatol*. 2013;40(1):15–20.
44. Nervi SJ, Schwartz RA, Dmochowski M. Eosinophilic pustular folliculitis: a 40 year retrospect. *J Am Acad Dermatol*. 2006;55(2):285–9.
45. Luelmo-Aguilar J, Santandreu MS. Folliculitis: recognition and management. *Am J Clin Dermatol*. 2004;5(5):301–10.
46. Laureano AC, Schwartz RA, Cohen PJ. Facial bacterial infections: folliculitis. *Clin Dermatol*. 2014;32(6):711–4.
47. Plewig G, Jansen T. Acneiform dermatoses. *Dermatology*. 1998;196(1):102–7.
48. Blankenship ML. Gram-negative folliculitis. Follow-up observations in 20 patients. *Arch Dermatol*. 1984;120(10):1301–3.

49. Böni R, Nehrhoff B. Treatment of gram-negative folliculitis in patients with acne. *Am J Clin Dermatol*. 2003;4(4):273–6.
50. Rubenstein RM, Malerich SA. Malassezia (pityrosporum) folliculitis. *J Clin Aesthet Dermatol*. 2014;7(3):37–41.
51. Gupta AK, Batra R, Bluhm R, Boekhout T, Dawson TL. Skin diseases associated with Malassezia species. *J Am Acad Dermatol*. 2004;51(5):785–98.
52. Malgotra V, Singh H. Malassezia (Pityrosporum) Folliculitis Masquerading As Recalcitrant Acne. *Cureus*. 2021;13(2):e13534.
53. Bäck O, Faergemann J, Hörnqvist R. Pityrosporum folliculitis: a common disease of the young and middle-aged. *J Am Acad Dermatol*. 1985;12(1 Pt 1):56–61.
54. Ratnam S, Hogan K, March SB, Butler RW. Whirlpool-associated folliculitis caused by *Pseudomonas aeruginosa*: report of an outbreak and review. *J Clin Microbiol*. 1986;23(3):655–9.
55. Toner CB. *Pseudomonas Folliculitis*. In: Dirk M Elston, editor. Medscape; 2020. Last accessed June 19, 2022.
56. Sporotrichosis - Infectious Diseases [Internet]. MSD Manual Professional Edition. [cited 2022 May 25]. Available from: <https://www.msmanuals.com/professional/infectious-diseases/fungi/sporotrichosis>
57. Kusahara M, Hachisuka H, Sasai Y. Statistical survey of 150 cases with sporotrichosis. *Mycopathologia*. 1988;102(2):129–33.
58. Mahlberg MJ, Patel R, Rosenman K, Cheung W, Wang N, Sanchez M. Fixed cutaneous sporotrichosis. *Dermatol Online J*. 2009;15(8):5.
59. Garcia SCG, Alanis JCS, Flores MG, Gonzalez SEG, Cabrera LV, Candiani JO. Coccidioidomycosis and the skin: a comprehensive review. *An Bras Dermatol*. 2015;90(5):610–9.
60. Ocampo-Garza J, Castrejón-Pérez AD, Gonzalez-Saldivar G, Ocampo-Candiani J. Cutaneous coccidioidomycosis: a great mimicker. *BMJ Case Reports*. 2015;bcr2015211680.
61. Lambert WC, Bagley MP, Khan Y, Schwartz RA. Pustular acneiform secondary syphilis. *Cutis*. 1986;37(1):69–70.
62. Harden D, Keeling JH. Papular and nodular lesions of the scalp, face, and neck. Secondary syphilis. *Arch Dermatol*. 1997;133(8):1027, 1030.
63. Hjorth N, Sjolín KE, Sylvest B, Thomsen K. Acne aestivalis--Mallorca acne. *Acta Derm Venereol*. 1972;52(1):61–3.
64. Jones C, Bleehen SS. Acne induced by PUVA treatment. *Br Med J*. 1977;2(6091):866–866.

65. Plewig G, Kligman AM. Acne Tropicalis (Tropical Acne). In: Plewig G, Kligman AM, editors. ACNE and ROSACEA. Berlin, Heidelberg: Springer; 1993, p. 339–40.
66. Zaenglein AL, Graber EM, Thiboutot DM. Chapter 80. Acne Vulgaris and Acneiform Eruptions. In: Goldsmith LA, Katz SI, Gilchrest BA, Paller AS, Leffell DJ, Wolff K, editors. Fitzpatrick's Dermatology in General Medicine. 8th edition. New York, NY: The McGraw-Hill Companies; 2012, p. 897-917.
67. Freiman A, Barankin B, Elpern DJ. Sports dermatology part 1: common dermatoses. CMAJ. 2004;171(8):851–3.
68. Kirkland R, Adams BB. Dermatological problems in the football player. International Journal of Dermatology. 2006;45(8):927–32.
69. Knierim C, Goertz W, Reifenberger J, Homey B, Meller S. [Fiddler's neck]. Hautarzt. 2013;64(10):724–6.
70. Kligman AM, Mills OH Jr. Acne Cosmetica. Archives of Dermatology. 1972;106(6):843–50.
71. Plewig G, Fulton JE, Kligman AM. Pomade acne. Arch Dermatol. 1970;101(5):580–4.
72. Martin WMC, Bardsley AF. The comedo skin reaction to radiotherapy. Br J Radiol. 2002;75(893):478–81.
73. Paganelli A, Mandel VD, Kaleci S, Pellacani G, Rossi E. Favre-Racouchot disease: systematic review and possible therapeutic strategies. J Eur Acad Dermatol Venereol. 2019;33(1):32–41.
74. Sonthalia S, Arora R, Chhabra N, Khopkar U. Favre-Racouchot syndrome. Indian dermatology online journal. 2014;5:S128-9.
75. Demir B, Cicek D. Occupational Acne. In: Selda Pelin Kartal, Müzeyyen Gönül, editors. Acne and Acneiform Eruptions. IntechOpen; 2017, p. 53-67.
76. Moustafa GA, Xanthopoulou E, Riza E, Linos A. Skin disease after occupational dermal exposure to coal tar: a review of the scientific literature. Int J Dermatol. 2015;54(8):868–79.
77. Zorba E, Karpouzis A, Zorbas A, Bazas T, Zorbas S, Alexopoulos E, et al. Occupational Dermatoses by Type of Work in Greece. Saf Health Work. 2013;4(3):142–8.
78. Lolis MS, Bowe WP, Shalita AR. Acne and systemic disease. Med Clin North Am. 2009;93(6):1161–81.
79. Do HK, Ezra N, Wolverson SE. Drug-Induced Acneiform Eruptions. In: Zeichner J, editor. Acneiform Eruptions in Dermatology. New York, NY: Springer New York; 2014, p. 389–404.

80. Du-Thanh A, Kluger N, Bensalleh H, Guillot B. Drug-induced acneiform eruption. *Am J Clin Dermatol*. 2011;12(4):233–45.
81. Fyrand O, Fiskaadal HJ, Trygstad O. Acne in pubertal boys undergoing treatment with androgens. *Acta Derm Venereol*. 1992;72(2):148–9.
82. Heydenreich G. Testosterone and anabolic steroids and acne fulminans. *Arch Dermatol*. 1989;125(4):571–2.
83. Gerber PA, Kukova G, Meller S, Neumann NJ, Homey B. The dire consequences of doping. *The Lancet*. 2008;372(9639):656.
84. Melnik B, Jansen T, Grabbe S. Abuse of anabolic-androgenic steroids and bodybuilding acne: an underestimated health problem. *J Dtsch Dermatol Ges*. 2007;5(2):110–7.
85. Hartgens F, Kuipers H. Effects of Androgenic-Anabolic Steroids in Athletes: *Sports Medicine*. 2004;34(8):513–54.
86. Scott MJ, Scott AM. Effects of anabolic-androgenic steroids on the pilosebaceous unit. *Cutis*. 1992;50(2):113–6.
87. Brunner MJ, Riddell JM, Best WR. Cutaneous side effects of ACTH cortisone and pregnenolone therapy. *J Invest Dermatol*. 1951;16(4):205–10.
88. Fung MA, Berger TG. A prospective study of acute-onset steroid acne associated with administration of intravenous corticosteroids. *Dermatology*. 2000;200(1):43–4.
89. Plewig G, Kligman AM. Induction of acne by topical steroids. *Arch Derm Forsch*. 1973;247(1):29–52.
90. Hughes JR, Higgins EM, du Vivier AW. Acne associated with inhaled glucocorticosteroids. *BMJ*. 1992;305(6860):1000.
91. Hurwitz RM. Steroid acne. *J Am Acad Dermatol*. 1989;21(6):1179–81.
92. Cohen HJ. Perioral dermatitis. *Journal of the American Academy of Dermatology*. 1981;4(6):739–40.
93. Gloor M, Mildemberger KH. On the influence of an external therapy with dexamethasone-21-sodium-m-sulfobenzoate on the amount of free fatty acids in the skin surface lipids. *Arch Dermatol Res*. 1978;261(1):33–8.
94. Lortscher D, Admani S, Satur N, Eichenfield LF. Hormonal Contraceptives and Acne: A Retrospective Analysis of 2147 Patients. *J Drugs Dermatol*. 2016;15(6):670–4.
95. Ilse JR, Greenberg HL, Bennett DD. Levonorgestrel-releasing intrauterine system and new-onset acne. *Cutis*. 2008;82(2):158.



96. Greenberg RD. Acne vulgaris associated with antigonadotropic (Danazol) therapy. *Cutis*. 1979;24(4):431–3.
97. Yeung CK, Chan HHL. Cutaneous adverse effects of lithium: epidemiology and management. *Am J Clin Dermatol*. 2004;5(1):3–8.
98. Heng M. Cutaneous manifestations of lithium toxicity. *Br J Dermatol*. 1982;106(1):107–9.
99. Hebert AA, Ralston JP. Cutaneous reactions to anticonvulsant medications. *J Clin Psychiatry*. 2001;62 Suppl 14:22–6.
100. Diphenylhydantoin and Acne. *N Engl J Med*. 1972;287(3):148–148.
101. Nielsen JN, Licht RW, Fogh K. Two Cases of Acneiform Eruption Associated With Lamotrigine. *J Clin Psychiatry*. 2004;65(12):1720–2.
102. Greenwood R, Fenwick P, Cunliffe W. Acne and Anticonvulsants. *British medical journal (Clinical research ed)*. 1984;287:1669–70.
103. Anticonvulsant drugs and the skin. *DermNet NZ* [Internet]. [cited 2022 May 25]. Available from: <https://dermnetnz.org/topics/cutaneous-adverse-effects-of-anticonvulsant-drugs>
104. Fleischhacker WW. Aripiprazole. *Expert Opinion on Pharmacotherapy*. 2005;6(12):2091–101.
105. Mishra B, Praharaj SK, Prakash R, Sinha VK. Aripiprazole-induced acneiform eruption. *Gen Hosp Psychiatry*. 2008;30(5):479–81.
106. Warnock JK, Morris DW. Adverse cutaneous reactions to antidepressants. *Am J Clin Dermatol*. 2002;3(5):329–39.
107. Vexiau P, Gourmel B, Castot A, Husson C, Rybojad M, Julien R, et al. Severe acne due to chronic amineptine overdose. *Arch Dermatol Res*. 1990;282(2):103–7.
108. Huet P, Dandurand M, Joujoux JM, Amaudric F, Guillot B. [Acne induced by amineptin: adnexal toxiderma]. *Ann Dermatol Venereol*. 1996;123(12):817–20.
109. Ponte CD. Maprotiline-induced acne. *Am J Psychiatry*. 1982;139(1):141.
110. Ossosky HJ. Amenorrhea in Endogenous Depression. *Int Pharmacopsychiatry*. 1974;9(2):100–8.
111. Štulhofer Buzina D, Martinac I, Ledić Drvar D, Čeović R, Bilić I, Marinović B. Adverse Reaction to Cetuximab, an Epidermal Growth Factor Receptor Inhibitor. *Acta Dermatovenerol Croat*. 2016;24(1):70–2.
112. Segaeert S, Van Cutsem E. Clinical signs, pathophysiology and management of skin toxicity during therapy with epidermal growth factor receptor inhibitors. *Ann Oncol*. 2005;16(9):1425–33.

113. Potthoff K, Hofheinz R, Hassel JC, Volkenandt M, Lordick F, Hartmann JT, et al. Interdisciplinary management of EGFR-inhibitor-induced skin reactions: a German expert opinion. *Ann Oncol*. 2011;22(3):524–35.
114. Pérez-Soler R, Saltz L. Cutaneous adverse effects with HER1/EGFR-targeted agents: is there a silver lining? *J Clin Oncol*. 2005;23(22):5235–46.
115. Lis K, Kuzawińska O, Bałkowiec-Iskra E. State of the art paper Tumor necrosis factor inhibitors – state of knowledge. *Arch Med Sci*. 2014;6:1175–85.
116. Sladden MJ, Clarke PJ, Mitchell B. Infliximab-induced acne: report of a third case. *British Journal of Dermatology*. 2007;158(1):172–172.
117. Michot C, Guillot B, Dereure O. Lenalidomide-Induced Acute Acneiform Folliculitis of the Head and Neck: Not Only the Anti-EGF Receptor Agents. *Dermatology*. 2010;220(1):49–50.
118. Koo J, Lee J. Cyclosporine: what clinicians need to know. *Dermatol Clin*. 1995;13(4):897–907.
119. Bencini PL, Montagnino G, Sala F, De Vecchi A, Crosti C, Tarantino A. Cutaneous lesions in 67 cyclosporin-treated renal transplant recipients. *Dermatologica*. 1986;172(1):24–30.
120. el-Shahawy MA, Gadallah MF, Massry SG. Acne: a potential side effect of cyclosporine A therapy. *Nephron*. 1996;72(4):679–82.
121. Mahé E, Morelon E, Lechaton S, Drappier JC, de Prost Y, Kreis H, et al. Acne in recipients of renal transplantation treated with sirolimus: clinical, microbiologic, histologic, therapeutic, and pathogenic aspects. *J Am Acad Dermatol*. 2006;55(1):139–42.
122. Bakos L. Focal Acne During Topical Tacrolimus Therapy for Vitiligo. *Arch Dermatol*. 2007;143(9):1209.
123. Antille C, Saurat JH, Lübke J. Induction of rosaceiform dermatitis during treatment of facial inflammatory dermatoses with tacrolimus ointment. *Arch Dermatol*. 2004;140(4):457–60.
124. El Sayed F, Ammouy A, Dhaybi R, Bazex J. Rosaceiform eruption to pimecrolimus. *J Am Acad Dermatol*. 2006;54(3):548–50.
125. Li JC, Xu AE. Facial acne during topical pimecrolimus therapy for vitiligo. *Clin Exp Dermatol*. 2009;34(7):e489–90.
126. Halogenoderma. *DermNet NZ* [Internet]. [cited 2022 May 26]. Available from: <https://dermnetnz.org/topics/halogenoderma>
127. Mcdonagh AJG, Gawkrödger DJ, Walker AE. Chloracne—study of an outbreak with new clinical observations. *Clin Exp Dermatol*. 1993;18(6):523–5.

128. Rodriguez-Pichardo A, Camacho F. Chloracne as a consequence of a family accident with chlorinated dioxins. *J Am Acad Dermatol.* 1990;22(6):1121.
129. Eskenazi B, Warner M, Brambilla P, Signorini S, Ames J, Mocarelli P. The Seveso accident: A look at 40 years of health research and beyond. *Environ Int.* 2018;121(Pt 1):71–84.
130. Onozuka D, Nakamura Y, Tsuji G, Furue M. Mortality in Yusho patients exposed to polychlorinated biphenyls and polychlorinated dibenzofurans: a 50-year retrospective cohort study. *Environ Health.* 2020;19(1):119.
131. Carpenter DO. Polychlorinated biphenyls (PCBs): routes of exposure and effects on human health. *Rev Environ Health.* 2006;21(1):1–23.
132. Tindall JP. Chloracne and chloracnegens. *J Am Acad Dermatol.* 1985;13(4):539–58.
133. Hesseler MJ, Clark MR, Zacur JL, Rizzo JM, Hristov AC. An acneiform eruption secondary to iododerma. *JAAD Case Rep.* 2018;4(5):468–70.
134. Tasker F, Fleming H, McNeill G, Creamer D, Walsh S. Contrast media and cutaneous reactions. Part 2: Delayed hypersensitivity reactions to iodinated contrast media. *Clin Exp Dermatol.* 2019;44(8):844–60.
135. Torkamani N, Sinclair R. Iododerma in pregnancy secondary to iodinated multivitamins: Letters to the Editor. *Australas J Dermatol.* 2015;56(3):235–6.
136. Young AL, Grossman ME. Acute iododerma secondary to iodinated contrast media. *Br J Dermatol.* 2014;170(6):1377–9.
137. Hoefel I da R, Camozzato FO, Hagemann LN, Rhoden DLB, Kiszewski AE. Bromoderma in an infant. *An Bras Dermatol.* 2016;91(5 Suppl 1):17–9.
138. Balta I, Ozuguz P. Vitamin B12-induced acneiform eruption. *Cutan Ocul Toxicol.* 2014;33(2):94–5.
139. Sherertz EF. Acneiform eruption due to “megadose” vitamins B6 and B12. *Cutis.* 1991;48(2):119–20.
140. Kazandjieva J, Tsankov N. Drug-induced acne. *Clin Dermatol.* 2017;35(2):156–62.
141. Veraldi S, Benardon S, Diani M, Barbareschi M. Acneiform eruptions caused by vitamin B12: A report of five cases and review of the literature. *J Cosmet Dermatol.* 2018;17(1):112–5.
142. Aalfs AS, Scholvinck LH, Horváth B. Acneiform eruption in a 5-year-old due to vitamin B12 supplementation. *Eur J Dermatol.* 2013;23(5):726–7.
143. Nwokolo U. Letter: Acneiform lesions in combined rifampicin treatment in Africans. *Br Med J.* 1974;3(5928):473.

144. Cohen LK, George W, Smith R. Isoniazid-Induced Acne and Pellagra: Occurrence in Slow Inactivators of Isoniazid. *Arch Dermatol*. 1974;109(3):377–81.
145. Levantine A, Almeyda J. Drug reactions. 18. Cutaneous reactions to antituberculous drugs. *Br J Dermatol*. 1972;86(6):651–5.
146. Ratto D, Joyner RW. Dantrolene. In: StatPearls [Internet]. Treasure Island (FL): StatPearls Publishing; 2022 [cited 2022 May 26]. Available from: <http://www.ncbi.nlm.nih.gov/books/NBK535398>

## 12. BIOGRAPHY

I was born on the 4th of November, 1997, in Zagreb, Croatia. After finishing elementary school, I enrolled in the bilingual Croatian – English high school programme of the XVI. Gymnasium in Zagreb. During my high school years, I participated in the National Dance ESDU Championship and the World Dance Masters championship together with the Dance Studio TransForm. Teamed up with my brother, I also participated in the National Robotics Competition "RoboCup Open "in Dubrovnik in 2015, where we were awarded third place. In 2016, I acquired a DSD2 (Deutsches Sprachdiplom) certificate of German language proficiency level C1. After completing high school, I started my university education in 2016 in English, at the School of Medicine, University of Zagreb. During my studies, I developed an interest in Dermatology and Venerology and became a member of the Student Section for Dermatovenerology. Currently, I hold the position of the President of the Student Section for Dermatovenerology. I participated in congresses such as CROSS17 and ZIMS2021 as an individual presenter and BFH2020 and ZIMS2020 as part of the Student section of Dermatovenerology. The scientific committee of ZIMS2021 ranked my paper presentation as the 2nd best at the conference.

Similarly, I got second place when presenting another paper at the International Medical Congress in Lublin, Poland. During my time at the university, I was awarded the Dean's Award for being the best student in the academic year 2017./2018. as well as a *STEM scholarship* issued by the Ministry of Science and Education, and a *Scholarship for excellence* issued by the University of Zagreb. I am a member of Rotaract, a club that brings people together to work on community service initiatives.