

Correlation between periacinar retraction clefting and the expression of E-cadherin and Beta-catenin proteins in prostatic adenocarcinoma

Limani, Rinë

Doctoral thesis / Disertacija

2016

Degree Grantor / Ustanova koja je dodijelila akademski / stručni stupanj: **University of Zagreb, School of Medicine / Sveučilište u Zagrebu, Medicinski fakultet**

Permanent link / Trajna poveznica: <https://um.nsk.hr/um:nbn:hr:105:464846>

Rights / Prava: [In copyright](#)/[Zaštićeno autorskim pravom.](#)

Download date / Datum preuzimanja: **2024-08-07**



Repository / Repozitorij:

[Dr Med - University of Zagreb School of Medicine Digital Repository](#)



UNIVERSITY OF ZAGREB
SCHOOL OF MEDICINE

Rinë Limani

**Correlation between periacinar
retraction clefting and the expression
of E-cadherin and Beta-catenin
proteins in prostatic adenocarcinoma**

DISSERTATION



Zagreb, 2016.

UNIVERSITY OF ZAGREB
SCHOOL OF MEDICINE

Rinë Limani

**Correlation between periacinar
retraction clefting and the expression
of E-cadherin and Beta-catenin
proteins in prostatic adenocarcinoma**

DISSERTATION

Zagreb, 2016.

This dissertation was made at the Department of Pathology "Ljudevit Jurak" of the Clinical Hospital Center "Sestre milosrdnice" in Zagreb and the Institute of Pathology Šalata University of Zagreb School of Medicine.

Mentor: Prof. Božo Krušlin, M.D., Ph.D.

This dissertation is dedicated to my parents—my mother Zymryte and my father Adem Limani—who have always believed in me and supported me, and whose good examples have taught me to work hard for the things that I aspire to achieve.

ACKNOWLEDGMENTS

My most sincere thanks go to my adviser and mentor Prof.Božo Krušlin, M.D., Ph.D., for the continuous support of my PhD study and related research, and for sharing expertise and valuable guidance during my research.

My sincere thanks also go to Prof. Sven Seiwert, M.D., Ph.D., and the staff of the Institute of Pathology Šalata, University of Zagreb School of Medicine, who gave me access to the laboratory and research facilities and were always very friendly and supportive.

I am very thankful and indebted to my residency mentor and professor, Prof. Lumturije Gashi Luci, M.D., Ph.D., Institute of Pathology, University of Prishtina Faculty of Medicine, for encouragement extended to me throughout.

Last but not least, I am grateful to my husband Sead Rama for the unceasing encouragement, support, patience, and attention through this venture

CONTENTS

1. INTRODUCTION.....	1
1.1 Embryology and development of the prostate.....	1
1.2 Gross anatomy of the prostate.....	1
1.3 Normal histology of the prostate.....	3
1.4 Benign prostatic hyperplasia.....	5
1.4.1 Epidemiology and prevalence.....	5
1.4.2 Etiology and pathogenesis.....	5
1.4.3 Gross anatomy.....	6
1.4.4 Histopathology.....	6
1.4.5 Clinical features and management.....	7
1.5 Precursor and putative precursor lesions to prostatic carcinoma.....	8
1.5.1 Prostatic intraepithelial neoplasia.....	8
1.5.2 Atypical adenomatous hyperplasia.....	9
1.5.3 Proliferative inflammatory atrophy.....	9
1.6 Prostate cancer.....	11
1.6.1 Epidemiology.....	11
1.6.2 Etiology and risk factors.....	12
1.6.3 Clinical presentation and diagnosis.....	15
1.6.4 Gross anatomy.....	18
1.6.5 Histopathology.....	18
1.6.6 Molecular and genetic alterations.....	28
1.6.7 Immunohistochemistry.....	29
1.6.8 TNM staging system.....	30
1.6.9 Risk stratification.....	33
1.6.10 Therapy and prognosis.....	33
1.7 Periacinar retraction clefting.....	36
1.8 E-cadherin/ Beta-catenin.....	38
2. HYPOTHESIS.....	41
3. AIMS OF THESIS.....	42
3.1 General aim.....	42
3.2 Specific aims.....	42
4. MATERIAL AND METHODS.....	43
4.1 Study population and material.....	43
4.2 Methods.....	43
4.2.1 Immunohistochemistry.....	44
4.2.2 Scoring.....	44
4.3 Statistical methods.....	44
5. RESULTS.....	45
5.1 Descriptive statistics.....	45

5.2	Correlation between the presence and extent of periacinar retraction clefting in prostatic adenocarcinoma and in the adjacent nonneoplastic prostatic tissue	47
5.3	IHC expression of E-cadherin and β -catenin cell adhesion proteins in prostatic adenocarcinoma and in the adjacent nonneoplastic prostatic issue	48
5.4	Correlation of expression of E- cadherin and β -catenin with periacinar retraction clefting in prostatic adenocarcinoma and in the adjacent nonneoplastic prostatic tissue	57
6.	DISCUSSION	60
7.	CONCLUSIONS AND IMPLICATIONS FOR FURTHER RESEARCH.....	68
8.	ABSTRACT	69
9.	SAŽETAK.....	70
10.	REFERENCES	71
11.	BIOGRAPHY	83

ABBREVIATIONS

AAH= Atypical adenomatous hyperplasia

ADT= Androgen deprivation therapy

AJCC= American Joint Committee on Cancer

AMACR= Alpha-methyl- CoA racemase

APC= Adenomatous polyposis coli

AR= Androgen receptor

β =Beta

BCC= Basal cell carcinoma

BCR= Biochemical recurrence

BPH= Benign prostatic hyperplasia

BT= Brachytherapy

CAM= Cell adhesion molecules

CAN = Copy number alterations

CI= Confidence interval

DHT= Dihydrotestosterone

DNA= Deoxyribonucleic acid

DRE= Digital rectal examination

EBRT= External beam radiation therapy

ERG = Ets related gene product

GSC= Gleason score

GSTP1= Glutathione-S-transferase Pi 1

H&E = Hematoxylin & eosin

HGPIN= High grade prostatic intraepithelial neoplasia

H3K27-me3= histone H-me3

HMWCK = High molecular weight cytokeratin

HPC= Hereditary prostatic carcinoma

HR= Hazard ratios

IHC= Immunohistochemistry

IGF-1= Insulin like growth factor- 1

ISUP= International Society of Urological Pathology

kDa= Kilodalton

LCNEC= Large cell neuroendocrine carcinoma

LGPIN= Low grade prostatic intraepithelial neoplasia

LUTS= Lower urinary tract symptoms

NCCN= National Comprehensive Cancer Network

PA= Prostatic atrophy

PAP = Prostatic acid phosphatase

PCA3- Prostate cancer antigen 3

PIA = Proliferative inflammatory atrophy

PIN = Prostatic intraepithelial neoplasia

PSA= Prostatic specific antigen

PTEN= Phosphatase and tensin homolog deleted on Chromosome 10

ROS= Reactive oxygen species

RP= Radical prostatectomy

RT= Radiotherapy

SCC= Squamous cell carcinoma

TNM = Tumor, Node, Metastasis

TRUS= Transrectal ultrasonography

TURP = Transurethral resection of the prostate

UICC= Union for International Cancer Control

US= United States

VACURG= Veterans Administration Cooperative Urological Research Group

WHO= World Health Organization

1. INTRODUCTION

1.1 Embryology and development of the prostate

The prostate develops from the urogenital sinus. Its glandular substance derives from the endodermal epithelial outgrowths of the prostatic segment of the urethra, whereas its fibromuscular and connective tissue derive from the mesodermal mesenchyme (1).

The epithelial outgrowth and branching start at week 10 during embryo growth and these are activated by androgen that is secreted by the fetal testes. By week 12, the prostate develops five lobes: the middle lobe, the left and right lateral lobes, the posterior lobe, and the anterior lobe (1, 2). No boundaries can be identified between these lobes at 2.5 months postnatally, nor do they do exist in the prepubertal and normal adult prostate.

The normal formation of the prostate requires the presence of 5 α -dihydrotestosterone, which is synthesized from fetal testosterone by the action of the 5 α -reductase enzyme localized in the urogenital sinus and the external genitalia in humans. Deficiency of 5 α reductase causes the development of only a rudimentary prostate, in addition to several abnormalities of the external genitalia (3).

From birth until puberty, the constitution of the prostate remains more or less identical. The prostate begins to undergo morphologic changes into the adult phenotype upon initiation of puberty. The prostate enlarges continuously in size, to reach the adult weight of approximately 20 grams by the age 25–30 (3).

1.2 Gross anatomy of the prostate

The prostate is an accessory structure of the male reproductive system. The main function of the prostate is to contribute to the production of the seminal fluid at the time of ejaculation. The prostate has the shape of an inverted cone, with the base located proximally at the bladder neck, and the apex distally at the urogenital diaphragm (4). At the base of the prostate are the seminal vesicles (4). The prostatic urethra, which runs through the center of the prostate, has a central 35-degree bend that divides it into proximal and distal segments of approximately equal length.

Ejaculatory ducts perforate the prostate and open in the middle of the prostatic urethra at the seminal colliculus, the verumontanum (5). The prostate is an assemblage of about 30 tubuloalveolar glands, with ducts, that empty into the prostatic urethra. The distal urethral segment receives the ejaculatory duct and the ducts of about 95% of the glandular prostate

tissue, whereas the proximal urethral segment is related to only about 5 to 10% of the prostatic glandular tissue (5).

The prostate is enclosed by a capsule composed of collagen, elastin, and large amounts of smooth muscle. Three distinct layers of fascia cover the anterior, lateral, and posterior aspects of the prostate (5). The anterior and anterolateral fasciae are in direct continuity with the so called “true” prostatic capsule, whereas posteriorly, a thin layer of connective tissue known as Denonvillier’s fascia separates the prostate and seminal vesicles from the rectum (5). Anteriorly, two puboprostatic ligaments fix the prostate to the pubic bone (5).

Anatomists initially divided the prostate, via the urethra and the ejaculatory ducts, into five lobes: the *anterior*, which is anterior to the urethra; the *posterior*, behind the urethra and below the ejaculatory ducts; the *median*, between the urethra and the ejaculatory ducts; and the *left* and the *right lobes*, which lie on either side of the urethra (4). More recently, *McNeal* (5) defined a concept of anatomic zones, rather than lobes, to describe the prostate. The recommended four zones are the anterior fibromuscular stroma; the central zone; the peripheral zone; and the preprostatic region, which encompasses the periurethral ducts and the large transition zone (5). This scheme is often simplified into a two zone concept, corresponding to the inner (transition zone) and the outer (peripheral and central zones) sections of the prostate (5).

The anterior fibromuscular stroma forms the convexity of the anterior external surface of the prostate. The apical half of this area is rich in striated muscle, which blends into the prostate and the muscle of the pelvic diaphragm. Toward the base, smooth muscle cells become predominant, blending into the fibers of the bladder neck. The distal portion of the anterior fibromuscular stroma is important in voluntary sphincter functions, whereas the proximal portion plays a central role in involuntary sphincter functions (3, 5).

The central zone is a cone-shaped area of the prostate, with the apex of the cone at the confluence of the ejaculatory ducts and the prostatic urethra at the verumontanum. The peripheral zone comprises all the prostatic glandular tissue at the apex, as well as all the tissue located posteriorly near the capsule. In this zone, carcinoma, chronic prostatitis, and postinflammatory atrophy are relatively more common. The transition zone consists of two equal portions of glandular tissue lateral to the urethra in the midgland. This portion of the prostate is involved in the development of age-related benign prostatic hyperplasia (BPH) and, less commonly, adenocarcinoma (3, 5).

The arteries supplying the prostate derive from the internal pudendal, inferior vesical, and middle hemorrhoidal arteries. The veins form a plexus around the sides and base of the

prostate and end in the hypogastric veins (4). The lymph vessels from the prostate drain into the sacral, external, and mainly internal iliac lymph nodes (4).

The autonomic innervations of the prostate derive from the pelvic plexuses; the parasympathetic visceral efferent and preganglionic fibers arise from the sacral levels (S2–S4) and the sympathetic fibers from the thoracolumbar levels (L1–L2). The parasympathetic nerves end at the acini and lead to prostatic secretion, whereas the sympathetic nerves stimulate prostatic smooth muscle contraction during ejaculation (4).

1.3 Normal histology of the prostate

The prostate is made of glandular and nonglandular components. In histologic sections, the peripheral zone forms about 70% of the glandular part, the central zone forms about 25% of the glandular prostate, and the transition zone forms about 5%, whereas the anterior fibromuscular zone is devoid of glandular tissue (5).

The glandular component of the prostate is composed of branching glands with ducts and acini. Microscopically, the ducts and acini cannot be reliably distinguished since they have a comparable caliber, spacing, and histologic appearance (5, 6).

The peripheral and transition zone ducts and acini are between 0.15 and 0.3 mm in diameter, and they have simple rounded contours with prominent undulations of the epithelial border. The undulations reflect the presence of corrugations of the wall, which are believed to provide for expansion of the lumina as secretory reservoirs (5, 6). Between the glandular spaces there is abundant fibromuscular stroma. The epithelial to stromal ratio of the peripheral and transition zone is 1:1 (5, 6).

Central zone ducts and acini are larger than those in the peripheral and transition zones; they are up to 0.6 mm or larger in diameter, they have polygonal contours, and they become progressively larger toward the capsule at the base of the prostate, often exceeding 1 mm in diameter. Intraluminal corrugations are more pronounced, and they partially subdivide the acini (5, 6). The ratio of epithelium to stroma is 2:1 (6).

The peripheral zone acini open through ducts into the distal prostatic urethra; the central zone ducts open mainly into the middle prostatic urethra, whereas the transition zone ducts open into the sphincteric part of the urethra (6).

The prostatic ducts and acini are lined with epithelial luminal secretory cells and basal cells. Scattered neuroendocrine cells are also present (5, 6).

Basal cells are markedly flattened cells that lie parallel to the underlying basement membrane; they are characterized by slender dark nuclei and little cytoplasm. They are

considered to be the pluripotent stem cells that can differentiate into luminal secretory and neuroendocrine cells (5, 7). Basal cells can undergo myoepithelial metaplasia, but they are not myoepithelial cells, as electron microscopy has shown that they do not contain muscle filaments (6).

Neuroendocrine cells are scattered endocrine-paracrine cells that are distributed along the basal cell layer and between secretory cells of the ducts and acini in all zones of the prostate (8). They are rich in serotonin granules and contain neuron-specific enolase. Subpopulations of these cells contain a variety of peptide hormones, such as somatostatin, calcitonin, and bombesin (8). Microscopically, they are difficult to identify if no special immunostains are used. Their biological role is unknown; they are presumed to have a paracrine function.

Luminal secretory epithelial cells represent the major cell type in the prostate. They are cubic to columnar, androgen dependent for growth, and generate a variety of products for the seminal plasma (6).

Prostatic specific antigen (PSA) and prostatic acid phosphatase (PAP) are produced by the secretory cells of the ducts and acini of all zones, whereas Pepsinogen II, tissue plasminogen activator, and lactoferrin are normally produced only in the ducts and acini of the central zone (6).

The cytoplasm of the normal luminal epithelial cells contains uniform, small, clear secretory vacuoles. In the peripheral and transition zone, the secretory vacuoles are more densely packed than in the central zone; therefore, in hematoxylin and eosin (H &E) staining for light microscopy, the cells of the peripheral and transition zones appear pale when compared to the central zone cells, which are darker (6).

The fibromuscular tissue of the prostate constitutes its proper stroma. The connective tissue is very scanty, with thin trabeculae between the muscular fibers in which the vessels and nerves ramify (6).

The stromal morphology differs between the central and peripheral zones, as well as between the peripheral and transition zones. The central zone stroma is the densest, and a sharp contrast is evident between the central zone stroma and the peripheral, loosely woven stroma (9).

The transition zone stroma is composed of compact smooth muscle bundles, in contrast to the adjacent loosely woven fibromuscular peripheral zone stroma (6). Stromal distinctions are less evident with age and may be obliterated by disease (6).

1.4 Benign prostatic hyperplasia

1.4.1 Epidemiology and prevalence

Benign prostatic hyperplasia (BPH) is an overgrowth of the epithelium and fibromuscular tissue of the prostate. BPH is a common problem in older men and can be responsible for considerable disability. The prevalence of histologically diagnosed BPH increases from 8% in men aged 31–40, to 40–50% in men aged 51–60, and to approximately 90% in men aged 81–90 (10). Reported data show that almost all men who live long enough will develop BPH. However, only 50% of men will develop macroscopic BPH, and only 50% of those will develop clinical symptoms (11).

The available literature on racial and regional incidence of BPH and the impact it has on individuals is somewhat contradictory. However, the age-related prevalence of histologic BPH, as determined by autopsy findings, is reportedly similar in several countries, despite differing racial mixes (11). The incidence of BPH is apparently lower in Chinese and Japanese men living in Asia than in the white population (12).

1.4.2 Etiology and pathogenesis

The pathogenesis of BPH remains largely unknown. Aging is the most significant risk factor of BPH; therefore, in a way, BPH can be considered a natural consequence of aging (13).

Various studies suggest a genetic link for BPH (12, 14). A 4-fold increase in the age specific risk has been reported for relatives of men who had undergone prostatectomy for BPH, whereas brothers of these men have a 6-fold increased risk when compared to men with sporadic BPH (12). Several possible causative mechanisms are considered responsible for BPH development and progression, such as hormonal mechanisms, stem cell differentiation, embryonic reawakening, metabolic syndrome, and inflammation/growth factor responses.

These mechanisms may act in synergy. For example, men castrated prior to puberty do not experience BPH, nor do men with genetically impaired androgen action or production.

1.4.3 Gross anatomy

BPH is a nodular regional growth, with variegated gross appearance resulting from the inhomogeneous and irregular mixture of glandular and stromal prostatic tissue. It consists of variably sized nodules that can be soft, firm, or rubbery, with a yellow-gray color (15).

Degenerative changes, such as calcifications and infarction, may also occur (15). The consistency and color of the nodules in BPH depends on is the presence or absence of prominent epithelial or stromal hyperplasia. If epithelial hyperplasia is predominant, then abundant luminal spaces create yellowish, soft, and spongy nodules that ooze a pale-white watery fluid. Predominant stromal hyperplasia, on the other hand, may be characterized by diffuse enlargement of numerous hard appearing, gray colored trabeculations, sometimes without prominent nodularity (15). The gross appearance of nodules in BPH is best presented in total prosectomies as they bulge from the cut surface upon transection.

BPH usually involves the transition zone of the prostate, and the nodules only occasionally arise from the periurethral tissue of the bladder neck. In the latter case, protrusion of bladder neck nodules into the bladder lumen is referred as median lobe hyperplasia (15). Very rarely, BPH nodules can develop in the peripheral zone (15).

1.4.4 Histopathology

Histologically, BPH is characterized by proliferation of the epithelial and stromal cells. *Franks* (16) emphasized the idea that BPH is a nodular disease, and based on the differing epithelial and stromal components, he described five histologic subtypes of prostatic hyperplasia: stromal (fibrous or fibrovascular), fibromuscular, muscular (leiomyoma), fibroadenomatous, and fibromyoadenomatous. The fibromyoadenomatous type is reportedly the most frequent histologic type, whereas the muscular type is the rarest (16). However, BPH is more commonly described as epithelial (glandular), mixed, and stromal (15).

Epithelial (glandular) hyperplasia is characterized by dilated and/or cystic glands, which frequently contain a secretion of glycoprotein nature, the so called corpora amylacea. The glands are composed of two main cell types: the secretory flat to cuboidal epithelial cells and the basal cells, which rest above the well-developed basal membrane (15). Three main patterns of glandular hyperplasia are recognized: *basal cell hyperplasia*, *the small gland pattern*, and *clear cell cribriform hyperplasia* (15).

Stromal hyperplasia of the prostate may be nodular or diffuse. Stromal nodules, which are considered as the first appearance of BPH, are found predominantly in the

suburothelial tissue, above the distal region of the verumontanum, although they have also been reported in the central zone (17). They present as well-circumscribed cellular masses of spindled cells, which can be arranged in bundles or whorls. Cytological atypia and mitoses are absent. Diffuse stromal hyperplasia is less common than the nodular form and is distinguished from stromal nodules only by being larger and with no clear borders merging with the surrounding normal fibrovascular stroma (17).

The mixed type of BPH is composed of both epithelial and stromal hyperplasia patterns, and it is the most common type of BPH (15). The earliest nodules that develop are usually found in the periurethral region and are typically stromal, composed of fibrous tissue mixed with smooth muscle. The proliferation of stromal nodules is then followed by hyperplasia of the glandular component. Therefore, in well developed BPH, the nodules are composed of varying proportions of both stromal and glandular elements (15).

1.4.5 Clinical features and management

The clinical symptoms of BPH result from the compression of the prostatic urethra and the consequent obstruction of the bladder outlet. The clinical syndrome that accompanies BPH is described as lower urinary tract symptoms (LUTS) (18). The severity of symptoms does not correlate with the degree of hyperplasia (18).

The most common LUTS are hesitancy, weak stream, nocturia, and incontinence (18).

BPH may be complicated by recurrent urinary tract infections, bladder stones, acute urinary retention, and, rarely, by irreversible renal insufficiency (18). About half of men with symptomatic BPH experience moderate to severe LUTS (19).

Management decisions are made according to the severity of symptoms and include medication, such as α 1-receptor antagonists and 5 α -reductase inhibitors, as well as surgical procedures. Transurethral resection of the prostate (TURP) is considered the benchmark of surgical treatment in BPH (18); nevertheless, other surgical procedures are used as appropriate, such as laser prostatectomy, transurethral incision of the prostate, and transurethral microwave (18).

1.5 Precursor and putative precursor lesions to prostatic carcinoma

Several morphological lesions have been proposed as precursor and putative precursor lesions of prostatic carcinoma. These are distinct morphologic entities and include prostatic intraepithelial neoplasia (PIN), atypical adenomatous hyperplasia (AAH) or adenosis, and proliferative inflammatory atrophy (PIA). However, PIN is currently the only accepted biological precursor of prostatic carcinoma, whereas AAH and PIA are considered pseudoneoplastic lesions that can mimic prostatic carcinoma.

1.5.1 Prostatic intraepithelial neoplasia

PIN is an abnormal proliferation of foci of cellular dysplasia without stromal invasion that occurs within prostatic ducts, ductules, and large acini (20). Based on the cytological characteristics of the cells, PIN is classified as high grade PIN (HGPIN) and low grade PIN (LGPIN) (20). The incidence and the extent of PIN increase with patient age (20-22).

HGPIN is the only accepted biological precursor of prostatic carcinoma (23). It precedes the onset of prostatic carcinoma by more than 10 years (21).

The available evidence indicates that some foci of PIN progressively gain the ability to invade or breach the basal cell layers, thereby transforming into invasive carcinoma. This is the so-called microinvasion (20, 22), which is observed in approximately 2% of high power microscopic fields of PIN samples (20).

The differential diagnosis of PIN includes lobular atrophy, postatrophic hyperplasia, atypical basal cell hyperplasia, clear cell cribriform hyperplasia, metaplastic changes associated with radiation, infarction, and prostatitis, as well as prostatic adenocarcinoma, cribriform adenocarcinoma, ductal carcinoma, and urothelial carcinoma involving the prostatic ducts and acini (20, 24).

Unlike the case for prostatic adenocarcinoma, basal cells are present in PIN. However, they can be discontinuous in H&E stained samples. Therefore, immunohistochemical (IHC) staining for basal cells with high molecular weight cytokeratins (HMWCK), detected with 34 β E 12 antibody or nuclear p63, is applied in making the differential diagnosis between PIN and prostatic carcinoma (20, 25).

Currently, PIN has no established routine treatment. Close follow up is recommended.

1.5.2 Atypical adenomatous hyperplasia

Atypical adenomatous hyperplasia (AAH), or adenosis of the prostate, is a pseudoneoplastic lesion that can mimic prostatic carcinoma because of its cytological and architectural features.

Initially, AAH was considered a precursor to prostatic carcinoma (26). However, no convincing progression from AAH to prostatic carcinoma has been demonstrated. Therefore, AAH is not currently considered a premalignant lesion, but rather a benign small glandular process that simulates prostatic carcinoma (27).

AAH occurs predominantly in the transition zone of the prostate; nevertheless, it can be found on rare occasions in the peripheral and the central zones.

AAH is grossly unrecognizable, whereas histologically it is typically a well circumscribed lesion, usually within or adjacent to hyperplastic prostatic nodules. It is typically composed of closely packed, small, pale acini that merge with larger, more complex glands. The lining epithelium of AAH glands is cuboidal to low columnar, and the basal cell layer is interrupted (27).

The differential diagnosis of AAH includes the presence of all small acinar prostatic proliferations, such as simple atrophy, the small cell type of benign prostatic hyperplasia, sclerosing adenosis, verumontanum mucosal gland hyperplasia, atypical small acinar proliferation, mesonephric remnants hyperplasia, basal cell hyperplasia, post-atrophic hyperplasia, nephrogenic adenoma, and radiation therapy and androgen therapy effects (27).

The clinical follow up of AAH suggests a benign outcome. If diagnosed on TURP or core needle biopsy, a clinical follow up, but not necessarily re-biopsy, is recommended (27).

1.5.3 Proliferative inflammatory atrophy

Prostatic atrophy (PA) is one of the most frequent mimics of prostatic carcinoma. It is most commonly found in the posterior lobe or the peripheral prostatic zone. The frequency of the lesion in autopsies is reported as 85% and the frequency increases with age (28). The etiopathogenesis of PA is unknown.

Morphologically, PA is classified into diffuse and focal atrophy. Diffuse atrophy is commonly referred to as hormonal atrophy; it occurs relatively uniformly throughout the entire prostate in response to castration or other forms of androgen withdrawal, as well as in response to radiotherapy. In diffuse atrophy, all acini of the gland are atrophic (28).

Focal atrophy is classified into simple atrophy with or without cyst formation, post-atrophic hyperplasia, partial atrophy, and mixed prostate atrophy lesions (29). Architecturally,

partial atrophy consists of crowded glands, often with a disorganized growth pattern. In contrast to complete focal atrophy, which is usually diagnosed at scanning magnification with light microscopy owing to the presence of the well-formed glands with a very basophilic appearance, partial atrophy has a pale cytoplasm lateral to the nuclei, giving rise to pale staining glands that more closely mimic cancer. Proliferative inflammatory atrophy (PIA) consists of foci of proliferative glandular epithelium with the morphological appearance of the simple atrophy or post-atrophic hyperplasia associated with inflammation (30).

De Marzo et al. (30) and *Putzi and De Marzo* (31) suggest that PIA may give rise to carcinoma indirectly, via development into PIN. Several other studies support the PIA relationship with prostatic carcinoma (32-34). *Tomas et al.* (34) analyzed the distribution frequencies of PIA vs. “proliferative atrophy” in prostatic carcinoma and BPH lesions in radical prostatectomy specimens and showed that the inflammatory subtype was significantly more frequent in prostates with carcinoma, whereas non-inflammatory proliferative atrophy was more frequently found in prostates with BPH.

Contrary to reported findings (30-34), however, *Billis* (35) reported no significant relation of atrophy to histologic (incidental) carcinoma or PIN, and he concluded that PA probably is not a premalignant lesion. A possible link between PIA and either PIN or prostatic carcinoma remains controversial in the literature.

1.6 Prostate cancer

1.6.1 Epidemiology

Worldwide, prostate cancer is the second most common cancer in men. According to the most recent GLOBOCAN (36) data, an estimated 1.1 million men worldwide were diagnosed with prostate cancer in 2012, accounting for 15% of cancers diagnosed in men.

Almost 70% of these cases occurred in more developed regions.

Prostate cancer incidence varies more than 25-fold worldwide; the reported rates are highest in Australia/New Zealand and Northern America (ASR 111.6 and 97.2 per 100,000, respectively), as well as in Western and Northern Europe (36). Incidence rates are also relatively high in certain less developed regions, such as the Caribbean (79.8), Southern Africa (61.8), and South America (60.1), but the rates remain low in Asian populations, with estimated rates of 10.5 and 4.5 in Eastern and South-Central Asia (36).

The most recent data report prostate cancer as the fifth leading cause of death from cancer in men. It comprises 6.6% of the total deaths in men globally (36). The mortality rates worldwide vary to a lesser extent (10-fold, from approximately 3 to 30 per 100,000) than is observed for incidence. The number of deaths from prostate cancer is higher in less developed than in more developed regions (36).

The high incidence of prostate cancer in developed countries is attributed to the practice of PSA testing and subsequent biopsy, which has become widespread in those regions. In the United States (US), prostate cancer death rates have been decreasing since the early 1990s in men of all races/ethnicities, though they remain more than twice as high in African Americans than in any other group (37). Mortality rates are generally high in predominantly black populations (Caribbean, 29 per 100,000 and sub-Saharan Africa, ASRs 19–24 per 100,000), very low in Asia (2.9 per 100,000 in South Central Asia, for example) and intermediate in the US and Oceania (36).

Unlike the clinical incidence, the age-specific prevalence of prostate cancer found at autopsy is relatively uniform across countries and ethnic groups, with contemporary studies indicating a rate as high as 80% by age 80 (38).

1.6.2 Etiology and risk factors

Despite a relatively high morbidity and mortality, the etiology of prostate cancer remains largely unknown. Prostate cancer risk factors can be classified as endogenous and exogenous, with some of the factors reflecting both endogenous and exogenous influences.

Endogenous risk factors include family history, hormones, race, aging, and oxidative stress, whereas exogenous risk factors include diet, environmental agents, occupation, and other factors (38). Nevertheless, only age, race, and a family history of prostate cancer are well-established risk factors for prostate cancer.

Age is an essential factor in prostate cancer. Men under 45 years of age are seldom diagnosed with prostate cancer, whereas the prostate cancer incidence increases progressively with age, with a peak around 65–70 years (38).

Cellular oxidants, such as free radicals and reactive oxygen species (ROS) that are produced during natural metabolic processes, are viewed as potentially damaging to DNA and can create an environment for mutagenesis and tumor initiation. In young, healthy individuals, most cells are equipped with adequate antioxidant defense mechanisms to protect against free radicals and ROS. However, aging is associated with a decline in ROS detoxification enzyme activities in most tissues (38).

Another well-established risk factor is race. The highest incidence rates for prostate cancer in the world are found in African-American men (39). In the US, the risk of developing and dying from prostate cancer is highest among blacks, intermediate among whites, and lowest among native Japanese (40). Race related differences in prostate cancer risk may be influenced by the exposure differences, particularly dietary, detection, and genetic differences.

African Americans have the highest intake of dietary fat, and this is considered to contribute to their higher risk of prostate cancer (41). By contrast, Japanese men consume a relatively low fat diet; however, as the fat content of Japanese diets has increased toward Western levels, the incidence of prostate cancer in Japanese men has increased as well.

Several studies have found that prostate cancer rates in different races shift toward those of the host country (38, 42).

Some of the differences in risk between races and countries may also reflect access to health care, especially regarding the stage of the disease and survival. Nevertheless, access to health care does not explain the higher incidence rate among African Americans compared to the white population in the US.

Several factors are all reported to play a role in the difference in the risk between races, including higher circulating levels of testosterone in African-American men than in their white counterparts, higher levels of sex hormone binding protein in African-Americans than in white men, a higher activity of 5 α -reductase in African-American and white men than in Japanese men, racial differences in IGF-I and IGF-binding protein-3, and differences in the allelic frequencies of the microsatellites at the AR locus (with shorter CAG microsatellite alleles in African men and longer CAG repeats in Japanese men), as well as larger content of vitamin A and D receptors in Japanese men (38, 42).

Family history is another well-established factor associated with increased prostate cancer risk. Risk is increased with a closer genetic linkage of a man to an affected relative, and with a greater number of relatives with prostate cancer. A meta-analysis study of 33 epidemiologic case control and cohort based studies reported an apparently greater risk for men with affected brothers than for men with affected fathers (43). One possible explanation was an X-linked recessive or autosomal recessive inheritance (43).

Another analysis of a Swedish cohort of more than 11.8 million individuals included 26,651 men with medically verified prostate cancer. Of the prostate cancer cases, 5,623 were familial cases. The age specific hazard ratios (HRs) for prostate cancer in these cases were 2.12 (95%CI, 2.05–2.20) for subjects with an affected father only, 2.96 (95% CI, 2.80–3.13) with an affected brother only, and 8.51 (95% CI, 6.13–11.80) with an affected father and two affected brothers (44). The highest HR of 17.74 (95% CI, 12.26–25.67) was seen in men with three brothers diagnosed with prostate cancer. The risks were even higher when the affected relative was diagnosed with prostate cancer before age 55 (44).

The risk of prostate cancer may also increase in men who have a family history of breast and/or ovarian cancer in a mother or sister. This association between family history of prostate cancer and breast/ovarian cancer in the same family may be explained, in part, by the increased risk of prostate cancer among men with BRCA1/BRCA2 mutations in a setting of hereditary breast/ovarian cancer or early-onset prostate cancer (45).

Exogenous factors, such as diet and nutrition, may contribute to prostate cancer development. Despite differences with respect to the selection of controls and the method of dietary assessment, several studies conducted in different countries, including the US, Canada, Japan, and Sweden, have concluded that high fat intake increases the risk of prostate cancer development. The proposed mechanisms involved are dietary fat-induced alterations in hormonal profiles, the effect of fat metabolites as protein or DNA-reactive intermediates, and dietary fat-induced elevation of oxidative stress (38).

Intake of vitamins and trace elements has also been studied in relation to prostate cancer. The reports are contradictory regarding vitamin A and C correlations with prostate cancer (38). Vitamin D deficiency, however, may be a risk factor for prostate cancer (38). Moreover, vitamin E (α -tocopherol) supplementation decreases serum androgen levels, which, in turn, may reduce the risk for prostate cancer (38, 46).

Lycopene, a dietary carotenoid that enters the body largely from the consumption of tomato foods, is found to play an important role in prostate cancer prevention. A lower risk for prostate cancer is reported in men who have higher plasma lycopene levels (38).

Trace elements, such as zinc and selenium, are considered to have a protective role with respect to prostate cancer. The levels of zinc and selenium are lower in the prostate with cancer than in non cancerous prostates (47, 48).

The mechanisms of action of zinc and selenium are not yet known, and the lower levels may be a result of prostate cancer itself (47, 48).

Gene-environment interactions in hormone synthesis, action, and metabolism represent another important factor in prostate cancer development. Two major hypotheses are proposed regarding the involvement of endogenous hormones in prostate cancer development.

The first holds that prolonged presence of androgens is linked to the risk of prostate cancer. The most potent androgen in the prostate is dihydrotestosterone (DHT), which is the active metabolite of testosterone. The effect of androgens on prostate cancer cell growth is thought to be mediated by modulation of growth factor expression and alteration of growth factor receptor levels (48). This idea is supported by the fact that men castrated prior to puberty and men with genetically impaired androgen action or production do not develop prostate cancer. Further support comes from the clinical observation that androgen withdrawal therapy constitutes the most effective therapy in men with prostate cancer.

The second major hormonal hypothesis is related to IGF-1 (insulin like growth factor-1). High levels of IGF-1 hormone, which mediates the action of growth hormone, have been associated with increased prostate cancer risk (49). Moreover, several concomitant medical conditions that alter the hormone levels in the organism have been related to a decreased risk for prostate cancer. For example, evidence supports a reduced risk for prostate cancer in men with cirrhosis, which is characterized by increased estrogen levels (49). A meta-analysis conducted by *Bansal et al.* (50) came to the conclusion that longstanding type 2 diabetes, characterized by low levels of insulin, is significantly inversely associated with prostate cancer risk in men.

1.6.3 Clinical presentation and diagnosis

Prostate cancer rarely causes symptoms early in the course of the disease. The presence of symptoms usually suggests locally advanced or metastatic disease; therefore, the clinical presentation of prostate cancer depends on the effects of the local growth of the tumor, the spread to regional lymph nodes via the lymphatic system, and the hematogenous dissemination to distant metastatic sites (51).

Local growth of the tumor may produce symptoms of urinary obstruction, such as decreased urinary stream, urgency, hesitancy, nocturia, and incomplete bladder emptying.

However, as men with prostate cancer are usually asymptomatic, these symptoms are more indicative of BPH than prostate cancer (51).

Prostate cancer may also present with symptoms of metastases, such as bone pain, pathologic fractures, or symptoms caused by bone marrow involvement (51).

Widespread screening has increased the number of prostate cancers identified in asymptomatic patients. Diagnosis in these cases is based on abnormalities in a screening for PSA and on the digital rectal examination (DRE) (52). PSA is a kallikrein-like serine protease produced almost exclusively by the epithelial cells of the prostate. PSA testing has revolutionized prostate cancer screening. It was initially introduced as a tumor marker to detect cancer recurrence or disease progression following treatment, and it became widely accepted for cancer screening by the early 1990s (53).

PSA levels may be elevated in men with prostate cancer because the PSA production is increased and because the tissue barriers between the prostate gland lumen and the capillary are disrupted, allowing a greater release of PSA into the serum. In the serum, PSA can be determined in three different molecular forms, such as total PSA, free PSA (not complexed to serum proteins), and complexed PSA (complexed to serum proteins α 2-macroglobulin and α 1-antichymotrypsin). Studies have estimated that elevations in total PSA can precede clinical disease by 5 to 10 years or even longer (54, 55).

PSA levels may be elevated in men with BPH, as well as in several benign transient conditions, and some of these, such as the DRE, ejaculation, bacterial prostatitis, prostate biopsy, and acute urinary retention, can affect the performance of PSA measurement as a screening test (54).

PSA has a half life of 2.2 days, and levels elevated by various benign conditions have variable recovery times. Therefore, PSA testing should be deferred accordingly (56).

Moreover, the level of PSA is a continuous parameter: the higher the value, the more likely is the existence of prostate cancer (56).

The traditional cutoff for an abnormal PSA level is 4.0 ng/mL. In a pooled analysis, the estimated sensitivity of a PSA cutoff of 4.0 ng/mL was 21% for detecting any prostate cancer and 51% for detecting high grade cancers (Gleason ≥ 8). Using a cutoff of 3.0 ng/mL increased these sensitivities to 32 and 68%, respectively. The estimated specificity was 91% for a PSA cutoff of 4.0 ng/mL and 85% for a 3.0 ng/mL cutoff (57). Overall, the positive predictive value (the proportion of men with elevated PSA who have prostate cancer) for a PSA level > 4.0 ng/mL is approximately 30%, meaning that slightly less than one in three men with an elevated PSA will have prostate cancer detected on biopsy. For PSA levels between 4.0 to 10.0 ng/mL, the positive predictive value is about 25%; this increases to 42 to 64 % for PSA levels > 10.0 ng/mL (58).

Some studies have suggested lowering the PSA cutoff because some men with PSA levels below 4.0 ng/mL and a normal DRE are found to have prostate cancer (58). However, other studies have confirmed that while lowering PSA cutoff would improve test sensitivity, a lower PSA cutoff would also reduce specificity, leading to far more false positive tests and unnecessary biopsies (59). Measurement of PSA velocity (the change in PSA over time) and PSA density (the PSA per unit volume of prostate), free PSA, and complexed PSA; calculation of free PSA/total PSA ratio; and using age- and race-specific reference ranges have been proposed to improve the diagnostic performance of PSA when levels are less than 10 ng/mL (52). Nevertheless, no consensus exists on using any of the PSA modifications, and none of them has been shown in clinical trials to reduce the number of unnecessary biopsies or improve clinical outcomes. The total PSA cutoff of 4.0 ng/mL has been the most accepted standard because it balances the tradeoff between missing important cancers at a curable stage and avoiding both detection of clinically insignificant disease and subjecting men to unnecessary prostate biopsies (52, 60). PSA serum levels are reported to correlate with the possibility of extraprostatic extension. No clear correlation, however, has been established between PSA serum levels and the prediction of extracapsular spread into the seminal vesicles or regional lymph nodes (61).

The DRE is another screening method that has long been used to diagnose prostate cancer. Abnormal findings with the DRE include nodules, asymmetry, or indurations. A DRE can detect tumors in the posterior and lateral aspects of the prostate.

Limitations of the DRE include the fact that only about 85% of prostate cancers arise peripherally, where they can be detected with a finger examination, as well as the fact that T1 cancers are nonpalpable by definition (62). The majority of cases detected by a DRE alone are clinically and pathologically advanced, and no controlled studies have shown a reduction in

the morbidity and mortality of prostate cancer when detected by a DRE at any age (62). Therefore, the DRE is used as a screening method for prostate cancer in combination with PSA serum levels.

The prostate cancer antigen 3 (PCA3) gene expresses a non-coding RNA. It was identified in 1999, and it is highly overexpressed in almost all prostate cancer tissue specimens, but not in the normal and hyperplastic tissue (62). The expression of PCA3, because of its high specificity, may eventually have a role in reducing unnecessary biopsies, but data are presently insufficient to support its routine use (62).

Transrectal ultrasonography (TRUS) is an outpatient procedure that has been tested as a possible screening method for prostate cancer. However, its low sensitivity and low positive predictive value have precluded its recommendation as a primary screening test. One study was reported that almost 40% of prostate cancers would have been missed if prostate biopsies had been performed only in men with suspicious findings on TRUS (58). Today, TRUS is typically used to guide prostate biopsies rather than as a screening test (62).

In making a prostate cancer diagnosis, the need to perform prostate biopsy is determined based on the PSA serum level and/or a suspicious DRE. TRUS-guided core needle biopsy is the standard biopsy method.

The average number of prostate core needle biopsies has risen from 2 to 6 to 12 over the past 20 years (63). A typical transrectal sextant biopsy involves samples from the parasagittal plane on the right and left sides of the base, midzone, and apex of the prostate (64). Several studies have confirmed that sampling more cores improves the cancer detection rate without increasing morbidity. As a result, today's biopsy protocols typically involve extracting 10–12 cores per biopsy, often from the standard sextant and from other areas of the peripheral, transition, or anterior prostate zones (64).

The primary purpose of needle biopsy has shifted from targeting of specific areas of concern on rectal examination to the systematic mapping of the prostate for cancer involvement and quantity (63, 65).

The use of TURP as a diagnostic method for prostate cancer has declined in recent years. Repeat transrectal core needle biopsies are recommended instead (64, 66).

Screening for prostate cancer has increased the number of detected early prostate cancers; however, this has created a constant concern regarding the potential harm from repeated biopsies in a patient with elevated PSA but negative core needle biopsies, as well as the risk of over-diagnosis.

In 2012, the American Urological Association reported a range from 0.6 to 4.1% of infectious complications in patients with repeated prostate needle biopsies (66). On the other hand, over-diagnosis presents a particular concern because most men with prostate cancers detected by screening have early stage disease and will be offered aggressive treatment. One US study examined the number of men diagnosed and treated for prostate cancer each year after 1986 (the year before PSA screening was introduced) and until 2005 (67) and documented that approximately 23 men had to be diagnosed and 18 men treated for prostate cancer to prevent one death (67). This led the authors to conclude that most additional cases found since 1986, in fact, represent over-diagnosis.

1.6.4 Gross anatomy

The identification of prostate cancer is often difficult or impossible by gross inspection. Any grossly visible tumors are usually firm, solid, and range in color from white-gray to yellow-orange (68).

Prostatectomies reveal that prostate cancer is commonly multifocal and is mainly found in the peripheral zone, followed by the transition zone and the central zone. Prostate cancer foci must be at least 5 mm in diameter for a reliable gross identification, although accurate identification may still be difficult or impossible even for much larger tumor areas (68).

1.6.5 Histopathology

Adenocarcinomas constitute about 90–95% of prostate cancer. Most adenocarcinomas are of the acinar type, with about 1% belonging to particular variants. The group of non-acinar prostatic carcinoma accounts for about 5–10% of carcinomas that originate in the prostate (68).

1.6.5.1 Acinar prostatic adenocarcinoma

Acinar adenocarcinomas of the prostate range from well- differentiated gland forming tumors, where it is often difficult to distinguish them from benign prostatic glands, to poorly differentiated tumors, difficult to identify as being of prostatic origin.

The histopathological diagnosis of prostatic adenocarcinoma rests on constellation of architectural, nuclear, cytoplasmic and intraluminal features (68). Features identifying prostatic lesions as malignant are infiltrative pattern, small and/or crowded glands, prominent

nucleoli, absence of basal cell layer, nuclear enlargement, marginated nucleoli, multiple nucleoli, hyperchromasia, mitoses, apoptic bodies, amphylic cytoplasm, blue-tinged mucinous secretions, pink amorphous secretions, intraluminal crystalloids, perineural invasion, glomerulations, mucinous fibroplasia and periacinar retraction clefts.

The infiltrative growth pattern, presence of macronucleoli, and absence of the basal cell layer are considered as major diagnostic criteria for prostatic adenocarcinoma (68-72).

However, only three characteristic features of prostatic adenocarcinoma such as perineural invasion, mucinous fibroplasia (collagenous micronodules) and glomerulations have not been described in benign prostatic glands (68, 71).

Usual acinar adenocarcinoma lacks desmoplastic or myxoid stromal response, and the evaluation of the stroma is not useful in the diagnosis of the acinar adenocarcinoma.

The Gleason grading system is the predominant histological grading system in use for prostatic adenocarcinoma. It was developed by Dr Donald F Gleason, and members of the Veterans Administration Cooperative Urological Research Group (VACURG) and further refined by Mellinger in 1977 (73-75). It is a 5-tier grading system that correlates with tumor differentiation and is solely based on the histological/architectural pattern of arrangement of malignant cells in H&E stained prostatic tissue sections. *Gleason et al.* (73-75) have demonstrated that prognosis of prostate cancer is intermediate between that of the most predominant pattern and that of the second most predominant pattern in prostatic adenocarcinoma.

These patterns are graded from 1 (most differentiated) to 5 (least differentiated) and the two grades are added; if only one grade presents in the tissue sample, it is multiplied by two to give the score which can range from 2 to 10. The initial grading of prostatic adenocarcinoma is performed by light microscopy at low magnification using 4x or 10x lens, after which the 20x lens may be used to verify the grade (75).

As the diagnosis and treatment of prostate cancer underwent an enormous evolution over time, in 2005 the International Society of Urological Pathology (ISUP) proposed several modifications to the Gleason system (76).

Gleason pattern 1, is a nodular or circumscribed mass with rounded borders, of very well differentiated closely packed but separate, uniform, rounded to oval, medium –sized acini and with no infiltrating acini into the surrounding stroma. Originally *Gleason et al.* (75) have reported this pattern to be present in 3.5 % of their cases. The 2005 ISUP consensus (76) recommended that Gleason score of 1+1=2 is a grade that should not be diagnosed regardless of the type of the specimen, with rare exceptions. Moreover, most cases diagnosed as Gleason

score $1+1=2$ in the era of Gleason are considered today as atypical adenomatous hyperplasia (77).

Gleason pattern 2, is a well differentiated pattern that forms less well-defined masses that are not as circumscribed as pattern 1, with a tumor stroma boundary that is not as rounded as in pattern 1, and with minimal infiltration at the periphery. Compared to Gleason pattern 1, the malignant glands of Gleason pattern 2 display a higher degree of separation by stroma with an average separation distance of less than one gland diameter and there is increase in variability in gland size and shape (76, 77).

The original description pattern and the standardized drawing of pattern 2 indicate that focal cribriform structures might be present (75). In contrast to the original Gleason's description, the 2005 ISUP consensus was that cribriform patterns are not allowed within Gleason pattern 2 (76).

Pattern 2 is usually reported admixed with pattern 3 to yield a Gleason score of 5. In a very small percentage of cases pattern 2 is pure, or is intermingled with pattern 1 (75, 76). Whereas a composition of pattern 2 with pattern 4 or 5, is extremely uncommon (68).

The 2005 ISUP consensus was that a Gleason score of $2+2=4$ or $1+2=3$ should be "rarely, if ever" assigned in core needle biopsies (76). A diagnosis of Gleason score 3 and 4 is poorly reproducible, has a poor correlation with prostatectomy grade at resection and may misguide clinicians and patients into believing that the patient has an indolent tumor.

Moreover, the major limitation of rendering a diagnosis of Gleason score 4 on needle biopsy is that one cannot see the entire edge of the lesion to determine if it is completely circumscribed (76).

Gleason pattern 3, is a moderately differentiated grade, and presents the most common pattern of growth of prostatic adenocarcinoma. Originally, Gleason pattern 3 was described as having three distinctive appearances which were designated as patterns 3A, 3B, and 3C. An increased aggressiveness of pattern 3 carcinoma proceeding from pattern 3A to 3B to 3C was considered (75), however, no data have been published in support of this. These patterns have no clinical significance, therefore, it is not necessary to specify patterns 3A, 3B and 3C.

Gleason pattern 3A consists of infiltrating, medium-sized, single glands with irregular shape and spacing and a haphazard, irregular extension of glands into stroma. The intervening stroma is usually greater than one gland diameter. However, densely packed gland arrangements are allowable in pattern 3, but there should be evidence of infiltrative growth. The shape of glands is quite variable, with angular, elongated, and twisted forms described (75).

In Gleason pattern 3B, the glands are similar to but smaller, than in pattern 3A. These glands should still have the capability of forming glandular luminal spaces (75).

In Gleason pattern 3C, expanded cylinders or ducts with masses of cribriform or papillary tumor were originally described (75). In contrast to Gleason pattern 4 cribriform glands, the edges of these masses should not be ragged and infiltrative, but rather smooth. If necrosis is visible, this is assigned as pattern 5, and not pattern 3 (75).

The 2005 ISUP (76) consensus departure from the original Gleason classification system is that “individual cells” are not allowed within Gleason pattern 3. A further change is that the consensus panel required extremely stringent criteria for the diagnosis of Gleason cribriform pattern 3. The criteria set to diagnose cribriform pattern 3 are rounded, well-circumscribed glands of the same size of normal glands. The consensus was that most of cribriform patterns fall into Gleason pattern 4 with only rare cribriform lesions satisfying diagnostic criteria for cribriform pattern 3 (76).

Gleason pattern 3 is usually found in pure form, such that the most common Gleason score is 3+3=6. It can also be seen in combination with low-grade pattern 2 for a score of 5 or with pattern 4 to yield a score of 7. Overall, Gleason scores of 5–7 with embedded pattern 3 are the most common histologic grades of prostatic adenocarcinoma (76, 77).

Gleason pattern 4, is a high-grade and poorly differentiated carcinoma growth. Two histological appearances 4A and 4B, were originally described (75). In Gleason pattern 4A the cellular arrangements can be fused microacinar, cribriform, or papillary with ragged edges or outlines of the invasive periphery (75). Carcinoma growing in this manner, but with cleared cytoplasm, was described as pattern 4B, and could simulate renal cell carcinoma of clear cell type (hypernephroma). Thus, Gleason termed this variant as the hypernephroid or hypernephromatoid pattern (75). The nuclei in pattern 4 may be deceptively bland, with little nucleomegaly and no nucleolomegaly.

In these cases, highly infiltrative small, fused glands should be a clue to the high-grade nature of the carcinoma (75). A controversial area where a consensus was reached in, was that ill-defined glands with poorly formed glandular lumina also warrant the diagnosis of Gleason pattern 4 (76). The ISUP consensus was that only a cluster of such glands, where a tangential section of Gleason pattern 3 glands cannot account for the histology, would be acceptable as Gleason pattern 4. It was also noted that in most cases ill-defined glands with poorly formed glandular lumina are accompanied by fused glands. Whereas, very small, well-formed glands still are within the spectrum of Gleason pattern 3. Gleason pattern 4 closely resembling renal

cell carcinoma (hypernephromatoid pattern) makes up only a very small percentage of Gleason pattern 4 cases (76).

Pattern 4 is most often combined with pattern 3 to yield a score of 7, which is currently one of the most commonly assigned Gleason scores.

Description of the amount of pattern 4 in the setting of Gleason score 7 (3+4 versus 4+3) is prognostically important. Gleason score 7 (3+4) and Gleason 7 (4+3) are considered separately for prognostic reasons (77).

Pure high-grade disease, where there is pure pattern 4 or mingling with pattern 5 to produce scores of 8 and 9, is less common. Pattern 4 is hardly ever found with well-differentiated pattern 2 (76).

Gleason pattern 5, is the most poorly differentiated pattern of prostatic carcinoma, which originally was described in two forms 5A and 5B (73, 75). There is no need to specify 5A and 5B as the distinction is solely for the purpose of grade 5 diagnostic recognition, and has no clinical importance. Pattern 5A resembles the comedo type of intraductal carcinoma of the breast, with smooth, rounded masses, cords or cylinders of carcinoma. The necrosis is typically central, being surrounded by papillary, cribriform, or solid masses of carcinoma (77). The appearance can be similar to pattern 3C except for the presence of necrosis. Some cases of pattern 5A actually represent comedo intraductal prostatic carcinoma or in situ spread of ductal adenocarcinoma since basal cells can be observed, but in the Gleason scheme, these designations are not used, and pattern 5A is just termed a Gleason pattern 5 prostatic adenocarcinoma. Pattern 5B is comprised of ragged sheets of anaplastic adenocarcinoma cells and this form is so poorly differentiated that only a few small glandular lumina or signet-ring cells may be present to indicate adenocarcinoma rather than a poorly differentiated malignant neoplasm of unknown cell type (77).

The 2005 ISUP consensus was that cribriform masses with comedonecrosis should be regarded as Gleason pattern 5 prostatic adenocarcinoma (76). However, one must be stringent as to the definition of comedonecrosis, requiring intraluminal necrotic cells and/or karyorrhexis.

Pattern 5 is most often found with pattern 3, with a resultant score of 8. Less common is pure pattern 5 or comingling with pattern 4, to yield scores of 10 and 9, respectively.

Gleason scores 9 and 10 are usually associated with high clinical stage disease and with clinically detectable cancer outside the prostate, either locally or in the form of metastatic disease (77).

In 2014, pathology experts gathered in a consensus conference to update the grading of prostate cancer, last revised in 2005. The 2014 ISUP major consensus was a new grading and terminology for the prostate cancer grading system (78). The new classification simplified the number of grading categories from Gleason scores 2 to 10, with even more permutations based on different pattern combinations, to grade groups 1 to 5. The lowest prostate cancer grade according to the 2014 ISUP consensus is 1 and not 6 as in Gleason grading system (78).

The new grades would, for the foreseeable future, be used in conjunction with the Gleason system (78).

Gleason scores can be grouped and arranged in prognostic groups, as presented in Table 1, with group I being the most favorable to group V the least favorable (79).

Table 1. Gleason score prognostic groups

Gleason score ≤ 6	Prognostic group grade I
Gleason score 3+4=7	Prognostic group grade II
Gleason score 4+3=7	Prognostic group grade III
Gleason score 8	Prognostic group grade IV
Gleason score 9-10	Prognostic group grade V

1.6.5.2 Histological variants of prostatic carcinoma

Histological variants of prostatic carcinoma have been variously defined. Two groups of variants are recognized in the WHO 2004 classification (68). The first group comprises histological variants of usual acinar adenocarcinoma and the second group consists of non-acinar carcinoma variants. Other variants of prostatic carcinoma, not present in the 2004 WHO classification, have been described, such as microcystic adenocarcinoma, prostatic intraepithelial neoplasia-like adenocarcinoma, large-cell neuroendocrine carcinoma, and pleomorphic giant cell carcinoma (80).

Variants of usual acinar adenocarcinoma, as defined in 2004 by the World Health Organization (WHO), include colloid (mucinous), signet ring cell, atrophic, pseudohyperplastic, foamy, lymphoepithelioma-like, and oncocytic carcinomas (68).

Colloid (mucinous) variant -Focal mucinous differentiation is noticed in about one third of prostate cancers. However, only when 25% of the tumor consists of pools of extracellular acidic type mucin can the term mucinous carcinoma be implied. In biopsy material, which may not be reflective of the entire lesion, these tumors should be diagnosed as

carcinomas with mucinous features (68). ‘Colloid variant’ is considered by *McNeal* as a Gleason grade 4 carcinoma (81). However, Gleason grading is recommended only for the nonmucinous components.

Signet-ring cell variant - Signet-ring cell carcinoma of the prostate is very rare. A small number of signet-ring cells are found in usual acinar adenocarcinoma, but the designation is only applied when at least 25–50% of the tumor is composed of signet-ring cells (68, 80). This tumor is associated with other types of poorly differentiated prostate cancers and some authors believe that this change is part of the spectrum of the appearance of prostatic carcinoma and should not be regarded as a subtype of specific significance (80).

Signet-ring cell carcinoma cells may be arranged in sheets, as small clusters, or as single cells and are characterized by clear cytoplasmic vacuoles that displace the nucleus at one side (68, 80). Signet-ring cell areas are considered Gleason grade 5 (68, 82).

Atrophic variant- Adenocarcinoma of the prostate with atrophic features resembles benign atrophy owing to its scant cytoplasm, where the nuclei occupy almost the entire cell height (68, 80). The most reliable criteria to establish a diagnosis of this variant are (i) an infiltrative pattern of growth, (ii) the presence of macronucleoli, (iii) increased nuclear size, (iv) the presence of the adjacent, nonatrophic cancer, and (v) lack of a desmoplastic stromal response (68, 80). Most atrophic carcinomas are associated with nonatrophic Gleason score 6 adenocarcinoma (68, 80).

Pseudohyperplastic variant - Pseudohyperplastic prostatic carcinoma is characterized by closely packed, complex, large gland formations with papillary infoldings, luminal undulations, branching, and cystic dilatation, and it resembles BPH (68, 80, 83). The recognition of carcinoma with this pattern is based on an architecture that includes numerous closely packed glands lined with malignant cells that show significant nucleomegaly and nucleolomegaly. Basal cells are completely lacking (68). Despite its benign appearance and lower Gleason score (median 5), the pseudohyperplastic variant can exhibit aggressive behavior (68, 80).

Foamy gland variant - Foamy gland carcinoma is an unusual variant of prostatic carcinoma, characterized by a very low nuclear to cytoplasmic ratio, dense hyperchromatic nuclei, abundant xanthomatous cytoplasm (containing no lipid, but empty vacuoles instead), an architectural pattern of crowded or infiltrative glands, and frequently present dense pink acellular secretions (80, 84). Most cases of foamy gland carcinoma are associated with usual acinar adenocarcinoma of higher grade, so this variant is best classified as an intermediate grade carcinoma (68).

Lymphoepithelioma-like variant - The terms lymphoepithelioma-like carcinoma, lymphoepithelioma, and medullary carcinoma are implied for undifferentiated PSA positive carcinoma with a syncytial pattern associated with dense lymphocytic infiltration (68). This type of carcinoma is of uncertain clinical significance and therefore no assignment of Gleason score is recommended (82).

Oncocytic variant - Only a few cases of prostatic adenocarcinoma with oncocytic differentiation have been reported (68, 80). The tumor cells have round to ovoid hyperchromatic nuclei and abundant eosinophilic granular cytoplasm that contains a great number of mitochondria. The cells immunohistochemically express PSA and PAP, but no neuroendocrine markers (68, 80). A high Gleason grade has been reported and the clinical behavior does not differ from that of usual acinar adenocarcinoma (80).

The group of non-acinar carcinoma histological variants or types of prostatic carcinoma accounts for about 5–10% of carcinomas that originate in the prostate. These include ductal adenocarcinoma, sarcomatoid carcinoma, urothelial carcinoma, squamous and adenosquamous carcinoma, basal cell carcinoma, and small cell (neuroendocrine) carcinoma (68).

Ductal adenocarcinoma- Prostatic ductal adenocarcinoma is a histologic subtype of prostatic adenocarcinoma. The pure ductal adenocarcinoma accounts for about 0.2–0.8% of prostatic adenocarcinomas, whereas ductal differentiation occurs in approximately 5% of prostatic carcinomas (68, 80). It can be located centrally around the prostatic urethra or is more frequently located in the periphery, admixed with usual acinar adenocarcinoma.

Histologically, it is characterized by large glands lined by a single layer of pseudostratified tall columnar cells with abundant cytoplasm. It can display a variety of architectural patterns, which often coexist: papillary, cribriform, individual gland, solid pattern, and PIN like pattern, with the papillary and cribriform pattern being the most common (68, 85). Ductal adenocarcinomas are not typically graded, they are most equivalent to Gleason pattern 4, and in cases with comedo necrosis, they are equivalent to Gleason pattern 5, except for PIN like patterns which behave like Gleason pattern 3 (68, 85). Notably, prostatic ductal adenocarcinoma may have a peripheral layer of basal cells (68, 85). This means that differentiation of PIN from this lesion should depend on complex architectural characteristics and cytological features, rather than on the presence of a basal cell layer (68, 85).

Sarcomatoid variant (carcinosarcoma, metaplastic carcinoma)- Sarcomatoid carcinoma and carcinosarcoma are often used as synonyms. Sarcomatoid carcinoma is

composed of both malignant epithelial and malignant spindle cells and/or mesenchymal elements (68). In most cases, these tumors develop in older men after hormonal and radiation therapy for usual acinar adenocarcinoma, so a sarcomatoid transformation could be favored (68, 80, 82). The sarcomatoid component is considered to be Gleason grade 5, whereas the glandular element is assigned a grade according to the usual rules and is almost always a high grade (82). The most frequent mesenchymal elements are osteosarcoma, leiomyosarcoma, and chondrosarcoma (68). The major differential diagnosis is primary prostatic sarcoma and the prognosis is very poor (68).

Urothelial carcinoma - About 0.7–2.8 % of prostatic tumors in adults are reported to be primary urothelial carcinoma of the prostate (68, 86). Primary urothelial carcinoma is usually located within the proximal prostatic ducts, and it is usually locally advanced at the time of diagnosis (68, 86). The immunoprofile corresponds to that of the bladder urothelial neoplasms in that the tumor cells are negative for prostatic markers and positive for CK7, CK 20 and high molecular weight cytokeratin (HMWCK) or P63 in up to 50% of the cases (68, 86).

Squamous and adenosquamous carcinoma - Primary squamous cell carcinoma (SCC) of the prostate is a very rare tumor (68). It has been reported in the setting of *Schistosomiasis* infection. SCC may originate in the periurethral glands or in the prostatic glandular acini, probably from the lining basal cells, which show a divergent differentiation pathway (68). Its histology is similar to that of other organs and its differentiations may be variable; however, keratinization is rare (80, 82). Adenosquamous carcinoma represents a combination of SCC and glandular carcinoma (68) and is another very rare cancer of the prostate. About 50% of the reported cases occurred after radiation and hormonal therapy (68). Nevertheless, some cases are reported that have not been associated with therapy (68, 82). Squamous and adenosquamous carcinomas of the prostate are not Gleason graded (68, 82).

Basal cell carcinoma- Basal cell lesions in the prostate span a wide range from obviously benign basal cell hyperplasia through varying ranges of atypia to lesions that have been described as basal cell carcinoma (BCC) and adenoid cystic carcinoma. The mean age of cases reported with basal cell carcinoma is 50 years (range 28–78 years) (87). Gleason grading of these tumors is not recommended (82).

Small cell (neuroendocrine) carcinoma -Neuroendocrine differentiation in prostatic carcinoma can appear in three forms, as *a*) focal neuroendocrine differentiation in usual acinar adenocarcinoma, *b*) carcinoid tumor (a WHO well-differentiated tumor) and *c*) small cell neuroendocrine carcinoma (a new WHO classification of poorly differentiated neuroendocrine

carcinoma) (68). Small cell carcinoma is reported mainly in patients with a previous history of hormonally treated usual acinar adenocarcinoma. Histologically, it is identical to small-cell carcinomas of the lung, as the tumor grows in sheets or nests with geographic areas of necrosis and the cells are characterized by a high mitotic rate and frequent apoptotic bodies (82). The average survival of patients with small cell carcinoma is less than a year (68). Small cell carcinomas of the prostate are not assigned a Gleason grade (69, 82).

Microcystic adenocarcinoma, prostatic intraepithelial neoplasia-like adenocarcinoma, large-cell neuroendocrine carcinoma, and pleomorphic giant cell carcinoma are recently characterized variants of prostatic carcinoma not present in the 2004 WHO classification (80).

Microcystic adenocarcinoma is a variant of usual acinar adenocarcinoma, which can be deceptively benign-looking at low magnification. Histologically, it consists of cystically dilated and rounded expansions of malignant glands, with a flat luminal cell lining layer. The microcystic glands are typically adjacent to usual acinar adenocarcinoma (80, 88). Atrophic features are commonly seen, although most of the microcystic adenocarcinoma epithelial cells have a moderate amount of cytoplasm. Gleason grade 3 is the predominant grade of the adjacent nonmicrocystic malignant glands (80, 88).

Prostatic intraepithelial neoplasia (PIN)-like adenocarcinoma resembles PIN in gland architecture, with stratified epithelium. It appears similar to the flat, tufted, and micropapillary patterns of PIN; however, the glands are more crowded than in PIN and the immunoprofile is that of adenocarcinoma, with IHC stains for basal cells being completely negative (89, 90).

Large cell neuroendocrine carcinoma (LCNEC) is a very rare variant of prostatic carcinoma. It has usually been reported in patients with hormonally treated prostatic adenocarcinoma (91). Similar to lung LCNEC, it is composed of sheets and ribbons of cells with large nuclei with coarse chromatin and prominent nucleoli; the cells show high mitotic activity and prominent necrosis. These tumors are immunopositive for chromogranin, synaptophysin, CD 56, and AMACR. Focal PSA and PAP positivity may also be noted. The prognosis is very poor (91).

Pleomorphic giant cell adenocarcinoma is composed of giant pleomorphic nuclei (92). It shows variable PSA staining, and the disease course is reported to be very aggressive (92).

1.6.6 Molecular and genetic alterations

Numerous molecular and genetic alterations have been implicated in prostatic carcinoma, which is commonly a multifocal tumor. The analysis and comparison of the genomic landscape within prostates has revealed independent tumor origins in these tumor foci in several studies (93-95). *Gundem et al.* (96), however, in a whole-genome sequencing of multiple metastatic sites from 10 tumors, have revealed that 40–90% of the total mutations in metastatic prostatic carcinoma have a common clonal origin.

These findings imply that metastases originate commonly from only one tumor focus.

Linkage analysis and genome wide association studies have identified several gene loci related to hereditary prostatic carcinoma (HPC). Prostate cancer susceptibility genes associated with HPC have been mapped to RNSAEL/HPC1 at 1q24-25, MSRI at 8p22-23, HPC2/ ELAC2 at 17p11, and HPC at Xq27-28 (97-99). Downregulation of these genes is reported in HPC.

Small mutations across tumor suppressor genes, such as SPOP (found in 10.1% of samples), TP53 (3.6%), ATM (2.2%), MED12 (3.6%), FOXA1 (2.9%), and COL5A1 (2.2%), have been identified in prostatic carcinoma (97, 98).

A large number of studies have identified several copy number alterations (CNA) and chromosomal rearrangements associated with prostatic carcinoma. Comparative genomic hybridization has shown gains and losses of chromosomal regions, including gains at 8q and losses at 3p, 6q, 8p, 10q, 13q, 16q, and 17p in prostatic carcinoma. Key regulatory genes within these chromosomal regions have been mapped to undergo CNA, including NKX3.1 at 8p21, MYC at 8q24, and PTEN at 10q23 (99). The frequency of CNA in prostatic carcinoma is significantly higher than that of point mutations, suggesting that carcinogenesis and progression of prostatic carcinoma is primarily a result of chromosomal rearrangements (99).

One key modification associated with prostate carcinogenesis is trimethylation of lysine residue 27 of histone H3 (H3K27-me3), a key oncogenic driver of advanced disease and metastasis (100). Increased levels of H3K27-me3 in prostatic carcinoma are associated with repression of tumor suppressor genes such as DAB2IP (100).

Chromosomal rearrangements that activate members of the ETS family of transcription factors (ERG, ETV1, and ETV4) have been identified in the majority of prostatic carcinomas (99). The most common of these rearrangements creates a TMPRSS2-ERG fusion gene (101). The frequency of TMPRSS2-ERG fusions is reported as 16-19% in PIN lesions, and 30–79% in localized prostatic carcinoma (23). This rearrangement corresponds to an early event that predisposes to the clinical progression of prostatic carcinoma.

The Akt/mTOR and Erk (p42/44) MAPK signaling pathways are frequently upregulated in prostatic carcinoma (99, 102). Mutations of RAS or RAF are also reported in advanced prostatic carcinomas (102). Aberrant tyrosine kinase signaling, particularly through Her2/Neu or SRC tyrosine kinases, has been implicated in aggressive disease, progression to metastasis, and castration resistance. Consequently, it has also been implicated as a key therapeutic target in patients with advanced prostatic carcinoma (103, 104).

The polycomb group gene EZH2 encodes a histone lysine methyltransferase that is frequently upregulated in advanced prostatic carcinoma—in some cases through gene amplification—and it is associated with aggressive tumors (105). EZH2 target genes, such as E-cadherin and DAB2IP, are associated specifically with metastasis in prostatic carcinoma (106-108).

Telomere shortening is another somatic DNA change that is seen in prostatic carcinoma, but not in benign prostatic tissue (109).

Silencing of the gene encoding glutathione-S-transferase Pi 1 (GSTP1), by hypermethylation of the promoter region, is linked to prostate carcinogenesis. Furthermore, GSTP1 promoter methylation is now being used in molecular diagnosis as a biomarker for prostate cancer in bodily fluids such as urine and semen (110).

Nevertheless, the high intra tumoral heterogeneity and multifocality in primary tumors, as well as the long course of the disease from diagnosis to metastasis or lethality, presents a significant challenge regarding the application of genomic medicine to prostate cancer.

1.6.7 Immunohistochemistry

Immunohistochemistry (IHC) is an ancillary technique useful in the diagnosis of prostatic carcinoma and an important tool for scientific research. IHC identifies discrete tissue components and allows the visualization of the distribution and localization of specific cellular components within cells, and in the proper tissue context, by the interaction of target antigens with specific antibodies tagged with a visible label.

The loss of basal cells in prostatic carcinoma is one of the most important diagnostic hallmarks of malignancy, and the use of basal cell markers, such as p63, HMWCK (high molecular weight cytokeratin), and CK5/6, is recommended as an adjunct for confirming the diagnosis of prostatic carcinoma. It is particularly recommended with core biopsies, which may present a diagnostic challenge (23, 24). Nevertheless, several benign mimickers of

prostatic carcinoma, such as atrophy, atypical adenomatous hyperplasia, nephrogenic adenoma, and mesonephric hyperplasia, can stain negatively for these markers (23).

Another useful marker is alpha-methyl-CoA racemase (AMACR), which is commonly overexpressed in prostatic carcinoma, whereas benign prostatic tissue and PIN usually show minimal to absent expression (23, 24, 111). In addition, AMACR expression has been demonstrated in atypical adenomatous hyperplasia/adenosis and nephrogenic adenoma of the prostate (24). A double-color triple antibody (AMACR, HMWCK and p63) cocktail is also helpful in making the diagnosis in suspicious cases of prostatic carcinoma. With this cocktail, prostatic carcinoma demonstrates red nuclear and cytoplasmic staining (24).

Prostate specific antigen (PSA) and prostate acid phosphatase (PAP) are valuable immunohistochemical markers of prostatic differentiation. PSA is diagnostically helpful in distinguishing prostatic adenocarcinomas from other neoplasms secondarily involving the prostate, and in establishing prostatic origin in metastatic carcinomas of unknown primary (68). PSA is also helpful in excluding benign mimics of prostatic carcinoma. PAP and PSA have similar diagnostic utility. PAP is primarily reserved for cases of suspected prostatic carcinoma in which the PSA stain is negative.

Androgen receptor (AR) is an androgen binding protein complex occurring in prostatic glandular, basal, and stromal cells. Most invasive prostatic adenocarcinomas are immunoreactive for AR (68). However, AR is not in routine clinical use.

1.6.8 TNM staging system

The tumor, node, metastasis (TNM) staging system is most commonly used to describe the size and spread of a tumor. The TNM staging system was first introduced in 1992 by the American Joint Committee on Cancer (AJCC) and the Union for International Cancer Control (UICC) (112). The TNM classification for prostate cancer is presented in Table 2.

Table 2. TNM Classification for prostate cancer

Clinical T	
Tx	Primary tumor cannot be assessed
T0	No evidence of primary tumor
T1	Clinically in apparent tumor not palpable or visible by imaging
T1a	Tumor incidental histologic finding in $\leq 5\%$ of tissue resected
T1b	Tumor incidental histologic finding in $>5\%$ of tissue resected
T1c	Tumor identified by needle biopsy (because of elevated prostate specific antigen [PSA] level)
T2	Tumor confined within prostate; tumors found in 1 or both lobes by needle biopsy but not palpable or reliably visible by imaging
T3	Tumor involves one-half of 1 lobe or less
T3a	Tumor involves more than one-half of 1 lobe but not both lobes
T3b	Tumor involves both lobes
T4	Tumor extends through the prostatic capsule; invasion into the prostatic apex, or the prostatic capsule is classified not as T3 but as T2
Pathologic (pT)*	
pT2	Organ confined
pT2a	Unilateral, involving one-half of 1 lobe or less
pT2b	Unilateral, involving more than one-half of 1 lobe but not both lobes
pT2c	Bilateral disease
pT3	Extraprostatic extension
pT3a	Extraprostatic extension or microscopic invasion of the bladder neck
pT3b	Seminal vesicle invasion
pT4	Invasion of the bladder and rectum
*Positive surgical margin should be indicated by an R1 descriptor (residual microscopic disease)	

Regional lymph nodes (N)	
Clinical	
NX	Regional lymph nodes were not assessed
N0	No regional lymph node metastasis
N1	Metastasis in regional lymph node(s)
Pathologic	
PNX	Regional nodes not sampled
pN0	No positive regional nodes
pN1	Metastases in regional nodes(s)
Distant metastasis	
M0	No distant metastasis
M1	Distant metastasis
M1a	Nonregional lymph nodes(s)
M1b	Bone(s)
M1c	Other site(s) with or without bone disease
*If more than 1 site of metastasis is present, the most advanced category is used (pM1c).	

1.6.9 Risk stratification

Prostatic carcinoma outcome is influenced by several factors, including the extent of the tumor, histologic grade, patient age and health, and the PSA level. Prediction of the outcome, either before or after operation, has been evaluated using different sophisticated prognostic instruments, including risk grouping, tables, and nomograms. Preoperative risk stratification is important for treatment decision making. Preoperative nomograms are based on clinical stage (TNM), PSA level, Gleason score, and the number of positive and negative prostate biopsy cores (112), whereas postoperative nomograms add pathologic findings as well, such as capsular invasion, surgical margins, seminal vesicle invasion, and lymph node involvement (112-114).

D'Amico et al. (112) first proposed a three group stratification system to predict biochemical failure following radical prostatectomy and external-beam radiotherapy. The clinical TNM stage, PSA level, and Gleason score were used to group nonmetastatic patients into three risk groups: low risk, intermediate risk, and high risk (113). Criteria for low risk prostatic carcinoma are stage T1-T2a, Gleason score ≤ 6 , and PSA ≤ 10 ng/mL; for the intermediate risk group, they are T2b-T2c or Gleason score ≤ 7 or PSA 10–20 ng/mL; and for the high risk group, they are T3a or Gleason score 8–10 or PSA > 20 ng/mL (113). Current National Comprehensive Cancer Network (NCCN) guidelines have included the very low risk (T1c, and Gleason score ≤ 6 , PSA ≤ 10 ng/mL, < 3 positive biopsy cores each $\leq 50\%$ involved and PSA density of < 0.15 ng/mL/g) and very high risk (T3b-T4) groups (115, 116).

1.6.10 Therapy and prognosis

The management of a patient with prostate cancer depends on the patient's health status and life expectancy, as well as the type of prostate cancer, PSA level, stage, and grade of cancer, metastasis, and patient's preference. Watchful waiting, active surveillance, radiotherapy, and radical prostatectomy are the standard applied approaches (115, 117). High intensity ultrasound, cryosurgery, and chemotherapy are other optional treatments (115, 117).

The use of watchful waiting and active surveillance for prostatic cancer has triggered much debate. Furthermore, not all institutions agree on the terminology of either watchful waiting or active surveillance.

Watchful waiting, also known as deferred treatment, is a symptom-guided treatment. It is an option for older patients with less aggressive tumors, for those with limited life

expectancy, and for those who experience recurrence after curative therapies (118). These patients undergo palliative therapy to aid the patient's quality of life.

Active surveillance involves postponing immediate treatment, but requires close monitoring of the patient. It includes regular PSA tests, DREs, and periodic TRUS-guided prostate biopsies. This option is suitable in cases where the patient's cancer may not progress quickly to cause morbidity or mortality, and it reduces the risk of overtreatment (119).

Radiotherapy (RT) utilizes high-energy X-rays to kill cancer cells. Radiotherapy includes external beam radiation therapy (EBRT) or brachytherapy (BT), or a combination of both. High cure rates are reported when patients are treated with these two methods (120).

Radical prostatectomy (RP) is a surgical treatment offered to patients with localized disease to control cancer. RP encompasses the removal of the prostate, seminal vesicles, and part of the urethra. Depending on the characteristics of the tumor and patient sexual function, RP may or may not be nerve-sparing. RP is a method of treatment and may be recommended when the cancer has not spread outside the prostate (i.e., patients with T1 or T2 tumors). Surgical removal of the prostate may be used in combination with other treatments such as radiotherapy (121). Perioperative morbidity must be taken into consideration when considering RP. Thus, RP is primarily recommended for patients who have life expectancies greater than 10 years (115).

Hormone therapy, also known as androgen deprivation therapy (ADT), can be used as a primary treatment to control tumor growth, but it is unable to completely eliminate the disease. ADT may be used in various stages of prostatic disease. It may be used by itself in the treatment of localized advanced cancer or with metastatic disease, or with radiotherapy as an adjuvant treatment (122).

Cryosurgery, also known as cryotherapy or cryoablation, is applied to treat prostate cancer by freezing it. It is usually not a first treatment option, but it can be applied if cancer recurs after other treatments (123).

High intensity ultrasound is applied to treat low stage prostatic cancer, as well as in cases of tumor recurrence or as a palliative treatment (123).

Chemotherapy is not a treatment of first choice for localized prostate cancer. It is applied in advanced prostate cancer and when the hormone therapy is not effective (124).

Prostate cancer is usually diagnosed at a local or regional stage. The most recent data report a nearly 100% 5-year relative survival rate for localized prostate cancer. The 10 and 15

year relative survival rates are reported as 98% and 94 %, respectively (37). By contrast, metastatic prostate cancer has a reported 5-year survival rate of about 30% (125).

1.7 Periacinar retraction clefting

Retraction clefts around malignant glands in prostatic carcinoma are one of the proposed supportive features favoring the diagnosis of prostatic carcinoma (71, 126-129). Clefts appear as the neoplastic cells “pull away” from the surrounding stroma, leaving halos around the acini (71). They are described as empty spaces that partially or completely encircle a nest of tumor cells, usually in conformity with the rounded or angular outline of that particular nest (130).

Retraction clefting around malignant glands in the histological diagnosis of particular tumors has been considered as an artifact owing to tissue fixation and processing (131).

Krušlin et al. (127-129, 132), however, have suggested that periacinar retraction clefting observed in more than 50% of the circumference in at least 50% of suspicious glands represents a reliable criterion for the diagnosis of prostatic adenocarcinoma. *Fávaro et al.* (133) have recently reported a significantly more frequent periacinar retraction clefting in prostatic carcinoma samples than in normal acini. In their study, more than 72% of the neoplastic acini showed retraction clefting of more than 50% of the circumference, and this was significantly more frequent in Gleason score 7 and 6 (133).

Retraction cleftings are reported in other neoplasms as well, such as basal cell carcinoma or micropapillary variants of carcinomas of various primary sites, including the breast, ovary, colon, lung, ureter, and urinary bladder (134,135). *Acs et al.* (136) analyzed a large series of 2742 consecutive cases of breast carcinoma and reported that retraction clefts are more frequently seen in invasive ductal (no special type) breast carcinoma than in in situ carcinomas or benign breast ducts and acini. The presence of extensive retraction clefting in several tumor sites has been reported to correlate with more advanced tumors and aggressive tumor behavior and to be an indicator of poor prognosis in several tumor sites (135-138).

Several suggestions have been put forward regarding the origin of retraction cleftings and the biologic mechanisms causing the clefting in tumor specimens. *Young et al.* (131), referring to the correlation between Gleason pattern 3 prostatic adenocarcinoma and prominent periacinar retraction clefting, suggested that this phenomenon was probably an artifact. More recent studies, have suggested a relationship between retraction cleftings and an abnormality in the basement membrane, the loss of adhesion factors, or the expression of extracellular matrix proteins or collagenases and other enzymes required for invasion (130, 139, 140). Periacinar retraction cleftings have also been attributed to stromal changes and the lack of basal cells in prostatic adenocarcinoma (133, 140).

Barsky et al. (141) suggested that retraction clefts may in fact be an early stage of lymphocapillary invasion, where the conversion of mesenchymal cells to endothelial cells has not yet been completed, and thus represent true spaces or “pseudoretraction artifact” around the tumor cells. *Acs et al.* (136), in their recent study of what they call retraction artifacts in breast carcinoma, have also concluded that the retraction artifact may represent an early stage of lymphovascular invasion. *Ulamec et al.* (132), however, using D2-40 antibody to highlight the lymphatic endothelium and differentiate actual lymph vessels or lymphovascular invasion from periacinar retraction clefts, have shown that the number of lymph vessels was significantly lower in prostatic adenocarcinoma compared to adjacent nonneoplastic prostatic tissue. They concluded that retractions do not represent lymph vessels but should be considered a distinct entity.

1.8 E-cadherin/ Beta-catenin

Alterations in adhesion properties of neoplastic cells play a crucial role in the development and progression of the malignant phenotype in a variety of tumor types.

Cadherins and catenins, as the prime mediators of cell-cell adhesion, are closely involved in the control of morphological differentiation and cellular proliferation; loss of their intercellular function allows malignant cells to escape from their site of origin, degrade the extracellular matrix, acquire a more motile phenotype, and invade and metastasize healthy tissues (142).

E-cadherin is one of the most important molecules involved in cell-cell adhesion in epithelial tissues. It is essential for the formation and maintenance of normal epithelia, but it also plays a major role in malignant cell transformation, particularly in tumor development and progression. The suppression of E-cadherin expression is regarded as one of the main molecular events responsible for dysfunction in cell-cell adhesion. The loss of function of the E-cadherin tumor suppressor protein correlates with increased invasiveness and metastasis of tumors (143).

E-cadherin is a member of a large family of genes coding for calcium-dependent cell adhesion molecules (CAMs). The human epithelial E-cadherin gene CDH1 maps to chromosome 16q22.1 and encodes a 135 kDa precursor form of E-cadherin (144). The precursor form is cleaved in the cytoplasm to form a mature 120 kDa protein important for the homophilic adhesions. The mature E-cadherin contains three distinct domains: the highly conserved carboxy-terminal domain, a single pass transmembrane domain, and an extracellular domain. The extracellular domain consists of five tandem subdomain repeats that bind calcium, referred to as the C1-C5 subdomains (144).

The cytoplasmic domain of E-cadherin is required for formation of the cadherin-catenin complex. The cytoplasmic tail of E-cadherin consists of two regions: the juxtamembrane region and the catenin-binding region. These regions are principally required for clustering of E-cadherin at the juxtamembrane and to serve as a major link to the actin cytoskeleton. These regions are known to stabilize E-cadherin clusters and participate in signal transduction processes via the catenin-binding region (144).

E-cadherin forms a complex with four catenin proteins: α -catenin (102 kDa), β -catenin (92 kDa), γ -catenin (83 kDa), and p120 catenin (75–120 kDa) (144). The interaction of E-cadherin with cytoplasmic catenins, α , β , γ and p120 (p120ctn), is required for the normal function of E-cadherin. E-cadherin binds to either β -catenin or γ -catenin, but does not directly

bind to α -catenin; α -catenin, however, binds to either β -catenin or γ -catenin. Therefore, in a single cell, one complex consists of E-cadherin with α - and β -catenin, and the other complex consists of E-cadherin with α - and γ -catenin (144). The sequential order of cadherin-catenin complex formation begins with β -catenin interacting with E-cadherin. If E-cadherin fails to associate with β -catenin, E-cadherin is retained in the endoplasmic reticulum, where it is subsequently degraded. E-cadherin and β -catenin are transported together in a bipartite fashion to the cell surface, where they associate with α -catenin. The amino-terminal region of α -catenin binds to actin filaments in the cytoplasm, linking the cadherin-catenin complex to the cytoskeleton (144).

Beta-catenin (β -catenin) is a 92 kDa multifunctional protein encoded by the CTNNB1 gene located on chromosome 3p21. It belongs to the armadillo family of proteins, characterized by a central domain of 12 repeats of about 40 amino acids called arm repeats (144). The arm domain was originally described in armadillo, which is the *Drosophila* homologue of β -catenin (145). β -catenin serves as a link between cadherins and the actin cytoskeleton. It also binds to numerous other proteins in cadherin-independent complexes, such as APC, lymphoid enhancer factor and T-cell factor (LEF/TCF) transcription factors, and the RGS domain proteins axin/conductin and prontin 52 (144). In addition to its role in cell-adhesion, β -catenin is a key effector molecule of the WNT signaling transduction in the nucleus (144).

Imbalance in the structural and signaling properties of β -catenin often results in diseases and deregulated growth related to cancer and metastasis (145). β -catenin is involved in organogenesis and tissue morphogenesis. It plays a critical role in the regulation of cadherin-mediated cell recognition and adhesion, acting as the regulator of the cadherin-catenin component linking the signal transduction within the intercellular adhesions (145, 146).

The E-cadherin-catenin complex is fundamental for the establishment and maintenance of multicellular organisms and regulates or significantly contributes to a variety of functions, such as signal transduction, cell-growth, differentiation, site-specific gene expression, morphogenesis, immunologic function, wound healing, and inflammation (145-148). Various studies have observed a correlation between the loss of E-cadherin-catenin immunoreactivity and high grade, advanced stage, and poor prognosis in certain tissue carcinomas (142, 143, 148-153). Expression of the E-cadherin- β -catenin complex has also been studied in prostatic carcinoma (154-163). The univariate analysis by *De Marzo et al.* (157) showed that reduced levels of E-cadherin correlated with advanced Gleason score

($P=0.003$) and advanced pathologic stage ($P=0.008$). *Jaggi et al.* (158) reported a significant downregulation of E-cadherin in Gleason score 7–10 prostatic carcinomas when compared to Gleason score ≤ 6 ($P=0.015$), suggesting a significant association of E-cadherin with increasing grade. A significant association of reduced membranous β -catenin expression was also revealed in prostatic adenocarcinoma with increasing Gleason score ($P=0.015$).

Moreover, these authors reported that β -catenin was localized in the nucleus of the poorly differentiated cancer cells of Gleason score 7–10, and a significant correlation existed between high Gleason score and nuclear β -catenin expression ($P=0.0001$). No association of E-cadherin and β -catenin expression was found with final pathologic stage ($P>0.05$) (158).

Several other studies, have reported decreased membranous β -catenin cell expression in prostatic adenocarcinoma to correlate with higher Gleason score, but no nuclear β -catenin immunostaining was detected (160-162).

The expression of αv , $\alpha v\beta 3$, $\alpha 2\beta 1$, and γ -catenin were abnormal in almost every case of primary and metastatic prostatic carcinoma reported by *Pontes-Júnior et al.* (159). Marked loss of E-cadherin and $\beta 4$ integrin was found in primary and metastatic lesions. Contrary to the findings of *Jaggi et al.* (158), β -catenin expression was normal in all primary cases and in 94% of the metastases (159). The $\alpha 6$ expression was normal in all primary tumors and metastases. The expression of $\alpha 3$ and $\alpha 3\beta 1$ was normal in 32% of primary cases and in 53% and 6% of metastases, respectively. In paired analyses, loss of E-cadherin, $\beta 4$, αv , $\alpha 3\beta 1$, and $\alpha v\beta 3$ was found in 65, 71, 59, 53 and 47% of patients, respectively. Catenins and $\alpha 2\beta 1$ showed maintenance of expression in most of the cases (159).

2. HYPOTHESIS

Our hypothesis is that periacinar retraction clefting is a result of decreased expression of E-cadherin and β -catenin proteins in epithelial cells of prostatic adenocarcinoma.

3. AIMS OF THESIS

3.1 General aim

To determine the expression of E-cadherin and β -catenin cell adhesion proteins and their correlation with periacinar retraction cleftings in prostatic adenocarcinoma and adjacent nonneoplastic prostatic tissue.

3.2 Specific aims

1. To determine the presence and extent of periacinar retraction clefting in prostatic adenocarcinoma and the adjacent nonneoplastic prostatic tissue.
2. To determine the expression of E-cadherin and β -catenin cell adhesion proteins in prostatic adenocarcinoma and in the adjacent nonneoplastic prostatic issue.
3. To correlate the expression of E-cadherin and β -catenin cell adhesion proteins in prostatic adenocarcinoma and in adjacent nonneoplastic prostatic tissue with periacinar retraction clefting.
4. To correlate the expression of E-cadherin and β -catenin with preoperative and postoperative Gleason score (GSC), serum prostate-specific antigen (sPSA), positive surgical margins, biochemical recurrence (BCR), and the TNM staging in prostatic adenocarcinoma.

4. MATERIAL AND METHODS

4.1 Study population and material

The research was conducted in archival tissue specimens of prostatic adenocarcinoma and the adjacent nonneoplastic prostatic tissue, obtained by radical prostatectomy in the Department of Pathology «Ljudevit Jurak» of the Clinical Hospital Center «Sestre milosrdnice» in Zagreb.

Patient identifiers were removed and replaced by study numbers in order to protect the identity of patients.

A total of 53 prostate samples, morphologically diagnosed as prostatic adenocarcinoma, were analyzed, including the adjacent nonneoplastic prostatic tissue.

4.2 Methods

Sections were cut at 5µm thickness from paraffin blocks containing prostatic lesional tissue fixed in 10% buffered formaldehyde. Slides were subsequently deparaffinized and stained with hematoxylin and eosin (H&E).

The presence and extent of periacinar retraction clefting was determined by light microscopy under high power field magnification (400x) and a minimum of 30 neoplastic and 30 nonneoplastic glands were assessed. Periacinar retraction clefting was graded as a percentage of gland circumference separated from the stroma in three categories, as previously described (127):

- group 1: glands without clefts or with clefts affecting less than 50% of the circumference,
- group 2: glands with clefts that affect more than 50% of the circumference in less than 50% of examined glands, and
- group 3: glands with clefts that affect more than 50% of the circumference in 50% or more of the examined glands.

4.2.1 Immunohistochemistry

Immunohistochemical analysis of the expression of E-cadherin (code M3612, clone NCH-38, dilution 1:50) and β -catenin (code M3539, clone β -catenin-1, dilution 1:200) cell adhesion proteins in neoplastic and adjacent nonneoplastic prostatic tissue was performed using an EnVision Flex-system on a Dako TechMate TM immunohistochemical autostainer.

Primary antibodies were purchased from Dako, Denmark. Breast cancer tissue was used as a positive control and Mouse IgG1 (code X0931) as a negative control.

4.2.2 Scoring

Immunohistochemical staining results were assessed by considering the intensity of cell membrane staining and the approximate percentage of positive tumor cells within the foci of neoplastic tissue, in adjacent nonneoplastic prostatic tissue, and within the foci of retraction clefting, as determined by light microscopy under high power field magnification (400x). The intensity of staining was graded semiquantitatively as 0 (no staining), 1+ (weak), 2+ (moderate), and 3+ (strong) staining. Distribution of staining percentage was graded as focal (<70% positive cells), diffuse (>70% positive cells), and heterogeneous (a mixed population of foci of positive and negative cells). Only strong and diffuse membranous staining (intensity score 3+, >70%,) was considered positive immunoreactivity for both markers (156, 158).

4.3 Statistical methods

Data are presented in tables. Quantitative values are shown through medians and corresponding interquartile ranges. Differences in periacinar retraction clefting in relation to other clinical parameters regarding categorical variables were analyzed with the chi-square test and differences in quantitative variables were analyzed with the Kruskal-Wallis test.

Spearman's and Kendall's tau_b (for nominal variables) correlation coefficients were calculated to assess the correlation of E-cadherin and β -catenin expression with periacinar retraction clefting, preoperative and postoperative Gleason score (GSC), serum prostate-specific antigen (sPSA), positive surgical margins, biochemical recurrence (BCR), and the TNM staging. All P values below 0.05 were considered significant.

Statistical software IBM SPSS Statistics version 21 was used in all statistical procedures. All samples were independently reviewed by two observers.

5. RESULTS

5.1 Descriptive statistics

Our study comprised 53 cases of prostate diagnosed as prostatic adenocarcinoma.

Morphologically, all 53 samples fulfilled criteria for prostatic adenocarcinoma. Our criteria for inclusion of a tissue block in the study were the presence of identifiable prostatic adenocarcinoma and availability of adjacent nonneoplastic prostatic tissue (Figure 1).

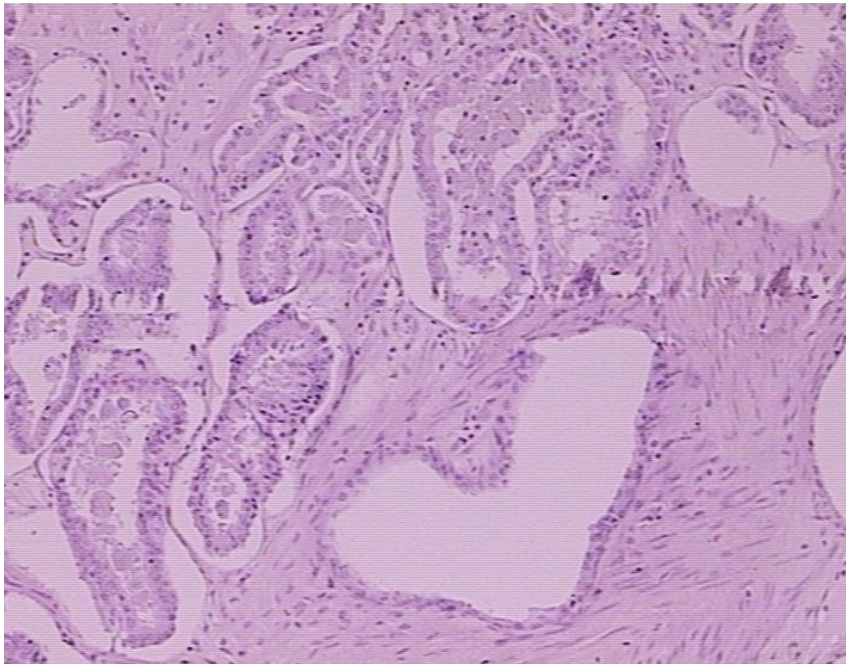


Figure 1. Hematoxylin & eosin (H&E) stained section showing prostatic adenocarcinoma glands infiltrating between nonneoplastic prostatic tissues.

Descriptive statistics of the patients are summarized in Tables 3 and 4. More than half of the patients (50.9%) had a preoperative Gleason score (GSC) of 6 (3+3). A total of 19 patients (35.8%) had a positive biochemical recurrence (BCR) status and nearly two thirds of patients (66 %) had T2N0Mx status.

The highest prevalence of postoperative GSC was 6 (3+3) in 30 (56.6%) patients. Forty tumors (75.5%) were confined to the prostate and 13 (24.5%) patients had positive surgical margins, with the tumor spreading through the prostatic capsule. The median (interquartile range –IQR) age of patients was 64.0 (61.0–67.0) years and the median preoperative serum prostate-specific antigen (sPSA) value was 9.0 (6.5–12.8) ng/mL. Median follow-up time was 62.0 (27.0–68.0) months.

Table 3. Descriptive statistics of patient characteristics: categorical variables.

		N	%
Preoperative GSC	6(3+3)	27	50.9%
	6(4+2)	1	1.9%
	7(3+4)	11	20.8%
	7(4+3)	11	20.8%
	9(4+5)	3	5.7%
Preoperative GSC No	6	28	52.8%
	7	22	41.5%
	9	3	5.7%
BCR	No	34	64.2%
	Yes	19	35.8%
TNM	T2N0Mx	35	66.0%
	T3N0Mx	15	28.3%
	T3N1Mx	3	5.7%
T	2	35	66.0%
	3	18	34.0%
N	0	50	94.3%
	1	3	5.7%
Postoperative GSC	6(3+3)	30	56.6%
	7(3+4)	9	16.9%
	7(4+3)	10	18.9%
	8(5+3)	1	1.9%
	9(4+5)	3	5.7%
Postoperative GSC No	6	30	56.6%
	7	19	35.8 %
	8	1	1.9%
	9	3	5.7%
Surgical margins	Negative	40	75.5%
	Positive	13	24.5%

Table 4. Descriptive statistics of patient characteristics: quantitative variables.

	N	Mean	SD	Minimum	Maximum	Percentiles		
						25th	50th (Median)	75th
Age (years)	53	63.96	5.26	52.00	74.00	61.00	64.00	67.00
PSA	53	10.62	6.43	3.20	38.40	6.49	9.00	12.80
Follow up (months)	53	51.89	23.86	6.00	84.00	27.00	62.00	68.00

5.2 Correlation between the presence and extent of periacinar retraction clefting in prostatic adenocarcinoma and in the adjacent nonneoplastic prostatic tissue

The presence and the extent of periacinar retraction clefting in prostatic adenocarcinoma and in the adjacent nonneoplastic prostatic tissue were determined on H&E stained slides by light microscopy under high power field magnification (400x) by assessing a minimum of 30 neoplastic and 30 nonneoplastic glands.

The most frequent group with periacinar retraction clefting in prostatic adenocarcinoma was group 3 (glands with clefts that affected more than 50% of the circumference in 50% or more of the examined glands). Group 3 periacinar retraction clefting was present in 33 (62.3%) samples (Figure 2A; Table 5) of prostatic adenocarcinoma. \

Whereas, group 1 (glands without clefts or with clefts affecting less than 50% of the circumference) was present in 44 (83.0%) samples in the adjacent nonneoplastic prostatic tissue (Figure 2B; Table 5).

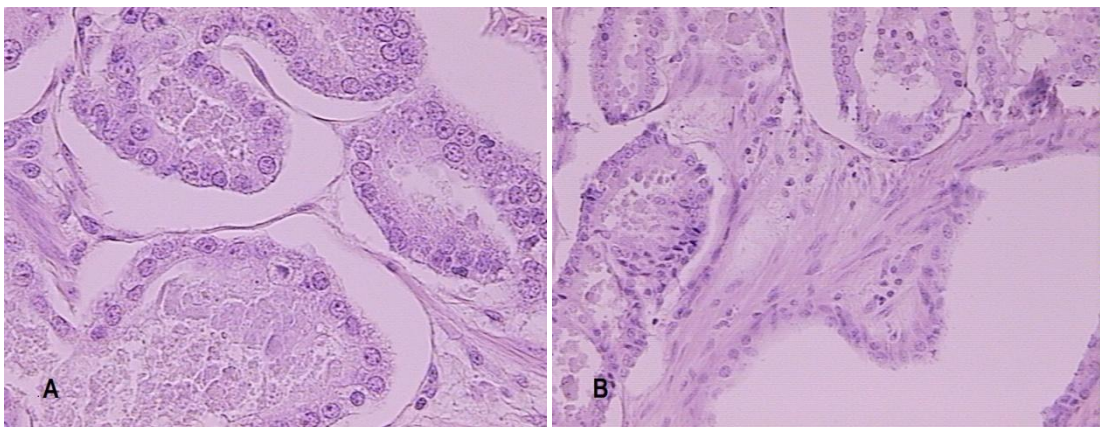


Figure 2A-B. Group 3 periacinar retraction clefting in prostatic adenocarcinoma (H&E) (A), group 1 periacinar retraction clefting in the nonneoplastic prostatic tissue (lower corner right) adjacent to group 3 periacinar retraction cleftings in prostatic adenocarcinoma (upper corner left) (H&E) (B).

Periacinar retraction clefting was significantly more extensive in prostatic adenocarcinoma samples than in the adjacent nonneoplastic prostatic tissue ($P < 0.001$).

Table 5. The presence and extent of periacinar retraction clefting in prostatic adenocarcinoma and in the adjacent nonneoplastic prostatic tissue.

		N	%
Periacinar retraction	1	3	5.7%
clefting in prostatic	2	17	32.1%
adenocarcinoma	3	33	62.3%
Periacinar retraction	1	44	83.0%
clefting in adjacent	2	9	17.0%
nonneoplastic prostatic			
tissue			

Group 1- glands without clefts or with clefts affecting less than 50% of the circumference,

Group 2- glands with clefts that affect more than 50% of the circumference in less than 50% of the examined glands, and

Group 3- glands with clefts that affect more than 50% of the circumference in 50% or more of the examined glands.

5.3 IHC expression of E-cadherin and β -catenin cell adhesion proteins in prostatic adenocarcinoma and in the adjacent nonneoplastic prostatic issue

IHC staining results for E-cadherin and β -catenin were assessed by considering the intensity of cell membrane staining and the approximate percentage of positive tumor cells within the foci of neoplastic tissue and the adjacent nonneoplastic prostatic tissue, as determined by light microscopy under high power field magnification (400x).

The expression pattern for E-cadherin, as determined by IHC, was predominantly membranous and weakly cytoplasmic in both the prostatic adenocarcinoma and the adjacent nonneoplastic prostatic tissue. Figure 3A–C and Table 6 show the pattern of E-cadherin IHC staining in prostatic adenocarcinoma and in the adjacent nonneoplastic prostatic tissue. Strong and diffuse cell staining (intensity score 3+, >70%), was considered a positive pattern of staining.

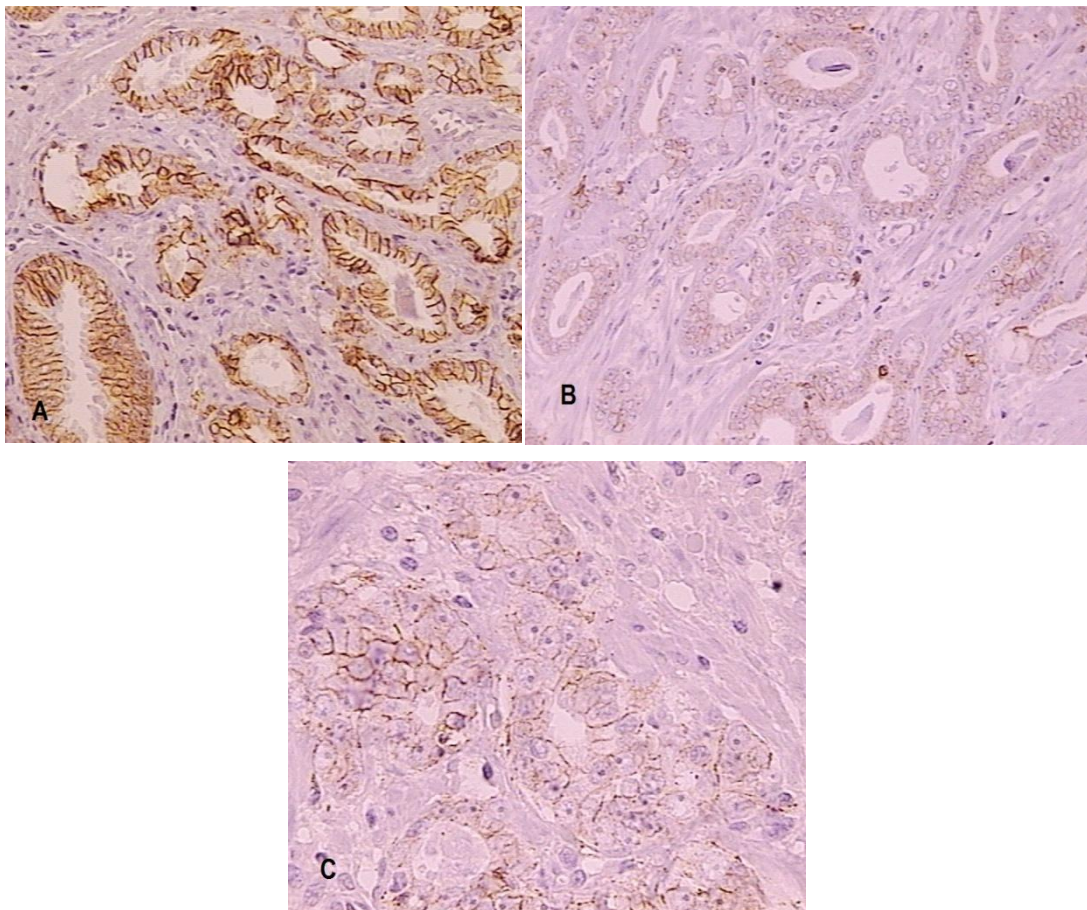


Figure 3A-C. IHC showing strong membranous expression of E-cadherin (score 3+) in prostatic adenocarcinoma (upper corner right) and in the adjacent nonneoplastic prostatic tissue (lower corner left) (A), no staining (score 0) in prostatic adenocarcinoma (B), and, heterogeneous staining with mixed foci of positive and negative cells in prostatic adenocarcinoma (C).

A strong and diffuse intensity of E-cadherin staining (score 3+, >70%) was evident in only 4 (7.5%) and 2 (3.8%) samples of prostatic adenocarcinoma, respectively. A weak and focal intensity of E-cadherin staining (score 1+, <70%) was evident in 31 (58.5%) and 18 (34%) samples of prostatic adenocarcinoma, respectively. A strong and diffuse intensity of E-cadherin staining (score 3+, >70%) was evident in all 53 (100%) samples of the adjacent nonneoplastic prostatic tissue.

A strong and diffuse (score 3+, >70%) intensity of E-cadherin staining was observed significantly more frequently in the samples of the adjacent nonneoplastic tissue than in prostatic adenocarcinoma ($P < 0.001$).

Heterogeneous staining of E-cadherin, indicative of a mixed population of foci of positive and negative cells was evident in 33 (62.3%) samples of prostatic adenocarcinoma, and a moderate intensity of E-cadherin staining (score 2+) was evident in 18 (34%) samples of prostatic adenocarcinoma.

Table 6. IHC staining of E-cadherin expression in prostatic adenocarcinoma and in the adjacent nonneoplastic prostatic tissue.

		N	%
E-cadherin: intensity of staining in prostatic adenocarcinoma	1	31	58.5%
	2	18	34.0%
	3	4	7.5%
E-cadherin: % of staining in prostatic adenocarcinoma	<70%	18	34.0%
	Heterogeneous	33	62.3%
	>70%	2	3.8%
E-cadherin: intensity of staining in adjacent nonneoplastic tissue	1	0	0.0%
	2	0	0.0%
	3	53	100%
E-cadherin: % of staining in adjacent nonneoplastic tissue	<70%	0	0.0%
	Heterogeneous	0	0.0%
	>70%	53	100%

Intensity of staining: 0 (no staining), 1+ (weak), 2+ (moderate), 3+ (strong)

Percentage of staining: focal (<70% of cells positive), diffuse (>70% of cells positive), heterogeneous (a mixed population of foci of positive and negative cells).

*Only strong and diffuse (score 3+, >70%) intensity of staining was considered as positive staining.

The pattern of β -catenin IHC staining, in both prostatic adenocarcinoma and the adjacent nonneoplastic prostatic tissue, was predominantly membranous and weakly cytoplasmic. We did not observe nuclear staining.

A strong intensity of β -catenin IHC staining (score 3+) was evident in 21 (39.6%) samples and diffuse staining (>70%) was identified among 30 (57%) samples of prostatic adenocarcinoma, whereas a strong and diffuse (score 3+, >70%) intensity of staining was seen in all 53 (100%) samples of the adjacent nonneoplastic prostatic tissue (Figures 4 A–C. Table 7).

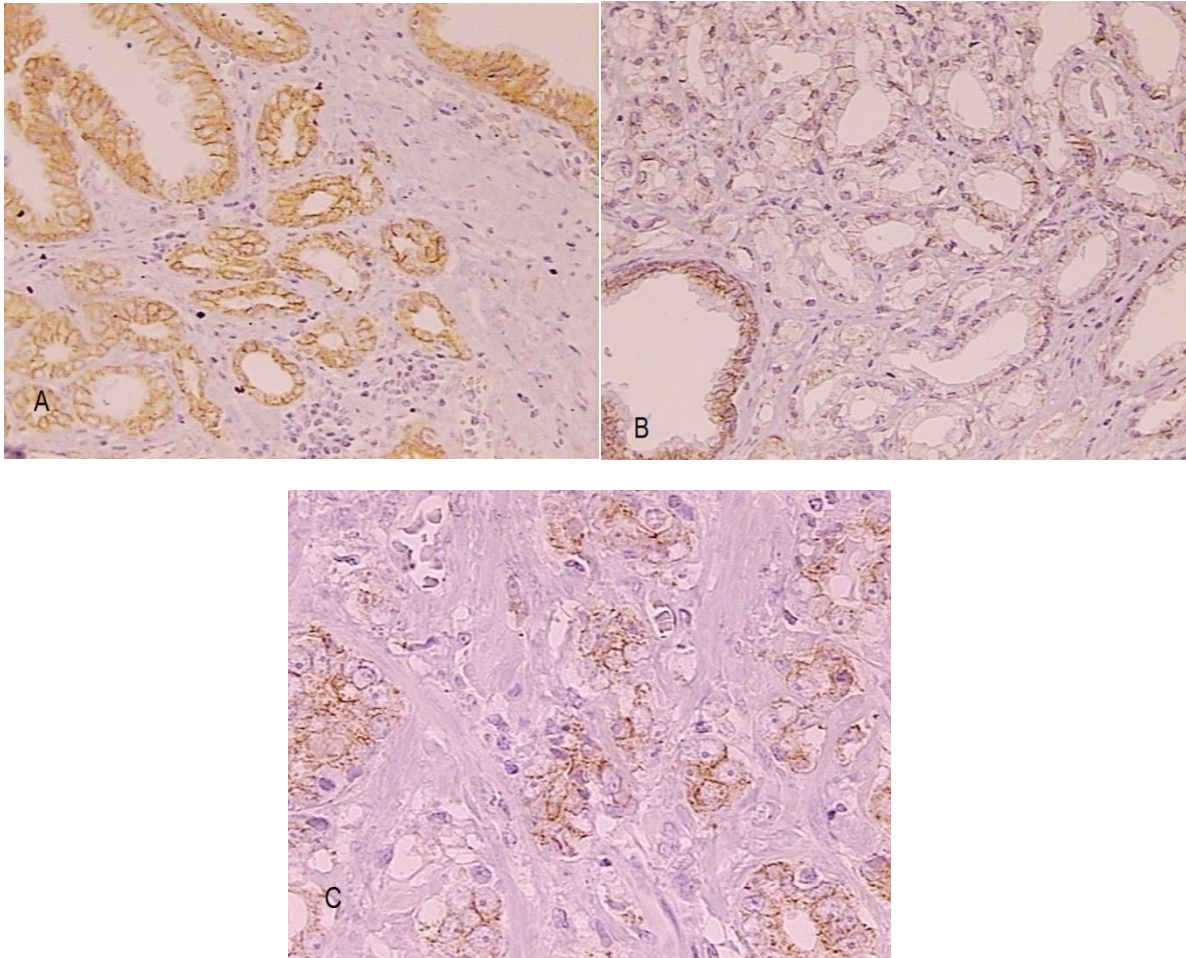


Figure 4A-C. IHC showing strong membranous expression of β -catenin (score 3+) in prostatic adenocarcinoma glands infiltrating between the adjacent nonneoplastic prostatic tissue (A), no staining (score 0) in prostatic adenocarcinoma (upper corner right) and strong intensity of staining (score 3+) in adjacent nonneoplastic gland (lower corner left) (B), and heterogeneous staining with mixed foci of positive and negative cells in prostatic adenocarcinoma (C).

Table 7. IHC staining of β -catenin expression in prostatic adenocarcinoma and in the adjacent nonneoplastic prostatic tissue.

		N	%
β -catenin: intensity of staining in prostatic adenocarcinoma	1	8	15.1%
	2	24	45.3%
	3	21	39.6%
β -catenin: % of staining in prostatic adenocarcinoma	<70%	5	9.4%
	Heterogeneous	18	33.94%
	>70%	30	57%
β -catenin: intensity of staining in adjacent nonneoplastic prostatic tissue	1	0	0.0%
	2	0	0.0%
	3	53	100%
β -catenin: % of staining in adjacent nonneoplastic prostatic tissue	<70%	0	0.0%
	Heterogeneous	0	0.0%
	>70%	53	100%

Intensity of staining: 0 (no staining), 1+ (weak), 2+ (moderate), 3+ (strong).

Percentage of staining: focal (<70% of cells positive), diffuse (>70% of cells positive), heterogeneous (a mixed population of foci of positive and negative cells).

*Only strong and diffuse staining (intensity score 3+, >70%) was considered positive staining.

Table 8 summarizes correlation of E-cadherin expression with serum prostate-specific antigen (sPSA), preoperative and postoperative Gleason score (GSC), positive surgical margins, biochemical recurrence (BCR) and the TNM staging.

Significant negative correlations were found between the intensity and the percentage of E-cadherin staining in prostatic adenocarcinoma and preoperative GSC and positive surgical margins. Postoperative GSC, BCR, and T stage were negatively correlated with the intensity of E-cadherin staining.

No correlations were found between E-cadherin intensity and percentage of staining and the sPSA and N status.

IHC staining of E-cadherin expression was significantly decreased in high grade prostatic adenocarcinomas (Figure 5).

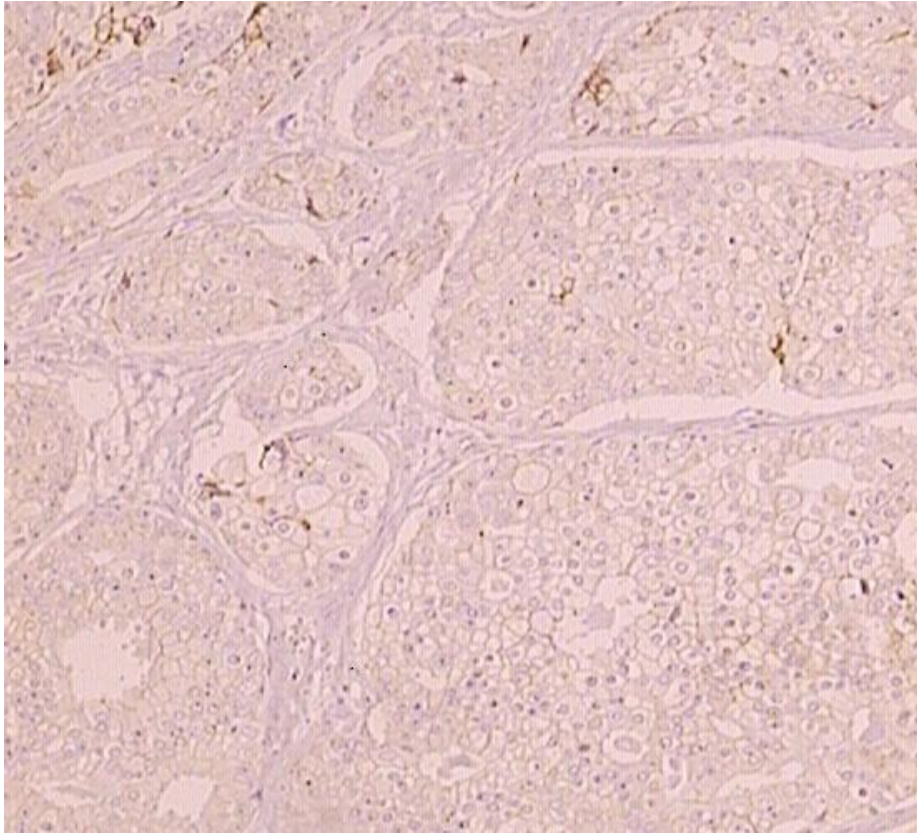


Figure 5. IHC showing weak (score 1+) to negative (score 0) membranous expression of E-cadherin in high grade prostatic adenocarcinoma Gleason score 9 (4+5).

Table 8. Correlation of E-cadherin expression with preoperative and postoperative Gleason score (GSC), serum prostate-specific antigen (sPSA), positive surgical margins, biochemical recurrence (BCR), and the TNM staging in prostatic adenocarcinoma: Spearman's and Kendall tau_b coefficients.

		E-cadherin: intensity of staining in prostatic adenocarcinoma	E-cadherin: % of staining in prostatic adenocarcinoma
sPSA	Correlation Coefficient	-0.039	-0.076
	P	0.781	0.587
	N	53	53
Preoperative GSC No	Correlation Coefficient	-0.445	-0.204
	P	0.001	0.143
	N	53	53
Postoperative GSC No	Correlation Coefficient	-0.634	-0.424
	P	0.001	0.002
	N	53	53
Surgical margins	Correlation Coefficient*	-0.309	-0.338
	P	0.024	0.013
	N	53	53
BCR	Correlation Coefficient*	-0.327	-0.235
	P	0.017	0.090
	N	53	53
T	Correlation Coefficient*	-0.445	-0.263
	P	0.001	0.058
	N	53	53
N	Correlation Coefficient*	-0.202	-0.170
	P	0.147	0.224
	N	53	53

*Kendall tau_b coefficient

Table 9 summarizes correlations of β -catenin expression with serum prostate-specific antigen (sPSA), preoperative and postoperative Gleason score (GSC), positive surgical margins, biochemical recurrence (BCR), and the TNM staging.

Intensity of β -catenin staining in prostatic adenocarcinoma was significantly negatively correlated with preoperative and postoperative GSC and BCR.

Similar findings were observed for the percentage of β -catenin staining in prostatic adenocarcinoma, where additional negative correlations were found with positive surgical margins and T status.

No correlations were found between intensity and percentage of β -catenin staining and sPSA and N status.

Decreased β -catenin expression in high grade prostatic adenocarcinoma is shown in Figure 6.

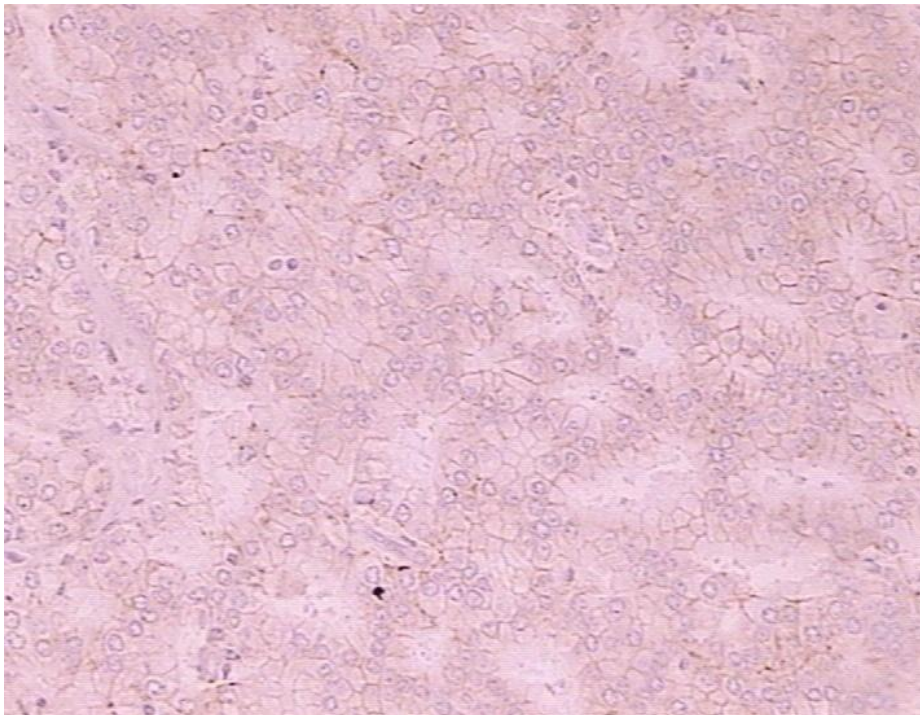


Figure 6. IHC showing weak (score 1+) membranous expression of β -catenin in prostatic adenocarcinoma GSC 9 (4+5).

Table 9. Correlation of β -catenin expression with preoperative and postoperative Gleason score (GSC), serum prostate-specific antigen (sPSA), positive surgical margins, biochemical recurrence (BCR), and the TNM staging in prostatic adenocarcinoma: Spearman's and Kendall's tau_b coefficients.

		β-catenin: intensity of staining in prostatic adenocarcinoma	β-catenin: % of staining in prostatic adenocarcinoma
PSA	Correlation Coefficient	-0.023	0.075
	P	0.871	0.593
	N	53	53
Preoperative GSC No	Correlation Coefficient	-0.467	-0.526
	P	0.001	0.001
	N	53	53
Postoperative GSC No	Correlation Coefficient	-0.531	-0.379
	P	0.001	0.005
	N	53	53
Surgical margins	Correlation Coefficient*	-0.153	-0.273
	P	0.274	0.048
	N	53	53
BCR	Correlation Coefficient*	-0.273	-0.388
	P	0.048	0.004
	N	53	53
T	Correlation Coefficient*	-0.149	-0.295
	P	0.287	0.032
	N	53	53
N	Correlation Coefficient*	-0.113	-0.261
	P	0.419	0.060
	N	53	53

*Kendall tau_b coefficient

5.4 Correlation of expression of E-cadherin and β -catenin with periacinar retraction clefting in prostatic adenocarcinoma and in the adjacent nonneoplastic prostatic tissue

Table 10 and Figure 7A–C show correlations of expression of E-cadherin in prostatic adenocarcinoma and in the adjacent nonneoplastic prostatic tissue with periacinar retraction clefting.

Periacinar retraction clefting was positively correlated with the intensity of E-cadherin staining in prostatic adenocarcinoma ($\rho=0.398$; $P=0.003$) and the percentage of E-cadherin staining in prostatic adenocarcinoma ($\rho=0.367$; $P=0.007$).

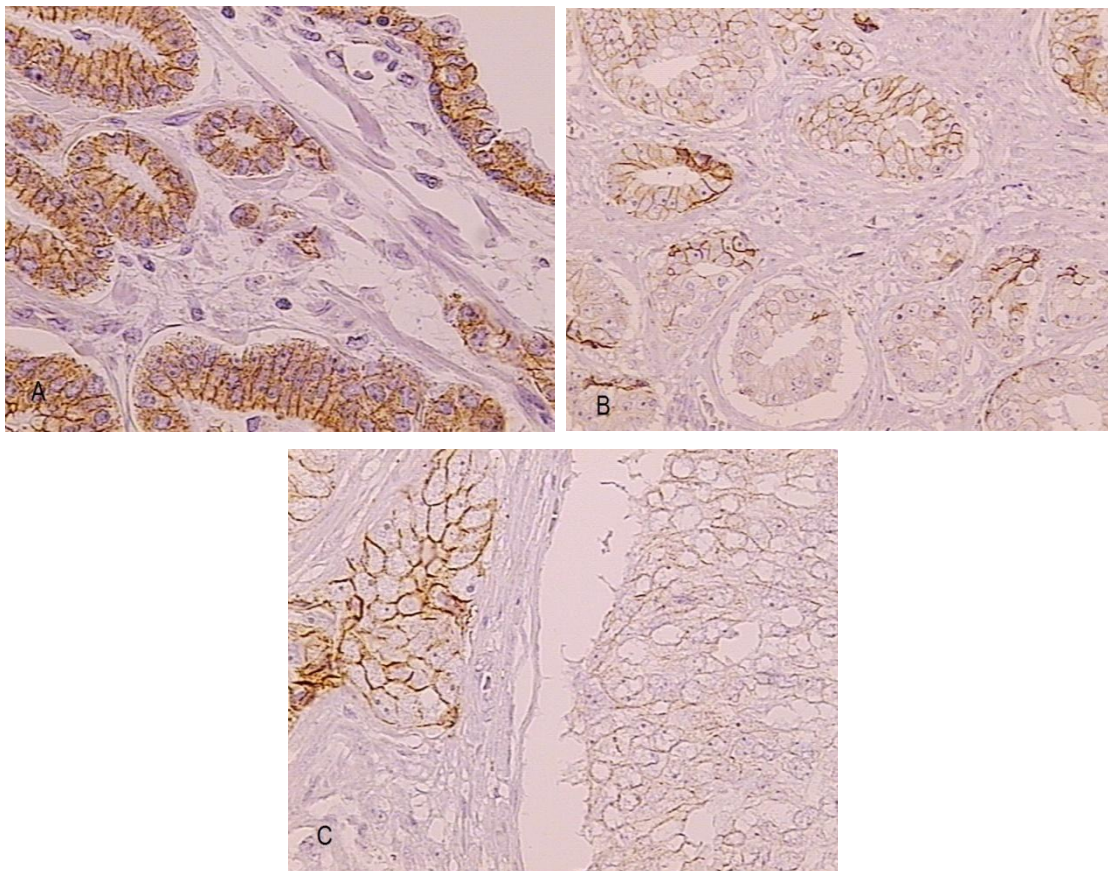


Figure 7A-C. IHC showing strong (score 3+) membranous expression of E-cadherin in glands with extensive retraction clefting in prostatic adenocarcinoma GSC 6 (3+3) (lower corner left) (A), and no staining (score 0) within the cells of glands with retraction clefts in GSC 7 (4+3) (B,C).

In 4 (7.54%) samples with Gleason score (GSC) 7 (4+3) and with a mixed population of positive and negative cells, E-cadherin staining was weak to negative in the cells of tumor glands with periacinar clefts and positive in tumor glands with no periacinar clefts (Figure 7 B-C). No significant correlations were found between periacinar retraction clefting and the intensity and percentage of E-cadherin staining in the adjacent nonneoplastic prostatic tissue.

Table 10. Correlation of expression of E-cadherin cell adhesion protein in prostatic adenocarcinoma and the adjacent nonneoplastic prostatic tissue, with periacinar retraction clefting: Spearman's correlation coefficients.

		Periacinar clefting
E-cadherin: intensity of staining in prostatic adenocarcinoma	Correlation Coefficient	0.398
	P	0.003
	N	53
E-cadherin: % of staining in prostatic adenocarcinoma	Correlation Coefficient	0.367
	P	0.007
	N	53
E-cadherin: intensity of staining in adjacent nonneoplastic prostatic tissue	Correlation Coefficient	0.037
	P	0.793
	N	53
E-cadherin: % of staining in adjacent nonneoplastic prostatic tissue	Correlation Coefficient	0.179
	P	0.199
	N	53

The correlations of the expression of β -catenin in prostatic adenocarcinoma with periacinar retraction clefting are presented in Table 11 and Figure 8A–B. Similar to our findings with E-cadherin, we found positive significant correlations between periacinar retraction cleftings and the intensity ($\rho= 0.374$; $P=0.006$) and percentage ($\rho=0.347$; $P=0.011$) of β -catenin staining in prostatic adenocarcinoma.

No significant correlations were found between periacinar retraction clefting and the intensity and percentage of β -catenin staining in the adjacent nonneoplastic prostatic tissue.

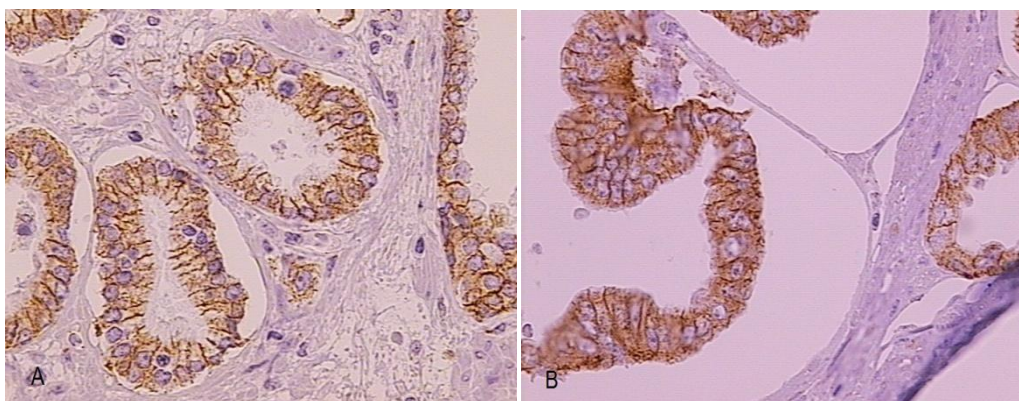


Figure 8A-B. IHC showing strong (score 3+) membranous expression of β -catenin in glands with extensive retraction clefting in prostatic adenocarcinoma Gleason score 6 (3+3) (A, B).

Table 11. Correlation of expression of β -catenin in prostatic adenocarcinoma and the adjacent nonneoplastic prostatic tissue with periacinar retraction clefting: Spearman's correlation coefficients.

		Periacinar clefting
β -catenin: intensity of staining in carcinoma	Correlation Coefficient	0.374
	P	0.006
	N	53
β -catenin: % of staining in carcinoma	Correlation Coefficient	0.347
	P	0.011
	N	53
β -catenin: intensity of staining in adjacent nonneoplastic prostatic tissue	Correlation Coefficient	0.190
	P	0.173
	N	53
β -catenin: % of staining in adjacent nonneoplastic prostatic tissue	Correlation Coefficient	0.083
	P	0.555
	N	53

6. DISCUSSION

Prostate cancer is the leading cause of new cancer in men. Its frequency increases with age, 3/4 of men diagnosed with prostate cancer are age 65 or older (37, 38). Despite a relatively high morbidity and mortality the etiology of prostate cancer remains largely unknown.

Contemporary methods of prostate cancer detection are resulting in the identification of increasingly smaller tumors, which adds to the difficulty in making the diagnosis of prostate cancer commonly based on very few atypical glands.

Adenocarcinomas constitute about 90–95% of prostate cancer. The histopathological diagnosis of prostatic adenocarcinoma is a constellation of architectural, nuclear, cytoplasmic and intraluminal features (68). Three major diagnostic criteria are established for prostatic adenocarcinoma: the infiltrative growth pattern, the absence of a basal cell layer, and the presence of macronucleoli (68-72). Other supportive diagnostic criteria for prostatic adenocarcinoma include marginated nucleoli, multiple nucleoli, hyperchromasia, mitoses, apoptotic bodies, amphophilic cytoplasm, blue-tinged mucinous secretions, pink amorphous secretions, intraluminal crystalloids, perineural invasion, glomerulations, mucinous fibroplasia, and periacinar retraction clefting. Nevertheless, many of these criteria can also be present in benign prostate glands or other nonneoplastic acinar proliferative conditions of the prostate.

The so-called periacinar retraction cleftings, retraction artifacts, periacinar halos, or clefts like spaces are also criteria favoring the diagnosis of prostatic adenocarcinoma (72, 126-129). The clefts appear as the neoplastic cells “pull away” from the surrounding stroma, leaving halos around the acini (72). Retraction clefting around malignant nests in the histological diagnosis of particular tumors has been considered an artifact of tissue fixation and processing. *Young et al.* (131), referring to the correlation between Gleason pattern 3 prostatic adenocarcinoma and prominent periacinar retraction clefts, also suggested that this phenomenon was probably an artifact. *Krušlin et al.* (127-129, 132), however, have observed that periacinar retraction clefting of more than 50% of the circumference in at least 50% of suspicious glands represents a reliable criterion for the diagnosis of prostatic adenocarcinoma.

Fávaro et al. (133) have recently reported that periacinar retraction clefting was significantly more frequent and extensive in prostatic carcinoma samples than in normal acini.

In their study, more than 72% of neoplastic acini showed retraction clefting of more than 50% of the circumference and was significantly more frequent in Gleason score 7 and 6 (133) tumors.

Retraction cleftings are also reported in other neoplasms, such as basal cell carcinoma or micropapillary variants of carcinomas of various primary sites, including breast, ovary, colon, lung, ureter, and urinary bladder (134, 135). *Acs et al.* (136), who examined a large series of 2742 consecutive cases of breast carcinoma, have reported that retraction clefts are seen more frequently in invasive ductal (no special type) breast carcinoma when compared to in situ carcinomas or benign breast ducts and acini.

The presence of extensive retraction clefting has been reported to correlate with more advanced tumors and aggressive behavior, and to be an indicator of poor prognosis in several tumor sites (135-138). In our study, periacinar retraction cleftings were significantly more extensive in prostatic adenocarcinoma samples than in the adjacent nonneoplastic tissue ($P < 0.001$). In total, 33 (62.3%) samples of prostatic adenocarcinoma were classified as group 3 (glands with clefts that affected more than 50% of the circumference in 50% or more of the examined glands) and 17 (32.1%) as group 2 (glands with clefts that affect more than 50% of the circumference in less than 50% of examined glands), whereas only 3 (5.7%) samples of prostatic adenocarcinoma were classified as group 1 (glands without clefts or with clefts affecting less than 50% of the circumference).

In the adjacent nonneoplastic prostatic tissue, however, 44 (83.0%) samples were classified as group 1 (glands without clefts or with clefts affecting less than 50% of the circumference) and 9 (17%) as group 2 (glands with clefts that affect more than 50% of the circumference in less than 50% of examined glands). None of the adjacent nonneoplastic prostatic tissue was classified as group 3 (glands with clefts that affected more than 50% of the circumference in 50% or more of the examined glands). Comparable to previous findings (127-129, 132, 133), our study demonstrated that periacinar retraction clefting is a feature of neoplastic glands in prostatic adenocarcinoma, particularly when the clefts affect more than 50% of the circumference in 50% or more of the examined glands (Figures 1 and 2A–B, Table 5).

Several suggestions have been made regarding the origin of periacinar retraction clefting and the biologic mechanisms causing the clefting in tumor specimens. Abnormalities in the basement membrane, loss of the adhesion factors, or the expression of extracellular matrix proteins or collagenases and other enzymes required for invasion are suggested to be related to the origin of periacinar retraction clefting (130, 139, 140).

Periacinar retraction cleftings have also been attributed to stromal changes and the lack of basal cells in prostatic adenocarcinoma (133, 140). *Fávaro et al.* (133) reported increased MMP-2, vimentin, IGF-1, and FGF-2 and a loss of laminin and dystroglycan positive immunolocalizations in periacinar retraction clefts in prostatic adenocarcinoma. They also reported a negative immunoreactivity for p63 in all carcinomas with periacinar retraction clefting and positive immunoreactivity in nonneoplastic samples, suggesting that the phenomenon of periacinar retraction clefting in prostatic adenocarcinoma could be related to the lack of basal cells (133).

Barsky et al. (141) suggested that retraction clefting may in fact be an early stage of lymphocapillary invasion, where the conversion of mesenchymal cells to endothelial cells has not yet been completed, and thus represent true spaces or “pseudoretraction artifact” around the tumor cells. The hypothesis that extensive retraction clefts may represent an early stage of lymphovascular invasion is also supported by the study of *Acs et al.* (136) in breast carcinoma. *Ulamec et al.* (132), however, used D2-40 antibody to highlight lymphatic endothelium and differentiate actual lymph vessels or lymphovascular invasion from periacinar retraction clefting and were able to show that the number of lymph vessels was significantly lower in prostatic adenocarcinoma than in adjacent nonneoplastic prostatic tissue.

They concluded that retractions do not represent lymph vessels but should be considered a distinct entity.

Alterations in adhesion properties of neoplastic cells play a crucial role in the development and progression of the malignant phenotype in a variety of tumors. Cadherins and catenins, as the prime mediators of cell-cell adhesion, are closely involved in the control of morphological differentiation and cellular proliferation. Loss of their intercellular function allows malignant cells to escape from their site of origin, degrade the extracellular matrix, acquire a more motile phenotype, and invade and metastasize (142, 144).

The E-cadherin-catenin complex is fundamental for the establishment and maintenance of multicellular organisms and regulates or significantly contributes to a variety of functions, such as signal transduction, cell growth, differentiation, site-specific gene expression, morphogenesis, immunologic function, wound healing, and inflammation (142-148). E-cadherin, as a Ca^{2+} dependent prime mediator of the epithelial cell-cell adhesion, functions through the cytoplasmic linkage to the actin cytoskeleton by the cytoplasmic catenin proteins (142-144).

β -catenin is involved in organogenesis and tissue morphogenesis. It plays a critical role in the regulation of cadherin-mediated cell recognition and adhesion, acting as the regulator of the cadherin-catenin component linking the signal transduction within the intercellular adhesions (144, 148).

The loss of E-cadherin-catenin immunoreactivity is reported to correlate with high grade, advanced stage, and poor prognosis in certain tissue carcinomas (144, 148-160). Expression of the E-cadherin- β -catenin complex has also been studied in prostatic adenocarcinoma (144, 154-160). *De Marzo et al.* (157) used univariate analysis to show that reduced levels of E-cadherin were correlated with advanced GSC ($P=0.003$) and advanced pathologic stage ($P=0.008$). *Jaggi et al.* (158) reported a significant downregulation of E-cadherin in GSC 7–10 prostatic adenocarcinoma compared with GSC ≤ 6 ($P=0.015$), suggesting a significant association of decreased E-cadherin with increasing grade. They also found a significant association of reduction in membranous β -catenin expression in prostatic adenocarcinoma with increasing GSC ($P=0.015$) (158). Furthermore, they reported that β -catenin was localized in the nucleus of poorly differentiated cancer cells of GSC 7–10, and that a significant correlation existed between higher GSC and nuclear β -catenin expression ($P=0.0001$) (158). They did not report any association of E-cadherin and β -catenin expression with the final pathologic stage ($P>0.05$) (158).

The expression of αv , $\alpha v\beta 3$, $\alpha 2\beta 1$, and γ -catenin were abnormal in almost every case of primary and metastatic prostatic carcinoma reported by *Pontes-Júnior et al.* (159). Marked loss of E-cadherin and $\beta 4$ integrin was found in primary and metastatic lesions (159).

Contrary to the findings of *Jaggi et al.* (158), β -catenin was normal in all primary cases and in 94% of metastases, $\alpha 6$ was normal in all primary tumors and metastases, $\alpha 3$ and $\alpha 3\beta 1$ were normal in 32% of primary cases and in 53% and 6% of metastases, respectively (159). In paired analyses, loss of E-cadherin, $\beta 4$, αv , $\alpha 3\beta 1$, and $\alpha v\beta 3$ was found in 65, 71, 59, 53 and 47% of patients, respectively (159). Catenins and $\alpha 2\beta 1$ showed maintained expression in most cases (159).

In our study, we analyzed the expression of E-cadherin and β -catenin cell adhesion proteins in prostatic adenocarcinoma and in the adjacent nonneoplastic prostatic tissue. We correlated the expression of E-cadherin and β -catenin proteins in prostatic adenocarcinoma with preoperative and postoperative GSC, sPSA, positive surgical margins, BCR, and the TNM staging. The hypothesis of our research was that periacinar retraction cleftings in prostatic adenocarcinoma are a result of decreased expression of E-cadherin and β -catenin cell adhesion proteins in the epithelial cells. Our results showed that strong intensity (score 3+)

and diffuse (>70%) membranous E-cadherin staining occurred in only 4 (7.5%) and 2 (3.8%) samples of prostatic adenocarcinoma, respectively. By contrast, in the adjacent nonneoplastic tissue, strong and diffuse (score 3+, >70%) intensity of E-cadherin staining was evident in all 53 (100%) samples.

Statistical analyses of the results confirmed a significantly higher positive pattern (intensity score 3 +, diffuse >70%) of E-cadherin staining in the adjacent prostatic nonneoplastic tissue than in prostatic adenocarcinoma ($P < 0.001$) (Figures 3A–C& 5, Table 6).

Our results confirm previously reported studies on the loss of E-cadherin membranous expression in prostatic adenocarcinoma compared to benign tissue (144, 154-160).

We found that the E-cadherin staining pattern in both prostatic adenocarcinoma and the adjacent nonneoplastic prostatic tissue was predominantly membranous and weakly cytoplasmic. Nevertheless, we did not notice any difference in the immunolocalization of the staining (membranous vs. cytoplasmic) between prostatic adenocarcinoma and the adjacent nonneoplastic prostatic tissue; therefore, we did not consider this pattern of staining as aberrant.

β -catenin showed strong intensity (score 3+) and diffuse (>70%) membranous staining in 21 (39.6%) and 25 (47.2%) samples of prostatic adenocarcinoma, respectively, and in all 53 (100%) samples of the adjacent nonneoplastic prostatic tissue. The intensity of staining was variable in our study, but β -catenin membranous staining was well preserved in 57% of prostatic adenocarcinomas. The statistical analyses of our results showed no statistically significant difference in the β -catenin intensity and percentage of membranous staining between prostatic adenocarcinoma and the adjacent prostatic nonneoplastic tissue (Table 7).

Nonetheless, in our study, heterogeneous and negative β -catenin immunostaining was seen in 18 (33.9%) and 5 (9.4%) samples of prostatic adenocarcinoma, respectively.

The pattern of staining for β -catenin in both prostatic adenocarcinoma and the adjacent nonneoplastic prostatic tissue was predominantly membranous and weakly cytoplasmic (Figures 4A–C&6). The β -catenin cytoplasmic staining was more intense than the observed E-cadherin cytoplasmic staining in both prostatic adenocarcinoma and the adjacent nonneoplastic prostatic tissue. However, we did not notice any difference in the immunolocalization of β -catenin staining (membranous vs. cytoplasmic) between prostatic adenocarcinoma and the adjacent nonneoplastic prostatic tissue; therefore, we did not consider this pattern of staining as aberrant.

Our data are in accordance with previously reported studies on decreased expression of membranous β -catenin in a certain percentage of prostatic adenocarcinomas (144,158,160-

162). Different studies, however, have set different evaluation criteria for β -catenin immunostaining, and no set recommendation exists in the literature on what should be accepted as positive immunostaining. Considering the role of β -catenin and its localization within the cell, we adopted the criteria defined by *Umbas et al.*(155) in our study, and we considered a positive pattern of β -catenin immunostaining to occur only when a strong and diffuse (score 3+, >70%) intensity of staining of the tumor cells cytoplasmic membranes was evident. *Bismar et al.* (160), however, considered a case as positive if β -catenin stained more than 10% of the tumor cells, and they reported only 16% of prostatic adenocarcinomas with decreased or negative β -catenin expression when compared to nonneoplastic prostatic glandular epithelium.

Pontes-Júnior et al. (159), who applied the same criteria for the evaluation of β -catenin as we did, compared the expression of integrins and other CAMs in primary and metastatic prostatic adenocarcinomas by tissue microarray immunostaining. They reported β -catenin expression to be positive in all primary cases and in 94% of metastases in prostatic adenocarcinoma (159). In our study, we encountered lower percentages of 39.6% (score 3+) and 57% (diffuse >70%) than was reported by *Pontes-Júnior et al.* (159) for positive β -catenin expression in prostatic adenocarcinoma.

Jaggi et al. (158) and *Chessire et al.* (163) have reported β -catenin nuclear staining in high grade prostatic adenocarcinomas (Gleason score ≥ 8). Furthermore, a similar β -catenin signaling pathway to that occurring in colorectal pathogenesis is proposed in prostatic adenocarcinoma (144, 163). In our study, however, we did not detect any nuclear β -catenin staining in prostatic adenocarcinoma. Despite the inconsistent and conflicting data in the literature regarding nuclear β -catenin detection in prostatic adenocarcinoma, our results agree with several other studies that have reported no nuclear β -catenin immunostaining in prostatic adenocarcinomas (160-162).

A very low frequency of β -catenin and APC mutations has been reported in prostatic adenocarcinoma to date, and the reported β -catenin and APC mutations are focal within prostatic adenocarcinoma. Therefore, these are not considered as tumor initiating events, as is the case with colorectal carcinoma (160).

Similar to the previously reported findings (154-157, 159, 160) on E-cadherin immunostaining expression in prostatic adenocarcinoma, we found a highly significant negative correlation between the percentage of E-cadherin staining in prostatic adenocarcinoma and preoperative GSC and positive surgical margins. Preoperative GSC, postoperative GSC, positive surgical margins, BCR, and T stage were negatively correlated

with the intensity of E-cadherin staining (Table 8). *Jaggi et al.* (158), however, did not find any correlation between the T stage and E-cadherin expression.

We did not find any correlations between E-cadherin intensity and percentage of staining and serum prostate-specific antigen(sPSA) and lymph node (N) status in prostatic adenocarcinoma.

In our study, the intensity of β -catenin staining in prostatic adenocarcinoma was significantly negatively correlated with preoperative and postoperative GSC and BCR.

Similar findings were noted with respect to the percentage of β -catenin staining in prostatic adenocarcinoma, where additional negative correlations were noted with positive surgical margins and T status (Table 9). No correlations were found between β -catenin intensity and percentage of staining and sPSA and N status. A decrease in β -catenin expression in higher grade prostatic adenocarcinoma has been reported by several other studies (160-162).

These observations suggest that E-cadherin and β -catenin cell adhesion proteins can play a potential role as markers for tumor progression and invasiveness. Nonetheless, the role of E-cadherin in maintaining cell integrity, in great part, is related to the catenin function through which it is anchored to the cytoskeleton.

In this regard, several hypotheses have been raised to explain the causes of E-cadherin loss or downregulation in prostatic adenocarcinoma, including the hypermethylation of the CpG islands in the E-cadherin gene promoter, mutational inactivation of the E-cadherin gene itself, homozygous deletion of the α -catenin gene, and increased tyrosine phosphorylation of the β -catenin gene (144, 155). This suggests that in low grade prostatic tumors, E-cadherin might be dysfunctional but its IHC expression is preserved.

Our results also support a role for β -catenin signaling in prostatic adenocarcinoma pathogenesis. β -catenin is a multifunctional protein that controls a number of cell activities, sometimes at the membrane, and sometimes in the nucleus as a transcription co-factor.

Nevertheless, contrary to the findings reported by *Jaggi et al.* (158) and *Chessire et al.* (163), we consider that the signaling pathway in prostatic adenocarcinoma differs from that occurring in colorectal tumorigenesis. The β -catenin role in prostate is more likely to be that of a cell adhesion molecule rather than a signal transduction component.

We also found a correlation between the expression of E-cadherin and β -catenin cell adhesion proteins and prostatic adenocarcinoma with periacinar retraction clefting. Our hypothesis was that periacinar retraction clefting in prostatic adenocarcinoma is a result of decreased expression of E-cadherin and β -catenin cell adhesion proteins in epithelial cells of

prostatic adenocarcinoma. Our results show that periacinar retraction clefting in prostatic adenocarcinoma is significantly positively correlated with the intensity of E-cadherin staining in prostatic adenocarcinoma ($\rho= 0.398$; $P=0.003$) and the percentage of E-cadherin staining in prostatic adenocarcinoma ($\rho= 0.367$; $P=0.007$) (Figure 7A–B, Table 10). We also encountered a statistically significant positive correlation between the intensity of β -catenin staining ($\rho= 0.374$; $P=0.006$) and percentage of β -catenin staining ($\rho=0.347$; $P=0.011$), and the extent of periacinar retraction clefting in prostatic adenocarcinoma (Figure 8A–B, Table 11). The correlation between E-cadherin and β -catenin IHC staining and periacinar retraction clefting in prostatic adenocarcinoma has not been previously studied.

Our results did not confirm our hypothesis that periacinar retraction clefting in prostatic adenocarcinoma is a result of decreased expression of E-cadherin and β -catenin cell adhesion proteins in epithelial cells of prostatic adenocarcinoma. Instead, we encountered a positive correlation between the E-cadherin and β -catenin expression and periacinar retraction clefting in prostatic adenocarcinoma. We consider this finding to be in concordance with the idea that periacinar retraction clefting in prostatic adenocarcinoma is more of a characteristic feature for Gleason pattern 3 adenocarcinomas (131,133). E-cadherin and β -catenin IHC expression decrease with increasing histopathological tumor grade (144,160). Therefore, E-cadherin expression was mainly preserved in the glands of low grade tumors of GSC 6, which had the most extensive periacinar halos in our study.

However, in 4 (7.54%) samples of prostatic adenocarcinoma GSC 7 (4+3), with a heterogeneous, mixed population of positive and negative cells, E-cadherin staining was weak to negative in the cells of the tumor glands that had pulled away from the stroma and had periacinar halo of more than 50% of the circumference, whereas positive immunostaining was seen in the tumor glands with no periacinar retraction clefts (Figure 7B–C). This suggests that the decreased membranous expression of E-cadherin might have a role in the origin of periacinar retraction clefting in higher grade tumors.

7. CONCLUSIONS AND IMPLICATIONS FOR FURTHER RESEARCH

- Periacinar retraction clefting is significantly more extensive in prostatic adenocarcinoma than in nonneoplastic prostatic tissue ($P < 0.001$). Therefore, periacinar retraction clefting can be used as a reliable criterion in making the diagnosis of prostatic adenocarcinoma, particularly when clefts affect more than 50% of the circumference in 50% or more of the examined glands.
- The pattern of E-cadherin immunostaining in both prostatic adenocarcinoma and in nonneoplastic prostatic tissue is predominantly membranous and weakly cytoplasmic. However, a significantly higher positive (intensity score 3+, diffuse >70%.) expression of E-cadherin staining occurs in nonneoplastic prostatic tissue compared to prostatic adenocarcinoma ($P < 0.001$).
- The intensity of E-cadherin staining in prostatic adenocarcinoma was negatively correlated with preoperative GSC ($P < 0.001$), postoperative GSC ($P < 0.001$), positive surgical margins ($P = 0.024$), BCR ($P = 0.017$), and T stage ($P < 0.001$), whereas the percentage of E-cadherin staining was negatively correlated with postoperative GSC ($P = 0.002$) and positive surgical margins ($P = 0.013$). These observations suggest that E-cadherin may potentially serve as a marker for tumor progression and invasiveness.
- The pattern of β -catenin immunostaining in both prostatic adenocarcinoma and in nonneoplastic tissue was predominantly membranous and weakly cytoplasmic. The intensity of β -catenin staining in prostatic adenocarcinoma was significantly negatively correlated with preoperative and postoperative GSC ($P < 0.001$) and BCR ($P = 0.048$), whereas β -catenin percentage of staining negatively correlated with preoperative GSC ($P < 0.001$) and postoperative GSC ($P = 0.005$), positive surgical margins ($P = 0.048$), BCR ($P = 0.004$), and T stage ($P = 0.032$).
- E-cadherin and β -catenin expression were positively correlated with the extent of periacinar retraction clefting in prostatic adenocarcinoma glands: intensity of E-cadherin staining ($\rho = 0.398$; $P = 0.003$), percentage of E-cadherin ($\rho = 0.367$; $P = 0.007$), intensity of β -catenin staining ($\rho = 0.374$; $P = 0.006$) and percentage of β -catenin ($\rho = 0.347$; $P = 0.011$).
- A decreased expression of E-cadherin was noticed in the cells of glands with extensive periacinar retraction clefting in higher grade prostatic adenocarcinomas when compared to the tumor glands with no clefting. This suggests that decreased expression of E-cadherin might have a role in the origin of periacinar retraction clefting in higher grade tumors.

8. ABSTRACT

Periacinar retraction clefting represents a criteria favoring prostatic adenocarcinoma diagnosis. In the present study, tissues from 53 cases of prostate morphologically diagnosed as prostatic adenocarcinoma and the adjacent nonneoplastic prostatic tissue were evaluated for the presence and the extent of periacinar retraction clefting. Immunohistochemistry (IHC) was used to evaluate the expression of E-cadherin and β -catenin, and this expression was compared with GSC, sPSA, positive surgical margins, BCR, TNM stage, and periacinar retraction clefting.

Our study confirmed that periacinar retraction clefting is significantly more extensive in prostatic adenocarcinoma than in nonneoplastic prostatic tissue ($P < 0.001$). We found a decreased expression of E-cadherin and β -catenin in prostatic adenocarcinoma and a negative correlation with GSC, positive surgical margins, BCR, and T stage.

Periacinar clefting was positively correlated with the intensity of E-cadherin staining ($\rho = 0.398$; $P = 0.003$), the percentage of E-cadherin staining ($\rho = 0.367$; $P = 0.007$), the intensity of β -catenin staining ($\rho = 0.374$; $P = 0.006$) and the percentage of β -catenin staining ($\rho = 0.347$; $P = 0.011$) in prostatic adenocarcinoma. However, in 4 (7.54%) samples with Gleason score (GSC) 7 (4+3) and with a mixed population of positive and negative cells, E-cadherin staining was weak to negative in the cells of tumor glands with periacinar clefts and positive in tumor glands with no periacinar clefts. This suggests that E-cadherin might play a role in the origin of periacinar clefting in higher grade tumors.

9. SAŽETAK

Periacinarne pukotine predstavljaju jedan od kriterija za dijagnozu adenokarcinoma prostate. U 53 slučajeva prostate s morfološkom dijagnozom adenokarcinoma i u okolnom neneoplastičnom tkivu prostate, određena je prisustnost i izraženost periacinarnih pukotina, i imunohistokemijska izraženost E-kadherina i β -katenina u usporedbi s Gleason zbrojem, sPSA, pozitivnim kirurškim rubovima, biokemijskim povratkom bolesti, TNM stadijem i periacinarnim pukotinama.

Naša studija potvrđuje da su periacinarne pukotine znatno jače izražene u adenokarcinomu nego u benignom tkivu prostate ($p < 0,001$).

Rezultati istraživanja pokazuju smanjenu izraženost E-kadherina i β -katenina u adenokarcinomu prostate i negativnu korelaciju s Gleason zbrojem, pozitivnim kirurškim rubovima, biokemijskim povratkom bolesti i T stadijem.

Izraženost periacinarnih pukotina je pozitivno povezana s intenzitetom ekspresije E-kadherina ($p = 0.398$; $P = 0,003$), postotkom ekspresije E-kadherina ($p = 0.367$; $p = 0.007$), intenzitetom β -katenina ($p = 0.374$; $p = 0,006$) i postotkom ekspresije β -katenina ($\rho = 0.347$; $P = 0.011$) bojenja u adenokarcinomu prostate.

U 4 (7.54%) uzoraka, Gleason zbroj 7 (4 + 3), s mješovitom populacijom pozitivnih i negativnih stanica, bojenje na E-kadherin je slabo do negativno u stanicama žlijezda s periacinarnim pukotinama i pozitivno u žlijezdama tumora bez periacinarnih pukotina. To sugerira da E-kadherin može imati ulogu u nastanku periacinarnih pukotina u tumorima prostate s većim gradusom.

10. REFERENCES

1. Mc Neal JE. Developmental and comparative anatomy of the prostate. In: Grayhack J, Wilson J, Scherbenske M, eds. Benign Prostatic Hyperplasia. DHEW publication no. (NIH) 76-1113. Washington DC: Department of Health, Education and Welfare; 1975:1-10.
2. Cunha GR, Donjacour AA. Mesenchymal–epithelial interactions in the growth development of the prostate. In: Lepor H, Ratliff TL, eds. Urologic Oncology. Boston: Kluwer Academic; 1989:159-175.
3. Hricak H, Scardino P (eds.) Prostate cancer. Cambridge University Press 2009: 1-14.
4. Drake RL, Vogl AW, Mitchell AWM (eds) Gray's Anatomy for Students. Elsevier Churchill Livingstone, 2 ed. 2010:406-504.
5. Mc Neal JE. Normal histology of the prostate. Am J Surg Pathol. 1988; 12:619-33.
6. Mills SE (eds). Histology for pathologists. Lippincot Williams & Wilkins, 3 ed. 2007: 923-942.
7. Bonkhoff H, Remberger K. Differentiation pathways and histogenetic aspects of normal and abnormal prostatic growth: a stem cell model. Prostate. 1996; 28:98-106.
8. di Sant'Agnesse PA. Neuroendocrine differentiation in prostatic carcinoma. Cancer. 1995; 75:1850-1859.
9. Srodon M, Epstein JI. Central zone histology of the prostate: a mimicker of high-grade prostatic intraepithelial neoplasia. Hum Pathol. 2002; 33:518-523.
10. Taylor BC, Wilt TJ, Fink HA, et al. Prevalence, severity, and health correlates of lower urinary tract symptoms among older men: the MrOS study. Urology. 2006; 68:804–809.
11. Isaacs JT, Coffey DS. Etiology and disease process of benign prostatic hyperplasia. Prostate. 1989; 2:33-50.
12. Sanda MG, Beaty TH, Stutzman RE, et al. Genetic susceptibility of benign prostatic hyperplasia. J Urol.1994;152:115–119.
13. Untergasser G, Madersbacher S, Berger P. Benign prostatic hyperplasia: age-related tissue-remodeling. Exp Gerontol. 2005; 40:121–128.
14. Pearson JD, Lei HH, Beaty TH, et al. Familial aggregation of bothersome benign prostatic hyperplasia symptoms. Urology. 2003; 61:781-785.

15. Kirby RS, McConell JC , Fitzpatrick JM, Roerhborn CG, Boyle P (eds) Textbook of Benign Prostatic Hyperplasia. Taylor & Francis Group. 2 ed 2005: 98-100.
16. Franks LM. Benign nodular hyperplasia of the prostate: a review. *Ann R Coll Surg Engl.* 1953; 14:92-106.
17. Hansel DE, Herawi M, Montgomery E, Epstein JI. Spindle cell lesions of the adult prostate. *Mod Pathol.* 2007; 20: 148-158.
18. Edward JL. Diagnosis and management of benign prostatic hyperplasia. *Am Fam Physician.* 2008; 77:1403-1410.
19. Roerhborn CG, McConnell JD. Etiology, pathophysiology, epidemiology and natural history of benign prostatic hyperplasia. In: Campbell MF, Walsh PC, Retz AB. *Campbell's Urology.* 8th ed. Philadelphia, Pa.: Saunders; 2002:1297–1330.
20. Bostwick DG, Qian J. High-grade prostatic intraepithelial neoplasia. *Mod Pathol.* 2004; 17:360–379.
21. Bostwick DG, Cheng L. Precursors of prostate cancer. *Histopathology.* 2012; 60:4–27.
22. Brawer MK. Prostatic intraepithelial neoplasia: an overview. *Rev Urol.* 2005; 7(Suppl 3):S11–S18.
23. Klink JC, Miocinovic R, Magi Galluzzi C, Klein EA. High-grade prostatic intraepithelial neoplasia. *Korean J Urol.* 2012; 53:297-303.
24. Zynger, DL, Yang, X. High-grade prostatic intraepithelial neoplasia of the prostate: the precursor lesion of prostate cancer. *Int J Clin Exp Pathol.* 2009; 2:327–338.
25. Shohreh ID. Premalignant and malignant prostate lesions: pathologic review. *Cancer Control.* 2010; 17:214-222.
26. Srigley JR. Benign mimickers of prostatic adenocarcinoma. *Mod Pathol.* 2004; 17:328-348.
27. Humphrey PA. Atypical adenomatous hyperplasia (adenosis) of the prostate. *J Urol.* 2012; 188:2371-2372.
28. Billis A. Prostatic atrophy: an autopsy study of a histologic mimic of adenocarcinoma. *Mod Pathol.* 1998; 11:47-54.
29. De Marzo AM, Platz EA, Epstein JI, et al. A working group classification of focal prostate atrophy lesions. *Am J Surg Pathol.* 2006; 30:1281-1291.
30. De Marzo AM, Marchi VL, Epstein JI, Nelson WG. Proliferative inflammatory atrophy of the prostate: implications for prostatic carcinogenesis. *Am J Pathol.* 1999; 155:1985-1992.

31. Putzi MJ, De Marzo AM. Morphologic transition between proliferative inflammatory atrophy and high grade intraepithelial neoplasia. *Urology*. 2000; 56:828-832.
32. Wang W, Bergh A, Damber JE. Morphological transition of proliferative inflammatory atrophy to high grade intraepithelial neoplasia and cancer in human prostate. *Prostate*. 2009; 69:1378-1386.
33. De Marzo AM, Meeker AK, Zha S, et al. Human prostate cancer precursors and pathobiology. *Urology*. 2003; 62:55-62.
34. Tomas D, Krušlin B, Rogatsch H, Schaefer G, Belicza M, Mikuz G. Different types of atrophy in the prostate with and without adenocarcinoma. *Eur Urol*. 2007; 51:98-103.
35. Billis A, Magna LA. Inflammatory atrophy of the prostate. Prevalence and significance. *Arch Pathol Lab Med*. 2003; 127:840-844.
36. GLOBOCAN 2012: Estimated cancer incidence, mortality and prevalence worldwide in 2012.
37. Cancer facts & figures 2014. American Cancer Society, Inc 2014.
38. Bostwick DG, Burke HB, Djakiew D, et al. Human prostate cancer risk factors. *Cancer*. 2004; 101:2371-2490.
39. Cooperberg MA. Re- examining racial disparities in prostate cancer outcomes. *J Clin Oncol*. 2013; 31:2979-2980.
40. Altekruse SF, Kosary CL, Krapcho M, et al: SEER cancer statistics review, 1975-2007. Bethesda, Md: National Cancer Institute, 2010.
41. Whittemore AS, Kolonel LN, Wu AH, et al. Prostate cancer in relation to diet, physical activity, and body size in blacks, whites, and Asians in the United States and Canada. *J Natl Cancer Inst*. 1995; 87:652-661.
42. Ito K. Prostate cancer in Asian men. *Nat Rev Urol*. 2014; 11:197-212.
43. Kicinski M, Vangronsveld J, Nawrot TS. An epidemiological reappraisal of the familial aggregation of prostate cancer: a meta-analysis. *PLoS One*. 2011; 6:e27130.
44. Brandt A, Bermejo JL, Sundquist J, et al. Age specific risk of incident prostate cancer and risk of death from prostate cancer defined by the number of affected family members. *Eur Urol*. 2010; 58:275-280.
45. Agalliu I, Karlins E, Kwon EM, et al. Rare germline mutations in the BRCA2 gene are associated with early onset prostate cancer. *Br J Cancer*. 2007; 97:826-831.
46. Hartman TJ, Dorgan JF, Woodson K, et al. Effects of long term alpha tochopehrol supplementation on serum hormones in older men. *Prostate*. 2001; 46:33-38.

47. Brooks JD, Metter EJ, Chan DW, et al. Plasma selenium level before diagnosis and the risk of prostate cancer development. *J Urol.* 2001; 166:2034-2038.
48. Gann PH. Risk factors for prostate cancer. *Rev Urol.* 2002; 4(Suppl 5):S3-S10.
49. Rowlands MA, Holly JM, Gunnell D, et al. Circulating insulin-like growth factors and IGF-binding proteins in PSA-detected prostate cancer: the large cohort-control study Protec T. *Cancer Res.* 2012; 72:503-515.
50. Bansal D, Bhansali A, Kapil G, Undela K, Tiwari P. Type 2 diabetes and risk of prostate cancer: a meta-analysis of observational studies. *Prostate Cancer Prostatic Dis.* 2013; 16:151-158.
51. Hamilton W, Sharp JD, Peters TJ, Round AP. Clinical features of prostate cancer before diagnosis: a population-based, case-control study. *Br J Gen Pract.* 2006; 56:756-762.
52. Hoffman RM. Screening for prostate cancer. *N Engl J Med.* 2011; 365:2013-2019.
53. Ries L, Eisner MP, Kosary CL, et al. SEER cancer statistics reviews, 1973-1999, National Cancer Institute, Bethesda, MD 2002.
54. Draisma G, Boer R, Otto SJ, et al. Lead times and overdiagnosis due to prostate-specific antigen screening: estimates from the European randomized study of screening for prostate cancer. *J Natl Cancer Inst.* 2003; 95:868.
55. Whittemore AS, Cirillo PM, Feldman D, Cohn BA. Prostate specific antigen levels in young adulthood predict prostate cancer risk results from a cohort of black and white Americans. *J Urol.* 2005; 174:872-876.
56. Thompson IM, Paulaeer DK, Goodman PJ, et al. Prevalence of prostate cancer among men with prostate-specific antigen level \leq 4.0 ng per milliliter. *N Engl J Med.* 2004; 27:2239-2246.
57. Wolf AM, Wender RC, Etzioni RB, et al. American cancer Society Prostate Cancer Advisory Committee. American Cancer Society Guidelines for the early detection of prostate cancer: update 2010. *Ca Cancer J Clin.* 2010; 60:70.
58. Catalona WJ, Smith DS, Ornstein DK. Prostate cancer detection in men with serum PSA concentrations of 2.6 to 4.0 ng/ml and benign prostate examination. Enhancement of specificity with free PSA measurements. *JAMA.* 1997; 277:1452.
59. Thompson IM, Ankerst DP, Chi C, et al. Operating characteristics of prostate specific antigen in men with an initial PSA level of 3.0 ng/ml or lower. *JAMA.* 2005; 294:66.
60. Carter HB. Prostate cancers in men with low PSA levels- must we find them? *N Engl J Med.* 2004; 350:2292.

61. Partin AW, Kattan MW, Subong EN, et al. Combination of prostate-specific antigen, clinical stage and Gleason score to predict pathological stage of localized prostate cancer. A multi-institutional update. *JAMA* .1997; 277:1445-1451.
62. Bradley LA, Palomaki GE, Gutman S, Samson D, Aronson N. Comparative effectiveness review: prostate cancer antigen 3 testing for the diagnosis and management of prostate cancer. *J Urol*. 2013; 190:389-398.
63. Amin M, Bococn-Gibod L, Egevad L, et al. Prognostic and predictive factors and reporting of prostate carcinoma in prostate needle biopsy specimens. *Scand J Urol Nephrol Suppl*. 2005; 216:20-33.
64. Lughezzani G, Sun M, Budaus L, et al. Effect of the number of biopsy cores on prostate cancer detection and staging. *Future Oncol*. 2010; 6:381-390.
65. Fine SW, Amin MB, Berney MB, et al. A contemporary update on pathology reporting for prostate cancer. Biopsy and radical prostatectomy specimens. *Eur Urol*. 2012; 62:20-39.
66. Taneja SS, Carter HB, Schellhammer P, et al. White Paper: AUA/optimal techniques of prostate biopsy and specimen handling 2013.
67. Welch HG, Albertsen PC. Prostate cancer diagnosis and treatment after the introduction of prostate-specific antigen screening: 1986-2005. *J Natl Cancer Inst*. 2009; 101:1325.
68. Epstein JI, Algaba F, Allsbrook WC, et al. Tumours of the prostate. In: *Pathology and Genetics of Tumours of the Urinary System and Male Genital Organs*, JN Elbe, G Sauter, JI Epstein, IA Sesterhenn, eds. WHO, IARC Press, Lyon, 2004:159-215.
69. Epstein JI, Netto GJ (eds). *Biopsy interpretation of the prostate*. Biopsy interpretation series. Philadelphia: Lippincott Williams and Wilkins; 4th ed 2008:35-41.
70. De Marzo AM, Nelson WG, Isaacs WB, et al. Pathological and molecular aspects of prostate cancer. *Lancet*. 2003; 361:955-964.
71. Baisden BL, Kahana H, Epstein JI. Perineural invasion, mucinous fibroplasias, and glomerulations: diagnostic features of limited cancer on prostate needle biopsy. *Am J Surg Pathol*. 1999; 23:918-924.
72. Halpert B, Sheehan EA, Schmalhorst WR, et al. Carcinoma of the prostate: a survey of 5000 autopsies. *Cancer*. 1963; 16:737-742.
73. Gleason DF. Classification of prostatic carcinomas. *Cancer Chemother Rep*. 1966; 50:125-128.

74. Gleason DF, Mellinger GT. The Veterans Administration Cooperative Urological Research Group. Prediction of prognosis for prostatic adenocarcinoma by combined histological grading and clinical staging. *J Urol*. 1974; 111:58-64.
75. Gleason DF. Histological grading and clinical staging of prostate carcinoma. In: Tannenbaum M ed. *Urologic Pathology: The Prostate*. Philadelphia: Lea & Feibiger. 1977:171-198.
76. Epstein JI, Allsbrook WC Jr, Amin MB, et al. The 2005 International Society of Urological Pathology (ISUP) consensus conference on Gleason grading of prostatic carcinoma. *Am J Surg Pathol*. 2005; 29:1228-1242.
77. Humphrey PA. Gleason grading and prognostic factors in carcinoma of the prostate. *Mod Pathol*. 2004; 17:292-306.
78. Epstein JI, Zelefsky MJ, Sjoberg DD, et al. A contemporary prostate cancer grading system: a validated alternative to the Gleason Score [published online ahead of print July 9, 2015]. *Eur Urol*. doi: 10.1016/j.eururo.2015.1006.1046.
79. Pierorazio PM, Walsh PC, Partin AW, Epstein JI. Prognostic Gleason grade grouping: Data based on the modified Gleason scoring system. *BJU Int*. 2013; 111:753-760.
80. Humphrey PA. Histological variants of prostatic carcinoma and their significance. *Histopathology*. 2012; 60:59-74.
81. Mc Neal JE, Alroy J, Villers A, et al. Mucinous differentiation in prostatic adenocarcinoma. *Hum Pathol*. 1991; 22:979-988.
82. Grignon DJ. Unusual subtypes of prostate cancer. *Mod Pathol*. 2004; 17:316-327.
83. Arista-Nasr J, Martinez Benitez B, Valdes S, Hernandez M, Bornstein-Quevedo I. Pseudohyperplastic prostatic adenocarcinoma in transurethral resections of the prostate. *Pathol Oncol Res*. 2003; 9:232-235.
84. Hudson J, Cao D, Vollmer R, Kibel AS, Grewal S, Humphrey PA. Foamy gland adenocarcinoma of the prostate: Incidence, Gleason grade, and early clinical outcome. *Hum Pathol*. 2012; 43:974-979.
85. Epstein JI. Prostatic ductal adenocarcinoma: A mini review. *Med Princ Pract*. 2010; 18:82-85.
86. Oliai BR, Kahane H, Epstein JI. A clinicopathologic analysis of urothelial carcinomas diagnosed on prostate needle biopsy. *Am J Surg Pathol*. 2001; 25:794-801.
87. Iczkowski KA, Ferguson KL, Grier DD, et al. Adenoid cystic/basal cell carcinoma of the prostate: clinicopathologic findings in 19 cases. *Am J Surg Pathol*. 2003; 27:1523-1529.

88. Yaskiv O, Cao D, Humphrey PA. Microcystic adenocarcinoma: a variant of pseudohyperplastic atrophic patterns. *Am J Surg Pathol.* 2010; 34:556-561.
89. Hameed O, Humphrey PA. Stratified epithelium in prostatic carcinoma: a mimic of high-grade prostatic intraepithelial neoplasia. *Mod Pathol.* 2006; 19:899–906.
90. Tavora F, Epstein JI. High-grade prostatic intraepithelial-like ductal adenocarcinoma of the prostate: a clinicopathologic study of 28 cases. *Am J Surg Pathol.* 2008; 32: 1060–1067.
91. Evans AJ, Humphrey PA, Belani J, van der Kwast TH, Srigley JR. Large cell carcinoma of prostate: a clinicopathologic summary of 7 cases of a rare manifestation of advanced prostate cancer. *Am J Surg Pathol.* 2006; 30:684–693.
92. Parwani AV, Herawi M, Epstein JI. Pleomorphic giant cell adenocarcinoma of the prostate: report of 6 cases. *Am J Surg Pathol.* 2006; 30:1254–1259.
93. Svensson MA, LaFargue CJ, MacDonald TY, et al. Testing mutual exclusivity of ETS rearranged prostate cancer. *Lab Invest.* 2011; 91: 404–412.
94. Lindberg J, Klevebring D, Liu W, et al. Exome sequencing of prostate cancer supports the hypothesis of independent tumour origins. *Eur Urol.* 2103; 63:347–353.
95. Cooper CS, Eeles R, Wedge DC, et al. Analysis of the genetic phylogeny of multifocal prostate cancer identifies multiple independent clonal expansions in neoplastic and morphologically normal prostate tissue. *Nat Genet.* 2015; 47:367–372.
96. Gundem G, Van Loo P, Kremeyer B, et al. The evolutionary history of lethal metastatic prostate cancer. *Nature.* 2015; 520:353–357.
97. Taylor BS, Schultz N, Hieronymus H, et al. Integrative genomic profiling of human prostate cancer. *Cancer Cell.* 2010; 18:11–22.
98. Lawrence MS, Stojanov P, Mermel CH, et al. Discovery and saturation analysis of cancer genes across 21 tumour types. *Nature.* 2014; 505:495–501.
99. Shen MM, Shen CA. Molecular genetics of prostate cancer: new prospects for old challenges. *Genes Dev.* 2010; 24:1967-2000.
100. Chen H, Tu SW, Hsieh JT. Down-regulation of human DAB2IP gene expression mediated by polycomb Ezh2 complex and histone deacetylase in prostate cancer. *J Biol Chem.* 2005; 280:2243–2244.
101. Clark J, Merson S, Jhavar S, Flohr P, et al. Diversity of TMPRSS2-ERG fusion transcripts in the human prostate. *Oncogene.* 2007; 26:2667–2673.
102. Shen MM, Abate-Shen C. Pten inactivation and the emergence of androgen-independent prostate cancer. *Cancer Res.* 2007; 67:6535–6538.

103. Mellingshoff IK, Vivanco I, Kwon A, Tran C, Wongvipat J, Sawyers CL. 2HER2/neu kinase-dependent modulation of androgen receptor function through effects on DNA binding and stability. *Cancer Cell*.2004; 6:517–527.
104. Fizazi K. The role of Src in prostate cancer. *Ann Oncol*. 2007; 18:1765–1773.
105. Bachmann IM, Halvorsen OJ, Collett K, et al. EZH2 expression is associated with high proliferation rate and aggressive tumor subgroups in cutaneous melanoma and cancers of the endometrium, prostate, and breast. *J Clin Oncol*. 2006; 24:268–273.
106. Cao Q, Yu J, Dhanasekaran SM, et al. Repression of E-cadherin by the polycomb group protein EZH2 in cancer. *Oncogene*.2008; 27:7274–7284.
107. Chen H, Tu SW, Hsieh JT. Down-regulation of human DAB2IP gene expression mediated by polycomb Ezh2 complex and histone deacetylase in prostate cancer. *J Biol Chem*. 2005; 280:22437–22444.
108. Min J, Zaslavsky A, Fedele G, et al. An oncogene-tumor suppressor cascade drives metastatic prostate cancer by coordinately activating Ras and nuclear factor- κ B. *Nat Med*. 2010; 16:286–294.
109. Meeker AK, Hicks JL, Platz EA, et al. Telomere shortening is an early somatic DNA alteration in human prostate tumorigenesis. *Cancer Res*. 2002; 62:6405-6409.
110. Nelson WG, De Marzo AM, Dewese TL, et al. Preneoplastic prostate lesions: an opportunity for prostate cancer prevention. *Ann NY Acad Sci*. 2001; 952:135-144.
111. Wu CL, Yang XJ, Tretiakova M, et al. Analysis of alpha-methylacyl-CoA racemase (P504S) expression in high-grade prostatic intraepithelial neoplasia. *Hum Pathol*. 2004; 35:1008-1013.
112. Cheng L, Montironi R, Bostwick DG, Lopez-Beltran A, Berney DM. Staging of prostate cancer. *Histopathology*. 2012; 60:87-117.
113. D’Amico AV, Whittington R, Malkowicz S, et al. Biochemical outcome after radical prostatectomy, external beam radiation therapy, or interstitial radiation therapy for clinically localized prostate cancer. *JAMA*. 1998; 280:969-974.
114. Kumar-Sinha C, Chinnaiyan AM. Molecular markers to identify patients at risk for recurrence after primary treatment for prostate cancer. *Urology*. 2003; 62:19-35.
115. Mohler J, Bahnson RR, Boston B, et al. NCCN clinical practice guidelines in oncology: prostate cancer. *J Natl Compr Canc Netw*. 2010; 8:162-200.
116. NCCN guidelines on prostate cancer, version 2. 2014. National Comprehensive Cancer Network Web site.
http://www.nccn.org/professionals/physician_gls/pdf/prostate.pdf.

117. Locke JA, Pra AD, Supiot S, Warde P, Bristow RG. Synergistic action of image-guided radiotherapy and androgen deprivation therapy. *Nat Rev Urol*. 2015; 12: 193-204.
118. Aus G, Abbou CC, Bolla M, et al, and European Association of Urology. EAU guidelines on prostate cancer *European Urology*. 2005; 48:546-551.
119. Klotz L, Zhang L, Lam A, Nam R, Mamedov A, and Loblaw A. Clinical results of long-term follow-up of a large, active surveillance cohort with localized prostate cancer. *J Clin Oncol*. 2010; 28:126-131.
120. Bruce JY, Lang JM, McNeel DG, Liu G. Current controversies in the management of biochemical failure in prostate cancer. *Clin Adv Hematol Oncol*. 2012; 10:716-722.
121. Thompson I, Thrasher JB, Aus G, et al. Guideline for the management of clinically localized prostate cancer: 2007 Update. *J Urol*. 2007; 177:2106–2131.
122. Mason M, Moffat L. *Prostate Cancer*. 2nd ed. 2010 *The Facts*. New York: Oxford University Press.
123. Ranjan P, Saurabh G, Bansal R, Gupta A. High intensity focused ultrasound vs. cryotherapy as primary treatment for prostate cancer. *Indian J Urol*. 2008; 24:16-21.
124. Berthold DR, Pond GR, Soban F, de Wit R, Eisenberger M, Tannock IF. Docetaxel plus prednisone or mitoxantrone plus prednisone for advanced prostate cancer: updated survival in the TAX 327 study. *J Clin Oncol*. 2008; 26:242-245.
125. Tollefson MK, Karnes RJ, Rangel LJ, Bergstralh EJ, Boorjian SA. The impact of clinical stage on prostate cancer survival following radical prostatectomy. *J Urol*. 2013; 189:1707-1712.
126. Varma M, Lee MW, Tamboli P, et al. Morphologic criteria for the diagnosis of prostatic adenocarcinoma in needle biopsy specimens. *Arch Pathol Lab Med*. 2002; 126:554-561.
127. Krušlin B, Tomas D, Rogatsch H, et al. Periacinar retraction clefting in the needle core biopsies: an important diagnostic criterion or a simple artifact? *Virchows Arch*. 2003; 443:524-527.
128. Krušlin B, Tomas D, Rogatsch H, et al. Correlation of periacinar retraction clefting in needle core biopsies and corresponding prostatectomy specimens of patients with prostatic adenocarcinoma. *Int J Surg Pathol*. 2006; 20:51-57.

129. Ulamec M, Tomas D, Ensinger C, et al. Periacinar retraction clefting in proliferative prostatic atrophy and prostatic adenocarcinoma. *J Clin Pathol.* 2007; 60:1098-10101.
130. Irie J, Manucha V, Ioffe OB, et al. Artefact as the pathologist's friend: Peritumoral retraction in in situ and infiltrating duct carcinoma of the breast. *Int J Surg Pathol.* 2007; 15:53-59.
131. Young RH, Srigley JR, Amin MB, et al. Atlas of Tumor pathology. AFIP, Washington, 1998:124-171.
132. Ulamec M, Džombeta T, Cupić H, Leniček T, Tomas D, Krušlin B. Peracinar retraction clefting and d2-40 expression in prostatic adenocarcinoma. *Pathol Oncol Res.* 2012; 18:365-370.
133. Fávoro WJ, Hetzl AC, Reis LO et al. Periacinar retraction clefting in nonneoplastic and neoplastic prostatic glands: artifact or molecular involvement. *Pathol Oncol Res.* 2012; 18:285-292.
134. Acs G, Paragh G, Chuang ST, et al. The presence of micropapillary features and retraction artifact in core needle biopsy material predicts lymph node metastasis in breast carcinoma. *Am J Surg Pathol.* 2009; 33:202-210.
135. Acs G, Dumoff KL, Solin LJ, et al. Extensive retraction artifact correlates with lymphatic invasion and nodal metastasis and predicts poor outcome in early stage breast carcinoma. *Am J Surg Pathol.* 2007; 31:129-140.
136. Acs G, Khakpour N, Kiluk J, et al. The presence of extensive retraction clefts in invasive breast carcinomas correlates with lymphatic invasion and nodal metastasis and predicts poor outcome. A prospective validation of 2742 consecutive cases. *Am J Surg Pathol.* 2015; 39:323-337.
137. Tomas D, Spajić B, Milošević M, et al. Extensive retraction artifact predicts biochemical recurrence free survival in prostatic carcinoma. *Histopathology.* 2011; 58:447-454.
138. Bujas T, Pavić I, Leniček T, et al. Peritumoral retraction clefting correlates with advanced stage squamous cell carcinoma of the esophagus. *Pathol Oncol Res.* 2008; 14:443-447.
139. Tuxhorn JA, Ayala GE, Rowley DR. Reactive stroma in prostate cancer progression. *J Urol.* 2001; 166:2472-2483.
140. Tomas D, Krušlin B. The potential value of (myo)fibroblastic stromal reaction in the diagnosis of prostatic adenocarcinoma. *Prostate.* 2004; 61:324-331.

141. Barsky SH, Ye Y, Karlin NJ. "Separation artifact" v Lymphovascular invasion: are mimics only mimics? *Mod Pathol.* 2006; 19:289A.
142. Takeichi M. Cadherins in cancer; implications for invasion and metastasis. *Curr Opin Cell Biol.* 1993; 5:806-811.
143. Pećina-Šlaus N. E-cadherin role in normal and malignant cells. *Cancer Cell Int.* 2003; 3:17.
144. Hamilton G (eds). *Advances in prostate cancer.* INTECH 2013: 641-664.
145. Conde IR, Drasdo D, Anderson ARA,Chaplain MAJ. Modeling the influence of the E-Cadherin- β -Catenin pathway in cancer cell invasion: A multiscale approach. *biophys J.* 2008; 95:155-165.
146. Harington KJ, Syrigos KN. The role of E-cadherin-Catenin complex: More than an intercellular glue? *Ann Surg Oncol.* 2000; 10:783-788.
147. Foty R, Steinberg M. Cadherin mediated cell-cell adhesion and tissue segregation in relation to malignancy. *Int J Dev Biol.* 2004; 48:397-409.
148. Hirohashi H. Inactivation of the E-cadherin mediated cell adhesion system in human cancers. *Am J Pathol.* 1998; 153:333-339.
149. Berx G, Van Roy F. The E Cadherin/catenin complex: an important gatekeeper in breast cancer tumorigenesis and malignant progression. *Breast Cancer Res.* 2001; 3:289-293.
150. Chen HC, Chu RY, Hsu PN, et al. Loss of E-cadherin expression correlates with poor differentiation and invasion into adjacent organs in gastric adenocarcinomas. *Cancer Lett.* 2003; 201:97-106.
151. Sun W, Herrera GA. E-Cadherin expression in urothelial carcinoma in situ, superficial papillary transitional cell carcinoma, and invasive transitional cell carcinoma. *Hum Pathol.* 2002; 33:996-1000.
152. Kanazawa T, Watanabe T, Kazama S, et al. Poorly differentiated adenocarcinoma and mucinous carcinoma of the colon and rectum show higher rates of heterozygosity and loss of E-cadherin expression due to methylation of promoter region. *Int J Cancer.* 2002; 102:225-229.
153. Takayama T, Shiozaki H, Shibamoto S, et al. β -catenin expression in human cancers. *Am J Pathol.* 1996; 148:39-46.
154. Contreras HR, Ledezma RA, Vergara J, et al. The expression of syndecan -1 and -2 is associated with Gleason score and epithelial-mesenchymal transition markers, E-cadherin and β -catenin, in prostate cancer. *Urol Oncol.* 2010; 28:534-540.

155. Umbas R, Isaacs WB, Bringuier PP, et al. Decreased E-cadherin expression is associated with poor prognosis in patients with prostate cancer. *Cancer Res.* 1994; 54:3929-3933.
156. Kallakury BV, Sheehan CE, Ross JS. Co-downregulation of cell adhesion proteins α and β catenins, p120CTN, E-cadherin, and CD-44 in prostatic adenocarcinomas. *Hum Pathol.* 2001; 32:849-855.
157. De Marzo AM, Knudsen B, Chan-Tack K, et al. E-cadherin expression as a marker of tumor aggressiveness in routinely processed radical prostatectomy specimens. *Urology.* 1999; 53:707-713.
158. Jaggi M, Johansson S, Baker J, et al. Aberrant expression of E-cadherin and β -catenin in human prostate cancer. *Urol Oncol.* 2005; 23:402-406.
159. Pontes-Júnior J, Reis ST, Dall'Oglio M, et al. Evaluation of the expression of integrins and cell adhesion molecules through tissue microarray in lymph node metastases of prostate cancer. *J Carcinog.* 2009; 8:3.
160. Bismar TA, Humphrey PA, Grignon DJ, et al. Expression of β -catenin in prostatic adenocarcinomas. *Am J Clin Pathol.* 2004; 121:557-563
161. Arenas MI, Romo E, Royuela M, et al. E-, N- and P-cadherin, and α -, β - and γ -catenin protein expression in normal, hyperplastic and carcinomatous human prostate. *Histochem J.* 2000; 32:659-667.
162. Kallakury BV, Sheehan CE, Winn-Deen E, et al. Decreased expression of catenins (α and β), p120 CTN, and E-cadherin cell adhesion proteins and E-cadherin gene promoter methylation in prostatic adenocarcinomas. *Cancer.* 2001; 92:2786-2795.
163. Chessire DR, Ewing CM, Sauvageot J, et al. Detection and analyzes of β -catenin mutations in prostate cancer. *Prostate.* 2000; 45:323-334.

11. BIOGRAPHY

I was born in Prishtina, Republic of Kosovo, and I graduated from the Faculty of Medicine, University of Prishtina (UP), in 2004. In January 2005, I was appointed as a Junior Teaching Assistant and in 2006 I was upgraded to Teaching Assistant in the Department of Pathology, Faculty of Medicine, UP. From 2005 until 2012, I was appointed by the Dean of the Faculty of Medicine, UP, as Coordinator for Cooperation between our Faculty of Medicine and Dartmouth Medical School, Hanover, NH, USA.

In 2009, I was awarded a DAAD research scholarship, and for three months I was a resident in training/researcher under the supervision of Prof. Dr. med. Guido Sauter in Uropathology at the Department of Pathology Universitätsklinikum Hamburg-Eppendorf, Germany.

In 2012, I completed my residency program in pathology, and in 2013, I joined the Institute of Pathology, University Clinical Center of Kosovo, as a staff pathologist.

In 2015, I completed the PhD program in Biomedicine and Health Sciences at the Zagreb University School of Medicine (Croatia).

In 2015, I was granted JICA (Japan International Cooperation Agency) funding and attended a one month training in Health Management in Japan.

Currently, besides my work in pathology, I also hold an appointment as Coordinator for International Collaboration at the Hospital University Clinical Service of Kosovo, which covers the secondary and tertiary medical care in Kosovo.

My professional fields of interest are uropathology, gynecopathology, and endocrine pathology. I am married and a happy mother of a two-year-old son, Yll.