

# The Characteristics of Patients With COVID-19-Associated Pediatric Vasculitis: An International, Multicenter Study

---

**Batu, Ezgi D.; Sener, Seher; Ozomay Baykal, Gulcan; Arslanoglu Aydin, Elif; Özdel, Semanur; Gagro, Alenka; Esen, Esra; Heshin-Bekenstein, Merav; Akpınar Tekgöz, Nilüfer; Demirkan, Fatma G.; ...**

*Source / Izvornik:* **Arthritis & Rheumatology, 2023, 75, 499 - 506**

**Journal article, Published version**

**Rad u časopisu, Objavljena verzija rada (izdavačev PDF)**

<https://doi.org/10.1002/art.42411>

*Permanent link / Trajna poveznica:* <https://um.nsk.hr/um:nbn:hr:105:574742>

*Rights / Prava:* [In copyright](#)/[Zaštićeno autorskim pravom.](#)

*Download date / Datum preuzimanja:* **2024-06-29**









*Repository / Repozitorij:*

[Dr Med - University of Zagreb School of Medicine  
Digital Repository](#)



# The Characteristics of Patients With COVID-19–Associated Pediatric Vasculitis: An International, Multicenter Study

Ezgi D. Batu,<sup>1</sup>  Seher Sener,<sup>1</sup>  Gulcan Ozomay Baykal,<sup>2</sup> Elif Arslanoglu Aydin,<sup>3</sup> Semanur Özdel,<sup>3</sup> Alenka Gagro,<sup>4</sup> Esra Esen,<sup>5</sup> Merav Heshin-Bekenstein,<sup>6</sup>  Nilüfer Akpınar Tekgöz,<sup>7</sup> Fatma G. Demirkan,<sup>8</sup> Kubra Ozturk,<sup>9</sup> Olga Vougiouka,<sup>10</sup> H. Emine Sonmez,<sup>11</sup> Maria Cristina Maggio,<sup>12</sup> Ummusen Kaya Akca,<sup>13</sup>  Marija Jelusic,<sup>14</sup> Aysenur Pac Kisaarslan,<sup>5</sup> Banu Acar,<sup>7</sup> Nuray Aktay Ayaz,<sup>8</sup>  Betül Sözeri,<sup>2</sup> and Seza Özen,<sup>1</sup>  on behalf of the Pediatric Rheumatology European Society (PREs) Vasculitis Working Party

**Objective.** COVID-19–associated pediatric vasculitis, other than Kawasaki disease (KD)–like vasculitis in multisystem inflammatory syndrome in children (MIS-C), is very rare. This study sought to analyze the characteristics, treatment, and outcomes in patients with COVID-19–associated pediatric vasculitis (excluding KD-like vasculitis in MIS-C).

**Methods.** The inclusion criteria were as follows: 1) age <18 years at vasculitis onset; 2) evidence of vasculitis; 3) evidence of SARS–CoV-2 exposure; and 4) ≤3 months between SARS–CoV-2 exposure and vasculitis onset. Patients with MIS-C were excluded. The features of the subset of patients in our cohort who had COVID-19–associated pediatric IgA vasculitis/Henoch Schönlein purpura (IgAV/HSP) were compared against a pre-pandemic cohort of pediatric IgAV/HSP patients.

**Results.** Forty-one patients (median age 8.3 years; male to female ratio 1.3) were included from 14 centers and 6 countries. The most frequent vasculitis subtype was IgAV/HSP (n = 30). The median duration between SARS–CoV-2 exposure and vasculitis onset was 13 days. Involvement of the skin (92.7%) and of the gastrointestinal system (61%) were the most common manifestations of vasculitis. Most patients (68.3%) received glucocorticoids, and 14.6% also received additional immunosuppressive drugs. Remission was achieved in all patients. All of the patients with IgAV/HSP in our cohort had skin manifestations, while 18 (60%) had gastrointestinal involvement and 13 (43.3%) had renal involvement. When we compared the features of this subset of 30 patients to those of a pre-pandemic pediatric IgAV/HSP cohort (n = 159), the clinical characteristics of fever and renal involvement were more common in our COVID-19–associated pediatric IgAV/HSP cohort (fever, 30% versus 5%, respectively [ $P < 0.001$ ]; renal involvement, 43.3% versus 17.6%, respectively [ $P = 0.002$ ]). Recovery without treatment and complete recovery were each less frequent among our COVID-19–associated pediatric IgAV/HSP patients compared to the pre-pandemic pediatric IgAV/HSP cohort (recovery without treatment, 10% versus 39%, respectively [ $P = 0.002$ ]; complete recovery, 86.7% versus 99.4%, respectively [ $P = 0.002$ ]).

**Conclusion.** This is the largest cohort of children with COVID-19–associated vasculitis (excluding MIS-C) studied to date. Our findings suggest that children with COVID-19–associated IgAV/HSP experience a more severe disease course compared to pediatric IgAV/HSP patients before the pandemic.

## INTRODUCTION

COVID-19 has been associated with a variety of complications since the beginning of the pandemic. Vasculitis and arthritis

are relatively common among these complications (1). Vasculitis can occur both during acute SARS–CoV-2 infection and days or weeks later after the onset of acute infection (1). The most common post–COVID-19 inflammatory syndrome is multisystem

<sup>1</sup>Ezgi D. Batu, MD, Seher Sener, MD, Seza Özen, MD: Hacettepe University Faculty of Medicine, Ankara, Turkey; <sup>2</sup>Gulcan Ozomay Baykal, MD, Betül Sözeri, MD: Umraniye Training and Research Hospital, Istanbul, Turkey; <sup>3</sup>Elif Arslanoglu Aydin, MD, Semanur Özdel, MD: Dr. Sami Ulus Maternity and Child Health and Diseases Research and Training Hospital, Ankara, Turkey; <sup>4</sup>Alenka Gagro, MD: Children's Hospital Zagreb, Zagreb, Croatia, School of Medicine, University of Zagreb, Zagreb, Croatia, and Faculty of Medicine, Josip Juraj Strossmayer, Josipa

Huttlara 4, University of Osijek, Osijek, Croatia; <sup>5</sup>Esra Esen, MD, Aysenur Pac Kisaarslan, MD: Erciyes University Faculty of Medicine, Kayseri, Turkey; <sup>6</sup>Merav Heshin-Bekenstein, MD: Dana Dwek Children's Hospital, Tel Aviv Medical Center, Tel Aviv, Israel; <sup>7</sup>Nilüfer Akpınar Tekgöz, MD, Banu Acar, MD: Ankara City Hospital, Ankara, Turkey; <sup>8</sup>Fatma G. Demirkan, MD, Nuray Aktay Ayaz, MD: Istanbul University Faculty of Medicine, Istanbul, Turkey; <sup>9</sup>Kubra Ozturk, MD: Istanbul Medeniyet University, Goztepe Research and Training Hospital, Istanbul, Turkey;

inflammatory syndrome (MIS), a condition that is more frequently observed in children (MIS-C) (2). Its estimated incidence is 316/1,000,000 SARS-CoV-2 infections among individuals younger than age 21 years (3,4).

COVID-19-associated pediatric vasculitides are rare, except for the Kawasaki disease (KD)-like vasculitis seen in the MIS-C spectrum. To date, there have been only case reports or small case series in the literature (1). In our recent systematic review, we identified only 36 previously published cases of COVID-19-associated pediatric vasculitis other than KD-like MIS-C (1).

Vasculopathy is usually a part of the clinical spectrum in acute COVID-19, along with immunothrombosis (5). However, vasculitis also occurs later in the follow-up period, probably as a result of the exaggerated immune response triggered by the virus. Although the exact pathogenesis remains unknown, there is a suggestion of causality in the temporal association of these vasculitides with SARS-CoV-2 exposure among previously published pediatric vasculitis cases.

In the present study, we aimed to analyze the characteristics, treatment, and outcomes in patients with COVID-19-associated pediatric vasculitis other than KD-like vasculitis in MIS-C. In addition, we compared the characteristics, treatment, and outcomes between our cohort of children with COVID-19-associated IgA vasculitis/Henoch-Schönlein purpura (IgAV/HSP) and our previous pre-pandemic cohort of children with IgAV/HSP.

## PATIENTS AND METHODS

**Patients.** Fourteen centers from 6 countries participated in this study. In all patients, the onset of vasculitis was before age 18 years. The inclusion criteria were as follows: 1) evidence of SARS-CoV-2 exposure, based on either a history of COVID-19 or contact with a COVID-19 patient or polymerase chain reaction (PCR) findings of SARS-CoV-2 or serology demonstrating positivity for SARS-CoV-2; 2) evidence of vasculitis, based on either histopathology or imaging test results consistent with the features of vasculitis or fulfillment of the EULAR/PRINTO/PRES Ankara 2008 classification criteria for pediatric vasculitides (6); and 3)  $\leq 3$  months between the exposure to SARS-CoV-2 and onset of vasculitis-related symptoms (in patients with a history of SARS-CoV-2 exposure). Patients with chilblains were included only if vasculitis was verified with histopathologic evaluation. Patients older than age 18 years and patients with MIS-C were excluded.

Demographic features, clinical and laboratory characteristics, treatment, and outcomes among the patients in this pediatric

vasculitis cohort were evaluated using standardized case report forms. The methods utilized for data collection in the pre-pandemic pediatric IgA vasculitis cohort were described previously (7).

The study was approved by the ethics committee of Hacettepe University (approval no. GO 22/266) and performed according to the ethics standards laid down in the 1964 Declaration of Helsinki and its later amendments.

**Statistical analysis.** SPSS software, version 15.0 (SPSS, Inc.) was used for statistical analyses. Descriptive analyses were presented using proportions, medians, and minimum and maximum values. Visual (histogram, probability plots) and analytic methods (Kolmogorov-Smirnov test) were used to check normality in the distribution of numeric variables. Differences in proportions between groups were investigated using the chi-square test or Fisher's exact test where appropriate. To compare the non-normally distributed continuous data between 2 groups, the Mann-Whitney U test was used. *P* values less than 0.05 were considered significant, and we used a 95% confidence interval.

## RESULTS

A total of 41 children with COVID-19-associated vasculitis were included in this study. The general characteristics of these patients are presented in Table 1, along with the features observed in previously published pediatric cases ( $n = 36$ ) (1).

In our cohort, male patients outnumbered female patients (male to female ratio 1.3) and IgAV/HSP was the most frequent vasculitis subtype ( $n = 30$ ). The median time between SARS-CoV-2 exposure and vasculitis onset was  $\sim 2$  weeks. There was no history of SARS-CoV-2 exposure in 5 patients (12.2%), although all 5 patients had a positive serologic finding for SARS-CoV-2. In 4 patients, vasculitis occurred simultaneously with acute COVID-19. In the rest of the cohort, the duration between SARS-CoV-2 exposure and vasculitis was  $\leq 1$  week in 9 patients, 2–6 weeks in 18 patients, and  $> 6$  weeks in 5 patients. Only 1 patient (an adolescent girl with chilblains) was vaccinated against COVID-19 before the onset of vasculitis. This patient received 2 doses of messenger RNA vaccine with a 1-month interval between doses, and she was diagnosed as having SARS-CoV-2 infection 4 months after the last vaccine dose. The onset of chilblains in this adolescent patient occurred 1 month after the diagnosis of acute COVID-19.

<sup>10</sup>Olga Vougiouka, MD: National Kapodistrian University School of Medicine, "P. A. Kyriakou" Children's Hospital, Athens, Greece; <sup>11</sup>H. Emine Sonmez, MD: Kocaeli University Faculty of Medicine, Kocaeli, Turkey; <sup>12</sup>Maria Cristina Maggio, MD: University of Palermo, Palermo, Italy; <sup>13</sup>Ummusen Kaya Akca, MD: Aydın Obstetrics and Pediatrics Hospital, Aydın, Turkey; <sup>14</sup>Marija Jelusic, MD, PhD: University of Zagreb School of Medicine, University Hospital Centre Zagreb, Zagreb, Croatia.

Author disclosures, a graphical abstract, and a video abstract are available online at <https://onlinelibrary.wiley.com/doi/10.1002/art.42411>.

Address correspondence via email to Ezgi Deniz Batu, MD, at [ezgidenizbatu@yahoo.com](mailto:ezgidenizbatu@yahoo.com).

Submitted for publication July 26, 2022; accepted in revised form November 22, 2022.

**Table 1.** The characteristics of patients with COVID-19-associated pediatric vasculitis in our international study cohort in comparison with pediatric vasculitis patients from the literature\*

Characteristic	Study cohort (n = 41)	Patients from the literature (n = 36)†
Age, median (min-max) years	8.3 (3.6-16.8)	13 (1.1-17)
Female sex	18 (44)	11/34 (32.3)
Evidence of SARS-CoV-2 exposure		
COVID-19 history	28 (68.3)	3 (8.3)
Positive COVID-19 on PCR	16/35 (45.7)	16 (44.4)
Positive COVID-19 on serology	21/21 (100)	18 (50)
Contact with a COVID-19 patient	33 (80.5)	8 (22.2)
Diagnosis		
IgAV/HSP	30 (73.2)	9 (25)
Chilblains	2 (4.9)	7 (19.4)
AAV	1 (2.4)	5 (13.8)
Takayasu arteritis	1 (2.4)	0
Postviral graft vasculitis	0	5 (13.8)
CNS vasculitis	0	4 (11.1)
Retinal vasculitis	0	2 (5.5)
Urticarial vasculitis	0	2 (5.5)
AHEI	0	1 (2.7)
Unclassified vasculitis	7 (17.1)	1 (2.7)
Time between SARS-CoV-2 exposure and vasculitis, median (min-max) days	13 (0-88)	17.5 (2-150)
Elevated inflammation markers	34 (83)	15/22 (68.1)
Positive imaging findings suggestive of vasculitis	12/13 (92.3)	9/12 (75)
Histopathologic proof of vasculitis	14/16 (87.5)	18/19 (94.7)
Organ affected by vasculitis		
Skin	38 (92.7)	21 (58.3)
GI system	25 (61)	5 (13.8)
Kidney	15 (36.6)	11 (30.5)
Lung	1 (2.4)	4 (11.1)
CNS	0	5 (13.8)
Eye	0	2 (5.5)
Liver	0	1 (2.7)
Treatment		
Glucocorticoid	28 (68.3)	14/33 (42.4)
NSAID	27 (65.9)	6/33 (18.1)
Any immunosuppressive drug‡	6 (14.6)	7/33 (21.2)
Methotrexate	4 (9.7)	0
MMF	3 (7.3)	1/33 (3.03)
CYC	1 (2.4)	4/33 (12.1)
IVIg	1 (2.4)	2/33 (6.1)
AZA	1 (2.4)	1/33 (3.03)
TOC	1 (2.4)	1/33 (3.03)
RTX	0	5/33 (15.1)
Plasmapheresis	0	2/33 (6.1)
IFX	0	1/33 (3.03)
HCQ	0	1/33 (3.03)
Antiplatelet/anticoagulant drug	5 (12.2)	2 (5.6)
Outcome		
Improved	41 (100)	23/28 (82.1)
Deceased	0	5/28 (17.8)

\* Except where indicated otherwise, values are the number (%) or number/total number assessed (%). min-max = minimum-maximum; PCR = polymerase chain reaction; IgAV/HSP = IgA vasculitis/Henoch-Schönlein purpura; AAV = antineutrophil cytoplasmic antibody-associated vasculitis; CNS = central nervous system; AHEI = acute hemorrhagic edema of infancy; GI = gastrointestinal; NSAID = nonsteroidal antiinflammatory drug; MMF = mycophenolate mofetil; CYC = cyclophosphamide; IVIG = intravenous immunoglobulin; AZA = azathioprine; TOC = tocilizumab; RTX = rituximab; IFX = infliximab; HCQ = hydroxychloroquine.

† From Batu et al (1).

‡ Includes any immunosuppressive drug other than glucocorticoids, except for the 6 patients in the current study cohort, who received glucocorticoids in conjunction with other immunosuppressive drugs.

SARS-CoV-2 was tested by serology in 21 patients, and all 21 had positive results. None of these 21 patients had been

vaccinated against COVID-19. Only anti-spike antibodies were tested in 20 patients, while recombinant antigens from both spike

and nucleocapsid proteins were used in the serology test in 1 patient. In 4 of our patients with IgAV/HSP and gastrointestinal involvement (also renal involvement in 1 of the patients), their features were suggestive of an overlap with MIS-C, according to the definitions of MIS-C provided by the US Centers for Disease Control and Prevention (8) or World Health Organization (9). All 4 patients had the typical IgAV/HSP symptoms of purpura in the lower extremities. Their echocardiograms did not reveal any abnormalities, and cardiac enzyme levels were within the normal limits, with no evidence of coagulopathy or lymphadenopathy. Thus, MIS-C was ruled out in these patients. The microbiologic test results regarding other infectious etiologies are summarized in Supplementary Table 1 (available on the *Arthritis & Rheumatology* website at <https://onlinelibrary.wiley.com/doi/10.1002/art.42411>).

Vasculitis most frequently affected the skin (92.7%) followed by the gastrointestinal system (61%) in our cohort. It is noteworthy that 4 patients had elevated D-dimer levels. None of our patients died, and the disease improved following treatment in all patients.

In a separate subset analysis, pediatric patients with COVID-19-associated IgAV/HSP (n = 30) were evaluated. The median age of the patients in this group at the time of vasculitis

onset was 8.2 years, and the male to female ratio was 2 to 1 (Table 2). The median duration between SARS-CoV-2 exposure and onset of vasculitis was 11 days (minimum–maximum 0–77 days); this duration was unknown in 3 patients, ≤1 week in 9 patients, 2–6 weeks in 12 patients, and >6 weeks in 4 patients. Vasculitis occurred simultaneously with the SARS-CoV-2 infection in 2 patients. In addition to purpura, which was present in all patients (examples in Figures 1A–C), musculoskeletal manifestations (80%) and gastrointestinal involvement (60%) were quite common in our IgAV/HSP patients (Table 2). Two-thirds of the IgAV/HSP patients received glucocorticoids. The main indication for glucocorticoid use was gastrointestinal involvement (n = 15), orchitis (n = 2), and severe skin lesions (n = 1). Of note, only partial remission with glucocorticoid treatment was achieved in 4 patients. All 4 of these patients had renal involvement (verified with renal biopsy), while 2 also had severe gastrointestinal bleeding that was challenging to control with glucocorticoid treatment.

We compared the features of these patients with those of our pre-pandemic cohort of 159 children with IgAV/HSP (7). The clinical features that were more common among our patients with COVID-19-associated IgAV/HSP compared to the pre-pandemic

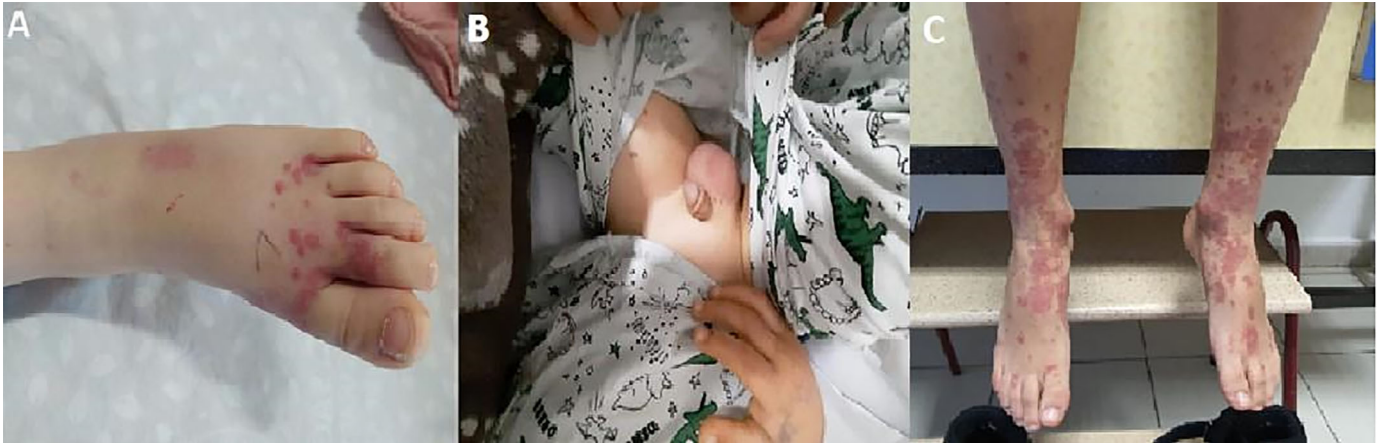**Table 2.** The characteristics of children with COVID-19-associated IgAV/HSP compared with the pre-pandemic pediatric IgAV/HSP cohort\*

Characteristic	Children with COVID-19-associated IgAV/HSP (n = 30)	Pre-pandemic cohort of children with IgAV/HSP (n = 159)†	P
Age at vasculitis onset, median (min–max) years	8.2 (3.6–16.8)	7 (1.5–17)	0.060
Male sex	20 (66.7)	82 (51.6)	0.128
Duration of follow-up, median (min–max) months	7.5 (1–24)	8 (6–48)	0.52
Evidence of SARS-CoV-2 exposure		NA	NA
COVID-19 history	19 (63.3)		
Positive COVID-19 on PCR	13/28 (46.4)		
Positive COVID-19 on serology	12/12 (100)		
Contact with a COVID-19 patient	24 (80)		
Disease characteristics			
Purpura	30 (100)	159 (100)	–
Fever	9 (30)	8 (5)	<0.001
Arthralgia	24 (80)	110 (69.2)	0.232
Arthritis	15 (50)	82 (51.6)	0.876
Musculoskeletal manifestations	24 (80)	110 (69.2)	0.232
GI system involvement	18 (60)	72 (45.3)	0.139
Renal involvement	13 (43.3)	28 (17.6)	0.002
Scrotal involvement	2 (6.6)	3 (1.9)	0.179
Treatment			
NSAID	20 (66.7)	77 (48.4)	0.067
Glucocorticoid	18 (60)	71 (44.7)	0.122
Other immunosuppressive drug‡	3 (10)	5 (3.1)	0.116
ACE inhibitor	5 (16.7)	22 (13.8)	0.776
Outcome			
Follow-up without any treatment	3 (10)	62 (39)	0.002
Complete recovery	26 (86.7)	158 (99.4)	0.002
Partial remission	4 (13.3)	0	0.004
Refractory disease	0	1 (0.6)	0.293
Relapse	1 (3.3)	9 (5.7)	1

\* Except where indicated otherwise, values are the number (%) or number/total number assessed (%). NA = not applicable; ACE = angiotensin-converting enzyme (see Table 1 for other definitions).

† From Batu et al (7).

‡ Two patients received mycophenolate mofetil, and 1 patient received methotrexate.



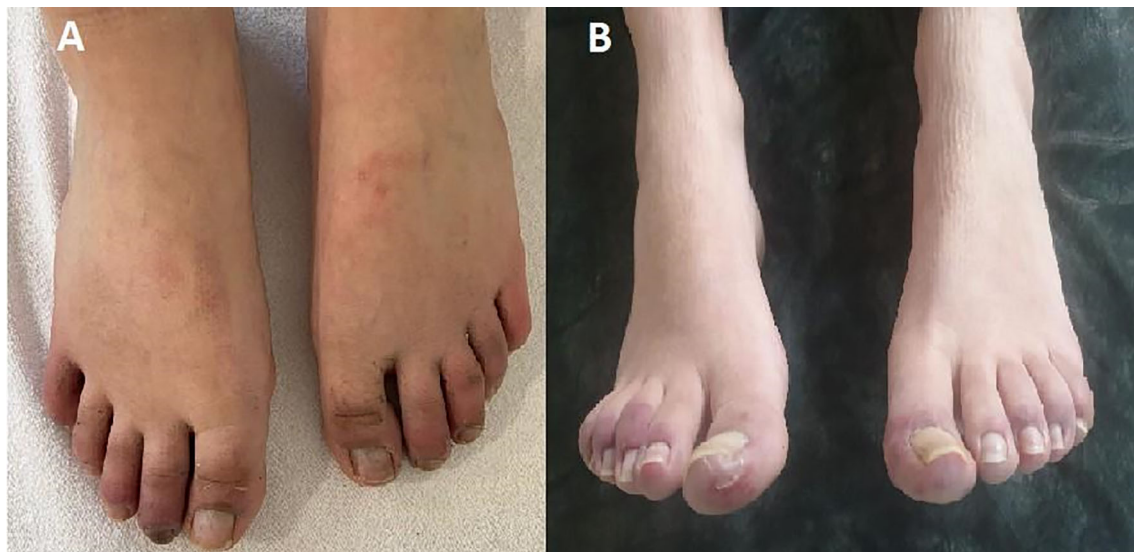**Figure 1.** Features of IgA vasculitis in representative pediatric patients from the study cohort, including palpable purpura on the left foot of a 3.5-year-old boy (A), scrotal edema in a 14-year-old patient (B), and violaceous plaques and scattered palpable purpura in the lower extremity of a 7-year-old boy (C).

cohort were fever (30% versus 5%, respectively [ $P < 0.001$ ]) and renal involvement (43.3% versus 17.6%, respectively [ $P = 0.002$ ]) (Table 2). In addition, gastrointestinal involvement was also more frequent in our COVID-19-associated IgAV/HSP cohort compared to the pre-pandemic cohort (60% versus 45.3%, respectively), but this difference was not statistically significant (Table 2). The outcomes of follow-up without treatment and complete recovery were more commonly seen in the pre-pandemic cohort compared to our COVID-19-associated IgAV/HSP cohort (follow-up without treatment, 39% versus 10%, respectively [ $P = 0.002$ ]; complete recovery, 99.4% versus 86.7%, respectively [ $P = 0.002$ ]) (Table 2).

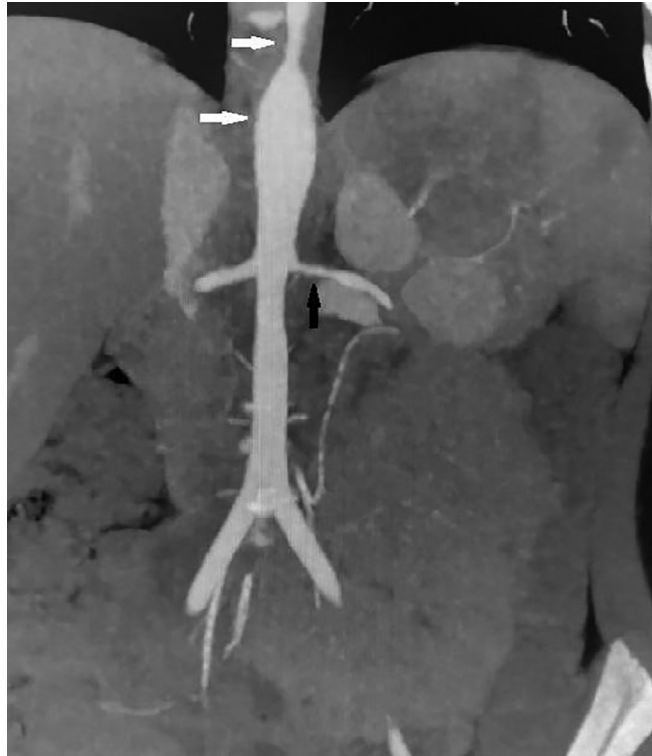In 2 patients with chilblains (Figures 2A and B), the skin biopsy demonstrated lymphocytic vasculitis. In 1 of these

2 patients, there was no history of SARS-CoV-2 exposure, although her serology test showed positive results for SARS-CoV-2 (but negative results on PCR). The other patient acknowledged a mild episode of acute COVID-19 that had occurred 1 month before the occurrence of chilblain lesions. One of these patients experienced improvement in their skin lesions with glucocorticoid treatment, while the other patient achieved complete remission with mycophenolate mofetil and bosentan in addition to glucocorticoids.

One patient, an 8.5-year-old girl who had granulomatosis with polyangiitis (GPA) and was positive for proteinase 3 antineutrophil cytoplasmic antibodies (PR3 ANCA), presented with maculopapular rash, arthritis, sinusitis, and pulmonary lesions. The onset of GPA in this patient was almost 3 months (88 days)



**Figure 2.** Chilblain-like lesions on the toes of both feet of 2 adolescent girls with IgA vasculitis, ages 15 years (A) and 15.5 years (B).



**Figure 3.** Computed tomography examination of an 8.5-year-old girl with Takayasu arteritis, revealing arteritis of the aortic arch and the branching arteries. Characteristics identified include increased wall thickness extending from the thoracic aorta to the abdominal aorta leading to an aneurysmatic appearance and slight narrowing in the lumen (**white arrows**) and the narrowed orifice of the left renal artery, with enlargement and blurring of the walls (**black arrow**).

later than the SARS-CoV-2 exposure, and her serologic test for SARS-CoV-2 was positive. This patient achieved remission following treatment with glucocorticoids, methotrexate, intravenous immunoglobulin, and low molecular weight heparin.

Another patient, an 8.5-year-old girl with Takayasu arteritis, presented with seizures and had evidence of hypertension on physical examination. Computerized tomographic angiography of the thoracic and abdominal aorta verified that this patient had increased wall thickness and aneurysms (Figure 3). She achieved complete remission with glucocorticoids, methotrexate, and tocilizumab.

In 7 patients, there was proof of vasculitis on histopathologic or imaging tests, but the phenotype did not fit any specific childhood vasculitis. Manifestations of vasculitis in the skin ( $n = 6$ ), musculoskeletal system ( $n = 6$ ), and gastrointestinal system ( $n = 6$ ) were frequent among these 7 patients. Six of the 7 patients achieved complete remission following treatment with glucocorticoids only. One patient, who had necrotic skin lesions (necrotizing vasculitis demonstrated on skin biopsy), severe gastrointestinal manifestations, and renal involvement, required treatment with cyclophosphamide and azathioprine in addition to glucocorticoids, which led to achievement of remission.

## DISCUSSION

In this study, we presented the largest cohort of children with COVID-19-associated vasculitis (other than KD-like MIS-C) studied to date, with a total of 41 patients. The median duration between SARS-CoV-2 exposure and vasculitis was  $\sim 2$  weeks and the most common vasculitis subtype was IgAV/HSP. Although the disease outcome was similar between our COVID-19-associated IgAV/HSP patients and the pre-pandemic IgAV/HSP patients, the disease course seemed to be more severe in COVID-19-associated IgAV/HSP.

There are several possible mechanisms that could contribute to the occurrence of vasculitis associated with COVID-19 (1). The down-regulation of angiotensin-converting enzyme 2 by SARS-CoV-2 binding causes an increase in angiotensin II (Ang II) (10,11). The type I interferon response against SARS-CoV-2 may lead to a decrease in nitric oxide (NO) by inhibiting NO synthetase (12). Both the increased level of Ang II and decreased level of NO contributes to vasoconstriction and inflammation by causing macrophages to shift to a proinflammatory (M1) status (13,14). Furthermore, endotheliitis resulting from the viral replication may lead to the loss of endothelial barrier and exposure of platelets to basement membrane components, which triggers the thrombosis cascade. Activated

platelets, proinflammatory macrophages, lymphocytes, and neutrophils in an immune system triggered by SARS-CoV-2 set the environment for vasculitis and possibly immunothrombosis. Glucocorticoids and immunosuppressive drugs used in the treatment of vasculitis usually suppress the inflammation. There is no conclusive evidence for the use of antiplatelet or anticoagulant drugs in COVID-19-associated vasculitis. The time from SARS-CoV-2 exposure to vasculitis onset was  $\leq 1$  week in 13 patients and  $>2$  weeks in 23 patients in our cohort. The direct effects of the virus (from viral replication) were probably dominant in patients who had vasculitis during the acute infection. On the other hand, it can be speculated that the damage might have been mainly caused by the immune activation triggered by the virus in patients in whom vasculitis had occurred  $>2$  weeks after the onset of acute COVID-19. The mechanism of the latter scenario may resemble that of MIS-C (15).

We analyzed and compared the characteristics of our patients in the present cohort ( $n = 41$ ) with those in previously described cases with COVID-19-associated pediatric vasculitides ( $n = 36$ ) (1). The age at vasculitis onset was younger in our cohort than in previously published cases (mean age at onset 8.3 years versus 13 years, respectively) (Table 1). Skin was the most frequently affected organ in both groups of patients, followed by gastrointestinal system involvement (61%) in our cohort and renal involvement (30.5%) in the literature cohort. Regarding outcome, the mortality rate was higher in the cohort from the literature than in our cohort (17.8% versus 0%, respectively). The higher mortality rate in the previous literature cohort could be attributed to the presence of patients with severe central nervous system (CNS) vasculitis. All 4 patients with CNS vasculitis died (16–19). There were no patients with CNS vasculitis in our cohort. We recruited patients from the pediatric rheumatology units. Children with CNS vasculopathy/vasculitis might have been taken care of by pediatric neurologists in some of these centers. Another reason for a higher mortality rate among case reports in the literature could be the bias toward reporting cases with more striking features.

Chilblains were more frequent in children during the pandemic compared to the pre-pandemic era (20–22). In a recent literature review, it was reported that 1,059 children developed chilblain-like lesions that were likely associated with COVID-19 (21). The more frequent occurrence of these lesions during late childhood to early adolescence and a male predominance were the striking common features in these reports (21). There were only 2 adolescent girls with COVID-19-associated chilblains in our cohort, since we included only patients with a histopathologic verification of vasculitis. COVID-19-associated chilblains are usually self-limited, and the lesions improve without immunosuppressive treatment in most cases (20), which decreases the rate of skin biopsy in these patients. COVID-19-associated chilblains are similar to the skin lesions of type I interferonopathies (23). A strong type I interferon response resulting from the acute infections could be the reason for these lesions. Consistent with this hypothesis, 1 of our patients with chilblains did not

acknowledge having a symptomatic acute COVID-19 infection, and the other patients gave a history of very mild COVID-19.

IgAV/HSP was the most common subtype of vasculitis associated with COVID-19. This finding is not surprising, given that IgAV/HSP is the most common primary systemic vasculitis of childhood (24) and has been strongly linked to triggers like infections (25,26). We compared the characteristics of COVID-19-associated IgAV/HSP in our pediatric patients with those of our pre-pandemic pediatric IgAV/HSP cohort of 159 patients (details in Table 2) (7). Age at vasculitis onset and predominance of the disease in male over female patients were similar features between the 2 cohorts. All patients had purpura, and musculoskeletal manifestations were present in more than two-thirds of the patients in both cohorts (Table 2). However, fever and renal involvement were more frequent, while the rate of complete recovery and the percentage of patients who achieved remission without any treatment were lower among patients with COVID-19-associated IgAV/HSP compared to patients in the pre-pandemic cohort. These differences suggest a more severe disease course in IgAV/HSP associated with COVID-19. SARS-CoV-2 appears to be a strong trigger of the immune system among viruses causing primarily respiratory tract infections (27,28). This could be the reason for a more severe disease course in COVID-19-associated IgAV/HSP. Having said that, the rate of complete recovery was quite high in both cohorts, underscoring the relatively benign course of IgAV/HSP during childhood.

In adults, pulmonary vasculature is often affected in vasculitis-mimic conditions during acute COVID-19. Lung involvement or vasculitis affecting pulmonary vessels was present in only 1 of our patients, a female patient who had GPA with sinusitis, PR3 ANCA positivity, skin manifestations, and pulmonary lesions. However, the onset of vasculitis was almost 3 months later than the acute infection in this patient, and the SARS-CoV-2 PCR result was negative, which excludes the possibility of a vasculitis-mimic.

There are several limitations in this study. The incidental occurrence of vasculitis should be considered in our patients, especially for the 2 groups stratified as patients with vasculitis onset  $>6$  weeks later than the SARS-CoV-2 exposure ( $n = 5$ ) and serology-positive patients with no history of SARS-CoV-2 exposure ( $n = 5$ ). Although the temporal association between COVID-19 and vasculitis (duration to vasculitis onset shorter than 3 months) suggests causality in the group who developed vasculitis  $>6$  weeks later than the SARS-CoV-2 infection, it is not possible to rule out coincidence. We acknowledge that for the group who were positive for SARS-CoV-2 on serology but had no history of SARS-CoV-2 exposure, it is challenging to comment on a COVID-19 association with only a positive serology result. The time span of having a positive serology result after the diagnosis of COVID-19 is highly variable, and the serology result could stay positive for long periods of time after infection, which is a limitation of our study. Another possibility is that immunothrombosis and ischemic complications during acute COVID-19 could mimic vasculitis (5). Our patients who had vasculitis simultaneously with acute COVID-19 ( $n = 4$ ) or within the first week



of acute infection ( $n = 9$ ) might have had a vasculitis-mimic with viral endothelitis, rather than true vasculitis. Given the retrospective and multicenter nature of the study, the laboratory tests conducted to exclude other infectious etiologies were not uniform and these tests were not comprehensive in all patients.

Other limitations of our study stem from its retrospective nature, and the limited number of patients. However, COVID-19-associated pediatric vasculitis (excluding KD-like MIS-C) is very rare, and the present report describes the first and largest international cohort of COVID-19-associated pediatric vasculitis patients. Thus it provides valuable insights into this understudied complication of COVID-19.

This is the largest cohort of children with COVID-19-associated vasculitis (excluding MIS-C) studied to date. Analyzing the characteristics of these patients provides insights into the potential SARS-CoV-2-associated immune complications in children. COVID-19-associated IgAV/HSP seems slightly more severe than IgAV/HSP not associated with COVID-19, with a higher frequency of renal involvement and lower rates of recovery without treatment and complete recovery in those with COVID-19-associated IgAV/HSP. The temporal association of SARS-CoV-2 with vasculitis suggest causality, although it is not possible to rule out incidental occurrence.

## AUTHOR CONTRIBUTIONS

All authors were involved in drafting the article or revising it critically for important intellectual content, and all authors approved the final version to be published. Dr. Batu had full access to all of the data in the study and takes responsibility for the integrity of the data and the accuracy of the data analysis.

**Study conception and design.** Batu, Özen.

**Acquisition of data.** Batu, Sener, Ozomay Baykal, Arslanoglu Aydin, Özdel, Gagro, Esen, Heshin-Bekenstein, Akpınar Tekgöz, Demirkan, Ozturk, Vougiouka, Sonmez, Maggio, Kaya Akca, Jelusic, Pac Kisaarslan, Acar, Aktay Ayaz, Sözeri.

**Analysis and interpretation of data.** Batu, Sener, Özen.

## REFERENCES

- Batu ED, Sener S, Ozen S. COVID-19 associated pediatric vasculitis: a systematic review and detailed analysis of the pathogenesis. *Semin Arthritis Rheum* 2022;55:152047.
- Chou J, Thomas PG, Randolph AG. Immunology of SARS-CoV-2 infection in children. *Nat Immunol* 2022;23:177–85.
- Belay ED, Abrams J, Oster ME, et al. Trends in geographic and temporal distribution of US children with multisystem inflammatory syndrome during the COVID-19 pandemic. *JAMA Pediatr* 2021;175:837–45.
- Payne AB, Gilani Z, Godfred-Cato S, et al. Incidence of multisystem inflammatory syndrome in children among US persons infected with SARS-CoV-2. *JAMA Netw Open* 2021;4:e2116420.
- Giryas S, Bragazzi NL, Bridgewood C, et al. COVID-19 vasculitis and vasculopathy-distinct immunopathology emerging from the close juxtaposition of type II pneumocytes and pulmonary endothelial cells. *Semin Immunopathol* 2022;44:375–90.
- Ozen S, Pistorio A, Iusan SM, et al. EULAR/PRINTO/PRES criteria for Henoch-Schonlein purpura, childhood polyarteritis nodosa, childhood Wegener granulomatosis and childhood Takayasu arteritis: Ankara 2008. Part II: final classification criteria. *Ann Rheum Dis* 2010;69:798–806.
- Batu ED, Sari A, Erden A, et al. Comparing immunoglobulin A vasculitis (Henoch-Schonlein purpura) in children and adults: a single-centre study from Turkey. *Scand J Rheumatol* 2018;47:481–6.
- Center for Disease Control and Prevention. Emergency preparedness and response: health alert network; 2020. URL: <https://emergency.cdc.gov/han/2020/han00432.asp>.
- World Health Organization. Multisystem inflammatory syndrome in children and adolescents with COVID-19; 2020. URL: <https://www.who.int/publications/i/item/multisystem-inflammatory-syndrome-in-children-and-adolescents-with-covid-19>.
- Lu R, Zhao X, Li J, et al. Genomic characterisation and epidemiology of 2019 novel coronavirus: implications for virus origins and receptor binding. *Lancet* 2020;395:565–74.
- Quinaglia T, Shabani M, Breder I, et al. Coronavirus disease-19: the multi-level, multi-faceted vasculopathy. *Atherosclerosis* 2021;322:39–50.
- Buie JN, Oates JC. Role of interferon  $\alpha$  in endothelial dysfunction: insights into endothelial nitric oxide synthase-related mechanisms. *Am J Med Sci* 2014;348:168–75.
- Cheung CY, Poon LL, Ng IH, et al. Cytokine responses in severe acute respiratory syndrome coronavirus-infected macrophages in vitro: possible relevance to pathogenesis. *J Virol* 2005;79:7819–26.
- Tousoulis D, Kampoli AM, Tentolouris C, et al. The role of nitric oxide on endothelial function. *Curr Vasc Pharmacol* 2012;10:4–18.
- Gurlevik SL, Ozsurekci Y, Sag E, et al. The difference of the inflammatory milieu in MIS-C and severe COVID-19. *Pediatr Res* 2022;92:1805–14.
- Daisley H Jr, Rampersad A, Daisley M, et al. COVID-19: a closer look at the pathology in two autopsied cases. Is the pericyte at the center of the pathological process in COVID-19? *Autops Case Rep* 2021;11:e2021262.
- De Marcellus C, Dupic L, Roux CJ, et al. Case report: cerebrovascular events associated with bacterial and SARS-CoV-2 infections in an adolescent. *Front Neurol* 2021;12:606617.
- Freij BJ, Gebara BM, Tariq R, et al. Fatal central nervous system co-infection with SARS-CoV-2 and tuberculosis in a healthy child. *BMC Pediatr* 2020;20:429.
- Poisson KE, Zygmunt A, Leino D, et al. Lethal pediatric cerebral vasculitis triggered by severe acute respiratory syndrome coronavirus 2. *Pediatr Neurol* 2022;127:1–5.
- Andina D, Noguera-Morel L, Bascuas-Arribas M, et al. Chilblains in children in the setting of COVID-19 pandemic. *Pediatr Dermatol* 2020;37:406–11.
- Fennell J, Karen O. Chilblains-like lesions in pediatric patients: a review of their epidemiology, etiology, outcomes, and treatment. *Front Pediatr* 2022;10:904616.
- Panda M, Agarwal A, Hassanandani T. Dermatological manifestations of COVID-19 in children. *Indian Pediatr* 2022;59:393–9.
- Melki I, Fremont ML. Type I interferonopathies: from a novel concept to targeted therapeutics. *Curr Rheumatol Rep* 2020;22:32.
- Eleftheriou D, Batu ED, Ozen S, et al. Vasculitis in children. *Nephrol Dial Transplant* 2015;30:i94–103.
- Heineke MH, Ballering AV, Jamin A, et al. New insights in the pathogenesis of immunoglobulin A vasculitis (Henoch-Schonlein purpura) [review]. *Autoimmun Rev* 2017;16:1246–53.
- Liu C, Luo L, Fu M, et al. Analysis of children with Henoch-Schonlein purpura secondary to infection. *Clin Rheumatol* 2022;41:803–10.
- Hu B, Guo H, Zhou P, et al. Characteristics of SARS-CoV-2 and COVID-19 [review]. *Nat Rev Microbiol* 2021;19:141–54.
- Shah VK, Fimal P, Alam A, et al. Overview of immune response during SARS-CoV-2 infection: lessons from the past. *Front Immunol* 2020;11:1949.