

# Angiomyoma--angioliomyoma of the cheek

---

Vidaković, Bruno; Kotarac Knežević, Ana; Manojlović, Spomenka;  
Knežević, Goran

Source / Izvornik: **Collegium Antropologicum, 2011, 35, 207 - 209**

**Journal article, Published version**

**Rad u časopisu, Objavljena verzija rada (izdavačev PDF)**

Permanent link / Trajna poveznica: <https://um.nsk.hr/um:nbn:hr:105:232508>

Rights / Prava: [In copyright](#)/[Zaštićeno autorskim pravom.](#)

Download date / Datum preuzimanja: **2025-02-02**



Repository / Repozitorij:

[Dr Med - University of Zagreb School of Medicine  
Digital Repository](#)



# Angiomyoma – Angioleiomyoma of the Cheek

Bruno Vidaković<sup>1</sup>, Ana Kotarac Knežević<sup>2</sup>, Spomenka Manojlović<sup>3</sup> and Goran Knežević<sup>2</sup>

<sup>1</sup> »Dr. Josip Benčević« General Hospital, Department of Otorhinolaryngology and Head and Neck Surgery, Slavonski Brod, Croatia

<sup>2</sup> University of Zagreb, School of Dental Medicine, Department of Oral Surgery, Zagreb, Croatia

<sup>3</sup> University of Zagreb, Dubrava University Hospital, Department for Clinical and Experimental Pathology, Zagreb, Croatia

## ABSTRACT

*The authors present the case of an angiomyoma – angioleiomyoma of the cheek in a 58-year-old man. The tumour was palpable, although clinically not visible, and the only case of a tumour of smooth muscle treated in the Clinical Department of Oral Surgery over the last 40 years. The operation was performed in the Outpatient Department by intraoral procedure. The postoperative course passed without complications. Current literature on leiomyomas is cited in the Introduction, followed by presentation of the case and histological characteristics of the tumour. The example is presented as a rarity and one of the differential diagnostic possibilities in the diagnostics of soft tissue tumours in the oral cavity.*

**Key words:** *angiomyoma, angioleiomyoma, oral cavity*

## Introduction

Leiomyomas are benign tumours of the smooth muscles which, on the basis of the histological finding, are generally classified into three sub-types: solid, angioleiomyomas or vascular leiomyomas and epitheloid or leiomyoblastomas<sup>1</sup>. Van der Waal and Van der Kwast<sup>2</sup> only cite angiomyoma as a sub-type of leiomyoma. Barnes<sup>3</sup> more precisely classifies leiomyomas into four sub-types: leiomyoma (simple, conventional or common), angiomyoma (angioleiomyoma, vascular leiomyoma) epitheloid leiomyoma (bizarre leiomyoma, leiomyoblastoma) and mesectodermal leiomyoma. Among 257 leiomyomas of the head and neck the same author found 27% angioleiomyomas, 1.2% epitheloid, 0.8% mesectodermal, and most frequently simple or common leiomyomas in 71% of cases. Among 69 angiomyomas of the head and neck he reported that 31 cases were found in the area of the oral cavity, most often in the lips, 13, soft palate 8, tongue 5, buccal mucosa 3, gingiva 1 and uvula 1. Others were situated in the skin of the head and neck and in the area of the nasal cavity, larynx etc. With regard to the distribution of leiomyomas in all areas of the body Farman<sup>4</sup> reported that 95% were situated in the female genital tract, 3% in the skin and 1% in the gastrointestinal tract and other parts of the body. Tumours occur in mid-

dle and older age and are usually painless, and although they are somewhat more frequent in women, because of the few series of leiomyomas of the head and neck in the literature gender prevalence cannot be confirmed. In current literature there are cases of smaller series or individual cases in the area of the oral cavity and jaw<sup>5</sup>, of which some were of such size that operations under general anaesthesia were indicated and extra oral approach<sup>6</sup>. There are cases that grow exophytically and resemble fibroepithelial polyps. Koca and coworkers<sup>8</sup> described very rare localisation of the tumour in the retromolar region of the mandible. The tumour clinically resembled an epulis and caused bone resorption. Hung and coworkers<sup>9</sup> also described similar localisation in the lingual gingiva of the mandible. A bizarre case of an angioleiomyoma in the inferior nasal turbinate, which had caused several years of epistaxis was described by He and coworkers<sup>10</sup>. Among unusual localisations was a case of an angioleiomyoma in the hard palate<sup>11</sup>. Cases have been reported in which leiomyomas caused painful sensation<sup>12</sup>. Hachisuga and coworkers<sup>13</sup> report pain as a frequent symptom of leiomyoma. In a sample of 562 patients tumours caused pain and tenderness in 327 cases (58%), of which 262 cases were solid tumours. Ramesh and co-

workers<sup>14</sup> believe that pain occurs due to contraction of smooth muscles, which induces ischemia, or because of ischemia of the area of the tumour induced by thrombosis. Another explanation of pain is the accumulation of blood in the tumour during effort which strains the capsule and nerve endings within it. However, the pain disappears during the period of rest<sup>14</sup>.

### Case Report

A 58-year-old man was referred to the Clinical Department of Oral Surgery, Clinic of Maxillofacial and Oral Surgery because of a painless swelling in the right cheek, which he had noticed a year ago and which was gradually increasing in size. No facial asymmetry was visible nor was any change in the right cheek observed during intraoral examination. However, a sharply circumscribed oval mass was detected by palpation, 2x1.5 cm in size, painless and moveable under the mucous membrane of the cheek and in relation to the facial skin. The patient denied odontogenic problems and trauma in the facial area. Excision biopsy was performed under local anaesthesia. A white greyish-brown oval mass with a smooth surface was removed from the soft tissue of the cheek by intraoral approach through the mucous membrane, submucosal tissue and m. buccinator. During the operative procedure continuity of Stensen's duct was preserved and the buccal branch of n. facialis was not damaged. A control examination 7 days after excision showed normal healing of the wound.

Histopathological finding No. 5301/10:

Grossly, the nodule was circumscribed, glistening, white-grey and firm. Histologically it was composed of numerous thick-walled vessels with partially patent, and partially collapsed lumina. Vessel walls consisted of smooth muscle fibres arranged circumferentially in inner, and swirled in outer, layers, merging with peripheral muscle fibres. The stroma surrounding the vessels revealed myxoid, hyaline and fatty changes.

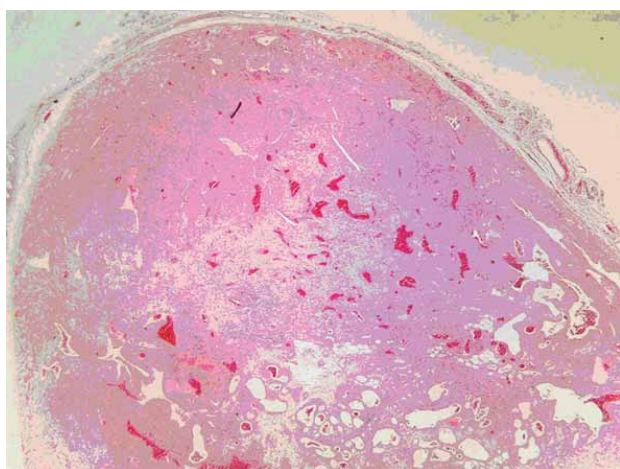


Fig. 1. Angiomyoma HE x 20.

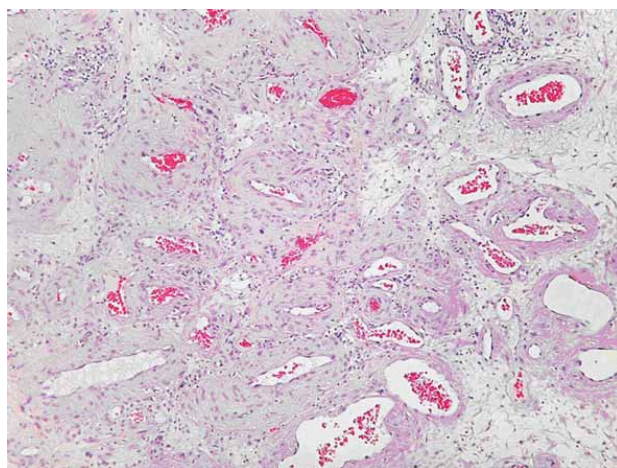


Fig. 2. Angiomyoma HE x 100.

Dg: Angiomyoma (angioleiomyoma) Figure 1 (Angiomyoma HE x 20), Figure 2 (Angiomyoma HE x 100).

### Discussion and Conclusion

Angioleiomyomas in the oral cavity are not a frequent finding, and localisation in the cheek, according to an example presented by Barnes<sup>3</sup>, takes fourth place behind the lips, palate and tongue. The case presented was situated in the area of the cheek, but between m. buccinator and the skin and was not visible like other exophytic examples localised in the mucous membrane of the cheek<sup>7</sup>, but was only palpable. Etiologically angiomyomas can be connected with the smooth muscle of the blood vessels of the head and neck, mm. arrectores pilorum and mesenchymal cells. Some authors recognise and classify angioleiomyomas in three histological classes: solid, cavernous and venous<sup>13</sup>, depending on the appearance of the blood vessels, which may be split-like, dilated, with smaller smooth muscle components, or more like veins than arteries. In the case presented it was impossible to determine one of the above classes of tumour. According to differential diagnostics they could have been muccocoela of the cheek, glandular tumour of the small salivary gland, tumour of the nerve sheaths – neurilemmoma, which is occasionally rather difficult to differentiate from angioleiomyoma, a neurofibroma and finally a granulocellular tumour. Although there is dilemma on the aetiology of granulocellular tumour, which is commonly found in the muscular tissue of the tongue, it can also occur in the oral cavity in the area of the lips, oral cavity floor, and in the region of the cheek<sup>3</sup>. In uncertain cases in the oral cavity and other parts of the body diagnosis is made by aspiration cytological examination<sup>14</sup>. As recurrence and malignant alterations of angiomyomas are rarely visible, correct evaluation of the tumour and prognosis determine: size smaller than 5 cm, sparse mitotic activity in the histopathological sample, abundant cytoplasm, prominent reticulin fibres and lack of invasion<sup>3</sup>. No element to suggest alteration of the tumour was found in the presented case.

The case presented of an angiomyomas of the cheek is presented as a rarity, which clinicians need to take into account in differential diagnostics of tumours and simi-

lar lesions in the soft tissue of the oral cavity and perioral region.

## REFERENCES

1. BROOKS JK, NIKITAKIS NG, GOODMAN NJ, LEVY BA, Oral Surg Oral Med Oral Pathol Oral Radiol Endod, 94 (2002) 221. — 2. VAN DER WAAL I, VAN DER KWAST WAM, Oral Pathology (Quintessence, Chicago London Berlin Sao Paulo Tokyo Hong Kong, 1988). — 3. BARNES L, Surgical Pathology of the Head and Neck 2nd ed. (Marcel Dekker, New York Basel, 2001). — 4. FARMAN AG, S Afr Med J, 49 (1975) 1333. — 5. GAITAN CAPEDA LA, QUEZADA RIVERA D, TENORIO ROCHA F, LEYVA HUERTA ER, MENDEZ SÁNCHEZ ER, Med Oral Patol Oral Cir Bucal, 13 (2008)E483. — 6. KEERTI R, NANJAPPA MADAN, DEORA SHAKTI SING, KUMARASWAMY SV, J Maxillofac Oral Surg, 8 (2009) 298. — 7. MC PARLAND H, WARNAKULASURIYA S, COOK RJ, Br J Oral Maxillofac Surg, 47 (2009) 641. — 8. KOCA H, GÜNERI P, ÇETİNGÜL E, ÖNAL T, International Journal of Pediatric Otorhinolaryngology Extra, 1 (2006) 110. — 9. HUNG KEFYAN AH, KAO SY, CHANG CS, Chin J Oral Maxillofac Surg, 16 (2005) 179. — 10. HE J, ZHAO LN, JIANG ZN, ZHANG SZ, Otolaryngol Head Neck Surg, 141 (2009) 663. — 11. AL-AMAD SH, ANGEL C, O'GRADY JF and MC CULLOUGH MJ, Oral Oncology Extra, 42 (2006) 244. — 12. TOIDA M, KOIZUMI H, SHIMOKAWA K, J Oral Maxillofac Surg, 58 (2000) 450. — 13. HACHISUGA T, HASHIMOTO H, ENJOJI M, Cancer, 54 (1984) 126. — 14. RAMESH P, ANNAPUREDDY SR, KHAN F, SUTARIA PD, Int J Clin Pract, 58 (2004) 587. — 15. LONČAR B, MARJANOVIĆ K, PAUZAR B, STAKLENAC B, Coll Antropol, 34 (2010) 261.

G. Knežević

University of Zagreb, School of Dental Medicine, Department of Oral Surgery, Gundulićeva 5, 10 000 Zagreb, Croatia  
e-mail: knezevic@sfzg.hr

## ANGIOMIOM – ANGIOLEIOMIOM OBRAZA

### SAŽETAK

Autori prikazuju slučaj angiomioma – angioleiomioma obraza u 58 godišnjeg muškarca. Tvorba je bila palpabilna, ali klinički nevidljiva i jedini je slučaj tumora glatke muskulature liječenog u Kliničkome zavodu za oralnu kirurgiju u zadnjih četrdeset godina. Zahvat je izveden ambulantno intraoralnim pristupom, a poslijeoperacijski tijek protekao je bez komplikacija. Uvodno se navodi suvremena literatura o leiomiomima, a zatim se prikazuje slučaj i histološke karakteristike tumora. Primjer se prikazuje kao raritet i jedna od diferencijalno dijagnostičkih mogućnosti u dijagnostici tumora mekih tkiva usne šupljine.