

# Perforated ascending colon cancer presenting as colocutaneous fistula with abscess to the anterior abdominal wall at the site of a cholecystectomy scar treated with biologic mesh

---

**Bogdanić, Branko; Augustin, Goran; Kekez, Tihomir; Mijatović, Davor; Hlupić, Ljiljana; Vanek, Maja**

*Source / Izvornik:* Collegium Antropologicum, 2012, 36, 335 - 338

**Journal article, Published version**

**Rad u časopisu, Objavljena verzija rada (izdavačev PDF)**

*Permanent link / Trajna poveznica:* <https://um.nsk.hr/um:nbn:hr:105:029993>

*Rights / Prava:* [In copyright](#) / [Zaštićeno autorskim pravom.](#)

*Download date / Datum preuzimanja:* **2025-01-09**



*Repository / Repozitorij:*

[Dr Med - University of Zagreb School of Medicine  
Digital Repository](#)



# Perforated Ascending Colon Cancer Presenting as Colocutaneous Fistula with Abscess to the Anterior Abdominal Wall at the Site of a Cholecystectomy Scar Treated with Biologic Mesh

Branko Bogdanić, Goran Augustin<sup>1</sup>, Tihomir Kekez<sup>1</sup>, Davor Mijatović<sup>1</sup>, Ljiljana Hlupić<sup>2</sup> and Maja Vanek<sup>1</sup>

<sup>1</sup> University of Zagreb, Zagreb University Hospital Center, Department of Surgery, Zagreb, Croatia

<sup>2</sup> University of Zagreb, Zagreb University Hospital Center, Department of Pathology, Zagreb, Croatia

## ABSTRACT

*Ascending colon cancer as a colocutaneous fistula to the abdominal wall at the site of a previous postoperative scar is extremely rare. A 69 year old male presented with five day history of pain and foul smelling discharge from right subcostal scar from elective cholecystectomy performed 8 years ago. Last three days, he had fever up to 39°C, with mild pain in right upper abdominal quadrant without vomiting, diarrhea, bloody stools or weight loss. Computed tomography, with peroral contrast, revealed extralumination into abdominal wall with several fistulas reaching the skin. Emergency median laparotomy found infiltrating tumor of ascending colon into abdominal wall. A right hemicolectomy and complete thickness abdominal wall excision (7×10 cm) was performed. The abdominal wall defect was too extensive for primary closure and two 20×20 cm moist gauzes were placed to cover the defect and were fixed with stitches to the skin. On second postoperative day, due to contamination, porcine dermal collagen implant was placed intraperitoneally. Such emergency presentations and therapeutic options are discussed.*

**Key words:** colon cancer, perforation, colocutaneous fistula, abdominal wall abscess

## Introduction

Presentation of ascending colon cancer as a colocutaneous fistula to the abdominal wall at the site of a previous postoperative scar is extremely rare, with only few case reports published<sup>1–6</sup>. Right-sided colonic cancers most often present with anemia, loss of weight, abdominal pain or palpable mass and often in its advanced stage. Perforated colon cancer can be defined and presented as 1) tumor perforating free into the peritoneal cavity causing peritonitis, 2) forming an abscess or 3) fistula with adjacent organs or skin and 4) a combination of some aforementioned conditions. The incidence of colonic perforation ranges from 2.6 to 10%<sup>2–7</sup>. Fistula, when present, is most often colovesical, coloenteric and colovaginal. Colocutaneous fistula is a very rare complication of perforated colon cancer partly due to colonic fixation to posterior abdominal wall<sup>1,8</sup>.

## Case report

A 69 year old male presented with five day history of pain and foul smelling discharge from right subcostal scar from elective cholecystectomy performed 8 years ago. Last three days, he had fever up to 39°C, with mild pain in right upper abdominal quadrant. There was no vomiting, diarrhea, bloody stools or weight loss. His family history was negative for any type of malignancy.

On examination, oedema of the skin around the scar 10×20 cm with marked erythema and spontaneous feculent drainage through the central opening was present. Laboratory tests on admission revealed a leukocytosis of 20.4×10<sup>9</sup>/L, C-reactive protein of 320 mg/L and microcytic anemia (Hg 102 g/L, MCV 75.1 fL). Plain abdominal X-Ray did not show air fluid levels, bowel distension or pneumoperitoneum. Computed tomography, with peroral contrast, revealed extralumination into abdominal

wall with several fistulas reaching the skin (Figure 1). No signs of extralumination of contrast into abdominal cavity were found. Preoperatively the patient was commenced on cefuroxime 3x1 g, metronidazole 3x500 mg and garamycin 2x120 mg continued also after the operation. Emergency median laparotomy was performed and infiltrating tumor of ascending colon into abdominal wall at the site of previous cholecystectomy was found. A right hemicolectomy and complete as well as partial thickness abdominal wall excision (7x10 cm) was performed (Figure 2). Liver metastases were not found. Terminal ileostomy was made through left rectus muscle, because of the abdominal wall defect on the right side. The abdominal wall defect was too extensive for primary closure and two 20x20 cm moist gauzes were placed to cover the defect and were fixed with stitches to the skin.

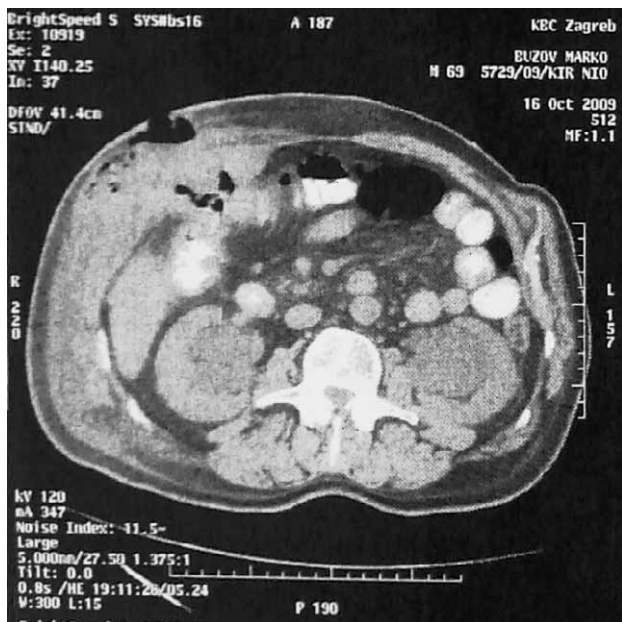


Fig. 1.

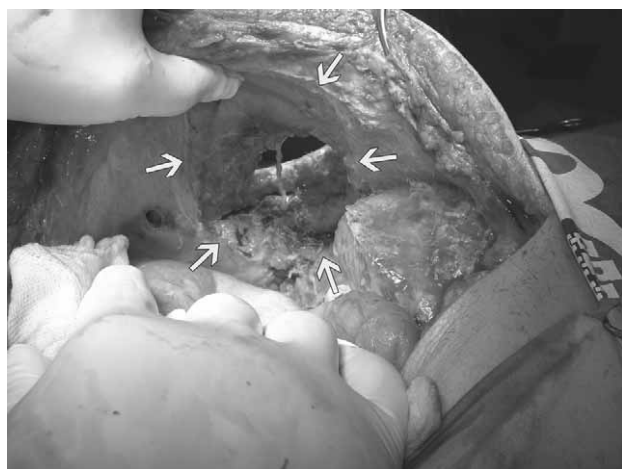


Fig. 2.

Laparotomy skin incision was left to heal by secondary intention. Two parallel skin incisions, 5 cm long, in the surrounding area of inflammatory skin were made to prevent synergistic bacterial infection.

Re-laparotomy was indicated to close the abdominal wall defect on the second postoperative day. Leukocyte level was normal ( $9.81 \times 10^9/L$ ) and C-reactive protein decreased to 155 mg/L. Because of contamination porcine dermal collagen implant (Surgisis, Cook Surgical, Bloomington, Ind., USA) size 13x15 cm was used, placed intraperitoneally (Figure 3). Due to skin tension, skin defect was not closed.

Abdominal wound cultures, taken during the first operative procedure, revealed *Escherichia coli* resistant to ciprofloxacin and amoxicillin, and *Enterococcus faecalis*. On histopathologic analysis ulcerated annular plaque tumor was found 4 centimeter from distal resected margin. Pathology confirmed colon adenocarcinoma (T4N0MO, Astler Coller B2) infiltrating fat and connective tissue. Fourteen lymph nodes examined were free of cancer cells. The margins of the resected bowel were free of cancer cells.

The wound was swathe twice a day and on twenty-fourth postoperative day, after uneventful course, normal laboratory findings and absence of wound infection, plastic surgeon was consulted for the closure of abdominal wall defect. The plan was, to use rectus abdominis muscular flap for closing the defect. This type of flap was chosen, because of its close position and minimal donor site damage. Unfortunately, after dissecting the muscle, insufficient vascularisation and advanced fibrosis were present. The subcutaneous tissue was mobilized, around the defect, from the underlying fascia, partially deepithelialized, folded and approximated without tension. Small central defect (1x1.5 cm), that left, was closed with split thickness skin graft. The skin was sutured with stitches and staples.

Three months later, patient recovered completely. He underwent chemotherapy according to Mayo protocol. One month after being discharged from hospital, tumor

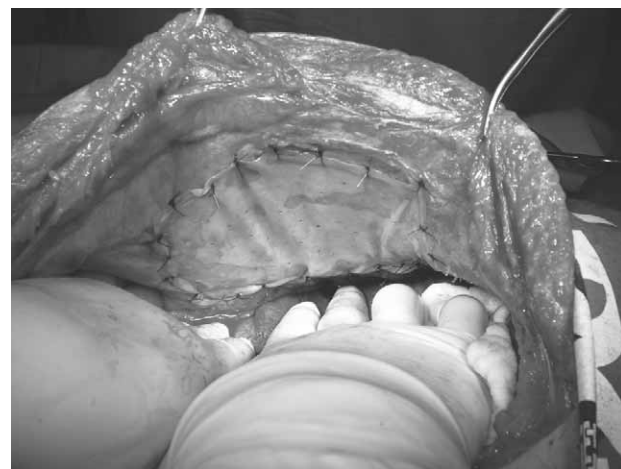

Fig. 3.

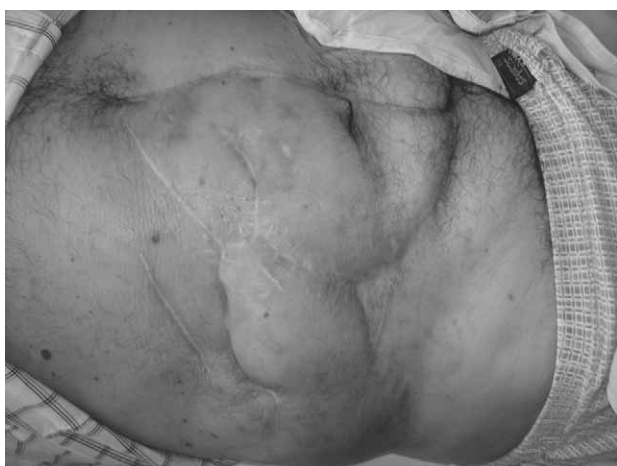

Fig. 4.

markers were normal (CEA 1.01 ng/mL, CA 19–9 6.35 U/mL).

After 5 months he returned to our emergency room, because of secretion from postoperative scar. On examination, cutaneous fistula, with diameter of 1 cm was present without signs of infection. Laboratory tests were normal. The fistula was bended and cultures were taken. After three days cultures revealed *Staphylococcus aureus* resistant to penicillin and sensitive to klindamycin, kloksacillin, azithromycin. He received peroral klindamycin 3×300 mg for 10 days. The cutaneous fistula healed completely without abdominal wall hernia (Figure 4). Further course was uneventful without tumor recurrence or abdominal wall hernia at the twelve month of follow up.

## Discussion

Perforated colon cancer have incidence 2.6–10%<sup>7,9</sup>. According to Mandava et al. primary perforated tumor in the right colon is in the second most common localization and the left colon is the most common one. Perforated colonic cancers can perforate free into the peritoneal cavity; forms an abscess or a fistula. Perforation is the most lethal complication due to high operative mortality due to sepsis, locally advanced malignancy, and a higher incidence of distant metastasis at presentation. Two types of

perforated colon carcinoma should be differentiated. One is »true« carcinoma perforation due to tumor necrosis and another is due to proximal colon blow-out from an obstructed tumor and a competent ileocecal valve producing a closed-loop phenomenon. Despite different pathophysiological mechanisms both types of perforations have similar long-term survival<sup>2</sup>.

Reviewing the literature with online date base Pub-Med, no case of perforation with colcutaneous fistula through cholecystectomy scar has been described. Freeman et al. have described a patient with a cecal tumor that formed colcutaneous fistula to the anterior abdominal wall at the site of an appendectomy scar<sup>1</sup>. Proposed pathophysiology in such situations is that previous operation (cholecystectomy) led to adhesions that made colon and abdominal wall in close contact, so when colon cancer appeared it invaded adjacent tissue, which is anterior abdominal wall. Several cases of ovarian cancer invading postoperative scars as metastasis or as primary cancer, especially after endometriosis surgery have also been described<sup>10,11</sup>.

Another problem is closure of the defect in such cases. Synthetic meshes are most commonly used in hernia repair, however in contaminated field; due to infection, removal is required in 50–90% of the cases. Biologic mesh is much better alternative, due to its greater resistance to infection<sup>12–14</sup>. Abdominal wall defect was covered with biosynthetic material mesh Surgisis (Cook Surgical, Bloomington, Ind., USA), because the operative field was contaminated. Surgisis mesh is derived from a natural biomaterial harvested from porcine small intestine mucosa. This type of mesh has been used for contaminated or potentially contaminated fields at inguinal, ventral and paraesophageal hernias, entero-cutaneous and rectovaginal fistulas and bile duct repairs<sup>14–21</sup>.

Although there is no clear consensus on the optimal method of reconstruction, in cases like here presented (local infiltration, without evident distant tumor spread), we recommend resection of primary tumor by oncologic principles with »en block« excision of the anterior abdominal wall with immediate (if infection is not present, elective procedure) or postponed (if abdominal wall infection is present) abdominal wall defect repair using biosynthetic material mesh.

## REFERENCES

1. FREEMAN HP, OLUWOLE SF, GANEPOLA GA, Cancer, 44 (1979) 1533. — 2. MANDAVA N, KUMAR S, PIZZI WF, APRILE IJ, Am J Surg, 172 (1996) 236. — 3. MATSUMOTO G, ASANO H, KATO E, MATSUNO S, Surg Today, 31 (2001) 166. — 4. Tsukuda K, IKEDA E, MIVAKE T, ISHIHARA Y, WATATANI H, NOGAMI T, MASUDA H, TAKAGI S, HIRAI R, MORIYAMA S, TSUJI H, FURUTANI S, KUNITOMO T, NAWA, Acta Med Okayama, 59 (2005) 281. — 5. MARRON CD, MCARDLE GT, RAO M, SINCLAIR S, MOOREHEAD J, BMC Surg, 6 (2006) 11. — 6. AL-HENDAL A, AL-MASRI W, AL-MISHAAN M, ALEXANDER S, Gulf J Oncolog, 5 (2009) 60. — 7. TSAI HL, HSIEH JS, YU FJ, WU DC, CHEN FM, HUANG CJ, HUANG YS, HUANG TJ, WANG JY, Int J Colorectal Dis, 22 (2007) 15. — 8. BHADURSINGH AM, LONGO WE, J Reprod Med, 48 (2003) 489. — 9. KELLEY WE, BROWN PW, LAWRENCE W, Arch Surg, 116 (1981) 381. — 10. ALVERTO VO, LYNCH M, LABBEI FN, JEFFERS M, Ir J Med Sci, 175 (2006) 69. — 11. MATSUO K, ALONSOZANA EL, ENO ML, ROSENSHEIN NB, IM DD, Arch Gynecol Obstet, 28 (2009) 637. — 12. SZCZERBA SR, DUMANIAN GA, Ann Surg, 237 (2003) 437. — 13. SAILES FC, WALLS J, GUELIG D, MIRZABEIGL M, LONG WD, CRAWFORD A, MOORE JH Jr, COPIT SE, TUMA GA, FOX J, Ann Plast Surg, 64 (2010) 696. — 14. CAVALLARO A, LO MENZO E, DI VITA M, ZANGHI A, CAVALLARO V, VEROUX PF, CAPPELLANI A, World J Gastroenterol, 16 (2010) 1928. — 15. SCHULTZ DJ, BRASEL KJ, SPINELLI KS, RASMUSSEN J, WEIGELT JA, J Am Coll Surg, 194 (2002) 541. — 16. ROSEN M, PONSKY J, PETRAS R, FANNING A, BRODY F, DU-

PERIER F, Surgery, 132 (2002) 480. — 17. OELSCHLAGER BK, BARRECA M, CHANG L, PELLEGRINI CA, Am J Surg, 186 (2003) 4. — 18. FRANKLIN ME Jr, GONZALEZ JJ Jr, GLASS JL, Hernia, 8 (2004) 186.

— 19. PYE PK, DADA T, DUTHIE G, PHILLIPS K, Dis Colon Rectum, 47 (2004) 1554. — 20. GUPTA A, ZAHRIYA K, MULLENS PL, SALMASSI S, KESHISHIAN A, Hernia, 10 (2006) 419.

*G. Augustin*

*University of Zagreb, Zagreb University Hospital Center, Department of Surgery, Kišpatićeva 12, 10000 Zagreb, Croatia  
e-mail: augustin.goran@gmail.com*

## **PREZENTACIJA PERFORIRANOG TUMORA UZLAZNOG KOLONA KAO KOLOKUTANE FISTULE I ABSCESA PREDNJE TRBUŠNE STIJENKE NA MJESTU OŽILJKA NAKON KOLECISTEKTOMIJE LIJEČENOG EN BLOK RESEKCIJOM UZ KORIŠTENJE BIOLOŠKE MREŽICE**

### **SAŽETAK**

Prezentacija karcinoma uzlaznog kolona kao kolokutane fistule na mjestu postoperativnog ožiljka je izrazito rijetka pojava. Bolesnik star 69 godina, javio se u Hitnu službu s petodnevnom anamnezom bolova i smrdljivog sekreta u području ožiljka od elektivne kolecistektomije, koja je bila prije 8 godina. Posljednja tri dana bio je febrilan do 39°C te je imao blagu bolnost u gornjem desnom kvadrantu. Negirao je povraćanje, krv u stolici ili gubitak tjelesne težine. Učinjena kompjuterizirana tomografija s peroralnim kontrastom, pokazala je ekstraluminaciju kontrasta u trbušnu stijenku s nekoliko fistula, koje su dosezale do kože. Hitnom medijalnom laparotomijom nađen je tumor uzlaznog kolona, koji infiltrira trbušnu stijenku. Učinjena je desna hemikolektomija s resekcijom trbušne stijenke pune debljine dimenzija 7×10 cm. Defekt trbušne stijenke, bio je preveliki za primarno zbrinjavanje, pa su postavljene dvije gaze 20×20 cm natopljene fiziološkom otopinom, koje su fiksirane za kožu pojedinačnim šavima. Drugi postoperativni dan, zbog kontaminiranosti rane, intraperitonealno postavljena je biološka mrežica (svinjska). Prikazani su slični slučajevi, kao i moguće metode u liječenju sličnih stanja.