

Causal connection of non-specific low back pain and disc degeneration in children with transitional vertebra and/or Spina bifida occulta: role of magnetic resonance--prospective study

Miličić, Gordana; Krolo, Ivan; Antičević, Darko; Roić, Goran; Zadravec, Dijana; Bojić, Davor; Žutelija Fattorini, Matija; Bumči, Igor

Source / Izvornik: *Collegium Antropologicum*, 2012, 36, 627 - 633

Journal article, Published version

Rad u časopisu, Objavljena verzija rada (izdavačev PDF)

Permanent link / Trajna poveznica: <https://um.nsk.hr/um:nbn:hr:105:181922>

Rights / Prava: [In copyright](#) / [Zaštićeno autorskim pravom](#).

Download date / Datum preuzimanja: **2024-07-18**



Repository / Repozitorij:

[Dr Med - University of Zagreb School of Medicine Digital Repository](#)



Causal Connection of Non-Specific Low Back Pain and Disc Degeneration in Children with Transitional Vertebra and/or *Spina bifida occulta*: Role of Magnetic Resonance – Prospective Study

Gordana Miličić¹, Ivan Krolo², Darko Antičević³, Goran Roić⁴, Dijana Zdravec², Davor Bojić¹, Matija Žutelija Fattorini¹ and Igor Bumčić⁵

¹ Zagreb Children's Hospital, Department of Orthopaedic, Zagreb, Croatia

² University of Zagreb, »Sestre milosrdnice« University Hospital Center, Department of Diagnostic and Interventional Radiology, Zagreb, Croatia

³ University of Zagreb, Zagreb University Hospital Center, Department of Orthopaedic, Zagreb, Croatia

⁴ Zagreb Children's Hospital, Department of Radiology, Zagreb, Croatia

⁵ Zagreb Children's Hospital, Department of Children Surgery, Zagreb, Croatia

ABSTRACT

The problem of low back pain (LBP) in children is very common and many specialists are dealing with it in everyday practice. The cause for low back pain often is not found and classified under the diagnosis of non specific low back pain. The objective of this prospective study is to determine whether children with non specific low back pain and existence of anomalies in LS spine (transitional vertebra- TV and/or Spina bifida occulta SBO) also have the degeneration of the intervertebral disc (DD) L4-L5 and/or L5-S1. This prospective study included 69 patients from 8 to 16 years of age (X 12.81) of whom 40 were male (57.97%), and 29 female (42.03%). They all were examined in University of Zagreb, »Sestre milosrdnice« University Hospital Center, Zagreb Children's Hospital, Department of Orthopaedic, Zagreb, Croatia. The reason of their visit was non specific low back pain. Pain was measured by visual analog scale (VAS) and mean score was three, duration of pain was between two and four weeks. Also, pain was sporadic, during daytime and not connected with level of physical activity. They all have undergone an algorithm of radiological examinations. Standard AP and LL radiographs (RTG) were made, as well as magnetic resonance (MR) of LS spine and sacrum in sagittal and transversal plane in T1 and T2 weighted sequence. The anomalies of L5 and S1 were found in 65 patients: transitional vertebra classified according to Castellvi et al. and SBO. In MRI in T2 weighted sequence DD was found in 61 patients which was classified modified from Pearce. Data analysis and comparison showed that 56 patients with TV and/or SBO have changes on vertebral dynamic segment L5-S1 (VDS) and that means DD. In 13 patients only DD or spinal anomaly (TV and/or SBO) were found. Correlation between anomalies and DD in those patients was established by McNemar analysis and has shown significant difference ($p=0.581$) in favour of the patients with anomaly and DD. This has established that all of 56 patients with spinal anomaly could have DD as known cause of LBP.

Key words: non-specific low back pain, transitional vertebra, Spina bifida occulta, disc degeneration, MR, X-ray

Introduction

Low back pain is not only a problem in adults, but also in children and adolescents which is confirmed by

growing number of scientific paper on that specific topic. This might be explained by growth spurts in puberty and

major changes in spinal balance¹. The cause for lower back pain in children often is not found. What is present is a group of symptoms and risk factors². This type of lower back pain is called non-specific and is presented without radicular pain and neurological deficit. Epidemiology studies find a large percentage of low back pain in children³. One of the causes of LBP are spinal anomalies, transitional vertebra (TV) and *Spina bifida occulta* (SBO). Prof. Mario Bertolotti from Torino has published a paper in 1917 that describes in detail all vertebra located in transitional areas of respective parts of the spine⁴. The most common occurrence of TV is in the area of L-S spine and is described as sacralisation, if L5 takes over features of the sacrum, and lumbalisation if S1 takes over features of the lumbar spine. In the first case the sacrum gets the sixth vertebra, and in the latter loses the first vertebra⁵. *Spina bifida occulta* (SBO) can be described as a minor anomaly that is seen on standard radiographs as a defect on *processus spinosus* and *lamina* (posterior vertebral arch). This defect is most commonly found in L5 and S1 vertebra⁶.

Degenerative changes in IVD start before the second decade of life, already in children and adolescent age^{7,8}. The basic change is that the volume of *nucleus pulposus* (NP) is diminishing as well as the distance between NP and *annulus fibrosus* (AF). IVD is a highly hydrophilic structure and has different densities in different parts (NP, AF, cartilaginous surfaces). Therefore, IVD is suitable for MR analysis, its normal structures and pathological conditions, in T2 weighted sequence. Analysis of VDS in MR is enabled due to high positive correlation between T2 relaxation time and water content in proteoglycan solution and negative correlation between collagen and water⁹. Any change in water concentration in IVD changes its density, and therefore the signal which is differently projected in the image. The changes in AF of IVD cause discogenic pain which was first mentioned by Inman in 1947¹⁰. Discogenic pain is caused by all those factors which affect IVD and cause DD, and by that also release of nociceptors from AF. This has been established also in IVD in low back pain cases¹¹. The aim of this study was to determine if spinal anomaly could change morphology of IVD and become source of discogenic pain.

Materials and Methods

This paper covers the prospective study in children aged 8–16 examined in University of Zagreb, »Sestre milosrdnice« University Hospital Center, Zagreb Children's Hospital, Department of Orthopaedic, Zagreb, Croatia. The cause for their presentation was LBP. It was located in lumbosacral junction, measured by VAS and mean score was three. Pain was occasional, lasting approximately 10 minutes, usually in the morning, no connection with level of physical activity and lasting between two and four weeks before presentation in outpatient clinic. In the period of one year we have examined 75 patients. First exam was X-ray of L-S spine, in 6 patients we found changes on the spine (spondylolysis – 1,

spondylolysis – 1, Schmorl's hernias – 2, Scheuerman's disease – 1, and scoliosis – 1 patient). They have been excluded from further analysis. The rest of 69 patients had TV or/and SBO.

Classification of transitional vertebra was done according to Castellvi et al. (Table 1)¹². The second exam was MR of L-S spine and sacrum.

Magnetic resonance imaging was conducted in Magnetom Harmony 1.0 by Siemens. For analysis we applied cuts of 3 mm in thickness. Standard Spine ECHO technique was applied: T1: TR 500 TE 15, T2: TR 4000, TE 105, matrix 2656x256.

The readings were conducted in T2 weighted sequences in sagittal and transversal cuts. In sagittal cuts we described the discs between L4-L5 and L5-S1 vertebra, and classified the disc changes modified from Pearce (Table 2)¹³. L-S junction was determined by counting sacral vertebrae from S5 upwards to S1^{14–16}.

Data obtained from radiographs and MR images were incorporated into questionnaires (Figure 1). The data was analyzed and compared to other data, as well as statistically analysed. The reading was done by two independent doctors. They analysed images in two separate sessions and had altogether four disagreements regarding the level of DD. We solved problem by choosing the lower level of DD.

Results

We analyzed a total of 69 patients, aged 8–16, of whom 58% male and 42% female. Analysis of plain AP radiographs of L-S spine found that from the total number of patients, 55 of them (79.7%) have transitional vertebra (TV), 38 sacralisation and 17 lumbalisation. According to Castellvi classification most patients had type I (A and B) 33, and least patients had type IV, in total 4 patients (Table 3). On the level of L5 we found mostly type IA and on level of S1 vertebra type IIIA was most common (Figure 2). The second anomaly analyzed is SBO which was detected on radiographs in 31 patients, mostly on S1 vertebra, in 24 patients (Figure 3). Our study therefore shows 55 patients with TV and 31 patients with SBO, which represents a total of 86 anomalies in 69 patients. A TV

TABLE 1
CLASSIFICATION OF LUMBOSACRAL TRANSITIONAL
VERTEBRAE ACCORDING TO CASTELLVI ET AL.

Type I	Dysplastic transverse process which is spatula formed and has a minimum height of 19 mm (IA unilateral, IB bilateral)
Type II	<i>Processus transversus</i> follows the contour of the sacrum, but there is no fusion between them, forms an articulation with adjacent sacral ala (IIA unilateral, IIB bilateral)
Type III	Real bony fusion between transverse process and iliac bone (III A unilateral, III B bilateral)
Type IV	Combination of type II (articulation) on one side and type III (fusion) on the other side

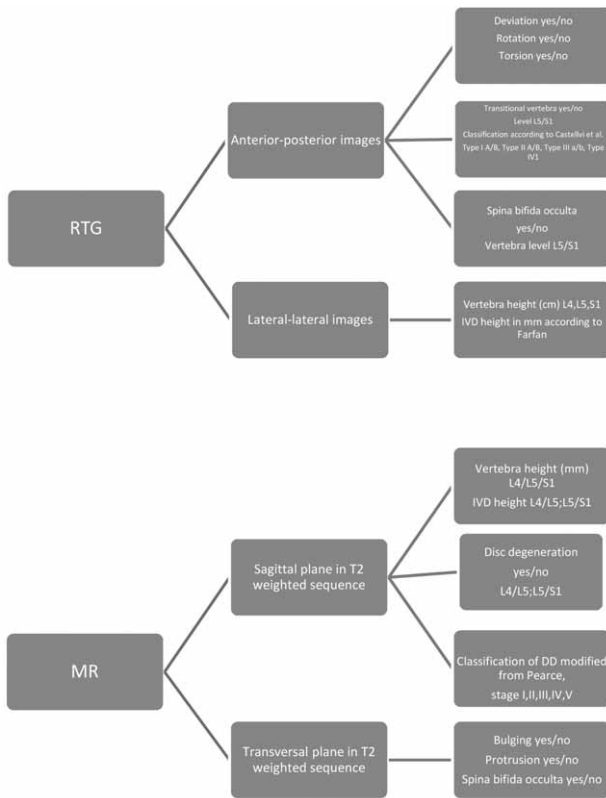


Fig. 1. Radiological questionnaires.

joint with SBO was found in 21 (30.43%) patients, and in 4 (5.8%) patients no anomaly was detected, while one anomaly was found in 44 patients (34 TV (49.27%) and 10 (14.29%) SBO). That means that a total of 65 patients had an anomaly in L-S junction. In 38 patients TV was L5, and in 24 patients we detected SBO in S1 vertebra.

The structure of IVD in patients was analyzed in MR images in sagittal cuts in T2 weighted sequence. We applied the Pearce classification. Data analysis has established that 61 (88.41%) patients had DD of whom 47 (77.05%) patients one DD, and 14 (22.95%) had two DDs. The majority of them, 41 patients, had one DD in the

TABLE 3
RELATION OF TRANSITIONAL VERTEBRAE ACCORDING TO TYPE AND VERTEBRA HEIGHT (L5 and S1)

Research parameter	L5		S1		
	N	%	N	%	
Tv according to Castellvi et al.	I A	12	31.58	0	0.00
	I B	10	26.32	1	5.88
	II A	5	13.16	2	11.76
	II B	3	7.89	4	23.53
	III A	4	10.53	5	29.41
	III B	1	2.63	4	23.53
	IV	3	7.89	1	5.88

TABLE 4
OCCURRENCE OF DISC DEGENERATION ACCORDING TO SEGMENT AND NUMBER IN PATIENTS

Research parameters		L4-L5		L5-S1	
		N	%	N	%
Number of dd in patients	One	6	12.77	41	87.23
	Two	7	50.00	7	50.00

TABLE 5
OCCURRENCE OF DISC DEGENERATION IN L4-L5 AND L5-S1 SEGMENT

Research parameters	N	%	
NO	8	11.59	
Dd according to segment	L4-L5	4	5.80
	L5-S1	39	56.52
	L4-L5 and L5-S1	18	26.09

L5-S1 level (Table 4) (Table 5). Classification of DD modified from Pearce was especially applied to discs of L4-L5 and L5-S1. DD of stage II were most common, while even 10 patients had stage III. Four patients had DD of stage IV (Figure 4). These disc changes, for this age of patients,

TABLE 2
CLASSIFICATION OF DISC DEGENERATION MODIFIED FROM PEARCE

1. disc structure; 2. distance between NP and AF; 3. signal intensity; 4. disc height According to measured parameters DD can be divided in 5 stages	
I. Stage	1. disc is homogenous, sharp and white, 2. border between NP and AF is clear, 3. signal hyper intensity is the same as in cerebral fluid; 4. disc height is normal. Such disc is normal.
II. Stage	1. disc is inhomogeneous with or without horizontal line of low signal intensity; 2. border between NP and AF is clear, 3. signal hyper intensity; 4. disc height is normal
III. Stage	1. disc is inhomogeneous, grey; 2. border between NP and AF is unclear; 3. medium signal intensity; 4. disc height is normal or slightly reduced
IV. Stage	1. disc is inhomogeneous, grey-black; 2. border between NP and AF is lost; 3. medium to weak signal intensity; 4. disc height is normal to moderately reduced
V. Stage	1. disc is inhomogeneous, black; 2. border between NP and AF is lost; 3. signal hypo intensity; 4. collapsed disc

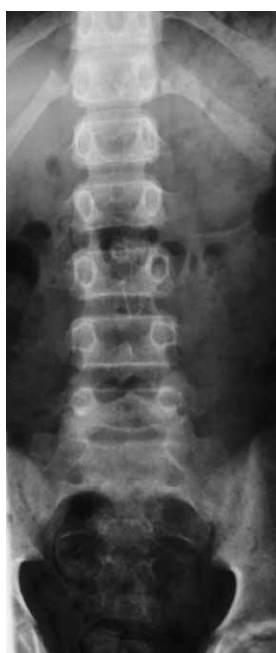

Fig. 2. Standard radiographs of L-S spine in AP projection: transitional vertebra S1 (lumbalisation) type IIIA according to Castellvi et al. Patient S.T., 16 years (boy).

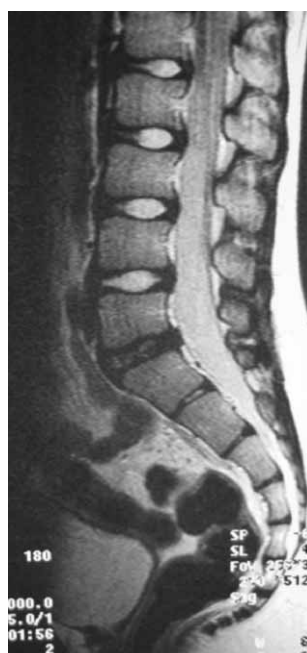

Fig. 4. MR, T2-weighted sequence in sagittal cut: DD of L5-S1 segment, stage IV. Patient S.T., 16 years (boy.)

are clinically relevant (Table 6). Second stage of DD which is shown in MR images as a line of low signal intensity, which is a sign of incipient disc dehydration, is in grown-ups considered normal. In children, it presents morphological change in IVD.

By comparative analysis of data obtained by radiographs and MR images, we found that 56 patients had DD and anomalies. McNemar’s test has established a statistically significant correlation (Table 7). Analysis and

comparison of types of TV according to Castellvi et al. and DD modified from Pearce, statistically analyzed by Fischer, the difference of TV type I and types II, III and IV is statistically significant in favour of the second group (Table 8).

In the group where a transitional L5 vertebra was found, 13 patients had DD of L4-L5 segment and 32 had DD in L5-S1 of II stage according to Pearce and type II according to Castellvi et al. This means that DD is mostly IVD below TV.

In patients with TV, we found that 5 patients had DD in L4-L5 segment, and 15 patients had DD in L5-S1 segment. That means that DD is above TV.

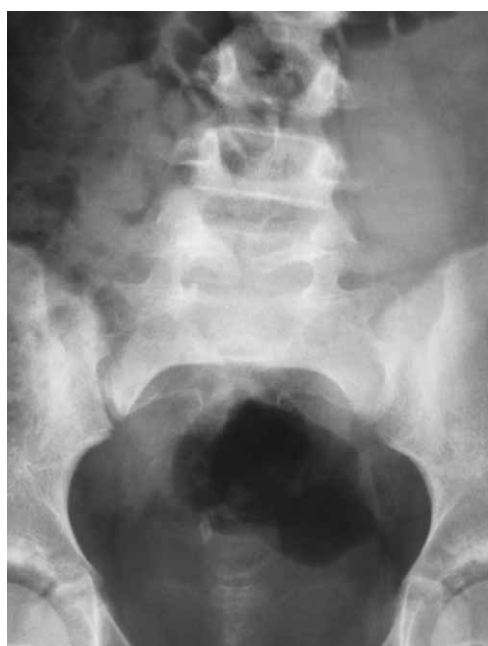

Fig. 3. Standard radiographs of L-S junction in AP projection: Spina bifida occulta of L5 vertebra. Patient K.M., 8 years (girl).

TABLE 6
DISC DEGENERATION ACCORDING TO PEARCE AND OCCURRENCE OF DISC DEGENERATION ACCORDING TO SEGMENT L4-L5 AND L5-S1 WITH EMPHASIS ON STAGE IV

Stage	L4L5		L5S1		L4L5 / L5S1		Total	
	N	%	N	%	N	%	N	%
II.	2	3.28	27	44.26			29	47.54
III.	2	3.28	8	13.11			10	16.39
IV.			4				4	6.56
II.. II.					8	13.11	8	13.11
II.. III.					4	6.56	4	6.56
II. IV.					1	1.64	1	1.64
III.. II.					2	3.28	2	3.28
III.. III.					1	1.64	1	1.64
III.. IV.					1	1.64	1	1.64
IV. II.					1	1.64	1	1.64
Total	4	6.56	39	63.93	18	29.51	61	100

TABLE 7
RELATION BETWEEN PATIENTS WHO HAVE ANOMALY AND DISC DEGENERATION AND THOSE THAT HAVE EITHER DISC DEGENERATION OR ANOMALY

		Disc degeneration	
		Yes	No
Anomaly	Yes	56 (91.80%)	8 (13.11%)
	No	5 (8.19%)	0

(McNemar) $p=0.581$

TABLE 8
RELATION OF TRANSITIONAL VERTEBRAE AND CLASSIFICATION ACCORDING TO CASTELVI AND OCCURRENCE OF DISC DEGENERATION IN THOSE PATIENTS

Research parameters		Disc degeneration			
		Yes		No	
		N	%	N	%
Transitional vertebra and classifications according to Castellvi et al.	I A	10	18.18	2	3.64
	I B	8	14.55	3	5.45
	II A	7	12.73	0	0.00
	II B	7	12.73	0	0.00
	III A	9	16.36	0	0.00
	III B	4	7.27	1	1.82
	IV	4	7.27	0	0.00

I/II, III, IV i DD $p=0.041$ (Fisher)

Comparison of SBO and DD, we found that in DD in L4-L5 segment, 4 (12.9%) patients had SBO, and in DD-a in L5-S1 segment 22 (70.97%) patients had SBO.

In those patients who had DD in both segments, SBO was found in 3 (9.68%) patients and according to the Castellvi et al. classification most common was type II.

Discussion

This paper undertakes a prospective study by analyzing data obtained with radiological research methods. The research was conducted in a group of 75 patients with occasional low back pain without radicular pain and neurological deficit. Six patients were excluded from further analysis after X-ray examination because a known cause for lower back pain was determined. The other 69 were referred to MR imaging under an assumption that they have non-specific low back pain.

Low back pain has been a challenge for many and has been particularly analysed. Most papers were published on back pain in adults, or in patients aged 20 or over. More and more authors tackle the question: Why low back pain in children? That has been at the same time a reason for many epidemiological studies¹⁷⁻¹⁹. Salminen et al. have conducted a prospective study in 1999 in 15-year old school children with and without low back pain.

Apart from clinical examination, MR imaging was included and one or more DD were found in 33% of all children²⁰. The cause for DD was not analyzed. In this paper as well radiographs and MR images were applied in order to determine connection of results obtained by X-ray and MR imaging.

Nejat et al. have investigated the occurrence of SBO and have identified it in 22 of patients²¹. In this study this percentage is even higher (44%).

More authors have dedicated their attention to occurrence of TV and correlation with low back pain.

Bertolotti was the first to describe TV in L-S transition, resulting in many calling low back pain with TV Bertolotti's syndrom²². Dai Liyang has reached the conclusion that the incidence of low back pain is high in persons with TV (35.1%). But, his research was conducted in grown-ups²³. Petherson et al. and Tinni et al. have limited themselves to radiographs^{24,25}.

Luoma et al. have had in their study 30% of patients with TV, but have also included MR imaging in their research and have reached the conclusion that TV leads to early appearance of DD above TV, but in middle age²⁶. In our study we have used the same methods, but in younger age group. Delport et al. have also detected TV in 30% of cases, although patients were not a target group with low back pain²⁷. Analyzing the data, in this study, obtained from standard AP radiographs 55 patients had TV.

A further step was to determine a connection, if existing, of morphological change of IVD in MR images with TV and/or SBO.

Luoma et al. have stressed in their study that *nucleus pulposus* can be best read in T2 weighted image and that early DD can be detected²⁸. The same is stressed by Perry in his study²⁹. Tertti et al. stress the correlation between DD and biochemical and histological composition of IVD. Due to that, in younger persons with change biochemical composition of IVD, a change in T2 weighted image can be detected in sagittal cuts³⁰. All these facts have been taken into account in this study. MR is here the method of choice for detection of pathomorphological substrate in IVD. Erkintalo et al. have in their study of patients with and without low back pain between ages 15 and 18, by analyzing MR in T2 weighted image found positive correlation between DD and low back pain. They did not pay any attention to the cause of DD³¹. Salminen et al. have analyzed MR images of L-S spine in 15-year old patients with low back pain and have found that 32.1% of them have DD³². Paajanen et al. have analyzed DD in MR images of their patients, aged 20, with non-specific low back pain. The data obtained show that 57% of patients have one or more DDs³³. All of these authors have neither searched for nor objectified the cause of DD. Analysis of data in this study has determined connection of anomalies with DD.

So, of 69 patients submitted to our research, 61 patients had DD, of whom additional 56 had also an anomaly in the region of L5-S1, which is statistically signifi-

cant in comparison to 13 patients who had either only DD or anomaly, which is then confirmed with McNemar's test ($p=0.581$). In 69 patients with non-specific low back pain in 56 (81.1%) patients we have determined the cause for low back pain.

Conclusion

Review of literature showed that problems related to low back pain in children are gaining more and more attention. As a result of data analysis this prospective study showed that some children with non-specific low back pain have anomaly of LS spine and DD. First refer-

ral of children presented with occasional low back pain should be radiography of L-S spine, because this method is most standard one and can detect pathological changes in bony part of L-S spine. All children with normal radiographs exam regardless of TV and/or SBO should be referred to MRI images in order to determine whether there is a morphological change in IVD. This study showed increased number of children with both spinal anomaly and DD in compare with children with only spinal anomaly or DD. So, we presumed that those morphological change in IVD, DD, found on MR images, could be a cause of LBP.

REFERENCES

1. SALMINEN JJ, Acta Paediatr Suppl, 315 (1984) 9. — 2. KING HA, Paediatr Clin North Am, 33 (1986) 1489. — 3. BEJIA I, ABID N, BEN SALEM K, LETAIEF M, YOUNES M, TOUZI M, Eur Spine J, 14 (2005) 331. — 4. BERTOLOTTO M., Radiol Med (Torino), 4 (1917) 113. — 5. MOORE KL, DALLEY AF, II: Clinically oriented Anatomy (fourth edition). (Philadelphia, Lippincott, 1999). — 6. AVRAHAMI E, FRISHMAN E, FRIDMAN Z, AZOR M, Spine, 19 (1994) 12. — 7. YOUNG JP, YOUNG PH, Mo Med, 102 (2005) 70. — 8. DIMAR II JR, GLASSMAN SD, CARREON LY, Spine J, 7 (2007) 332. DOI: 10.1016/j.spinee.2006.03.008. — 9. STÄBLER A, BAUR A, REISER MF, Methodology, Spectroscopy and clinical MRI. (Sevilla, Syllabus, 1999). — 10. INMAN VT, SAUNDERS JB, J Bone Joint Surg, 29 (1947) 461. — 11. HYODO H, SATO T, SASAKI H, TANAKA Y, Eur Spine J, 14 (2005) 573. — 12. CASTELLVI A.E., GOLDSTEIN LA, CHAIN DPK, Spine J (1984) 493 — 13. PFIRRMANN ChWA, METZDORF A, ZANETTI M, HODLER J, BOOS N, Spine, 26 (2001) 1873. — 14. MILIČIĆ G, KROLO I, VRDOLJAK J, MAROTTI M, ROIĆ G, HAT J, Coll Antropol, 30 (2006) 55. — 15. BRON JL, VAN ROYEN BJ, WUISMAN PIJM, Acta Orthop Belg, 73 (2007) 687. — 16. HANSON EH, MISHRA RK, CHANG DS, PERKINS TG, BONIFIELD DR, TANDY RD, J Neurosurg Spine, 12 (2010) 47. — 17. JONES MA, STRATTON G, REILLY T, UNNITHAN VB, Health Educ Res, 19 (2004) 284. DOI: 10.1093/her/cyg025. — 18. BEJIA I, ABID N, BEN SALEM K, TOUZI M, BERGAOUI N, Clin Rheumatol, 25 (2006) 715. — 19. AUERBACH JD, AHN J, ZGONIS MH, REDDY SC, ECKER ML, FLYNN JM, Clin Orthop Relat Res, 466 (2008) 1971. — 20. SALMINEN JJ, ERKINTALO MO, PENTTI J, OKSANEN A, KORMANO MJ, Spine, 24 (1999) 1316. — 21. NEJAT F, RADMANESH F, ANSARI S, TAJIK P, KAJBAFZADEH A, EIKHASHAB M, J Neurosurg Pediatrics, 1 (2008) 114. — 22. ELSTER AD, Spine, 14 (1989) 1373. — 23. DAI L, Bull Hosp Jt Dis, 58 (1999) 191. — 24. PETERSON CK, BOLTON J, HSU W, WOOD A, J Manipulative Physiol Ther, 28 (2004) 570. DOI: 10.1016/j.jmpt.2005.08.011. — 25. TINNI PG, WIESER C, ZINN WM, Rheumatol and Rehabilitation, 16 (1977) 180. — 26. LUOMA K, VEHMAS T, RAININKO R, LUUKKONE R, RIIHIMÄKI H, Spine, 29 (2004) 200. — 27. DELPORT EG, CUCUZZELLA TR, KIM N, MARLEY J, PRUITT Ch, DELPORT AG, Pain Physician, 9 (2006) 53. — 28. LUOMA K, VEHMAS T, RIIHIMÄKI H, RAININKO R, Spine, 26 (2001) 680. — 29. PERRY J, HAUGHTON V, ANDERSON PA, WU Y, FINE J, MISTRETTA C, Am J Neuroradiol, 27 (2006) 337. — 30. TERTTI M, PAAJANEN H, LAATO M, AHO H, KOMU M, KORMANO M, Spine, 16 (1991) 62. — 31. ERKINTALO MO, SALMINEN JJ, ALANEN AM, PAAJANEN HEK, KORMANO MJ, Radiology, 196 (1995) 529. — 32. SALMINEN JJ, ERKINTALO-TERTTI MO, PAAJANEN HEK, J Spinal Disord, 6 (1993) 386. — 33. PAAJANEN H, ERKINTALO M, KUUSELA T, DAHLSTROM S, KORMANO M, Spine, 14 (1989) 982.

G. Miličić

Zagreb Children's Hospital, Klaićeva 16, 10000 Zagreb, Croatia
e-mail: gmilicic55@gmail.com

UZROČNA POVEZANOST NESPECIFIČNE NISKE KRIŽOBOLJE I DEGENERACIJE DISKA KOD DJECE S PRIJELAZNIM KRALJEŠKOM I/ILI SPINOM BIFIDOM OCCULTOM – ULOGA MAGNETSKE REZONANCIJE - PROSPEKTIVNA STUDIJA

SAŽETAK

Problem u smislu niske križobolje u djece i adolescenata bavi se sve više stručnjaka. Često se ne nađe uzrok niske križobolje i vode se pod dijagnozom nespecifične niske križobolje. Tema ove prospektivne studije je utvrditi, da djeca s nespecifičnom niskom križoboljom kojima se otkrije postojanje anomalija (prijelazni kralješak - PK i *Spina bifida occulta* – SBO) u lumbosakralnoj (L-S) kralješnici, imaju i degeneraciju intervertebralnog diska (DD) L4-L5 i/ili L5-S. Prospektivnom studijom obrađeno je 69 ispitanika od 8 do 16 godina (X 12,81) i to 40 (57,97%) muških i 29 (42,03%) ženskih ispitanika koji su pregledani u ortopedskoj ambulanti Klinike za dječje bolesti, KBC »Sestre milosrdnice«. Uzrok dolaska je bila nespecifična niska križobolja (NNK). Bol je mjerena vizualnom analognom skalom (VAS) i srednje vrijednosti su bile 3. Trajala je dva do četiri tjedna prije pregleda. Javljala se povremeno tijekom dana i nije bila uzročno povezana s fizičkom aktivnosti. Ispitanici su se podvrgli radiologijskom algoritmu pretraga. Učinjene su standardne snimke (RTG) L-S kralješnice u AP i LL projekciji i magnetska rezonancija (MR) L-S prijelaza i sakruma u sagitalnom i

transverzalnom presjeku na T1 i T2 mjerenoj slici. Na RTG snimkama utvrđene su anomalije na L5 i S1 kralješku kod 65 ispitanika, i to PK koji se klasificirao prema Castellviju et al. i SBO. Na MR-u u T2 mjerenoj slici kod 61 ispitanika pronađen je DD koji se klasificirao modifikacijom prema Pearceu. Obradom i usporedbom podataka, kod 56 ispitanika je potvrđeno da imaju i promjenu na vertebralnom dinamičkom segmentu L5-S1 (VDS-u) (PK i/ili SBO) i DD. Kod 13 ispitanika su pronađeni ili samo DD ili samo anomalije (PK i/ili SBO). Korelacija između anomalija i DD-a kod ispitanika, analizirana je McNemarovim testom kojim je dobivena statistički značajna razlika ($p=0,581$) u korist onih ispitanika koji imaju i anomaliju i DD. Time je utvrđeno da je kod ispitanika, njih 56, uzrok DD-a anomalija u području L-S kralješnice, a time i uzrok njihove niske križbolje.