

# Pleomorphic adenoma in ectopic salivary gland tissue in the neck

---

Lukšić, Ivica; Suton, Petar; Manojlović, Spomenka; Macan, Darko; Dediol, Emil

Source / Izvornik: **Collegium Antropologicum, 2012, 36, 133 - 136**

Journal article, Published version

Rad u časopisu, Objavljena verzija rada (izdavačev PDF)

Permanent link / Trajna poveznica: <https://um.nsk.hr/um:nbn:hr:105:256929>

Rights / Prava: [In copyright](#)/[Zaštićeno autorskim pravom.](#)

Download date / Datum preuzimanja: **2024-08-14**



Repository / Repozitorij:

[Dr Med - University of Zagreb School of Medicine Digital Repository](#)



# Pleomorphic Adenoma in Ectopic Salivary Gland Tissue in the Neck

Ivica Lukšić<sup>1</sup>, Petar Suton<sup>2</sup>, Spomenka Manojlović<sup>3</sup>, Darko Macan<sup>4</sup> and Emil Dediol<sup>1</sup>

<sup>1</sup> University of Zagreb, School of Medicine, Department of Maxillofacial Surgery, University Hospital Dubrava, Zagreb, Croatia

<sup>2</sup> University of Zagreb, School of Medicine, Zagreb, Croatia

<sup>3</sup> University of Zagreb, School of Medicine, Department of Pathology, University Hospital Dubrava, Zagreb, Croatia

<sup>4</sup> University of Zagreb, University Hospital Dubrava, School of Dental Medicine, Department of Maxillofacial Surgery, Division of Oral Surgery, Zagreb, Croatia

## ABSTRACT

*A case of pleomorphic adenoma originating from ectopic salivary gland tissue (ESGT) of the upper neck is reported. A 34-year-old male patient was referred to our Department for a painless swelling in the right submandibular region. Preoperative evaluation (clinical examination, fine-needle aspiration cytology (FNAC) and imaging studies) was performed and the finding was that of a pleomorphic adenoma in ESGT. A modified »S« incision with extension to the submandibular region was performed and the tumour was extirpated. The histopathological report confirmed our initial diagnosis. No recurrence was obtained during a four-year follow-up period. Isolated neck mass may be overlooked as ectopic salivary gland tissue neoplasm (ESGTN). Proper preoperative assessment and optimal surgical treatment are the keys for successful management of these rare tumours. The distinction between metastatic lesion from a head and neck tumour and ESGTN may present considerable diagnostic problem. A review of the literature on ESGT and associated tumours with emphasis on clinical features, diagnosis and treatment is also presented.*

**Key words:** ectopic salivary gland tissue, choristoma, pleomorphic adenoma, upper neck

## Introduction

Salivary tissue neoplasms may originate from normal, accessory and heterotopic (ectopic) sites of salivary gland tissue<sup>1</sup>. Regular salivary tissue is organized in three major (parotid, submandibular and sublingual) and multiple minor salivary glands. Accessory parotid gland is salivary tissue that is located anteriorly and anatomically separated from the main parotid by Stensen's duct<sup>2,3</sup>. Salivary tissue found in unusual locations is termed ectopic or heterotopic salivary tissue, as well as salivary tissue choristoma. In the head and neck region ectopic salivary gland tissue (ESGT) has been found in the middle ear, hypophysis, thyroglossal duct, mandible, tongue, gingiva, lymph nodes of the neck, thyroid gland, parathyroid glands and in the sternoclavicular joint<sup>4–10</sup>. The presence of ESGT is rare and neoplasms of this tissue are even rarer. In the neck it usually manifests as an asymptomatic lump, as a cyst or a draining sinus<sup>11</sup>. According to Willis<sup>12</sup>, there are three main hypotheses for salivary

ectopia: abnormal persistence and development of vestigial structures, dislocation of a portion of definitive organ rudiment mass and further development along with abnormal differentiation of local tissues. In 1999, Ferlito et al.<sup>1</sup> reviewed the literature on ESGTN of the head and neck and identified 111 cases. Ninety-three percent (104 of 111) of these neoplasms were found in the neck region. Neoplasms arising in the ectopic salivary tissue are mostly benign with Warthin's tumour being the commonest histologic type, but several other benign and malignant tumours have been documented including pleomorphic adenoma, papillary cystadenoma, sebaceous lymphadenoma, oncocytoma, mucoepidermoid carcinoma and malignant oncocytoma<sup>1</sup>. We present a case of pleomorphic adenoma (mixed tumour) arising within salivary gland tissue in the neck. To the best of our knowledge, only 19 cases of pleomorphic adenoma in ESGT have been reported so far.

### Case Report

A 34-year-old man was referred to the Department of Maxillofacial Surgery, University of Zagreb School of Medicine with a history of a painless swelling in the right submandibular area, just below the angle of the mandible. The neck lump was present for about five years ago and during that period the patient was symptomless. Clinically there was a palpable node posteriorly to the right submandibular gland, just below the angle of the mandible (Figure 1). The mass was 2.5 x 1.5 cm in size, non attached to the overlying skin, painless, freely movable and separated from the submandibular gland and

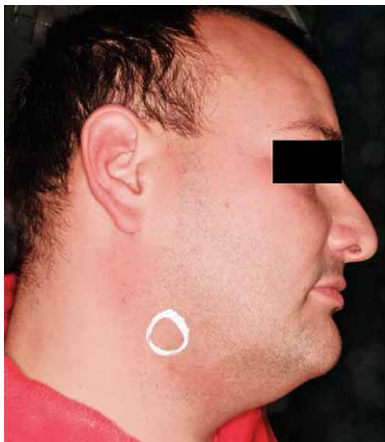

Fig. 1. Preoperative photograph.

the tail of the parotid. There were no other palpable lymph nodes in the neck. Ultrasound guided fine-needle aspiration cytology (FNAC) was performed and the finding was that of a pleomorphic adenoma. Additionally, computed tomography (CT) was done and it revealed a lesion of 23 mm in diameter not adherent to the submandibular nor the parotid gland (Figure 2). Intraoperative

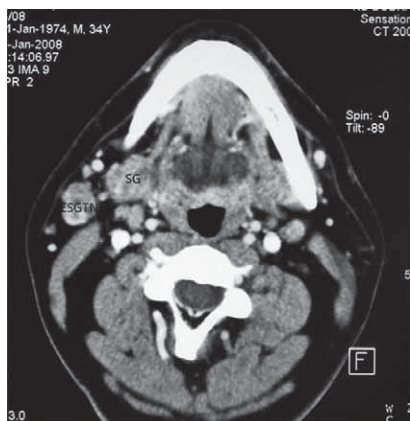


Fig. 2. CT scan showing ectopic salivary gland tissue neoplasm posterior and separated from the submandibular gland. ESGTN – ectopic salivary gland tissue neoplasm, SG – submandibular gland.

finding was identical to clinical and radiographic examinations (Figure 3). The tumour was extirpated and the pathohistologic review confirmed the cytologic report of

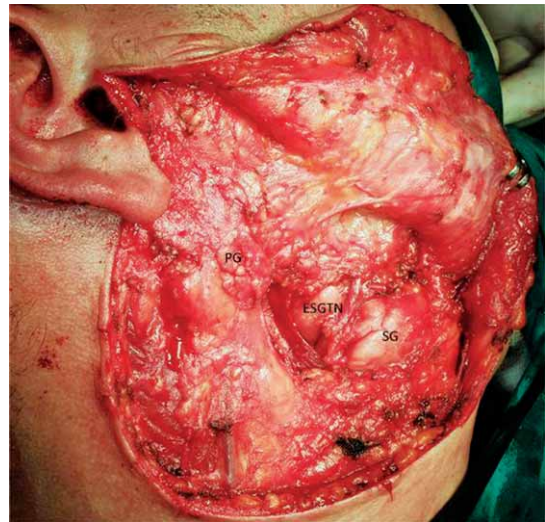

Fig. 3. Intraoperative view showing the retracted subplatysmal flap with the tumour seen between the submandibular gland and the parotid gland. ESGTN – ectopic salivary gland tissue neoplasm, SG – submandibular gland, PG – parotid gland.

a pleomorphic adenoma in ESGT (Figure 4). Postoperative course was uneventful, and function of the facial nerve remains intact. No recurrence was detected during the four-year follow-up period.

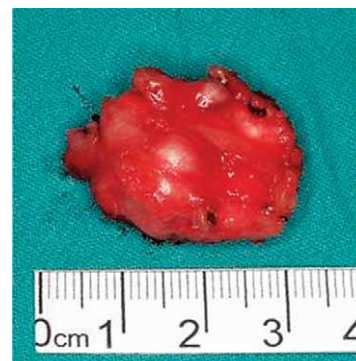

Fig. 4. Extirpated tumour mass.

### Pathologic findings

The well circumscribed, encapsulated oval mass was histologically revealed to be a tumour composed of uniform, mostly cuboidal epithelial cells forming tubuloductal structures, embedded within the chondromyxoid stroma. Remnants of inconspicuous salivary tissue overlies the fibrous capsule of the tumour (Figure 5).

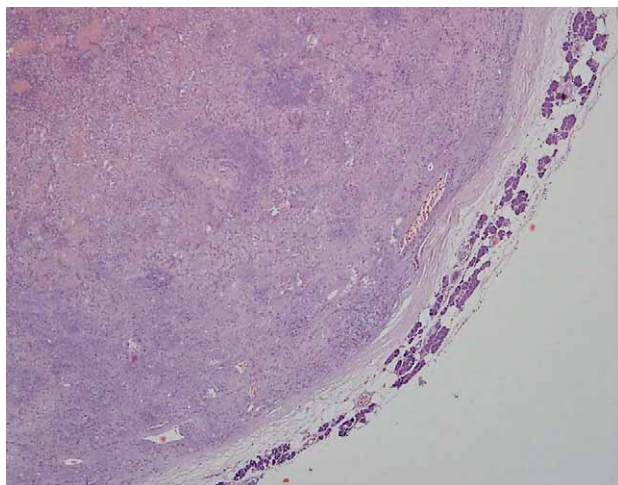


Fig. 5. Pleomorphic adenoma with remnants of salivary tissue. HE x 100.

## Discussion

Ferlito et al.<sup>1</sup> in 1999, reviewed 44 papers with 111 cases of ESGTN previously published. According to Singer et al.<sup>5</sup> the first case was described by Hildebrand in 1895. Histological types of tumours arising in ectopic salivary tissue are similar to those in major salivary glands. Eighty percent of tumours are benign, with Warthin's tumour being most frequent<sup>1,13</sup>. The first case of pleomorphic adenoma of ESGT has been documented in 1976 by Pesavento and Ferlito<sup>9</sup> and since then additionally 18 new cases reports have been published in the English language literature<sup>5,6,9,11,14–24</sup>. Malignant transformation of the ESGT is extremely rare<sup>5,14,18,25–30</sup>.

ESGT in the neck is found predominantly in the jugulodigastric and periparotid area which is consistent with the embryonic theory of late invaginations of salivary tissue in the parotid region leading to incorporation of salivary rests within lymph nodes<sup>30</sup>. However, some studies reported higher incidence in the lower neck<sup>1,11</sup>. On the other hand, ESGTN are reported to be more frequent in the upper neck than in the lower neck, with only one case of neoplastic transformation of ESGT in the mid-cervical region<sup>21</sup>. Although the etiology is not completely understood, there are different theories regarding the development of ESGT of the upper and lower neck. Inclusions of the normal salivary tissue in the

lymph nodes have been proposed for the ectopic salivary tissue in the upper neck and heteroplasia of the ectodermal lining of the cervical sinus of His for the lower neck<sup>5,31</sup>. Clinically in the upper neck ESGT manifests as a slowly enlarging, painless and mobile mass, while lower cervical EST usually presents as a draining sinus<sup>21</sup>.

ESGTN is probably often overlooked in the differential diagnosis of a neck mass. After clinical exam and FNAC of the tumour, radiographic imaging (CT and ultrasound) should follow, because ESGTN should be considered a metastatic lesion until no primary tumour is identified. Daniel and McGuirt<sup>30</sup> proposed an algorithm for evaluation and management of neck/periparotid masses, suggesting excision or parotidectomy alone for benign lesions and isolated low-grade malignant tumours, whereas high-grade malignant lesions require more extensive surgical treatment with possible irradiation which is consistent with reports of other authors<sup>11,18</sup>.

In our case we have treated our patient similarly, having a radiological staging performed with an ultrasound of the neck plus a FNAC of the lesion and CT head/neck after clinical evaluation. Since no primary tumour in major or minor salivary glands or metastatic nodes were found, the neck mass was classified as an ESGTN. The surgical approach included a modified »S« incision extended to the submandibular's gland which provided excellent exposure and facilitated extirpation of tumour mass.

To the best of our knowledge, excision for benign lesions has been reported as sufficient and we have treated our patient according to previously described guidelines<sup>11,18,30</sup>.

## Conclusion

The evaluation and management of neck mass represents a complex task. The differential diagnosis of an isolated neck lump includes cysts of the neck, primary tumours (i.e. lymphoma), metastases from head and neck malignancies and extremely rare ESGTN. Recommended management, after proper preoperative evaluation (physical examination, FNAC and imaging studies), includes excision of the tumour with healthy margins and extended treatment (including neck dissection) with possible postoperative therapy depending on location, size and histological features of the tumour.

## REFERENCES

1. FERLITO A, BERTINO G, RINALDO A, MANNARÀ GM, DEVANEY KO, J Laryngol Otol, 113 (1999) 299, DOI: 10.1017/S0022215100143841. — 2. PERZIK SL, WHITE IL, Am J Surg, 112 (1966) 498, DOI: 10.1016/0002-9610(66)90311-4. — 3. ATTIE JN, SCIUBBA JJ, Curr Probl Surg, 18 (1981) 74, DOI: 10.1016/S0011-3840(81)80003-2. — 4. BROWN RB, CAPTAIN MC, GAILLAND RA, COMMANDER MC, Ann Surg, 138 (1953) 850. — 5. SINGER MI, APPLEBAUM EL, LOY KD, Laryngoscope, 89 (1979) 1772, DOI: 10.1288/00005537-197911000-00009. — 6. LIND O, BANG G, Int J Oral Surg, 12 (1983) 201, DOI: 10.1016/S0300-9785(83)80068-4. — 7. SHINOHARA M, HARADA T, NAKAMURA S, OKA M, TASHIRO H, Int J Oral Maxillofac Surg, 21 (1992) 166, DOI: 10.1016/S0901-5027(05)80787-8. — 8. PERRY BP, SCHER RL, GRAY L, BOSSEN EH, TUCCI DL, Arch Otolaryngol Head Neck Surg, 124 (1998) 714. — 9. PESAVENTO G, FERLITO A, J Laryngol Otol, 90 (1976) 577, DOI: 10.1017/S0022215100082475. — 10. ENOZ M, SUOGLU Y, Laryngoscope, 116 (2006) 1033. — 11. RODGERS GK, FELDER H, YUNIS EJ, Otolaryngol Head Neck Surg, 104 (1991) 533. — 12. WILLIS RA, Br Med J, 3 (1968) 267, DOI: 10.1136/bmj.3.5613.267. — 13. GUDBRANDSSON FK, LISTON SL, MAISEL RA, Otolaryngol Head Neck Surg, 90 (1982) 279. — 14. SURANA R, MOLONEY R, FITZGER-

ALD RJ, Surg Oncol, 2 (1993) 133, DOI: 10.1016/0960-7404(93)90023-R — 15. BOTHRA AC, AGARWAL RK, DUBE MK, BOTHRA S, DIXIT SM, Int Surg, 62 (1977) 228. — 16. MAIR IW, ELVERLAND HH, KNUDSEN OS, J Otolaryngol, 7 (1978) 158. — 17. HULBERT JC, J Laryngol Otol, 92 (1978) 533, DOI: 10.1017/S0022215100085728. — 18. ZAJTCHUK JT, PATOW CA, HYAMS VJ, Otolaryngol Head Neck Surg, 90 (1982) 178. — 19. COTELINGAM JD, GERBERI MP, Arch Otolaryngol, 109 (1983) 563, DOI: 10.1001/archotol.1983.00800220069017. — 20. EVANS MG, RUBIN SZ, J Pediatr Surg, 26 (1991) 1314, DOI: 10.1016/0022-3468(91)90608-V. — 21. TAY HL, HOWITT RJ, J Laryngol Otol, 109 (1995) 445, DOI: 10.1017/S0022215100130403. — 22. SHINOHARA M, IKEBE T, NAKAMURA S, TAKENOSHITA Y, OKA M, MORI M, Br J Oral Maxillofac Surg, 34 (1996) 515, DOI: 10.1016/S0266-4356(96)90248-X. — 23. OHSAWA T, FUKUDA H, KATO J, YAMAGUCHI K, HASHIMOTO K, Bull Kanagawa

Dent Col, 30 (2002) 111. — 24. KUBOTA Y, NITTA S, TAKENOSHITA Y, SHIMIZU M, SHIRASUNA K, Oral Oncology Extra, 41 (2005) 93, DOI: 10.1016/j.ooe.2005.02.002. — 25. BHASKAR SN, Oral Surg Oral Med Oral Pathol, 17 (1964) 62, DOI: 10.1016/0030-4220(64)90316-0. — 26. PERZIN KH, LIVOLSI VA, Cancer, 45 (1980) 967, DOI: 10.1002/1097-0142(19800301)45:5<967::AID-CNCR2820450522>3.0.CO;2-A. — 27. LUDMER B, JOACHIMS HZ, BEN-ARIE J, ELIACHAR I, Arch Otolaryngol, 107 (1981) 547, DOI: 10.1001/archotol.1981.00790450023007. — 28. HATA T, IGA H, IMAI S, HIROKAWA M, Int J Oral Maxillofac Surg, 26 (1997) 290, DOI: 10.1016/S0901-5027(97)80872-7. — 29. SEIFERT G, Pathologie, 18 (1997) 141, DOI: 10.1007/s002920050202. — 30. DANIEL E, MCGUIRT WF SR, Am J Otolaryngol, 26 (2005) 96, DOI: 10.1016/j.amjoto.2004.08.009. — 31. YOUNGS LA, SCOFIELD HH, Arch Pathol, 83 (1967) 550.

I. Lukšić

University of Zagreb, School of Medicine, Department of Maxillofacial Surgery, University Hospital Dubrava, Avenija Gojka Šuška 6, 10000 Zagreb  
e-mail: luksic@kbd.hr

## PLEOMORFNI ADENOM EKTUPIČNOG TKIVA ŽLIJEZDE SLINOVNICE U VRATU

### SAŽETAK

Prikazan je slučaj pleomorfnog adenoma ektopičnog tkiva žlijezde slinovnice u gornjem dijelu vrata. Tridesetčetverogodišnji muškarac upućen je u našu Kliniku zbog bezbolne otekline desne submandibularne regije. Preoperativnom obradom (klinički pregled, citološka punkcija, slikovne metode) dijagnosticiran je pleomorfnu adenom ektopičnog tkiva žlijezde slinovnice. Učinjena je modificirana »S« incizija sa nastavkom na submandibularnu regiju i tumor je odstranjen u cijelosti. Patohistološki nalaz potvrdio je inicijalno postavljenu dijagnozu. Tijekom četverogodišnjeg praćenja bolesnik je bio bez subjektivnih smetnji i nije zabilježen recidiv bolesti. Među izoliranim tvorbama u vratu rijetko se dijagnosticira tumor ektopičnog tkiva žlijezde slinovnice. Detaljna preoperativna obrada i optimalni kirurški zahvat ključ su uspješnog liječenja ovih rijetkih tumora. Značajan dijagnostički problem može predstavljati diferencijalna dijagnoza između metastaza tumora glave i vrata i tumora ektopičnog tkiva žlijezde slinovnice. Dat je pregled literature o ektopičnom tkivu žlijezde slinovnice i pridruženim tumorima s naglaskom na kliničke značajke, dijagnozu i liječenje.