

Calcifying epithelial odontogenic tumor of the maxilla (Pindborg tumor)

Müller, Danko; Manojlović, Spomenka; Lukšić, Ivica; Grgurević, Jakša

Source / Izvornik: **Collegium Antropologicum, 2012, 36, 205 - 208**

Journal article, Published version

Rad u časopisu, Objavljena verzija rada (izdavačev PDF)

Permanent link / Trajna poveznica: <https://um.nsk.hr/um:nbn:hr:105:284455>

Rights / Prava: [In copyright](#) / [Zaštićeno autorskim pravom.](#)

Download date / Datum preuzimanja: **2024-07-10**



Repository / Repozitorij:

[Dr Med - University of Zagreb School of Medicine Digital Repository](#)



Calcifying Epithelial Odontogenic Tumor of the Maxilla (Pindborg Tumor)

Danko Müller¹, Spomenka Manojlović¹, Ivica Lukšić² and Jakša Grgurević²

¹ University of Zagreb, Dubrava University Hospital, Department of Pathology, Zagreb, Croatia

² University of Zagreb, Dubrava University Hospital, Department of Maxillofacial and Oral Surgery, Zagreb, Croatia

ABSTRACT

Calcifying epithelial odontogenic tumor (CEOT), or the Pindborg tumor, is very rare neoplasm, which accounts up to 1% of all odontogenic tumors. These tumors involve mandible almost twice as common as the maxillary bone, mostly in the premolar and molar region and present at first with local swelling. There is no gender predilection and the tumor usually appears between 2nd and 6th decade of life. We report the case of a 36-year-old male patient with a Pindborg tumor in the maxillary region on the right side, also involving the adjacent maxillary sinus, with destroying of the local anatomical structures. Complete surgical excision of the tumor has been performed and four years after surgical treatment, there is no sign of recurrence.

Key words: calcifying epithelial odontogenic tumor (Pindborg tumor), maxilla

Introduction

Calcifying epithelial odontogenic tumor (CEOT) also known as Pindborg tumor is very rare, locally invasive neoplasm, characterized by amyloid-like material that may become calcified¹. It accounts for less than 1% of all odontogenic tumors, without gender predilection and usually clinically presents as slow-growing, painless mass, most often involving premolar and molar region^{2–4}. The most common and prominent clinical symptom of this tumor is swelling with slowly growing mass causing mechanical effects¹. The mandible is affected twice as often as maxilla³, with about two thirds being found in the posterior parts of the mandible, most often in connection with the unerrupted mandibular third molar⁴. Patients between 2nd and 6th decade, with a mean age of 40 years are usually affected². The vast majority of cases are intraosseous, with approximately 6% arising in extraosseous locations². On radiological images the tumor usually shows a multilocular, or less common, an unilocular radiolucency, sometimes with calcified structures inside the lesion, most often around the crown of the impacted (unerupted) tooth⁴, up to 60% of cases³. The third mandibular molar is usually involved in such cases⁴. The two most common appearances of CEOT on radiological images are of pericoronar lucency and of lucent areas with diffuse opacities⁵. According to Kaplan et al., their research based on 67 cases of CEOT reveals that the

mixed radiolucent-radiopaque pattern was the most frequent one with 65%, followed by 32% of radiolucent cases and just 3% of radiopaque cases⁶. In the same study, the unilocular type was more frequent in the maxilla than in the mandible⁶.

The clear cell variant of CEOT is mainly composed of clear cells, which can be often very similar to other clear cell tumors. This variant is often associated with recurrence, together with incompletely excised cases³.

Case Report

A 36-year-old Caucasian male patient was admitted to our Department of Maxillofacial Surgery because of painless swelling, which lasted over 3 months in the region of hard palate and buccal aspect of maxilla on the right side. All radiographic findings, including AP cranial radiography, panoramic radiography and computed tomography, showed a tumorous mass of the right maxillary sinus destroying and resorbing the bone of the lateral wall of the nasal cavity with disrupted structure of the ipsilateral upper jaw, affecting the adjacent teeth and intact lower floor of the orbital space (Figure 1a, b and c). The last two loose molar teeth (17 and 18) were extracted

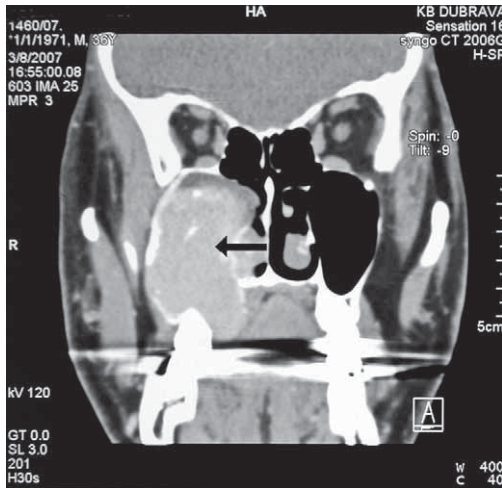


Fig. 1a. CT-scan showing tumor mass in the right maxillar sinus (frontal view).

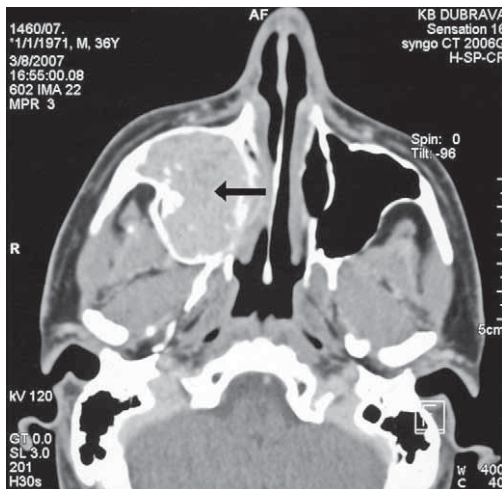


Fig. 1b. CT-scan showing tumor mass in the right maxillar sinus (horizontal view).

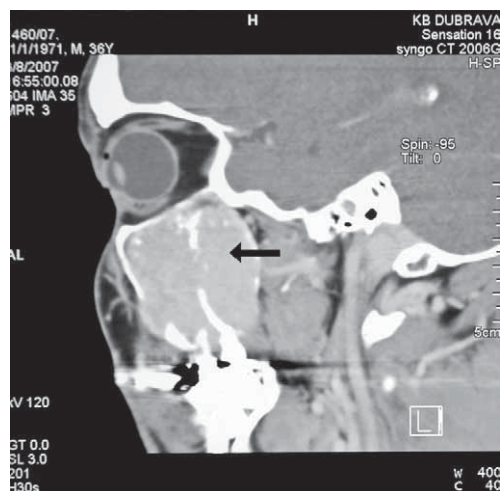


Fig. 1c. CT-scan showing tumor mass in the right maxillar sinus (sagittal view).

and the biopsy was performed which confirmed the diagnosis of calcifying epithelial odontogenic tumor. Surgical treatment included transoral enucleation of the tumorous mass with curettage. The tumorous tissue was very soft and vascularized. After tamponade of the sinus with iodoform band, the same was removed 5 days after surgery and the stitches were removed 12 days after operation. So far, four years after surgical removal, there is no sign of recurrence, both clinically and radiologically.

The tumor volume was about 15 cm³ and histologically it was composed of small islands and sheets of polygonal cells with abundant eosinophilic cytoplasm, clear cell borders and noticeable intercellular bridges (Figure 2a, b and c). Nuclei were pleomorphic, without mitotic figures. Eosinophilic, homogeneous hyaline material, within and around tumor cells, was proven to be amyloid-like, because when stained with Congo red, demonstrated the classic bright green birefringence viewed with polarized light under microscope (Figure 2d). This amyloid-like material was often centrally calcified in the form of Liesegang concentric laminar rings. The entire lesion showed typical cribriform appearance with islands of tumor cells enclosing the previous described hyaline, amyloid-like material.

Discussion and Conclusion

In 1958 Pindborg described these relatively rare lesions⁷. There are around 200 cases described in the literature to the present. Long-term follow up is essential because there is a recurrence risk if the tumor was incompletely resected and in particular with the clear cell variant², which is locally more aggressive. The clear cell variant carries the least favourable prognosis⁸. The recurrence rate of 15% has been reported in this variant, with highest frequency being in the lesions treated with curettage⁴. According to the current literature, the prognosis appears to be good, although a high mitotic activity tends to be connected with malignant behaviour¹.

Malignant transformation and metastatic spread to cervical lymph nodes has also been described in the literature, however in only few cases to the present^{9–12}. Kawano et al. described a case of CEOT of the mandible with malignant transformation and development of metastases of the lung after repeated local recurrence¹⁰. These recurrent tumors had malignant features, like increased nuclear pleomorphism, increased mitotic activity together with increased proliferative activity measured with MIB-1 and vascular invasion¹². Chemotherapy with platinum derivatives has been performed for the pulmonary metastases in this case, which showed very good response, suggesting use of chemotherapeutic agents in such rare cases¹². On the other hand, one has to ask himself about malignant transformation in such rare cases and if it was pure CEOT in the first place, considering the rare occurrence of benign cases.

According to the literature, our case is one of rare CEOT-s described in the maxillary sinus^{13–17}, adding this way to the series of reported CEOT-s. A case of CEOT

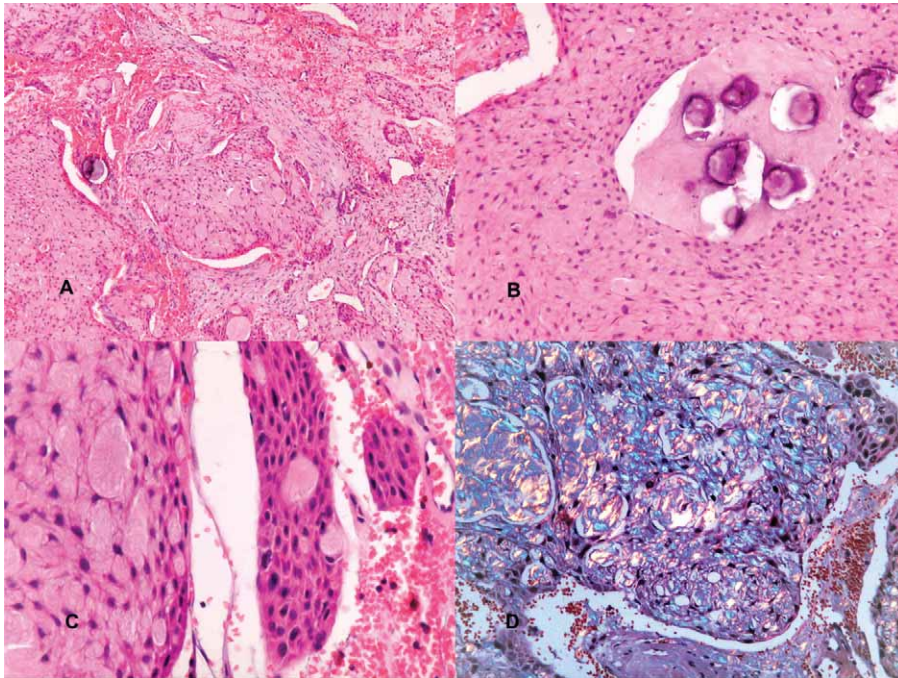


Fig. 2. Hemalaun-eosin stain. A – 100x magnification, B – 200x magnification, C – 400x magnification, D – polarized light (200x).

with intracranial extension has also been reported¹⁴ and sometimes it can even present itself with abnormal eye signs¹¹. A case of CEOT, which presented itself with nasal obstruction as the first presenting symptom was described by Bousdras VA et al.¹⁵.

Differential diagnosis includes adenomatoid odontogenous tumor and other odontogenous tumors, especially the group with radioopaque particles¹⁸. The squamous cell carcinoma should also be considered because of cytological pleomorphism and intercellular bridges². The clear cell variant of CEOT can be mistaken for clear cell odontogenic carcinoma, some metastatic carcinoma, like renal cell carcinoma, and some salivary gland tumors like mucoepidermoid carcinoma and acinic cell carcinoma².

The method of treatment varies and depends mostly on the size and anatomic location of the lesion. Franklin

and Pindborg advise to remove a rim of normal tissue as safe margins together with complete local resection¹⁹. Enucleation with curettage is not recommended because of local recidive possibility¹⁹. They advise against a radical surgical approach of wide resection such as hemimaxillectomy which used to be performed in the past¹⁹. However, sometimes it's impossible to avoid enucleation with curettage, like in our case, because of previously mentioned anatomic location of the tumor. In such cases surgical treatment depends very much on tumor size and its localization.

As previously mentioned, this case is one of the rare occurrences of CEOT in the maxillary sinus, which are documented in the literature. In this way we would like to contribute the series of this tumor occurring in the maxillary region.

REFERENCES

1. SLOOTWEG PJ, Calcifying epithelial odontogenic tumour. In: CARDESA A, SLOOTWEG PJ (Eds) Pathology of the head and neck (Springer-Verlag Berlin Heidelberg, Germany, 2006).
2. TAKATA T, SLOOTWEG PJ, Calcifying epithelial odontogenic tumour. In: BARNES EL, EVESON JW, REICHART P, SIDRANSKY D (Eds) Pathology and Genetics of Head and Neck Tumours WHO Classification of Tumours (IARC Press, Lyon, 2005).
3. NELSON B, Calcifying epithelial odontogenic tumor. In: THOMPSON LDR (Eds) Head and Neck Pathology (Churchill Livingstone Elsevier, Philadelphia, USA, 2006).
4. WALDRON CA (2002) Calcifying epithelial odontogenic tumor (Pindborg tumor). In: NEVILLE BW (Eds) Oral and Maxillofacial Pathology (Saunders Elsevier, Philadelphia, USA, 2002).
5. CHING AS, PAK MW, KEW J, METREWELI C, Am J Neuroradiol, 21 (2000) 343.
6. KAPLAN I, BUCHNER A, CALDERON S, KAFFE I, Dentomaxillofac Radiol, 30 (2001) 22. DOI: 10.1038/sj.dmf.4600566
7. PINDBORG JJ, Cancer, 11 (1958) 838.
8. HICKS MJ, FLAITZ CM, WONG MEK, McDANIEL RK, CA-GLE PT, Head Neck, 16 (1994) 272. DOI:10.1002/hed.2880160311
9. VENESS MJ, MORGAN G, COLLINS AP, WALKER DM, Head Neck, 23 (2001) 692. DOI: 10.1002/hed.1097
10. BASU MK, MATTHEWS JB, SEAR AJ, BROWNE RM, J Oral Pathol, 13 (1984) 310. DOI: 10.1111/j.1600-0714.1984.tb01429.x
11. BRIDLE C, VISRAM K, PIPER K, ALI N, Oral Surg Oral Med Oral Pathol Oral Radiol Endod, 102 (2006) 12. DOI: 10.1016/j.tripleo.2005.12.019
12. KAWANO K, ONO K, YADA N, TAKAHASHI Y, KASHIMA K, YOKOYAMA S, YANASIGAWA S, Oral Surg Oral Med Oral Pathol Oral Radiol Endod, 104 (2007) 76. DOI: 10.1016/j.tripleo.2006.04.014
13. MOHTASHAM N, HABIBI A, JAFAR-ZADEH H, AMICHAGHMAGHI M, J Oral Pathol Med, 37 (2008) 59. DOI: 10.1111/j.1600-0714.2007.00567.x
14. BOUCKAERT MM, RAUBENHEIMER EJ, JACOBS FJ, Oral Surg Oral Med Oral Pathol Oral Radiol Endod, 90 (2000) 656. DOI: 10.1067/moe.2000.106577
15. BOUSDRAS VA, BOUSDRAS KA, NEWMAN L, Dent Update, 36 (2009) 350.
16. NASCIMENTO GJ, PEREIRA KM, NONAKA CF, MEDEI-

ROS AM, GALVÃO HC, Braz J Otorhinolaryngol, 75 (2009) 468. DOI: 10.1590/S1808-86942009000300026 — 17. NAKANO H, OTA Y, YURA Y, Br J Oral Maxillofac Surg, 47 (2009) 222. DOI: 10.1016/j.bjoms.2008.07.

201 — 18. LI L, JÄKEL KT, FRIEDRICH RE, Mund Kiefer GesichtsChir, 8 (2004) 46. DOI: 10.1007/s10006-003-0517-5 — 19. FRANKLIN CD, PINDBORG JJ, Oral Surg Oral Med Oral Pathol, 42 (1976) 753.

I. Lukšić

*University of Zagreb, School of Medicine, Dubrava University Hospital, Department of Maxillofacial and Oral Surgery, Avenija Gojka Šuška 6, 10000 Zagreb, Croatia
e-mail: luksic@kbd.hr*

KALCIFICIRAJUĆI EPITELIJALNI ODONTOGENI TUMOR

S A Ž E T A K

Kalcificirajući epitelijski odontogeni tumor ili Pindborgov tumor je vrlo rijetka novotvorina, koja čini oko 10% svih odontogenih tumora. Oni zahvaćaju mandibulu gotovo dva puta češće nego maksilu., najčešće u području premolara i molara, a prvo se manifestiraju kao ograničena oteklina. Tumor se javlja obično između drugog i šestog desetljeća života. Mi prezentiramo bolesnika straog 36 godina sa Pindborgovim tumorom desne maksilarne regije, koji zahvaća maksilarni sinus sa destrukcijom okolnih anatomskih struktura. Učinjena je kompletna kirurška ekscizija i nakon četiri godine i dalje nema znakova bolesti.