

Cardiac metastases and a sudden death as a complication of advanced stage of head and neck squamous cell carcinoma

Marjanović Kavanagh, Marcel; Janjanin, Saša; Prgomet, Drago

Source / Izvornik: *Collegium Antropologicum*, 2012, 36, 19 - 21

Journal article, Published version

Rad u časopisu, Objavljena verzija rada (izdavačev PDF)

Permanent link / Trajna poveznica: <https://urn.nsk.hr/urn:nbn:hr:105:375192>

Rights / Prava: [In copyright](#) / [Zaštićeno autorskim pravom](#).

Download date / Datum preuzimanja: **2024-09-18**



Repository / Repozitorij:

[Dr Med - University of Zagreb School of Medicine Digital Repository](#)



Cardiac Metastases and a Sudden Death as a Complication of Advanced Stage of Head and Neck Squamous Cell Carcinoma

Marcel Marjanović Kavanagh, Saša Janjanin and Drago Prgomet

University of Zagreb, Zagreb University Hospital Center, Department of Otorhinolaryngology and Head and Neck Surgery, Zagreb, Croatia

ABSTRACT

In head and neck squamous cell carcinoma distant metastases are rare and metastases to the heart are extremely rare. In this report we present a patient with a sublingual and laryngeal carcinoma with metastases to lung and heart. Cardiac metastases present with non-specific symptoms that depends on the size and location of the metastases. The ideal tools for diagnosing cardiac metastases are echocardiography and cardiac MRI. CT scan could be used as a screening method of distant metastases in head and neck cancer. The treatment of cardiac metastases is generally ineffective.

Key words: cardiac metastases, sudden death, head neck cancer, tongue

Introduction

Head and neck squamous cell carcinoma has a lower incidence of distant metastases compared to other malignancies. Common locations of distant metastases are lungs (most common), bones, liver and skin. Distant metastases to heart are extremely rare. In this report we report a case of an advanced sublingual and laryngeal carcinoma with metastases to lungs and heart.

Case Report

A 50-year old male with a long history of tobacco and alcohol abuse presented at the emergency ENT clinic with symptoms of cyanosis and dyspnea. On physical examination we found cyanotic skin and lips, cold skin, and orotracheocutaneous fistula of the right side of the neck, with the pus covering the defect. Tracheal fiberoendoscopy showed suppurative secretion from the fistula, but without greater luminal obstruction. Several minutes after his appearance to the outpatient clinic the patient suddenly died of cardiac arrest.

The patient history revealed that 5 years ago he underwent primary radiotherapy due to squamous cell carcinoma of the right hemilarynx. There was no data on the size of the primary cancer. A year after the radiother-

apy he underwent commando procedure of the left side due to sublingual carcinoma and left neck metastases. A year before his sudden death he underwent total laryngectomy, thyroidectomy and right selective neck dissection due to laryngeal squamous cell carcinoma. The chest X-ray at that time showed no intrathoracic metastases. Histological analysis revealed glottic tumor of 1 cm in diameter with the infiltration of both vocal cords and the subglottic region. There was also an intrathyroid propagation of the tumor. All surgical margins were clear, and the neck was also disease free. A month later he started adjuvant radiotherapy. Couple of weeks before his death he started a palliative chemotherapy due to local residual cancer (larynx) which was ongoing at that time. There was no history of chest pain or any symptoms regarding heart disease.

Following his death, autopsy revealed recurrence in the operated area (larynx) and pulmonary and heart metastases (multiple metastatic small nodes in the lungs and multiple nodes in the right cardiac ventricle, with the largest of 2 cm in diameter, and substantial myocardial tumor infiltration). Cardiac conducting system blockade by metastases was considered to have caused the arrhythmia and sudden cardiac arrest (Figure 1 and 2).

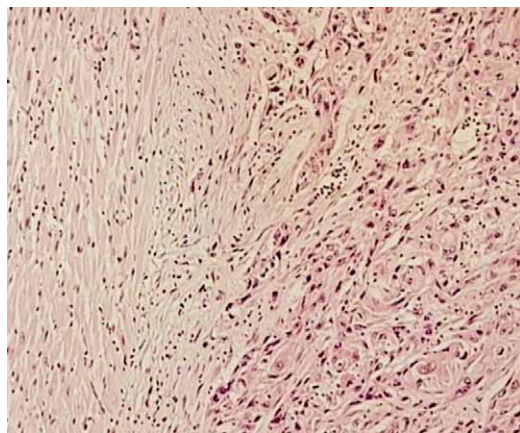


Fig. 1. Normal myocardial tissue (left) and tumor infiltration of the myocardium (right) with atypical low grade squamous cells (HE, magnification 10x).

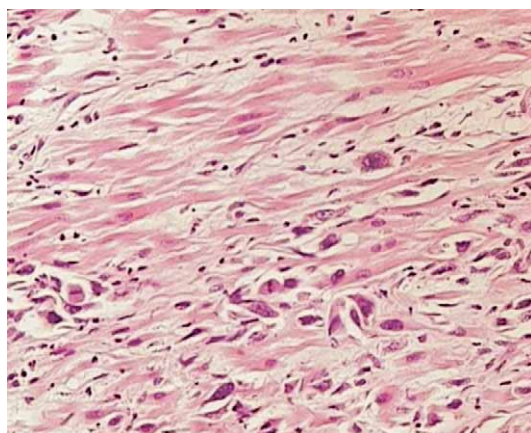


Fig. 2. Squamous cancer cells infiltration between the myocardial fibers (HE, magnification 20x).

Discussion

Primary heart tumors are rare, while the exact incidence of cardiac metastases is not clear. Different studies show that metastatic infiltration of the heart varies from 2.3–18.3%¹, most commonly from lung and breast cancer, lymphoma, leukemia and esophagus. In the autopsy

studies of Kotwall et al. the most common locations of head and neck carcinoma that metastasized distantly were hypopharynx (60%) and the base of the tongue (53%)². Most cases of head and neck distant metastases are discovered within two years after the initial diagnosis³. Although head and neck cancer metastases to the heart are very rare, the cardiac tongue metastases seem to be more frequent than from other head and neck cancer sites. The incidence of tongue cardiac metastases reported in literature is variable, ranging from 1.5–50%^{4–6}. Due to late and unspecific symptoms only very selected cases of ante mortem cardiac tongue cancer metastases are diagnosed. The most common sites of cardiac metastases are pericardium, epicardium and myocardium¹. The clinical presentation varies from hypotension, shortness of breath, arrhythmias (atrial flutter, premature beats, ventricular arrhythmias, conduction disturbances), congestive heart failure and depends on the size and location of the cardiac metastases¹. The electrocardiographic changes are non-specific¹. The electrocardiography of our patient's showed ventricular fibrillation and asystole that would suggest the infiltration of the conduction system which is in accordance with the autopsy finding. The diagnosis of heart metastases in patient with head and neck cancer is not easy. One must think of a cardiac metastasis in a patient with a tongue cancer with cardiac symptoms. The ideal tools for diagnosing the cardiac metastases are echocardiography and cardiac MRI. The CT as a screening tool for distant metastases in head and neck cancer was suggested by some authors for three or more positive lymph nodes, positive bilateral lymph nodes, lymph nodes of 6 cm or larger, positive low jugular lymph nodes, loco regional recurrence and secondary tumor⁷. Although the resection of the cardiac metastases would be the ideal treatment, several attempts were unsuccessful⁸, so mainly radiation and chemotherapy are used for palliation.

Conclusion

We report a case of cardiac metastases which are very rare with the head and neck cancer, and a bit more common with the tongue cancer. Since the treatment of cardiac metastases is unsuccessful, sudden death in patients with tongue cancer should draw more attention on cardiac metastases as a possible cause of death⁹.

REFERENCES

1. BUSSANI R, DE-GIORGIO F, ABBATE A, SILVESTRI F, J Clin Pathol, 60(1) (2007) 27. DOI: 10.1136/jcp.2005.035105 — 2. KOTWALL C, SAKO K, RAZACK MS, RAO U, BAKAMJIAN V, SHEDD DP, Am J Surg, 154(4) (1987) 439. DOI: 10.1016/0002-9610(89)90020-2 — 3. ALVI A, JOHNSON JT, Head Neck, 19(6) (1997) 500. DOI: 10.1002/(SICI)1097-0347(199709)19:6<500::AID-HED7>3.3.CO;2-W — 4. GASSMAN HS, MEADOWS R JR, BAKER LA, Am J Med, 19(3) (1955) 357. — 5.

MANOJLOVIĆ S, Zentralbl Allg Pathol, 136(7-8) (1990) 657. — 6. NAKAYAMA R, YONEYAMA T, TAKATANI O, KIMURA K, Jpn Heart J, 7(3) (1966) 227. — 7. DE BREE R, DEURLOO EE, SNOW GB, LEEMANS CR, Laryngoscope, 110 (2000) 397. — 8. MOSER C, RISSE N, LANGER HJ, Dtsch Med Wochenschr, 116 (1991) 1670. — 9. ITO T, ISHIKAWA N, NEGISHI T, Auris Nasus Larynx, 35 (2008) 423.

M. Marjanović Kavanagh

*University of Zagreb, Zagreb University Hospital Center, University Department of Otorhinolaryngology and Head and Neck Surgery, Kišpatićeva 12, Zagreb 10000, Croatia
e-mail: mmarjano@kbc-zagreb.hr*

SRČANE METASTAZE I IZNENADNA SMRT KAO KOMPLIKACIJA UZNAPREDOVALOG STADIJA PLANOCELULARNOG KARCINOMA GLAVE I VRATA

S A Ž E T A K

Planocelularni karcinomi glave i vrata rijetko udaljeno metastaziraju, a iznimno rijetko metastaziraju u srce. U ovom članku opisujemo bolesnika sa sublingvalnim i laringealnim karcinomom koji je metastazirao u pluća i srce. Srčane metastaze daju nespecifične simptome, koji ovise o mjestu i veličini metastaza. Ultrazvuk i MRI srca najbolje su dijagnostičke metode za otkrivanje srčanih metastaza. CT toraksa bi se mogao koristiti kao metoda probira za udaljene metastaze karcinoma glave i vrata. Liječenje srčanih metastaza u pravilu nije uspješno i svodi se na palijativnu terapiju.