

Auditory evoked potentials and vestibular evoked myogenic potentials in evaluation of brainstem lesions in multiple sclerosis

Ivanković, Anita; Neseck Mađarić, Vesna; Starčević, Katarina; Krbot Skorić, Magdalena; Gabelić, Tereza; Adamec, Ivan; Habek, Mario

Source / Izvornik: **Journal of the Neurological Sciences, 2013, 328, 24 - 27**

Journal article, Accepted version

Rad u časopisu, Završna verzija rukopisa prihvaćena za objavljivanje (postprint)

<https://doi.org/10.1016/j.jns.2013.02.005>

Permanent link / Trajna poveznica: <https://um.nsk.hr/um:nbn:hr:105:969775>

Rights / Prava: [In copyright](#)/[Zaštićeno autorskim pravom.](#)

Download date / Datum preuzimanja: **2024-11-12**



Repository / Repozitorij:

[Dr Med - University of Zagreb School of Medicine Digital Repository](#)





Središnja medicinska knjižnica

Ivanković A., Nesek Mađarić V., Starčević K., Krbot Skorić M., Gabelić T., Adamec I., Habek M. (2013) *Auditory evoked potentials and vestibular evoked myogenic potentials in evaluation of brainstem lesions in multiple sclerosis*. *Journal of the Neurological Sciences*, 328 (1-2). pp. 24-7. ISSN 0022-510X

<http://www.elsevier.com/locate/issn/0022510X>

<http://www.sciencedirect.com/science/journal/0022510X>

<http://dx.doi.org/10.1016/j.jns.2013.02.005>

<http://medlib.mef.hr/1894>

University of Zagreb Medical School Repository

<http://medlib.mef.hr/>

Auditory evoked potentials and vestibular evoked myogenic potentials in evaluation of brainstem lesions in multiple sclerosis

Anita Ivanković, MD^{1,2}, Vesna Neseć Mađarić, MD¹, Katarina Starčević, MD¹, Magdalena Krbot Skorić, Ms EE¹, Tereza Gabelić, MD¹, Ivan Adamec, MD¹, Mario Habek, MD, PhD^{1,3}

¹ University Hospital Center Zagreb, Department of Neurology, Referral Center for Demyelinating Diseases of the Central Nervous System, Zagreb, Croatia

² University Hospital Mostar, Department of Neurology, Mostar, Bosnia and Herzegovina

³ School of Medicine, University of Zagreb, Zagreb, Croatia

Corresponding author:

Mario Habek, MD, PhD

University Department of Neurology

Zagreb School of Medicine and University Hospital Center

Kišpatićeva 12

HR-10000 Zagreb

Croatia

Phone: +38598883323; Fax: +38512376033; e-mail: mhabek@mef.hr

Word count: 1666

Number of references: 22

Number of figures: 2

Number of tables: 1

Authors' contributions

Study concept and design: Ivanković, Krbot Skorić, Adamec and Habek. Acquisition of data: Ivanković, Neseć Mađarić, Starčević, Krbot Skorić, Gabelić, Adamec, Habek. Analysis and interpretation of data: Ivanković, Neseć Mađarić, Starčević, Krbot Skorić, Gabelić, Adamec, Habek. Drafting of the manuscript: Habek. Critical revision of the manuscript for important intellectual content: Ivanković, Neseć Mađarić, Starčević, Krbot Skorić, Gabelić, Adamec, Habek. Administrative, technical, and material support: Ivanković, Neseć Mađarić, Starčević, Krbot Skorić, Gabelić, Adamec, Habek.

Conflict of interest statement: There is no conflict of interest.

Source of funding: None other than the authors own institution.

Abstract

Objective: The aim of this study was to determine the role of magnetic resonance imaging (MRI), auditory evoked potentials (AEP) and vestibular evoked myogenic potentials (VEMP) in the evaluation of brainstem involvement in multiple sclerosis (MS).

Patients and methods: Altogether 32 patients with the diagnosis of MS participated in the study. The following data was collected from all patients: age, gender, Expanded Disability Status Scale (EDSS) score, brainstem functional system score (BSFS) (part of the EDSS evaluating brainstem symptomatology), and involvement of the brainstem on the brain MRI. AEP and ocular VEMP (oVEMP) and cervical VEMP (cVEMP) were studied in all patients.

Results: BSFS, MRI, AEP, oVEMP and cVEMP involvement of the brainstem was evident in 9 (28.1%), 14 (43.8%), 7 (21.9%), 12 (37.5%) and 10 (31,0%) patients, respectively. None of the test used showed statistically significant advantage in the detection of brainstem lesions. When combining oVEMP and cVEMP 18 (56.3%) patients showed brainstem involvement. This combination showed brainstem involvement in greater percentage than BSFS or AEP, with statistical significance ($p=0.035$ and $p=0.007$, respectively).

Conclusion: VEMP is a reliable method in detection of brainstem involvement in MS. It is comparable with MRI, but superior to clinical examination or AEP.

Key words: Auditory evoked potentials, vestibular evoked myogenic potentials, brainstem, multiple sclerosis

Introduction

Multiple sclerosis (MS) is a chronic idiopathic demyelinating illness of the central nervous system and it is the leading cause of disability in young adults.

It is estimated that around 65% of MS patients had one or more brainstem or cerebellar manifestations in the course of the disease. (1) The presence of infratentorial lesions has been associated with worse Expanded Disability Status Scale (EDSS) score at follow-up and is one of the major predictive factors for future disability. (2, 3) As well, several studies have shown that infratentorial lesions are related to long-term prognosis for patients with clinically isolated syndrome and thus may help to identify patients at high risk for earlier occurrence of clinically relevant disability. (4, 5)

Although there is relatively good correlation between brainstem impairment and T2 lesion burden, the association between clinical findings and radiological extent of involvement generally is poor (the so called clinico-radiological paradox). (6, 7)

Evoked potentials are reliable procedures to predict disability in MS patients. Index of global EP alteration (EP score) which combines alterations in visual evoked potentials, AEP, motor and somatosensory evoked potentials showed significant correlation with EDSS score at the time of neurophysiological study and at 1, 3 and 5 years of follow-up. (8) On the other hand, AEP alone are insufficient in detecting subclinical lesions of the brainstem. (9) However, newer brainstem evoked potentials like ocular and cervical vestibular evoked myogenic potentials (oVEMP and cVEMP) have shown promise in detecting brainstem involvement in MS.(10)

The aim of the present study was to determine the role of MRI, AEP and VEMP in the evaluation of brainstem involvement in MS.

Patient and Methods

Patients: Patients with the diagnosis of relapsing-remitting MS according to the revised McDonald's criteria were prospectively included in the study. (11) The following data was collected from all patients: age, gender, Expanded Disability Status Scale (EDSS) score, brainstem functional system score (BSFS) (part of the EDSS evaluating brainstem symptomatology), and involvement of the brainstem on the brain MRI. All participants were informed about the details of the experiment and they all signed informed consent forms. Study was approved by the Ethical committee of the University Hospital Centre Zagreb.

Auditory evoked potentials: During the experiment participants sat or lay in a relaxed position in slightly darkened room. Their eyes were closed in order to avoid ocular artifacts. Activity was recorded with four surface disk electrodes. Active electrodes were situated on the mastoids on both sides and referred to the vertex electrode Cz. Frontal electrode Fz was used as ground electrode. A pair of headphones delivered the stimuli. The stimulation rate was 10 Hz and stimuli were acoustic clicks of 0.1 ms duration. At the beginning of the experiment the perceptive threshold for each participant for each ear was assessed. During the experiment, the intensity of stimulation delivered to the tested ear was 70 dB higher than the perceptive threshold. In the same time the

white noise with the intensity 30 dB lower than the intensity delivered to the tested ear was delivered to the contralateral ear in order to reduce the effect of the bone conductivity. Each series consisted of 1000 stimuli and was repeated twice for each ear in order to provide reproducibility. Recordings were performed using Medelec Synergy, Oxford Instruments, UK. Automated analysis according to the normative values was performed with the same system.

The results of AEP were regarded either as pathological or normal according to the normative values for the laboratory.

Vestibular evoked myogenic potentials: During the experiment participants sat in comfortable chair. Patients were instructed to slightly move their head away from the back of the chair and push it forward in order to activate sternocleidomastoid muscle. The contraction of muscle was maintained due to the cooperation of patients in maintaining the same position during the test. Participants were also instructed to direct their gaze to the ceiling in order to activate ocular muscles. The evoked response from the SCM was recorded from the active surface electrode placed on the belly of the SCM of the stimulated side and referred to the surface electrode placed on the tendon of the same SCM. The evoked response from the OM was recorded from two surface electrodes situated 2 cm below the contralateral eye. Active electrode was situated closer to the eye and referred to the reference 1 cm below. The stimuli were delivered by a pair of headphones in series of 50 trails to one ear at a time and repeated two times for each ear in order to provide reproducibility. The presented stimuli were acoustic clicks of 1 ms duration at the intensity of 130 dB SPL and the stimulation frequency of 1 Hz. Recording were performed using a Brain Products Brain Vision Recorded and the analysis of the recorded data was performed

using a Brain Products Brain Vision Analyzer. Signals were filtered with bandpass filter from 5 Hz to 1000 Hz. For the purpose of the analysis signals were divided in segments of 120 ms duration (20 ms before the stimulus and 100 ms after the stimulus) and averaged for each set of 50 trials. From the averaged responses from the two sets, the grand average was computed and used for further analysis. We used baseline normalized values of the SCM amplitude data instead of the absolute value of amplitude, because absolute amplitude of the evoked response depends on the amplitude of the muscle activity (muscle contraction) and is not reliable measure. The baseline normalized value of amplitude is calculated by dividing the absolute peak to peak amplitude (P13-N23) with mean value of rectified activity of muscle in the period prior the stimulus.

The results of oVEMP and cVEMP were regarded either as pathological or normal according to the normative values for the laboratory.

Statistical analysis: Statistic analysis was performed using IBM SPSS 19.0 (Chicago, IL). We used the McNemar's test, which evaluates changes in related or paired binomial attributes, whether changes in one direction is significantly greater than that in the opposite direction. Phi correlation was performed for MRI, AEP, VEMP and clinical brainstem involvement. P values less than 0.05 were considered significant.

Results

Altogether 32 patients participated in the study, 19 females and 13 males, aged from 21 to 49 years (median 29 years). Median EDSS was 2 (range from 0 to 3.5).

Clinical involvement of the brainstem was evident in 9 (28.1%) patients, meaning that BSFS was greater or equal to 1. Brainstem lesions were evident on MRI in 14 (43.8%) patients.

In only 7 (21.9%) patients AEP showed brainstem involvement. In contrast oVEMP showed brainstem involvement in 12 (37.5%) and cVEMP in 10 (31.0%) patients. When combining oVEMP and cVEMP 18 (56.3%) patients had signs of brainstem involvement.

Although brain MRI showed brainstem involvement in the greatest percentage of patients, none of the test used showed statistically significant advantage in the detection of brainstem lesions (BSFS vs AEP $p=0.791$; BSFS vs MRI $p=0.227$; BSFS vs cVEMP $p=1$, BSFS vs oVEMP $p=0.549$, AEP vs MRI $p=0.092$; AEP vs cVEMP $p=0.549$, AEP vs oVEMP $p=0.302$; MRI vs cVEMP $p=0.344$; MRI vs oVEMP $p=0.815$). Graphical presentation of these results is presented in Figure 1.

However, when oVEMP and cVEMP results are combined, the VEMP results showed brainstem involvement in greater percentage than BSFS or AEP, with statistical significance ($p=0.035$ and $p=0.007$, respectively) (Table 1). Graphical presentation of these results is presented in Figure 2.

There was no correlation between all studies variables (BSFS and AEP: Phi - 0.163, $p=0.357$; BSFS and MRI: Phi 0.289, $p=0.102$; BSFS and VEMP: Phi 0.131, $p=0.457$, MRI and AEP: Phi 0.143, $p=0.419$; VEMP and AEP: Phi 0.162, $p=0.360$, MRI and VEMP: Phi 0.016, $p=0.928$).

Discussion

Results of this study showed that combination of oVEMP and cVEMP is superior in detecting brainstem involvement than clinical examination and AEP. VEMP detects brainstem involvement in greater percentage than MRI, however this was not statistically significant.

Bearing in mind the poor correlation between clinical symptoms and MRI findings there is a need for ancillary tools in the evaluation of brainstem pathology in MS. (6)

Compared to healthy individuals, patients with relapsing-remitting MS have higher values for latencies of waves III and V and interpeaks I-III and I-V of AEP. (12) The combined application of AEP, the auditory middle latency response, and slow cortical potentials promotes better detection of silent MS loci than either of these EP alone. (13) Although AEP may be normal in 30 - 50% of MS patients with symptoms or signs of brainstem involvement, (9, 14) one study on a relatively small number of patients showed that AEP was able to localize lesions along the auditory pathways at a rate that was almost similar to that of MR imaging. (15) Our study showed relatively small percentage of pathological AEP in MS patients compared to MRI and VEMP.

Several studies have already shown that cVEMP is a useful diagnostic method in an evaluation of clinically silent lesions in patients with MS. (16, 17) In patients with MS, cVEMPs are abnormal in up to 50% of patients, and similar results were obtained in our study as well. (17-22) However, when cVEMP and oVEMP are combined up to 80% of patients have pathological finding. (23) Although there was no statistical significance between brainstem clinical findings with

brainstem MRI and cVEMP findings in this study, statistically significant difference was found between brainstem clinical findings and oVEMP ($p=0.02$) (with no statistical significance between brainstem MRI and oVEMP). (23)

The main shortcoming of the present study is relatively small number of patients. However the results have clearly shown that VEMP is a reliable method in detection of brainstem involvement in MS. It is comparable with MRI, but superior to clinical examination or AEP. Although VEMP detects brainstem involvement in greater percentage than the MRI, this difference did not reach statistical significance. Further studies with larger number of patients and follow-up are needed to establish the definite role of VEMP in the diagnosis and monitoring of MS patients.

References

1. Nakashima I, Fujihara K, Okita N, Takase S, Itoyama Y. Clinical and MRI study of brain stem and cerebellar involvement in Japanese patients with multiple sclerosis. *Journal of neurology, neurosurgery, and psychiatry*. 1999;67(2):153-7. Epub 1999/07/17.
2. Filippi M, Horsfield MA, Morrissey SP, MacManus DG, Rudge P, McDonald WI, et al. Quantitative brain MRI lesion load predicts the course of clinically isolated syndromes suggestive of multiple sclerosis. *Neurology*. 1994;44(4):635-41. Epub 1994/04/01.
3. Sailer M, O'Riordan JI, Thompson AJ, Kingsley DP, MacManus DG, McDonald WI, et al. Quantitative MRI in patients with clinically isolated syndromes suggestive of demyelination. *Neurology*. 1999;52(3):599-606. Epub 1999/02/20.
4. Tintore M, Rovira A, Arrambide G, Mitjana R, Rio J, Auger C, et al. Brainstem lesions in clinically isolated syndromes. *Neurology*. 2010;75(21):1933-8. Epub 2010/11/26.
5. Minneboo A, Barkhof F, Polman CH, Uitdehaag BM, Knol DL, Castelijns JA. Infratentorial lesions predict long-term disability in patients with initial findings suggestive of multiple sclerosis. *Archives of neurology*. 2004;61(2):217-21. Epub 2004/02/18.
6. Zadro I, Barun B, Habek M, Brinar VV. Isolated cranial nerve palsies in multiple sclerosis. *Clinical neurology and neurosurgery*. 2008;110(9):886-8. Epub 2008/04/01.
7. Barkhof F. The clinico-radiological paradox in multiple sclerosis revisited. *Current opinion in neurology*. 2002;15(3):239-45. Epub 2002/06/05.
8. Invernizzi P, Bertolasi L, Bianchi MR, Turatti M, Gajofatto A, Benedetti MD. Prognostic value of multimodal evoked potentials in multiple sclerosis: the EP score. *Journal of neurology*. 2011;258(11):1933-9. Epub 2011/04/12.
9. Comi G, Filippi M, Martinelli V, Scotti G, Locatelli T, Medaglini S, et al. Brain stem magnetic resonance imaging and evoked potential studies of symptomatic multiple sclerosis patients. *European neurology*. 1993;33(3):232-7. Epub 1993/01/01.
10. Gabelic T, Krbot M, Sefer AB, Isgum V, Adamec I, Habek M. Ocular and cervical vestibular evoked myogenic potentials in patients with multiple sclerosis. *Journal of clinical neurophysiology : official publication of the American Electroencephalographic Society*. 2013;30(1):86-91. Epub 2013/02/05.
11. Polman CH, Reingold SC, Banwell B, Clanet M, Cohen JA, Filippi M, et al. Diagnostic criteria for multiple sclerosis: 2010 revisions to the McDonald criteria. *Annals of neurology*. 2011;69(2):292-302. Epub 2011/03/10.
12. Matas CG, Matas SL, Oliveira CR, Goncalves IC. Auditory evoked potentials and multiple sclerosis. *Arquivos de neuro-psiquiatria*. 2010;68(4):528-34. Epub 2010/08/24.
13. Japaridze G, Shakarishvili R, Kevanishvili Z. Auditory brainstem, middle-latency, and slow cortical responses in multiple sclerosis. *Acta neurologica Scandinavica*. 2002;106(1):47-53. Epub 2002/06/18.

14. Soustiel JF, Hafner H, Chistyakov AV, Yarnitzky D, Sharf B, Guilburd JN, et al. Brain-stem trigeminal and auditory evoked potentials in multiple sclerosis: physiological insights. *Electroencephalography and clinical neurophysiology*. 1996;100(2):152-7. Epub 1996/03/01.
15. Ko KF. The role of evoked potential and MR imaging in assessing multiple sclerosis: a comparative study. *Singapore medical journal*. 2010;51(9):716-20. Epub 2010/10/13.
16. Alpini D, Pugnetti L, Caputo D, Cesarani A. Vestibular evoked myogenic potentials in multiple sclerosis: a comparison between onset and definite cases. *The international tinnitus journal*. 2005;11(1):48-51. Epub 2006/01/20.
17. Versino M, Colnaghi S, Callieco R, Bergamaschi R, Romani A, Cosi V. Vestibular evoked myogenic potentials in multiple sclerosis patients. *Clinical neurophysiology : official journal of the International Federation of Clinical Neurophysiology*. 2002;113(9):1464-9. Epub 2002/08/10.
18. Bandini F, Beronio A, Ghiglione E, Solaro C, Parodi RC, Mazzella L. The diagnostic value of vestibular evoked myogenic potentials in multiple sclerosis. *Journal of neurology*. 2004;251(5):617-21. Epub 2004/05/28.
19. Murofushi T, Nakahara H, Yoshimura E, Tsuda Y. Association of air-conducted sound oVEMP findings with cVEMP and caloric test findings in patients with unilateral peripheral vestibular disorders. *Acta oto-laryngologica*. 2011;131(9):945-50. Epub 2011/05/14.
20. Patko T, Simo M, Aranyi Z. Vestibular click-evoked myogenic potentials: sensitivity and factors determining abnormality in patients with multiple sclerosis. *Mult Scler*. 2007;13(2):193-8. Epub 2007/04/19.
21. Sartucci F, Logi F. Vestibular-evoked myogenic potentials: a method to assess vestibulo-spinal conduction in multiple sclerosis patients. *Brain research bulletin*. 2002;59(1):59-63. Epub 2002/10/10.
22. Shimizu K, Murofushi T, Sakurai M, Halmagyi M. Vestibular evoked myogenic potentials in multiple sclerosis. *Journal of neurology, neurosurgery, and psychiatry*. 2000;69(2):276-7. Epub 2000/08/29.
23. Gabelic T, Krbot M, Sefer AB, Isgum V, Adamec I, Habek M. Ocular and cervical vestibular evoked myogenic potentials in patients with multiple sclerosis. *Journal of Clinical Neurophysiology*. 2012(in press).

Tables

Table 1. Clinical, MRI and evoked potentials ability to detect brainstem involvement in the studied cohort.

Studied parameter	p value
BSFS vs AEP	0.791
BSFS vs VEMP	0.035
BSFS vs MRI	0.227
AEP vs VEMP	0.007
AEP vs MRI	0.092
VEMP vs MRI	0.454

BSFS brainstem functional system score (part of the EDSS) showing clinical involvement of the brainstem; AEP auditory evoked potentials, VEMP vestibular evoked myogenic potentials, MRI magnetic resonance imaging

Figures

Figure 1. Clinical, MRI and evoked potentials findings showing brainstem involvement in the studied cohort.

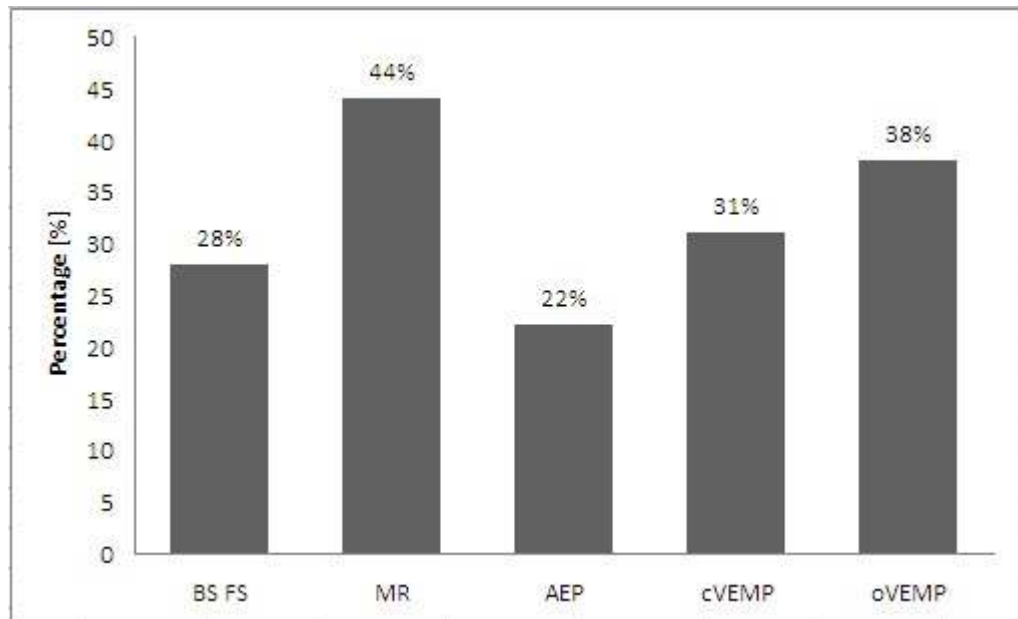


Figure 2. Clinical, MRI and evoked potentials findings showing brainstem involvement in the studied cohort, when oVEMP and cVEMP results are combined.

