

Comparison of multidetector-row computed tomography and duplex Doppler ultrasonography in detecting atherosclerotic carotid plaques complicated with intraplaque hemorrhage

Ajduk, Marko; Bulimbašić, Stela; Pavić, Ladislav; Šarlija, Mirko; Patrlj, Leonardo; Brkljačić, Boris; Pavić, Predrag; Čikara, Igor; Ivanac, Gordana

Source / Izvornik: *Collegium Antropologicum*, 2013, 37, 213 - 219

Journal article, Published version

Rad u časopisu, Objavljena verzija rada (izdavačev PDF)

Permanent link / Trajna poveznica: <https://um.nsk.hr/um:nbn:hr:105:713870>

Rights / Prava: [In copyright](#)/[Zaštićeno autorskim pravom.](#)

Download date / Datum preuzimanja: **2024-08-04**



Repository / Repozitorij:

[Dr Med - University of Zagreb School of Medicine Digital Repository](#)



Comparison of Multidetector-Row Computed Tomography and Duplex Doppler Ultrasonography in Detecting Atherosclerotic Carotid Plaques Complicated with Intraplaque Hemorrhage

Marko Ajduk¹, Stela Bulimbašić², Ladislav Pavić³, Mirko Šarlija¹, Leonardo Patrlj¹, Boris Brkljačić³, Predrag Pavić¹, Igor Čikara³ and Gordana Ivanac³

¹ University of Zagreb, Dubrava University Hospital, Department of Vascular Surgery, Zagreb, Croatia

² University of Zagreb, Dubrava University Hospital, Department of Pathology, Zagreb, Croatia

³ University of Zagreb, Dubrava University Hospital, Department of Radiology, Zagreb, Croatia

ABSTRACT

This study compared sensitivity and specificity of multidetector-row computed tomography and duplex Doppler ultrasonography in detecting atherosclerotic carotid plaques complicated with intraplaque hemorrhage. Carotid plaques from 50 patients operated for carotid artery stenosis were analyzed. Carotid endarterectomy was performed within one week of diagnostic evaluation. Results of multidetector-row computed tomography and duplex Doppler ultrasonography diagnostic evaluation were compared with results of histological analysis of the same plaque areas. American Heart Association classification of atherosclerotic plaques was applied for histological classification. Median tissue density of carotid plaques complicated with intraplaque hemorrhage was 14.7 Hounsfield units. Median tissue density of noncalcified segments of uncomplicated plaques was 54.3 Hounsfield units ($p=0.00003$). The highest tissue density observed for complicated plaques was 31.8 Hounsfield units. Multidetector-row computed tomography detected plaques complicated with hemorrhage with sensitivity of 100% and specificity of 70.4%, with tissue density of 33.8 Hounsfield units as a threshold value. Duplex Doppler ultrasonography plaque analysis based on visual in-line classification showed sensitivity of 21.7% and specificity of 89.6% in detecting plaques complicated with intraplaque hemorrhage. Multidetector-row computed tomography showed a very high level of sensitivity and a moderate level of specificity in detecting atherosclerotic carotid plaques complicated with hemorrhage. Duplex Doppler ultrasonography plaque analysis based on visual in-line classification showed a low level of sensitivity and a moderate-high level of specificity in detecting atherosclerotic carotid plaques complicated with hemorrhage.

Key words: carotid plaque, hemorrhage, multidetector-row computed tomography, duplex Doppler ultrasonography

Introduction

Stroke is the third leading cause of death and second leading cause of death among patients with cardiovascular diseases in developed countries^{1–3}. Atherosclerotic carotid plaque is the main cause of most strokes in people with carotid artery disease, by either causing embolisation or reducing blood flow through cerebral circulation. Carotid artery bifurcation and proximal segment of the internal carotid artery are the usual locations of the atherosclerotic carotid plaque⁴. Large randomized trials showed benefit of carotid endarterectomy (CEA) in sym-

ptomatic patients and to a lesser degree in asymptomatic patients^{5–8}. To justify carotid endarterectomy in asymptomatic patients, higher risk subgroups of asymptomatic patients should be identified. Histological content of the atherosclerotic plaque could be one of the indicators of its higher propensity for causing a stroke. The American Heart Association (AHA) classification of atherosclerotic plaques defines eight types of atherosclerotic plaques, according to its histological content^{9,10}. Atherosclerotic carotid plaques complicated with intraplaque hemorrhage

(AHA type VIb) are considered unstable and are associated with a higher incidence of cerebrovascular events^{11–14}. Occurrence of hemorrhage within the atherosclerotic plaque represents a transition point when a stable plaque becomes unstable (vulnerable) plaque i.e. it becomes more prone to causing a neurologic event. The ideal diagnostic method in evaluation of carotid artery atherosclerotic plaque should provide precise measurement of the degree of carotid artery stenosis, but also it should be able to give information about histological content of the plaque, thus detecting some characteristics of the plaque that make it vulnerable. In our recent published study MDCT showed a very high level of sensitivity and a moderate level of specificity in detecting hemorrhage within atherosclerotic carotid plaque¹⁵. This study compared sensitivity and specificity of multidetector-row computed tomography (MDCT) and duplex Doppler ultrasonography in detecting hemorrhage within atherosclerotic plaque.

Material and Methods

In this prospective study we analyzed 50 carotid plaques taken after carotid endarterectomy (CEA) (Table 1). There were 36 male and 14 female patients, aged 48–87, median 69 years. Twenty patients (40%) were symptomatic and 30 patients (60%) were asymptomatic. Patients were considered symptomatic if cerebral insult, transient ischemic attack, or amaurosis fugax on the side of the affected carotid artery occurred within 6 months of MDCT and duplex Doppler ultrasonography analysis. Indications for CEA were symptomatic patients with carotid artery stenosis >60% and asymptomatic patients with stenosis >70%. All patients had the same imaging evaluation: duplex Doppler ultrasonography first, and MDCT in patients with carotid stenosis >60% on duplex. Endarterectomy was performed within one week of MDCT and duplex evaluation. The approval from the institutional

ethical committee was obtained. Results of histological, duplex Doppler ultrasonography and MDCT analysis were compared.

Surgical technique

Standard surgical technique of CEA with longitudinal arteriotomy over the diseased segment of carotid artery was performed. During the surgery plaques were carefully manipulated in order to preserve morphological integrity of plaques as much as possible. There were no verified perioperative insults.

Duplex Doppler ultrasonography analysis

Duplex Doppler ultrasonography examination was performed using the Logiq 9 scanner, with 7–9 and 9–14 MHz probes (GE Healthcare, Milwaukee, WI), by two experienced radiologists. Degree of carotid artery stenosis was estimated based on flow velocities according to standardized tables.

Visual in-line analysis and classification (analysis and classification during the examination with no additional computer analysis) of carotid plaques based on their appearance on B-mode ultrasound analysis was applied. Predominantly hypoechoic plaques were classified as plaques type 1, predominantly hyperechoic as plaques type 3, and mixed hypo- and hyperechoic plaques were classified as plaques type 2. We believe that more detailed classification without adequate software would be too subjective.

MDCT analysis

The Siemens (Erlangen, Germany) Q1 Somatom Sensation 16-row MDCT scanner was used. One radiologist evaluated data on a Siemens Leonardo Syngo2004A workstation. The standardized optimized, contrast enhanced protocol was used with intermediate reconstruction: 120 kVp, 120 mAs, collimation 16 x 0.75 mm, pitch 1, slice thickness 0.75 mm. Iopamidol was used as contrast medium (370 mg iodine/mL, 4 mL/sec, 70 mm³, 325 psi). Transversal multiplanar reconstructions, orthogonal to the vessel long axis in both coronal and sagittal planes, were used for plaque analysis. Three measurements of tissue density were performed on the visually least dense area of plaque at the level of maximal stenosis. Measurements were performed on a 2 mm² circular area and the smallest value was recorded (Figure 1). Calcifications are obvious on MDCT and were not further analyzed. The distance between carotid bifurcation and level of maximal stenosis was recorded in order to help the pathologist find the corresponding level for histological analysis. Percentage of stenosis was calculated applying North American Symptomatic Carotid Endarterectomy Trial (NASCET) criteria. 7

Histological analysis

Immediately after CEA, plaques were formalin fixed (10% buffered formaldehyde) and sent for histological analysis. One pathologist, blinded for MDCT plaque density,

TABLE 1
PATIENTS' CHARACTERISTICS

Patients' characteristics	
Sex	M 36; F 14
Age	Median 69; Range (48 to 87)
Neurological symptoms	20 (40%)
Diabetes	20 (40%)
Arterial hypertension	48 (96%)
Hyperlipoproteinemia	35 (70%)
Smoking	29 (58%)
Body mass index (BMI) BMI = weight/(height/100) ²	Mean 26,8; SD 4,0
Family anamnesis	17 (34%)
Peripheral arterial disease	20 (40%)
Coronary artery disease	20 (40%)

SD – standard deviation

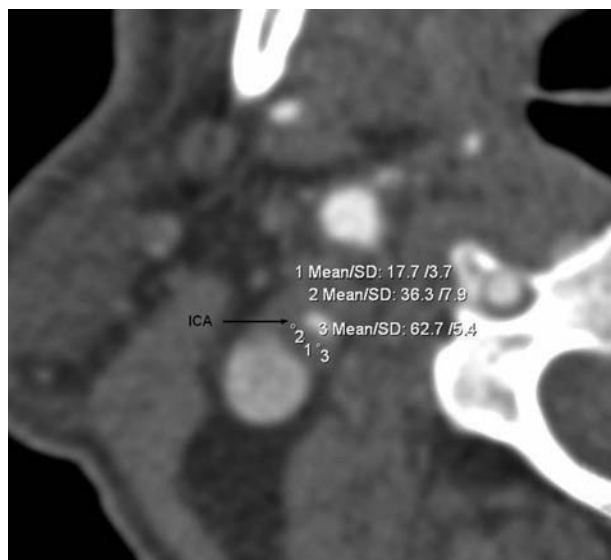


Fig. 1. MDCT. Plaque with the least measured tissue density of 17.7 HU (Hounsfield units). ICA – internal carotid artery.




Fig. 2. Hemorrhage within plaque (plaque type VIb). Same plaque as in Figure 1. Hematoxylin and eosin stain, original magnification $\times 40$. P – plaque, L – lumen.

performed histological analysis. If calcifications were extensive, plaques were first decalcified using 20% nitric acid. That procedure eliminates calcifications while preserving remaining histological content. Samples were sliced in a serial manner, starting from the bifurcation, followed by sections 2 mm apart toward the internal carotid artery. The serial section technique assured precise measurement of the distance between the bifurcation and the level of maximal stenosis. Plaque sections were embedded in paraffin and cut in 4 μm thin slices, using the standard process. Slices were stained with hematoxylin and with Mallory trichrome if necessary (Figure 2). One pathologist examined all plaques and classified them according to the AHA classification of atherosclerotic plaques. The radiologist who performed MDCT analysis was involved in histological analysis, to make sure that the same plaque areas were analyzed on MDCT and histology.

Statistical analysis

The difference of median tissue density between AHA type VIb plaques and other plaque types was calculated using the Mann-Whitney U-test. $P < 0.05$ was considered statistically significant. To determine the cut-off value of tissue density, receiver operating characteristic (ROC) analysis was used. The Wilcoxon test was used to compare degrees of carotid artery stenosis measured by MDCT and duplex Doppler ultrasonography.

Results

Results of MDCT, duplex Doppler and histological analysis are presented in Table 2. Mean carotid artery stenosis measured by MDCT and duplex Doppler was 82.6% (± 9.6) and 80.4% (± 10.0), respectively, ($p = 0.066878$, $Z = 1.832496$, Wilcoxon test). There were 23 (46%) plaques AHA type VIb, 19 (38%) type V, 7 (14%) type VII and 1 (2%) type VIII. Median tissue density AHA VIb carotid plaques was 14.7 HU (range -17.6 to 31.8) while plaques not complicated with intraplaque hemorrhage had median tissue density of 54.3 HU (range -23.6 to 150) ($P = 0.00003$; $U = 97.00$; Mann-Whitney U test) (Figure 3).

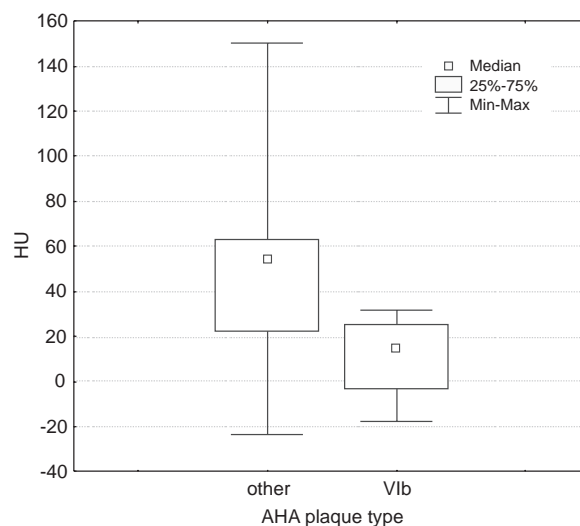


Fig. 3. Box-whisker plots of tissue density of plaques without hemorrhage (other) and plaques with hemorrhage (VIb). HU – Hounsfield units, AHA – American Heart Association.

ROC curve analysis showed 100% sensitivity and 70.4% specificity of MDCT in detecting hemorrhage within atherosclerotic plaque with cut-off value of 33.8 HU (no plaque with tissue density over 33.8 HU was complicated with intraplaque hemorrhage) (Figure 4).

Results of MDCT analysis for different plaque types are summarized in Table 3. On duplex Doppler ultrasonography analysis 8 plaques (16%) were classified as type 1, 29 (58%) as type 2 and 13 (26%) as type 3. Among duplex type 1 plaques (predominantly hypoechogenic plaques) there were 5 (5/8; 62.5%) AHA type VIb plaques.

TABLE 2
RESULTS OF MDCT, DUPLEX DOPPLER AND HISTOLOGICAL ANALYSIS

n	Stenosis % (MDCT)	Stenosis % (duplex)	AHA plaque type	HU	Duplex plaque type
1	70	65	VII	59	2
2	95	90	VIb	-11.6	2
3	95	95	VIb	-17.6	2
4	95	95	V	62.6	1
5	90	90	V	-23.6	2
6	90	90	V	63	3
7	90	90	V	62.8	1
8	90	90	VIb	22.2	1
9	80	85	VIb	31.2	2
10	70	70	VIb	18.2	2
11	80	75	V	22.4	2
12	90	90	VIb	28.5	2
13	80	70	V	62.8	3
14	95	75	VIb	25.2	2
15	70	65	V	60.7	3
16	90	70	VIb	24.1	2
17	80	65	VIb	14.7	2
18	80	70	VIb	21.7	1
19	80	80	V	17.7	2
20	90	80	VIb	23.3	1
21	80	95	V	42.1	3
22	95	95	VIb	26.8	2
23	90	80	V	6.7	3
24	80	70	VII	131	3
25	95	80	VIb	-3.0	1
26	90	80	V	150	3
27	90	90	VIb	-4.0	2
28	70	75	V	28.6	2
29	80	70	VIII	35.8	2
30	90	95	V	11.6	2
31	70	75	V	59.8	2
32	80	80	VIb	3.0	2
33	80	80	V	45.1	2
34	70	75	VIb	31.8	1
35	95	95	VIb	4.0	2
36	80	95	VIb	31.1	2
37	70	80	VIb	5.3	2
38	70	90	VII	54.3	3
39	70	70	VII	79.0	3
40	90	70	V	83.0	3
41	90	80	VII	11.9	2
42	70	75	VII	119.3	3
43	60	60	V	44.9	1
44	90	80	VII	130	3
45	70	80	VIb	9.3	2
46	80	80	VIb	-9.3	2
47	70	70	VIb	11.8	2
48	90	95	VIb	-5	2
49	80	70	V	10.5	3
50	95	90	V	43	2

MDCT – Multi-row Detector Computed Tomography,
AHA – American Heart Association, HU – Hounsfield unit

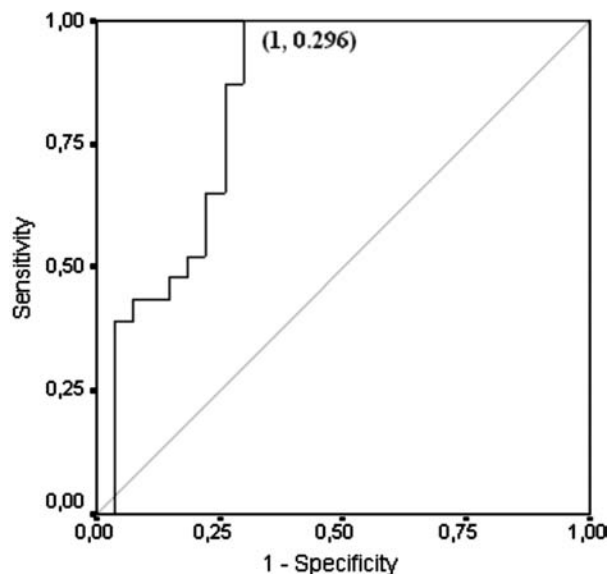


Fig. 4. ROC analysis. Cut-off value of od 33.8 HU, sensitivity 100%, specificity 70.4%, area under curve 0.844, $p=0.0004$.

Among duplex type 2 plaques (mixed hypo- and hyper-echogenic plaques) there were 18 (18/29; 62.1%) AHA type VIb plaques. There were no AHA type VIb plaques among duplex type 3 (predominantly hyperechogenic) plaques.

Thus, in detecting hemorrhage within atherosclerotic carotid plaque, duplex Doppler showed sensitivity of 21.7% and specificity of 89.8% for plaques classified as duplex type 1, and sensitivity of 78.2% and specificity of 59.2% for duplex type 2 plaques. Taking duplex type 1 and 2 as a single group gave duplex Doppler sensitivity of 100% but specificity of only 48.1%.

Discussion

Aim of this study was to find out and compare sensitivity and specificity of MDCT and in-line duplex Doppler ultrasonography analysis in detecting hemorrhage within atherosclerotic carotid plaque. In our previous study we analysed 31 carotid plaques and showed high level of sensitivity (100%) and moderate level of specificity (64.7%) of MDCT in detecting hemorrhage within the atherosclerotic carotid plaque¹⁵. In this study we analyzed 50 carotid plaques and found even higher level of specificity (70.4%) while keeping the sensitivity of 100%. In-line duplex Doppler analysis of the same plaques showed sensitivity of 21.7% and specificity of 89.8% in detecting hemorrhage within atherosclerotic carotid plaque for plaques classified as duplex type 1 (plaques considered to be most vulnerable).

This study showed superiority of MDCT over in-line duplex Doppler analysis in detecting hemorrhage within carotid plaque. Only when duplex predominantly hyperechogenic and mixed hypo- and hyperechogenic plaques were considered as a single group did the duplex Doppler reached the sensitivity of MDCT but at the cost of speci-

TABLE 3
RESULTS OF MDCT PLAQUE ANALYSIS FOR DIFFERENT PLAQUE TYPES

AHA Type	n	Median, range HU	p	Cut-off	Sensitivity	Specificity	p	AUC
VIb	23	14.7 (–17.6; 31.8)	0.00003	33.8	100.0	70.4	0.00004	0.844
V	19	44.9 (–23.6; 150)	0.0349	38.9	63.2	80.6	0.035	0.679
VII	7	94.5 (11.9; 131)	0.0045	49.7	85.7	81.4	0.005	0.837
VIII	1	35.8*						

AHA – American Heart Association, HU – Hounsfield unit, AUC – area under curve.

* Only one plaque type VIII with tissue density of 35,8 HU.

ficity which was only 48.1%. Lal et al. used pixel distribution analysis (PDA) of duplex images and found good correlation with histological analysis^{16,17}. Good correlation of results of computer analysis of duplex images and results of histological analysis of plaques was also found by El-Barghouty et al.¹⁸. Studies that compared visual and computer analysis of duplex images of atherosclerotic plaques showed better concordance with histological analysis when computer analysis of duplex images with adequate software was used^{19,20}.

Results of these studies suggest that low sensitivity of duplex in detecting hemorrhage within the atherosclerotic carotid plaque that we showed in our study could probably be better if computer analysis of duplex images was used.

Currently, clinical practice in treatment of carotid artery stenosis varies among different countries. In some countries asymptomatic patients make majority of operated patients despite the low overall benefit of endarterectomy in those patients^{21–34}. Some authors point out that carotid endarterectomy in asymptomatic patients should be performed only in medically stable patients with carotid artery stenosis >80%, with life expectancy of at least 5 years and only if a <3% perioperative complication rate is expected^{35,36}.

Taking only a degree of carotid artery stenosis in making decision whether to operate the patient or not, leaves patients with <80% stenosis but with vulnerable plaque out of consideration for operation despite the increased risk for neurological event. These patients could benefit from a diagnostic method which not only gives information about degree of stenosis but also about a histological content of the plaque.

On the other hand, in countries where majority of asymptomatic patients with >70% stenosis are operated, patients with <80% stenosis and stable plaque (whose benefit from operation is negligible) could also benefit from the diagnostic method that indicates their low risk of getting neurological event (lower than risk of the operation).

MDCT has potential to address both problems: it can detect patients with increased risk of neurological event who would not be operated (if only degree of carotid artery stenosis is considered in making decision whether to

operate or not), and it can also detect patients with low risk from natural course of carotid artery disease but who are nevertheless considered for the operation.

Previous studies showed high accuracy and very good interobserver agreement of MDCT in evaluation of degree of carotid artery stenosis; it can give information about the type of analyzed tissue and it can also detect intracranial stenoses.^{15,37–44} This study reinforced the role of MDCT in providing information about the content of atherosclerotic carotid artery plaque.

Disadvantages of MDCT are increase of the cost of diagnostic evaluation (compared to duplex Doppler alone) and exposing the patients to radiation. However, MDCT is noninvasive and accurate tool in evaluation of patients with carotid artery disease and increase cost of the evaluation could be in part compensated with reduction of the number of operated patients.

We believe that MDCT and duplex Doppler are complementary studies. We perform duplex Doppler examination first, followed by MDCT if >60% carotid artery stenosis is found on duplex. This algorithm is applicable in most vascular centers.

Duplex Doppler analysis of the carotid artery plaque performed by an experienced investigator using additional computer analysis of duplex images can yield results that are comparable to results of MDCT analysis. In such circumstances, duplex Doppler analysis is probably the only diagnostic method needed for great majority of patients with carotid artery disease.

Conclusion

In this study MDCT showed a very high level of sensitivity and a moderate level of specificity in detecting hemorrhage within atherosclerotic carotid plaque. In-line duplex Doppler analysis of the same plaques showed a low level of sensitivity and a moderate-high level specificity in detecting hemorrhage within atherosclerotic carotid plaque for plaques classified as duplex type 1 (plaques considered to be most vulnerable). Sensitivity of the duplex Doppler in detecting hemorrhage within the atherosclerotic carotid plaque could probably be improved if computer analysis of duplex images was used.

REFERENCES

1. ROSAMOND W, FLEGAL K, FRIDAY G, FURIE K, GO A, GREENLUND K, HAASE N, HO M, HOWARD V, KISSELA B, KITTNER S, LLOYD-JONES D, MCDERMOTT M, MEIGS J, MOY C, NICHOL G, O'DONNELL CJ, ROGER V, RUMSFELD J, SORLIE P, STEINBERGER J, THOM T, WASSERTHIEL-SMOLLER S, HONG Y, Circulation, 115(5) (2007) 69. DOI: 10.1161/CIRCULATIONAHA.106.179918. — 2. KANNEL WB, Epidemiology of cerebrovascular disease: An epidemiologic study of cerebrovascular disease. In: AMERICAN NEUROLOGICAL ASSOCIATION AND AMERICAN HEART ASSOCIATION, Cerebral Vascular Disease (New York, Grune & Stratton, 1966) — 3. KULLER LH, COOK LP, FRIEDMAN GD, Stroke, 3 (1972) 579. DOI: 10.1161/01.STR.3.5.579. — 4. BAMFORD J, SANDERCOCK P, DENNIS M, BURN J, WARLOW C, Lancet, 337 (1991) 1521. DOI: 10.1016/0140-6736(91)93206-O. — 5. THE EXECUTIVE COMMITTEE FOR THE ASYMPTOMATIC CAROTID ATHEROSCLEROSIS STUDY, JAMA, 273(18) (1995) 1421. DOI: 10.1001/jama.1995.03520420037035. — 6. HALLIDAY A, MANSFIELD A, MARRO J, Lancet, 363 (2004) 1491. DOI: 10.1016/S0140-6736(04)16146-1. — 7. NORTH AMERICAN SYMPTOMATIC CAROTID ENDARTERECTOMY TRIAL COLLABORATORS, N Engl J Med, 325 (1991) 445. DOI: 10.1056/NEJM199108153250701. — 8. EUROPEAN CAROTID SURGERY TRIALIST'S COLLABORATIVE GROUP, Lancet, 337 (1991) 1235. DOI: 10.1016/0140-6736(91)92916-P. — 9. STARY HC, CHANDLER AB, DINSMORE R, ET AL, Circulation 92 (1995) 1355. DOI: 10.1161/01.CIR.92.5.1355. — 10. STARY HC, Arterioscler Thromb Vasc Biol, 20 (2000) 1177. DOI: 10.1161/01.ATV.20.5.1177. — 11. GRONHOLDT MLM, NORDESTGAARD BG, SCHROEDER TV, Circulation, 104 (2001) 68. DOI: 10.1161/hc2601.091704. — 12. MATHIESEN EB, BONAA KH, JOAKIMSEN O, Circulation, 103 (2001) 2171. DOI: 10.1161/01.CIR.103.17.2171. — 13. POLAK JF, SHEMANSKI L, O'LEARY DH, Radiology, 208 (1998) 649. PMID: 9722841. — 14. TAKAYA N, YUAN C, CHU B, Stroke, 37 (2006) 818. DOI: 10.1161/01.STR.0000204638.91099.91. — 15. AJDUK M, PAVIĆ L, BULIMBAŠIĆ S, ŠARLIJA M, PAVIĆ P, PATRLJ L, BRKLJAČIĆ B, Ann Vasc Surg, 23(2) (2009) 186. DOI: 10.1016/j.avsg.2008.05.008. — 16. LAL BK, HOBSON RW 2ND, PAPPAS PJ, KUBICKA R, HAMEED M, CHAKHTOURA EY, JAMIL Z, PADBERG FT JR, HASSER PB, DURAN WN, J Vasc Surg, 35(6) (2002) 1210. DOI: 10.1067/mva.2002.122888. — 17. LAL BK, HOBSON RW 2ND, HAMEED M, PAPPAS PJ, PADBERG FT JR, JAMIL Z, DURAN WN, Ann Vasc Surg, 20(2) (2006) 167. DOI: 10.1007/s10016-006-9000-8. — 18. EL-BARGHOUTY NM, LEVINE T, LADVA S, FLANAGAN A, NICOLAIDES A, Eur J Vasc Endovasc Surg, 11(4) (1996) 414. PMID: 8846173. — 19. WILHJELM JE, GRONHOLDT ML, WIEBE B, JESPERSEN SK, HANSEN LK, IEEE Trans Med Imaging, 17(6) (1998) 910. DOI: 10.1109/42.746624. — 20. FOSSE E, JOHNSEN SH, STENSLAND-BUGGE E, JOAKIMSEN O, MATHIESEN EB, ARNESEN E, NJOLSTAD I, Ultrasound Med Biol, 32(1) (2006) 3. DOI: 10.1016/j.ultrasmedbio.2005.09.006. — 21. MCPHEE JT, HILL JS, CIOCCA RG, MESSINA LM, ESALMI MH, J Vasc Surg, 46 (2007) 1112. DOI: 10.1016/j.jvs.2007.08.030. — 22. KRAGSTERMAN B, BJORCK M, LINDBACK J, BERQVIST D, PARSSON H, Stroke, 37 (2006) 2886. DOI: 10.1161/01.STR.0000248967.44015.88. — 23. ŠOŠA T, AJDUK M, ERDELEZ L, ŠKOPLJANAC A, Acta Clin Croatica, 43 (Suppl. 1) (2004) 106. — 24. MAYO SW, ELDRUP-JORGENSEN J, LUCAS FL, WENNBERG DE, BREDENBERG CE, J Vasc Surg, 27 (1998) 1017. PMID: 9652463. — 25. LONG GW, NUTHAKKI V, BOVE PG, Ann Vasc Surg, 21 (2007) 321. DOI: 10.1016/j.avsg.2006.08.003. — 26. LAMURAGLIA GM, BREWSTER DC, MONCURE AC, Ann Surg, 240 (2004) 535. DOI: 10.1097/01.sla.0000137142.26925.3c. — 27. MEHTA RH, ZAHN R, HOCHADEL M, Am J Cardiol, 99 (2007) 1288. DOI: 10.1016/j.amjcard.2006.12.047. — 28. SMURAWSKA LT, BOWYER B, ROWED D, MAGGISANO R, OH P, NORRIS JW, Stroke, 29 (1998) 2014. DOI: 10.1161/01.STR.29.10.2014. — 29. KARP HR, FLANDERS WD, SHIPP CC, TAYLOR B, MARTIN D, Stroke, 29 (1998) 46. DOI: 10.1161/01.STR.29.1.46. — 30. SETACCI C, CHISCI E, DE DONATO G, SETACCI F, GALEZARNO G, Eur J Vasc Endovasc Surg, 34 (2007) 655. DOI: 10.1016/j.ejvs.2007.07.008. — 31. RODGERS H, OLIVER SE, DOBSON R, THOMSON RG, Eur J Vasc Endovasc Surg, 19 (2000) 362. DOI: 10.1053/ejvs.1999.1053. — 32. WONG JH, LUBKEY TB, SUAREZ-ALMAZOR ME, FINDLAY JM, Stroke, 30 (1999) 12. DOI: 10.1161/01.STR.30.1.12. — 33. CEBUL RD, SNOW RJ, PINE R, HERTZER NR, NORRIS DG, JAMA, 279 (16) (1998) 1282. DOI: 10.1001/jama.279.16.1282. — 34. MELISSANO G, CASTELLANO R, MAZZITELLI S, ZOPPEI G, CHIESA R, Eur J Vasc Endovasc Surg, 14 (1997) 164. PMID: 9345234. — 35. DODICK DW, MEISSNER I, MEYER FB, CLOFT HJ, Mayo Clin Proc, 79 (2004) 937. DOI: 10.4065/79.7.937. — 36. ROCKMAN CB, RILES TS, LAMPARELLO PJ, J Vasc Surg, 25 (1997) 423. PMID: 9081121. — 37. JOSEPHSON SA, BRYANT SO, MAK HK, Neurology, 63 (2004) 457. DOI: 10.1212/01.WNL.0000135154.53953.2C. — 38. CHEN CJ, LEE TH, HSU HL, Stroke, 35 (2004) 83. DOI: 10.1161/01.STR.0000106139.38566.B2. — 39. KOELEMAY MJW, NEDERKOORN PJ, REITSMA JB, Stroke, 35 (2004) 2306. DOI: 10.1161/01.STR.0000141426.63959.cc. — 40. MOLL R, DINKEL HP, Eur J Radiol, 39 (2001) 155. PMID: 11566242. — 41. IBARRA DE GRASSA B, ROMERO-VIDAL FJ, MUNOZ-MARTINEZ V, Rev Neurol, 37 (2003) 632. PMID: 14582019. — 42. DE WEERT TT, OUHLOUS M, MELJERING E, Arterioscler Thromb Vasc Biol, 26 (2006) 2366. DOI: 10.1161/01.ATV.0000240518.90124.57. — 43. SABA L, MALLARINI G, AJR Am J Roentgenol, 190 (2008) 41. DOI: 10.2214/AJR.07.2604. — 44. SCHUKNECHT B, Neuroradiology, 49 (Suppl. 1) (2007) 15. DOI: 10.1007/s00234-007-1469-5.

M. Ajduk

University of Zagreb, Dubrava University Hospital, Department of Vascular Surgery, Av. Gojka Šuška 6, 10000 Zagreb, Croatia

e-mail: majduk@yahoo.com

USPOREDBA VIŠESLOJNE KOMPJUTERIZIRANE TOMOGRAFIJE I DUPLEX DOPPLER ULTRAZVUKA U OTKRIVANJU ATEROSKLEROTSKIH KAROTIDNIH PLAKOVA KOMPLICIRANIH KRVARENJEM U PLAK

SAŽETAK

Cilj ove studije bio je usporediti osjetljivost i specifičnost višeslojne kompjuterizirane tomografije i duplex Doppler ultrazvuka u otkrivanju krvarenja u aterosklerotski karotidni plak. U studiji je analizirano 50 karotidnih plakova uzetih nakon karotidne endarterektomije. Uspoređeni su rezultati prijeoperacijske analize višeslojnom kompjuteriziranom tomografijom i duplex-om sa nalazima histološke analize istih područja plakova. Karotidna endarterektomija radila se unutar tjedan dana od analize višeslojnom kompjuteriziranom tomografijom. Prilikom histološke analize koristila se klasifikacija aterosklerotskih plakova predložena od American Heart Association. Median tkivne gustoće karotidnih plakova kompliciranih krvarenjem bio je 14,7 Hounsfieldovih jedinica. Median tkivne gustoće nekalcificiranih dijelova

plakova bez krvarenja bio je 54,3 Hounsfieldove jedinice ($p=0,00003$). Najveća izmjerena tkivna gustoća plakova kompliciranih krvarenjem bila je 31,8 Hounsfieldove jedinice. Višeslojna kompjuterizirana tomografija pokazala je osjetljivost od 100% i specifičnost od 70,4% u otkrivanju plakova kompliciranih krvarenjem pri graničnoj vrijednosti od 33,8 Hounsfieldove jedinice. Koristeći vizuelnu klasifikaciju plakova, duplex je pokazao osjetljivost od 21,7% i specifičnost od 89,7% u otkrivanju plakova kompliciranih krvarenjem. Rezultati ove studije pokazali su vrlo visoku osjetljivost i umjerenu specifičnost višeslojne kompjuterizirane tomografije, te nisku osjetljivost i umjereno visoku specifičnost duplex-a u otkrivanju plakova kompliciranih krvarenjem.