

Fever of unknown origin: large vessel vasculitis diagnosed by PET/CT

Bosnić, Dubravka; Barešić, Marko; Padjen, Ivan; Balenović, Antonija; Žarković, Kamelija; Anić, Branimir

Source / Izvornik: **Rheumatology International, 2013, 33, 2417 - 2421**

Journal article, Accepted version

Rad u časopisu, Završna verzija rukopisa prihvaćena za objavljivanje (postprint)

<https://doi.org/10.1007/s00296-012-2425-1>

Permanent link / Trajna poveznica: <https://urn.nsk.hr/urn:nbn:hr:105:677318>

Rights / Prava: [In copyright](#)/[Zaštićeno autorskim pravom.](#)

Download date / Datum preuzimanja: **2024-07-23**



Repository / Repozitorij:

[Dr Med - University of Zagreb School of Medicine
Digital Repository](#)





Središnja medicinska knjižnica

Bosnić D., Barešić M., Padjen I., Balenović A., Žarković K., Anić B.
(2013) *Fever of unknown origin: large vessel vasculitis diagnosed by*
***PET/CT*. *Rheumatology International*, 33 (9). pp. 2417-21. ISSN**
0172-8172

<http://www.springer.com/journal/296/>

<http://link.springer.com/journal/296/>

<http://dx.doi.org/10.1007/s00296-012-2425-1>

<http://medlib.mef.hr/1937>

University of Zagreb Medical School Repository

<http://medlib.mef.hr/>

Fever of unknown origin – large vessel vasculitis diagnosed by PET/CT

Authors: Dubravka Bosnić¹, Marko Barešić¹, Ivan Padjen¹, Antonija Balenović², Kamelija Žarković³, Branimir Anić¹

¹*Division of Clinical Immunology and Rheumatology, Department of Internal Medicine, University of Zagreb School of Medicine, University Hospital Centre Zagreb, Kišpatičeva 12, Zagreb, Croatia*

²*Medikol Polyclinic, PET/CT Centre, Vinogradska 29, Zagreb, Croatia*

³*Department of Pathology and Cytology, University of Zagreb School of Medicine, University Hospital Centre Zagreb, Kišpatičeva 12, Zagreb, Croatia*

Corresponding author:

Ivan Padjen,

Division of Clinical Immunology and Rheumatology, Department of Internal Medicine, University of Zagreb School of Medicine, University Hospital Centre Zagreb, Kišpatičeva 12, 10000 Zagreb, Croatia

Telephone: +385 1-238-8330

Fax: +385 1-238-8335

E-mail: ivan_padjen@yahoo.ca

Abstract

PET/CT is starting to play an important role in evaluating fever of unknown origin (FUO), due to its ability to localize and delineate areas of high metabolic activity, such as neoplastic proliferation and inflammation, including vasculitis. We present a case of giant cell arteritis (GCA) in a 72 year old female patient admitted to our department with a four month history of FUO, weight loss and fatigue, without specific symptoms or signs. Laboratory investigations suggested acute phase response, with a pronounced erythrocyte sedimentation rate (ESR), high CRP level and microcytic anemia. A thorough diagnostic evaluation was performed in order to exclude an unknown primary tumor which was initially suspected due to a positive family history of cancer. Surprisingly, PET/CT revealed large vessel vasculitis affecting the ascending, descending and abdominal aorta, as well as subclavian, proximal brachial and carotid arteries bilaterally. Biopsy of the superficial temporal artery confirmed the diagnosis of GCA. Treatment with methylprednisolone and azathioprine led to resolution of clinical symptoms and normalization of laboratory parameters. In addition to the use of PET/CT in the evaluation of FUO, its value as a method complementary to temporal artery biopsy is also discussed.

Keywords: fever of unknown origin (FUO), PET/CT, giant cell arteritis (GCA), vasculitis

Abbreviations:

FUO: fever of unknown origin;

ESR: erythrocyte sedimentation rate;

CRP: C reactive protein;

GCA: giant cell arteritis;

PMR: polymyalgia rheumatica;

PET: positron emission tomography;

FDG: 2-deoxy-2-[18F]fluoro-D-glucose;

CT: computed tomography;

MSCT: multislice CT;

SUVmax: maximum standard uptake value;

SUVs: standard uptake values

Introduction

Fever of unknown origin (FUO) is classically defined as fever of at least 38.3°C on several occasions, lasting for more than three weeks. In addition, an uncertain diagnosis after three days despite adequate in-hospital investigations or three out-patient visits is also an integral part of the definition [1].

A variety of possible clinical entities should be considered in the workup of FUO: infectious diseases, chronic granulomatous non-infectious diseases, oncological and hematological diseases, as well as inflammatory rheumatic conditions, including connective tissue diseases and vasculitides [2, 3, 4].

Vasculitides are a heterogenous group of diseases characterized by vessel wall inflammation, leukocyte infiltration and reactive damage to mural structures and surrounding tissues [5]. Patients with different types of vasculitis may present with constitutional symptoms, such as fever and weight loss. This may be accompanied by an elevated erythrocyte sedimentation rate (ESR) and C reactive protein (CRP) level, along with abnormalities of other laboratory results, suggesting acute phase response [6].

Giant cell arteritis (GCA) is the most common form of systemic vasculitis in adults, especially among the elderly female population. The highest incidence is found in northern Europe and Minnesota (USA); rates are lower in Mediterranean countries. GCA is a granulomatous inflammation involving large- and medium-sized arteries. In addition to previously mentioned nonspecific symptoms, it may present with headache, jaw claudication, toothache and sudden visual loss (usually unilateral), as well as limb claudication in rare cases. Moreover, approximately one half of patients with GCA have polymyalgia rheumatica (PMR), a condition characterized by shoulder and pelvic girdle morning stiffness and pain. Nevertheless, symptoms of GCA may be absent or constitutional, as already mentioned [7].

Positron emission tomography (PET) scans with 2-deoxy-2-[¹⁸F]fluoro-D-glucose (FDG) combined with computed tomography (CT) is starting to play an important role in evaluating FUO. FDG is a radioactive and nonmetabolizable analog of glucose accumulating in metabolically active cells. High uptake of FDG is normally observed in the brain, myocardium, kidneys and the urinary bladder. However, the diagnostic use of PET is based on the high uptake of FDG into malignant and inflammatory cells. PET/CT is superior to PET alone, due to its greater ability to delineate areas of high FDG uptake [8, 9].

We present an unusual case of a patient presenting with FUO, suspected as large vessel vasculitis by PET/CT and confirmed as GCA by biopsy of the superficial temporal artery.

Report of Case

A 72 year old Caucasian female was referred to our department with a four month history of excessive fatigue, fever up to 38.5°C with occasional rigors and a 6 kilogram body weight loss due to lack of appetite. There was no leading sign or symptom suggesting infectious disease. Urine cultures were positive for *E. coli* and the patient was treated accordingly. The control urine culture was negative. Nevertheless, the previously mentioned symptoms persisted.

The patient denied night sweats, muscle weakness and dryness of the eyes and mouth. She also denied jaw claudication, headache, toothache and sudden visual impairment. Moreover, there was no history of upper or lower limb claudication, abdominal or chest pain.

Prior to onset of the symptoms, the patient's history was unremarkable, apart from essential arterial hypertension, which was diagnosed 17 years ago and has been treated since then. She also underwent a diagnostic evaluation 20 years ago because of a positive PPD test. However, tuberculosis was not confirmed. The patient's father suffered from cancer of the upper jaw, although the exact type of the cancer was unknown to our patient.

She was admitted to our department for further evaluation. She was subfebrile 37.5°C on physical examination. A systolic murmur was audible over the entire precordium, with a *punctum maximum* in the projection of the apex. Blood pressure was elevated (160/90 mmHg) and equal on both arms. Skin examination did not reveal any rashes. There was no scalp tenderness or decrease of temporal artery pulsations. Other findings on physical examination were unremarkable. There were no physical signs of vascular insufficiency or malignancy, except for the weight loss. Musculoskeletal examination was completely normal, with a normal range of motion and no signs of synovitis.

Laboratory investigations suggested acute phase response (Table 1).

The PPD skin test was positive (15 mm in diameter), as well as the Quantiferone test for detecting *M. tuberculosis*.

Results of ECG, chest X-ray, X-ray of the lumbosacral spine, pelvis and both hips, bone marrow cytology, abdominal and pelvic ultrasound and multislice CT (MSCT), colonoscopy, esophagogastroduodenoscopy, gynaecologic examination and transvaginal ultrasound came back

unremarkable, except for several diverticula of the large intestine, without signs of diverticulitis. Echocardiography revealed a hemodynamically insignificant pericardial effusion. Furthermore, technetium-99m bone scan revealed mild accumulation in the right hip and right knee, most likely of degenerative origin.

The previously described detailed evaluation did not reveal the cause of the patient's clinical presentation. An unknown primary tumor was suspected considering the family history of cancer. Therefore, an integrated FDG-PET/CT was performed.

Coronal and sagittal views on the integrated PET/CT revealed diffusely increased accumulation of FDG in the walls of large arteries, including the ascending, descending and abdominal aorta, as well as subclavian, proximal brachial and carotid arteries bilaterally, suggesting large vessel vasculitis. The maximum standard uptake value (SUVmax) was 3.7 (Figure 1). Diffusely inhomogenous accumulation was observed in the area of the spine, with a small focal accumulation in the region of the Th12 vertebra, as well as the S2 region, without a defined morphological substrate or evidence of secundarism (SUVmax 3.8). A mild diffuse accumulation was also noticed in the spleen (SUVmax 2.1).

Although there were no symptoms of headache or visual impairment, GCA was strongly suspected given the patient's age and previously mentioned findings. Biopsy of the left superficial temporal artery was performed. It revealed an inflammatory granulomatous reaction that included histiocytes, giant multinuclear cells and lymphocytes. The inflammatory reaction fragmented the internal and external elastic lamina. This pattern was compatible with GCA (Figure 2).

Based on the findings of the integrated PET/CT and temporal artery biopsy, the patient was diagnosed with GCA.

Treatment was started with methylprednisolone 32 mg (0.5 mg/kg) daily for the first two weeks, along with daily azathioprine and aspirin (50 mg and 100 mg, respectively). Pantoprazole, alendronic acid, cholecalciferol and calcium supplementation were added to the treatment from the beginning, in order to prevent side effects. The treatment led to a prompt resolution of symptoms and a decrease of ESR and CRP, as well as normalization of red blood count levels. Methylprednisolone was tapered according to the clinical course. At a follow-up visit ten months after the beginning of treatment, the patient was in remission receiving 4 mg methylprednisolone daily, including other medications as mentioned previously. During the observed ten-month period the patient regained 5 kilograms and felt generally good.

Discussion

Several diagnostic methods are recommended for the evaluation of FUO, including nuclear imaging [10]. Nuclear imaging detects functional and metabolic changes even before a morphological correlate develops. PET is a nuclear imaging method based on the uptake of FDG by metabolically active cells. FDG has shown to be a useful tracer, since it accumulates in both malignant and inflammatory cells, covering more than 50% of possible causes of FUO, including vasculitis [8, 9]. FDG scans are more sensitive (77% to 92% in untreated patients) and specific (89-100% in untreated patients) in detecting vessel wall inflammation compared to gallium-67 scans. Thus, a smaller number of cases remains undiagnosed. Additionally, data suggest that the level of FDG accumulation is associated with disease activity. This is potentially useful in the follow-up of patients with vasculitis [11, 12, 13]. PET combined with CT allows more precise anatomic localization and better spatial resolution in delineating areas of FDG uptake, being superior to PET alone [8, 9].

On the other hand, it is important to notice that vasculitis is not the most common cause of increased FDG uptake in blood vessel walls. Atherosclerosis is the most common inflammatory condition of the arteries, hence it is more often responsible for an increased FDG uptake. This may lead to a false positive result in patients otherwise suspected with vasculitis. Thus, it is important to distinguish large vessel vasculitis from atherosclerosis on PET/CT. Mean standard uptake values (SUVs) of atherosclerotic arteries increase with age and are up to 2.01 ± 0.50 in the eldest group of patients [14], similar to the values of vessels affected by vasculitis. Therefore, the distinction should be made not only on the basis of SUVs, but pathoanatomic properties and distribution of the affected vascular segments should also be taken into account [15]. If none of these criteria lead to a diagnostic conclusion, an *ex iuvantibus* steroid trial may be useful.

Vasculitides are categorized into three groups, according to vessel size [16, 17]. Large vessel vasculitis represents about 17% of all FUO cases among patients over 50 years of age [3, 4]. GCA is the most common cause of large vessel vasculitis, predominantly involving the proximal aorta and its branches, and characterized by a granulomatous inflammation of the vessel wall [5]. It may present with vascular insufficiency and/or constitutional symptoms. Methods used in the evaluation of GCA are temporal artery biopsy, color duplex ultrasonography, angiography, MRI, scintigraphy, FDG-PET, and integrated FDG-PET/CT [8, 18, 19]. Temporal artery biopsy is still the gold standard for diagnosing GCA. However, it is suggested when the probability of the

diagnosis is at least intermediate [20]. In addition, the biopsy is positive in only 60% of GCA patients with the involvement of the aorta and its main branches [21]. Therefore, a delayed diagnosis is not uncommon in this subgroup of patients.

Our patient presented with constitutional symptoms – FUO and a pronounced weight loss. Due to the patient's age, clinical presentation and a family history of cancer, an unknown primary tumor was initially suspected. As the patient did not present with clinical signs of temporal arteritis, temporal artery biopsy was not considered to be a method of choice in the clinical workup before performing integrated PET/CT. Surprisingly, PET/CT revealed signs of large vessel vasculitis, leading to a strong suspicion of GCA. Temporal artery biopsy confirmed the diagnosis.

Even though a temporal artery biopsy *per se* would have been sufficient to diagnose GCA in this case, the likelihood of a histological pattern suggesting GCA was only 60%. PET/CT was the only method that could enable us to clearly assess the anatomic extent of vessel wall inflammation. With an important limitation: it did not reveal pathological increase of FDG uptake in the temporal arteries. This false negative finding is due to a low spatial resolution of PET/CT in that area [11].

In conclusion, PET/CT seems to be a helpful method in evaluating FUO and diagnosing large vessel vasculitis, including GCA, especially in cases with no specific symptoms suggesting vascular insufficiency. The method is also interesting because of its potential in the assessment of disease extent and activity. Nevertheless, further studies are needed to establish more precise quantitative criteria for diagnosis and patient follow-up. Furthermore, PET/CT can not completely replace temporal artery biopsy, due to its low spatial resolution in the temporal artery area. We believe that the biopsy and PET/CT are complementary methods that should be used depending on the clinical presentation: PET/CT as a method of choice in patients presenting with FUO/constitutional symptoms, and biopsy in patients with specific symptoms suggesting temporal arteritis.

Conflict of Interest

The authors declare that they have no conflict of interest.

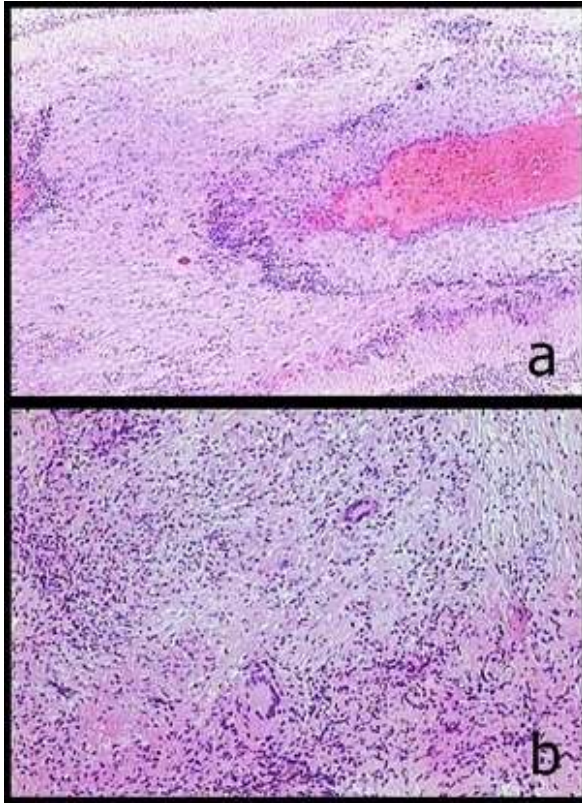
Reference List

1. Durack DT, Street AC (1991) Fever of unknown origin--reexamined and redefined. *Curr Clin Top Infect Dis* 11:35-51
2. Ergönül O, Willke A, Azap A, Tekeli E (2005) Revised definition of "fever of unknown origin": limitations and opportunities. *J Infect* 50(1):1-5
3. Vanderschueren S, Knockaert D, Adriaenssens T, Demey W, Durnez A, Blockmans D, Bobbaers H (2003) From prolonged febrile illness to fever of unknown origin: the challenge continues. *Arch Intern Med* 163(9):1033-1041
4. Knockaert DC, Vanderschueren S, Blockmans D (2003) Fever of unknown origin in adults: 40 years on. *J Intern Med* 253(3):263-275
5. Bijlsma J (2009) EULAR Compendium on rheumatic diseases. BMJ Publishing Group Ltd., London
6. Langford CA (2010) Vasculitis. *J Allergy Clin Immunol* 125(2):S216-S225
7. Salvarani C, Cantini F, Hunder GG (2008) Polymyalgia rheumatica and giant-cell arteritis. *Lancet* 372(9634):234-245
8. Meller J, Sahlmann C-O, Scheel AK (2007) 18F-FDG PET and PET/CT in fever of unknown origin. *J Nucl Med* 48(1):35-45
9. Ferda J, Ferdová E, Záhlava J, Matejovic M, Kreuzberg B (2010) Fever of unknown origin: a value of (18)F-FDG-PET/CT with integrated full diagnostic isotropic CT imaging. *Eur J Radiol* 73(3):518-525
10. Mourad O, Palda V, Detsky AS (2003) A comprehensive evidence-based approach to fever of unknown origin. *Arch Intern Med* 163(5):545-551
11. Brodmann M, Lipp RW, Passath A, Seinost G, Pabst E, Pilger E (2004) The role of 2-18F-fluoro-2-deoxy-D-glucose positron emission tomography in the diagnosis of giant cell arteritis of the temporal arteries. *Rheumatology* 43:241-242
12. Blockmans D, de Ceuninck L, Vanderschueren S, Knockaert D, Mortelmans L, Bobbaers H (2006) Repetitive 18F-fluorodeoxyglucose positron emission tomography in giant cell arteritis: A prospective study of 35 patients. *Arthritis Rheum* 55:131-137
13. Bleeker-Rovers CP, Bredie SJ, van der Meer JW, Corstens FH, Oyen WJ (2003) F-18-fluorodeoxyglucose positron emission tomography in diagnosis and follow-up of patients with different types of vasculitis. *Neth J Med* 61(10):323-329
14. Bural GG, Torigian DA, Chamroonrat W, Houseni M, Chen W, Basu S, Kumar R, Alavi A (2008) FDG-PET is an effective imaging modality to detect and quantify age-related atherosclerosis in large arteries. *Eur J Nucl Med Mol Imaging* 35:562-569
15. Belhocine T, Blockmans D, Hustinx R, Vandevivere J, Mortelmans L (2003) Imaging of large vessel vasculitis with (18)FDG PET: illusion or reality? A critical review of the literature data. *Eur J Nucl Med Mol Imaging* 30(9):1305-1313
16. Hunder GG, Arend WP, Bloch DA, Calabrese LH, Fauci AS, Fries JF, Leavitt RY, Lie JT, Lightfoot RW Jr, Masi AT et al (1990) The American College of Rheumatology 1990 criteria for the classification of vasculitis. Introduction. *Arthritis Rheum* 33(8):1065-1067
17. Jennette JC, Falk RJ, Andrassy K, Bacon PA, Churg J, Gross WL, Hagen EC, Hoffman GS, Hunder GG, Kallenberg CG et al (1994) Nomenclature of systemic vasculitides. Proposal of an international consensus conference. *Arthritis Rheum* 37(2):187-192
18. Ball EL, Walsh SR, Tang TY, Gohil R, Clarke JM (2010) Role of ultrasonography in the diagnosis of temporal arteritis. *Br J Surg* 97(12):1765-1771
19. Bley TA, Reinhard M, Hauenstein C, Markl M, Warnatz K, Hetzel A, Uhl M, Vaith P, Langer M (2008) Comparison of duplex sonography and high-resolution magnetic resonance imaging in the diagnosis of giant cell (temporal) arteritis. *Arthritis Rheum* 58(8):2574-2578
20. Buchbinder R, Detsky AS (1992) Management of suspected giant cell arteritis: a decision analysis. *J Rheumatol* 19(8):1220-1228
21. Brack A, Martinez-Taboada V, Stanson A, Goronzy JJ, Weyand CM (1999) Disease pattern in cranial and large-vessel giant cell arteritis. *Arthritis Rheum* 42(2):311-317

Fig. 1 Whole body integrated PET/CT. Coronal views (panels a and b): increased FDG uptake in the walls of subclavian and proximal brachial arteries (full arrows), as well as carotid arteries (dotted arrows) bilaterally. Sagittal view (panel c): increased FDG uptake in the walls of the ascending, descending and abdominal aorta (full arrows), as well as carotid arteries (dotted arrows)

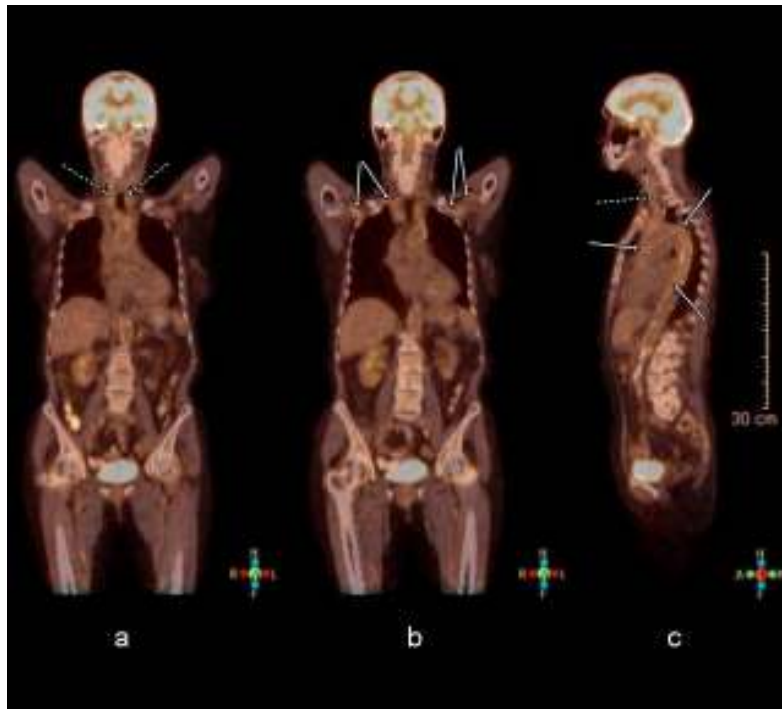

Fig. 2 Transverse section of the superficial temporal artery. (a) Thickening of the vascular wall with granulomatous inflammation (hematoxylin-eosin stain, $\times 100$) (b) Granulomatous inflammation consisting of mononuclear cells and some giant multinuclear cells (hematoxylin-eosin stain, $\times 400$)



Laboratory test	Result
CBC ^a	Microcytic anemia
ESR (mm/h)	90
CRP (mg/L)	121.0
Ferritin (µg/L)	534.3
Coagulation parameters ^b	Normal
Biochemistry ^c	Normal
Urinalysis	Normal
RF ^d	Negative
AST ^e	Negative
ANA, ENA ^f	Negative
ANCA ^g	Negative
Total proteins (g/L)	67.0 (normal)
- Albumin (g/L)	34.7 (↓)
- Globulins (g/L) ^h	32.3 ^h
Thyroid status ⁱ	Normal
Tumor markers ^j	Normal

Table 1. Laboratory test results at the admission to the hospital

^a CBC – complete blood count

^b thrombocytes, prothrombin time and activated partial thromboplastin time

^c aspartate aminotransferase, alanine aminotransferase, alkaline phosphatase, gamma-glutamyl transferase, bilirubin, urea, creatinin, creatine kinase, lactate dehydrogenase, sodium, potassium, calcium, phosphate, urate, glucose and lipids

^d RF – rheumatoid factor

^e AST – antistreptolysin titer

^f ANA – antinuclear antibodies, including indirect immunofluorescence, antibodies to double-stranded DNA (dsDNA), anti-histone antibodies and ENA – antibodies to extractable nuclear antigens (SS-A, SS-B, Sm, U1-RNP, topoisomerase I, centromere and Jo-1);

^g ANCA – anti-neutrophil cytoplasmic antibodies

^h alpha-1 globulin 5.0 g/L (↑), alpha-2 globulin 10.6 g/L (↑), beta globulin 8.2 g/L (normal), gamma globulin 8.5 g/L (normal)

ⁱ T3, T4 and TSH

^j AFP, CEA, CA 125, CA 19-9, CA 15-3, NSE and CYFRA 21-1.