

# Influence of silicone oil tamponade after vitrectomy on intraocular pressure

---

Matić, Suzana; Popović Suić, Smiljka; Biuk, Dubravka; Matić, Mate; Barać, Josip; Vinković, Maja

Source / Izvornik: **Collegium Antropologicum, 2013, 37, 227 - 235**

Journal article, Published version

Rad u časopisu, Objavljena verzija rada (izdavačev PDF)

Permanent link / Trajna poveznica: <https://um.nsk.hr/um:nbn:hr:105:639422>

Rights / Prava: [In copyright](#)/[Zaštićeno autorskim pravom.](#)

Download date / Datum preuzimanja: **2024-09-30**



Repository / Repozitorij:

[Dr Med - University of Zagreb School of Medicine Digital Repository](#)



# Influence of Silicone Oil Tamponade after Vitrectomy on Intraocular Pressure

Suzana Matić<sup>1</sup>, Smiljka Popović Suić<sup>1,2</sup>, Dubravka Biuk<sup>1</sup>, Mate Matić<sup>3</sup>, Josip Barać<sup>1</sup> and Maja Vinković<sup>1</sup>

<sup>1</sup> »J. J. Strossmayer« University, Osijek University Hospital Centre, Department of Ophthalmology, Osijek, Croatia

<sup>2</sup> University of Zagreb, School of Medicine, Zagreb, Croatia

<sup>3</sup> »J. J. Strossmayer« University, Osijek University Hospital Centre, Department of Oncology and Radiotherapy, Osijek, Croatia

## ABSTRACT

*The aim of this prospective study was to determine the possible influence of the silicone oil tamponade after vitrectomy on the early intraocular pressure (IOP) elevation, which is a major risk factor for developing secondary glaucoma in patients with vitreal and retinal proliferative changes. The research included 110 patients which were allocated in three groups according to the medical history data. The surgical procedures were performed at the Eye Clinic, University of Zagreb School of Medicine. The control group comprised 40 patients who underwent vitrectomy with air or saline solution tamponade. The second group consisted of 40 patients with retinal detachment and proliferative retinopathy who had vitrectomy with silicone oil tamponade and the third group were 30 patients with diabetic retinopathy who underwent vitrectomy and tamponade with silicone oil. The intraocular pressure was measured and gonioscopy was performed in all patients one month before and after vitrectomy. The results showed that there is no statistically significant difference among IOP values before and after vitrectomy in the control group ( $p=0.104$ ) as well as in the preoperative IOP values among all three groups of patients. The data analysis determined that in both groups of patients with silicone oil tamponade after vitrectomy, there is a statistically significant difference in IOP values one month after the surgical procedure ( $p=0.000$ ). The mean IOP values in those patients a month after vitrectomy were significantly higher compared to the control group ( $p<0.05$ ). Comparison of the IOP one month after vitrectomy between the patients with retinal detachment and those with diabetic retinopathy showed no statistically significant difference ( $p=0.331$ ) but the qualitative analysis showed that the IOP one month after vitrectomy was 2 mmHg higher in the diabetic retinopathy group. The results suggest that there is no difference in angle width before and after vitrectomy among different groups of patients. Emulsified silicone oil was confirmed in 18% of patients in the retinal detachment group. In 17% of patients in the diabetic retinopathy group the emulsified oil was found in the angle, whereas a 10% of patients had neovascularization of the angle one month after vitrectomy. The IOP elevation in the early postoperative course may be caused by intravitreal instillation of the silicone oil after vitrectomy. Emulsification of the silicone oil may lead to the early IOP rise; especially in the diabetic patients with angle neovascularization which itself can additionally accelerate the development of the secondary glaucoma.*

**Key words:** silicone oil, vitrectomy, intraocular pressure, secondary glaucoma

## Introduction

Pars plana vitrectomy with silicone oil tamponade is a successful method of surgical management of the most difficult cases of proliferative retinopathy<sup>1</sup>. Silicone oil instilled in the vitreous cavity ensures stability of the eye ball, restores the initial intraocular anatomical relations and slows down further proliferation, it is well tolerated and because of its transparency it enables easier postop-

erative visualization of the posterior segment of the eye<sup>2-5</sup>. Apart from the possible development of band keratopathy, corneal decompensation, cataract formation and under oil re-proliferation, one of the major side effects of the silicone oil is secondary intraocular pressure (IOP) elevation<sup>6-14</sup>. The early detection of the IOP elevation as well as its adequate and timely management

contribute to the maintaining of the good postoperative outcome of the vitrectomy and prevent from the progressive and irreversible optic nerve damage and further deterioration of the visual acuity, which are, along with the primary pathological process, aggravated by the IOP elevation. According to the recent studies the IOP elevation after vitrectomy with silicone oil tamponade most frequently occurs in the early postoperative period<sup>15-17</sup> and therefore we have tried to establish if there is a significant difference in the IOP values one month before and after vitrectomy with silicone oil in each group of patients and also to determine its possible influence on the morphology and degree of angle width in each group of patients.

### Patients and Methods

This prospective study was conducted from January 2004 to October 2004 in the Zagreb University Hospital Center, Ophthalmology Clinic, Department of the posterior segment of the eye and vitreoretinal surgery, and involved 110 patients. All patients had vitrectomy with or without silicone oil tamponade.

The patients were divided into three groups according to the medical history data:

1<sup>st</sup> group (40 patients) was the control group, consisting of patients with retinal detachment and diabetic retinopathy who had intravitreal tamponade with saline solution or air.

2<sup>nd</sup> group (40 patients) consisted of patients with retinal detachment with proliferative vitreoretinopathy (PVR) who underwent vitrectomy with silicone oil tamponade.

3<sup>rd</sup> group (30 patients) were patients with advanced proliferative diabetic retinopathy who had vitrectomy with silicone oil tamponade.

Selection criteria for tamponade agents (air, saline solution, or silicone oil) were shape, size and location of retinal hole in retinal detachment and extent of proliferative changes in retinal detachment as well as in diabetic retinopathy.

Exclusion criteria was medical history positive for pre-existing glaucoma regardless of etiology, which was confirmed or excluded after intraocular pressure (IOP) measurement and gonioscopy in each patient prior to vitrectomy.

All patients had complete ophthalmologic examination which included: IOP measurement with applanation tonometry performed one month before and after vitrectomy and gonioscopy one month before and after vitrectomy

### Statistical Analysis

T-test was used to test hypothesis of equal arithmetic mean for two basic sets. ANOVA – analysis of variance was used for testing hypothesis of equal arithmetic mean for more basic sets. Descriptive statistics were employed for description of observed groups, in particular central

tendency measures: MEAN – average value, MEDIAN – middle number in a sorted list of numbers and MOD – the most frequent value. Statistically significant difference was expressed with p value. It represents the probability of error in accepting the thesis that there is a difference and a p value <0.05 represents a statistically significant difference. Statistical analysis was performed with SPSS 12 statistical package.

### Results

Both sexes and wide range of age were equally presented in tested specimens and they were suitable for statistical comparison (Figures 1 and 2).

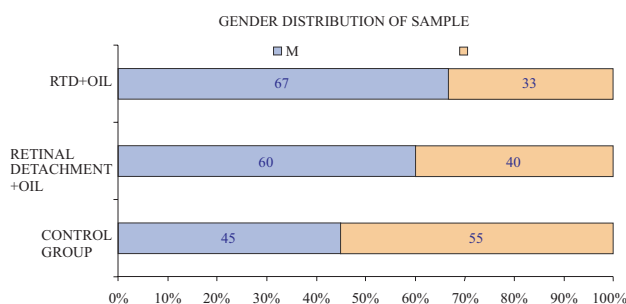


Fig. 1. Demographic gender profile of patients. RTD – diabetic retinopathy, M – men, Z – women.

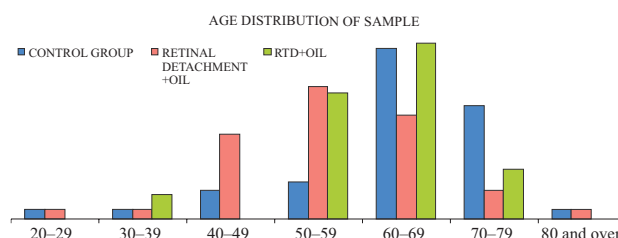


Fig. 2. Demographic profile of patients according to age.

### Comparison of IOP values before and after vitrectomy in each group of patients

A comparison of the IOP values in the control group of patients after vitrectomy with an air tamponade or saline solution tamponade one month before and after the surgical procedure showed that there is no statistically significant difference among IOP values in the control group (p=0.104) (Table 1). The mean IOP value a month before surgery was 13.4 mmHg and one month after the vitrectomy was 13.78 mmHg.

The mean IOP before vitrectomy in patients with retinal detachment was 12.90 mmHg and a mean IOP one month after vitrectomy with silicone oil tamponade was 19.30 mmHg. Comparison of IOP values among these patients showed statistically significant difference in IOP values before and after vitrectomy with silicone oil tamponade (p=0.000) (Table 2).

**TABLE 1**  
IOP VALUES BEFORE AND AFTER VITRECTOMY IN THE CONTROL GROUP

Control group					
	N	$\bar{X}$	Median	Mode	Std. Dev.
Tapl 0	40	13.40	13.50	12	2.085
Tapl 1	40	13.78	14.00	12(a)	2.130

T-Test, Paired Samples Test

Paired Differences									
		$\bar{X}$	Std. Dev.	Std. Error mean	95% Confidence Interval of the Difference		t	df	Sig. (2-tailed)
					Lower	Upper			
Pair 1	Tapl 0 – Tapl 1	-0.375	1.427	0.226	-0.831	0.081	-1.662	39	0.104

**TABLE 2**  
IOP VALUES IN THE RETINAL DETACHMENT GROUP BEFORE AND AFTER VITRECTOMY WITH SILICONE OIL TAMPONADE

Retinal detachment + oil				
	$\bar{X}$	Median	Mode	Std. Dev.
Tapl 0	12.90	12.00	12	3.327
Tapl 1	19.30	16.00	16	8.864

T-Test, Paired Samples Test

Paired Differences									
		$\bar{X}$	Std. Dev.	Std. Error Mean	95% Confidence Interval of the Difference		t	df	Sig. (2-tailed)
					Lower	Upper			
Pair 1	Tapl 0 – Tapl 1	-6.400	8.949	1.415	-9.262	-3.538	-4.523	39	0.000

**TABLE 3**  
IOP VALUES IN THE DIABETIC RETINOPATHY GROUP BEFORE AND AFTER VITRECTOMY WITH SILICONE OIL TAMPONADE

RTD+oil						
	N		$\bar{X}$	Median	Mode	Std. Dev.
	Valid	Missing				
Tapl 0	30	0	13.40	13.00	12	2.253
Tapl 1	30	0	21.33	19.50	14	8.235

Histogram, Paired Samples Test

Paired Differences									
		$\bar{X}$	Std. Deviation	Std. Error Mean	95% Confidence Interval of the Difference		t	df	Sig. (2-tailed)
					Lower	Upper			
Pair 1	Tapl 0 – Tapl 1	-7.933	8.073	1.474	-10.948	-4.919	-5.383	29	0.000

Mean IOP in patients with diabetic retinopathy was 13.40 mmHg a month before vitrectomy and one month after vitrectomy and instillation of silicone oil the value was 21.33 mmHg. Statistically significant difference ( $p=0.000$ ) was determined in IOP values among this group of patients before and after vitrectomy with silicone oil tamponade (Table 3).

*Comparison of IOP values before and after vitrectomy among different groups based on diagnosis*

Analyzing the IOP values between each group of patients regarding the diagnosis which was indication for the vitrectomy, it was determined that there was no statistically significant difference in preoperative IOP val-

**TABLE 4A**  
IOP VALUES BEFORE VITRECTOMY IN THE RETINAL DETACHMENT GROUP AND CONTROL GROUP

Tabl 0

	N	$\bar{X}$	Std. Deviation	Std. Error	95% Confidence Interval for Mean		Minimum	Maximum
					Lower	Upper		
Control group	40	13.40	2.085	0.330	12.73	14.07	9	18
Retinal detachment+oil	40	12.90	3.327	0.526	11.84	13.96	8	24
Total	80	13.15	2.770	0.310	12.53	13.77	8	24

Test of Homogeneity of Variances, Tabl 0

Levene Statistic	Df1	df2	Sig.
6.181	1	78	0.015

ANOVA, Tabl 0

	Sum of Squares	df	$\bar{X}$ Square	F	Sig.
Between Groups	5.000	1	5.000	0.649	0.423
Within Groups	601.200	78	7.708		
Total	606.200	79			

**TABLE 4B**  
IOP VALUES AFTER VITRECTOMY IN THE RETINAL DETACHMENT GROUP WITH SILICONE OIL TAMPONADE AND CONTROL GROUP WITH INSTILLATION OF AIR OR SALINE SOLUTION IN THE VITREOUS CAVITY

TAPL 1

	N	$\bar{X}$	Std. Deviation	Std. Error	95% Confidence Interval for Mean		Minimum	Maximum
					Lower	Upper		
Control group	40	13.78	2.130	0.337	13.09	14.46	10	19
Retinal detachment+oil	40	19.30	8.864	1.402	16.47	22.13	11	52
Total	80	16.54	6.983	0.781	14.98	18.09	10	52

Test of Homogeneity of Variances; Tapl 1

Levene Statistic	Df1	df2	Sig.
16.066	1	78	0.000

ANOVA; Tapl 1

	Sum of Squares	df	$\bar{X}$ Square	F	Sig.
Between Groups	610.513	1	610.513	14.691	0.000
Within Groups	3.241.375	78	41.556		
Total	3.851.888	79			

ues between second and third group of patients as compared with preoperative IOP values in the control group ( $p > 0.05$ , Tables 4a, 5a and 6a).

Comparing the IOP values one month after vitrectomy and silicone oil tamponade in both second and third group of patients there was a statistically significant difference regarding the postoperative IOP values in the control group ( $p < 0.05$ , Tables 4b, 5b and Comparison of

the preoperative and postoperative IOP values in the second (patients with retinal detachment and PVR) and third group (patients with diabetic retinopathy) showed no statistically significant difference in the IOP values ( $p = 0.48$ ,  $p = 0.33$ , Tables 6a and 6b). However, qualitative analysis of the IOP values shows that one month after vitrectomy the IOP value is 2 mmHg higher in the group of patients with diabetic retinopathy.

**TABLE 5A**  
MEAN IOP BEFORE VITRECTOMY IN THE DIABETIC RETINOPATHY GROUP AND CONTROL GROUP

	N	$\bar{X}$	Std. Deviation	Std. Error	95% Confidence Interval for Mean		Minimum	Maximum
					Lower	Upper		
					Control group	40		
Rtd+oil	30	13.40	2.253	0.411	12.56	14.24	10	18
Total	70	13.40	2.143	0.256	12.89	13.91	9	18

Test of Homogeneity of Variances; Tapl 0

Levene Statistic	df1	df2	Sig.
0.276	1	68	0.601

ANOVA; Tapl 0

	Sum of Squares	df	$\bar{X}$ Square	F	Sig.
Between Groups	0.000	1	0.000	0.000	1.000
Within Groups	316.800	68	4.659		
Total	316.800	69			

**TABLE 5B**  
IOP VALUES AFTER VITRECTOMY AND SILICONE OIL TAMPONADE IN THE DIABETIC RETINOPATHY GROUP AND CONTROL GROUP

TAPL 1

	N	$\bar{X}$	Std. Deviation	Std. Error	95% Confidence Interval for Mean		Minimum	Maximum
					Lower	Upper		
					Control group	40		
Rtd+oil	30	21.33	8.235	1.504	18.26	24.41	12	50
Total	70	17.01	6.728	0.804	15.41	18.62	10	50

Test of Homogeneity of Variances; Tapl 1

Levene Statistic	Df1	df2	Sig.
16.378	1	68	0.000

ANOVA; Tapl 1

	Sum of Squares	df	$\bar{X}$ Square	F	Sig.
Between Groups	979.344	1	979.344	31.066	0.000
Within Groups	2.143.642	68	31.524		
Total	3.122.986	69			

**TABLE 6A**  
IOP VALUES BEFORE VITRECTOMY IN THE RETINAL DETACHMENT GROUP AND DIABETIC RETINOPATHY GROUP

Tapl 0

	N	$\bar{X}$	Std. Deviation	Std. Error	95% Confidence Interval for Mean		Minimum	Maximum
					Lower	Upper		
Retinal detachment+oil	40	12.90	3.327	0.526	11.84	13.96	8	24
Rtd+oil	30	13.40	2.253	0.411	12.56	14.24	10	18
Total	70	13.11	2.907	0.347	12.42	13.81	8	24

Test of Homogeneity of Variances; Tapl 0

Levene Statistic	Df1	df2	Sig.
3.377	1	68	0.070

ANOVA; Tapl 0

	Sum of Squares	df	$\bar{X}$ Square	F	Sig.
Between Groups	4.286	1	4.286	0.504	0.480
Within Groups	578.800	68	8.512		
Total	583.086	69			

**TABLE 6B**  
MEAN IOP ONE MONTH AFTER VITRECTOMY IN THE RETINAL DETACHMENT GROUP AND DIABETIC RETINOPATHY GROUP WITH SILICONE OIL TAMPONADE

TAPL 1

	N	$\bar{X}$	Std. Deviation	Std. Error	95% Confidence Interval for Mean		Minimum	Maximum
					Lower	Upper		
Retinal detachment+oil	40	19.30	8.864	1.402	16.47	22.13	11	52
Rtd+oil	30	21.33	8.235	1.504	18.26	24.41	12	50
Total	70	20.17	8.599	1.028	18.12	22.22	11	52

Test of Homogeneity of Variances; Tapl 1

Levene Statistic	df1	df2	Sig.
0.043	1	68	0.837

ANOVA; Tapl 1

	Sum of Squares	df	$\bar{X}$ Square	F	Sig.
Between Groups	70.876	1	70.876	0.958	0.331
Within Groups	5.031.067	68	73.986		
Total	5.101.943	69			

*Analysis of the gonioscopic finding before and after vitrectomy in each group of patients*

There was no significant difference in gonioscopic finding before and after vitrectomy in any group of patients ( $p > 0.05$ ). A qualitative analysis confirmed for each group of patients before and after vitrectomy that there

were not any significant changes in the angle width, and the majority of the examined subjects had grade III and IV according to Shaffer (Figure 4).

In the group of patients with retinal detachment and silicone oil tamponade, 18% had emulsified silicone oil bubbles in the anterior chamber and trabeculum one month after vitrectomy (Figure 5). 7 of 40 patients in this

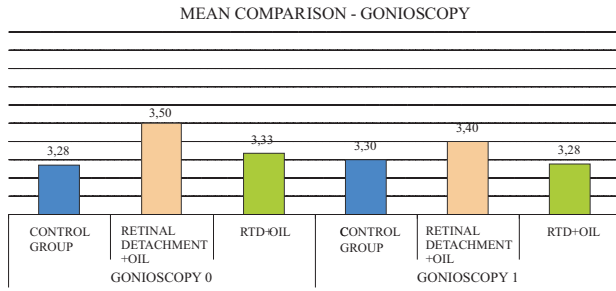


Fig. 4. Gonioscopy before and after vitrectomy for each group of patients.

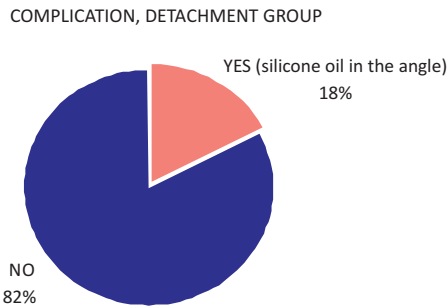


Fig. 5. Emulsification of silicone oil in the retinal detachment group one month after vitrectomy and silicone oil tamponade.

group had emulsified silicone oil. In 6 patients the bubbles were predominantly located in the trabeculum, whereas 1 patient had 3 bubble of silicone oil in the anterior chamber one month after vitrectomy. Only 2 patients had change in the angle width (from Shaffer’s grade IV to II), and all the other patients one month after the vitrectomy had the same grade of angle width as before the surgical procedure. 17% of patients with diabetic retinopathy after vitrectomy with silicone oil tamponade had emulsified silicone oil in the chamber angle (Figure 6).

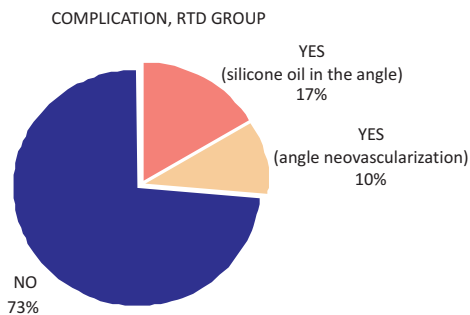


Fig. 6. Gonioscopy finding and angle complication one month after vitrectomy in the diabetic retinopathy group with silicone oil tamponade after vitrectomy.

Qualitative analysis detected bubbles of emulsified silicone oil in the trabecular meshwork in 5 patients. Only one patient had iridotomy block at 6 o’clock position and silicone oil bubbles were found in the trabecular meshwork as well as in the anterior chamber of this patient where the silicone oil bubble filled the entire ante-

rior chamber in the form of »inverse hypopion«. Three patients had initial neovascularization found on gonioscopy one month after vitrectomy which comprises 10% of the examined subjects in this group. Only one patient with diabetic retinopathy had numerous goniosynechiae of the angle one month after the surgery and all the other patients had the same angle width as before the surgical procedure.

## Discussion and Conclusion

Silicone oil as a tamponade agent after pars plana vitrectomy in the early postoperative period may cause IOP elevation in some patients<sup>18</sup>. Patients at risk of developing secondary glaucoma after silicone oil tamponade are diabetics, aphakic patients and those with pre-existing glaucoma. Mechanisms responsible for developing secondary glaucoma are pupillary block due to the obstruction of peripheral iridectomy<sup>19</sup>, emulsified silicone oil bubbles in the chamber angle<sup>20</sup>, angle closure by anterior synechial, inflammation, rubeosis iridis, idiopathic IOP rise after silicone oil instillation as well as the surgeon’s inattention and overfilling of the eye with silicone oil. The most of these cases are well controlled by topical antiglaucoma therapy, whereas the minority of patients require evacuation of the silicone oil to normalize IOP and the most refractory cases mandate penetrating filtration surgery in order to stabilize the IOP in the long term<sup>21</sup>.

IOP rise, which occurs according to some authors in 7 to 48% of cases in the early postoperative period, is due to different course of proliferation and silicone bubble shift towards the lens and iris<sup>15,16</sup>. If, during the vitrectomy, entire pathological substrate is removed from the vitreous cavity, a re-proliferation process will occur under the silicone oil altering the usual anterior – posterior direction and traverses into tangential causing shallow retinal detachments.

The other major issue is propensity of the oil to emulsify, i.e. to create small surrounding bubbles in addition to the existing, larger one. When these bubbles cross the anterior chamber, anterior lens capsule or the anterior iris surface, they may reach the trabeculum. It may lead to an aqueous humour outflow disturbances and consequently IOP rise. The studies report an incidence of the silicone oil emulsification after vitrectomy of 0.7%<sup>22</sup> up to 56%<sup>23</sup>. Although some authors hold that the amount of the emulsified oil in the anterior chamber is not in linear correlation with the IOP elevation<sup>16</sup>, Leaver<sup>22</sup> et al. found silicone oil in 9 out of 14 of the observed patients. He also confirmed the presence of the macrophages filled with silicone within the trabecular meshwork, but lacking the obvious signs of the structural damage to the trabecular collagen fibres.

Our results suggest that the early elevation of the IOP, measured one month after vitrectomy, is equally present in the patients with retinal detachment as well as in patients with diabetic retinopathy. However, a qualitative analysis of the two groups of patients showed



higher IOP elevation in the early postoperative period in the diabetic retinopathy group. The higher IOP values in this group of patients one month after vitrectomy are to a certain extent related with the basic pathological process, diabetes, which owing to retinal ischemia causes neovascularization of the chamber angle, present in 10% of patients and it may also cause a secondary glaucoma. Although we did not find statistically significant difference in the angle width before and after vitrectomy among the observed groups, the finding of the emulsified silicone oil in 18% of patients with retinal detachment and 17% in diabetic retinopathy group may suggest its

possible influence on the early elevation of the IOP values. In conclusion, silicone oil as a tamponade agent after pars plana vitrectomy may cause rise in the IOP values in the early postoperative period in some patients. Therefore the timely detection and appropriate ant glaucomatous treatment is extremely important since every elevation of the IOP may interfere with the positive outcome of the surgical procedure and functional visual outcome. The IOP elevation in the early postoperative course in these challenging patients presents a major risk factor for developing a secondary glaucoma.

## REFERENCE

1. MACHEMER H, BRUETTNER H, NORTON EDW, Ophthalmology, 75 (1971) 813. — 2. SCOTT JD, Trans Ophthalmol Soc UK, 103 (1983) 280. — 3. LAKITS A, NENNADAL T, SCHOLDA C, KNAUS S, GRUBER H, Ophthalmology, 106 (1999) 1091. — 4. PETERSEN J, Graefes Arch Clin Exp Ophthalmol, 225 (1987) 452. — 5. HEIDENKUMMER HP, MES-SMER EM, KAMPIK A, Ophthalmology, 93 (1996) 121. — 6. GUNGEL H, MENCEOGLU Y, YILDIZ B, AKBULUT O, Retina, 25 (2005) 332. — 7. BARTOV E, PENNAROLA F, SAVION N, NAVEN N, TREISTER G, Retina, 12 (1992) 23. — 8. HEIDENKUMMER HP, KAMPIK A, THIER-FELDER S, Retina, 12 (1992) 28. — 9. GABEL VP, KAMPIK A, BURK-HARDT J, Graefes Arch Clin Exp Ophthalmol, 225 (1987) 160. — 10. JO-NAS JB, KNORR HLJ, RANK RM, BUDDER WM, Journal of Glaucoma, 10, (2001) 102. — 11. BUCH H, NIELSEN NV, PRAUSE JU, Acta Ophthalmologica Scandinavica, 77 (1999) 410. — 12. HEIDENKUMMER HP,

KAMPIK A, THIERFELDER S, Graefes Archive for Clinical & Experimental Ophthalmology, 229 (1991) 88. — 13. ABRAMS GW, AZEN SP, MC CUEN BV II, Arch Ophthalmol, 115 (1997) 335. — 14. FREEMAN HM, CATILLEJOS ME, Trans Am J Ophthalmol Soc, 79 (1981) 89. 1981. — 15. LUCKE KH, FOERSTER MH, LAQUA H, Am J Ophthalmol, 104 (1987) 624. — 16. NGUYEN QH, LLOYD MA, HEUER DK, Ophthalmology, 99 (1992) 1520. — 17. STAMPER RL, Highlights of ophthalmology, 30 (2002) 3. — 18. POPOVIĆ SUIĆ S, ŠIKIĆ J, Coll. Antropol, 25 (2001) 117–25. — 19. MADREPERLA SA, MCCUEN BW, Retina, 15 (1995) 87. — 20. LA HELJ EC, HENDRIKSE F, KESSELS AG, Retina, 21 (2001) 107. — 21. AL-JAZAAF A, NETLAND PA, CHARLES S, Journal of Glaucoma, 14 (2005) 40. — 22. LEAVER PK, GREY RHB, GARNER A, Br J Ophthalmol, 63 (1979) 361. — 23. VALPNE J jr, Mc CARTHY M, Ophthalmology, 101 (1994) 1908.

S. Matić

»J. J. Strossmayer« University, Osijek University Hospital Centre, Department of Ophthalmology, Europske Avenije 14–16, 31000 Osijek, Croatia  
e-mail: suzimate72@gmail.com

## TAMPONADA SILIKONSKIM ULJEM I NJEZIN UTJECAJ NA VRIJEDNOSTI INTRAOKULARNOG TLAKA

### SAŽETAK

Cilj i svrha ovog prospektivnog istraživanja bio je utvrditi moguć utjecaj tamponade mrežnice silikonskim uljem nakon kirurškog zahvata vitrektomije na rani porast očnog tlaka kao glavnog rizičnog čimbenika u nastanku sekundarnog glaukoma kod bolesnika s proliferacijskim promjenama mrežnice i staklovine. Ispitivanje je provedeno na 110 bolesnika koji su temeljem anamneze podijeljeni u 3 skupine, a operirani su u razdoblju od siječnja 2004.– listopada 2004. godine na Klinici za očne bolesti Medicinskog fakulteta u Zagrebu. Kontrolnu skupinu kojoj je nakon vitrektomije instaliran zrak ili fiziološka tekućina u oko činilo je 40 bolesnika. Bolesnika s ablacijom i proliferacijskim promjenama mrežnice, kod kojih je nakon vitrektomije instalirano ulje u oko bilo je 40, dok je bolesnika sa dijabetičkom retinopatijom kod kojih je nakon vitrektomije instalirano ulje u oko bilo 30. Svim bolesnicima izmjerene su vrijednosti očnog tlaka prije i mjesec dana nakon vitrektomije metodom aplanacijske tonometrije te se gonioskopskim pregledom prije i mjesec dana nakon vitrektomije analizirala morfologija kuta i eventualne patološke promjene kuta. Rezultati su pokazali da nema statistički značajne razlike u vrijednostima očnog tlaka prije i poslije vitrektomije u kontrolnoj skupini ( $p=0,104$ ), kao ni u prijeoperacijskim vrijednostima očnog tlaka između sve tri skupine bolesnika. Analizom je utvrđeno da u obje skupine bolesnika sa silikonskom tamponadom mrežnice nakon vitrektomije postoji statistički značajna razlika u vrijednostima očnog tlaka mjesec dana nakon operacije ( $p=0,000$ ). Prosječne vrijednosti očnog tlaka kod tih bolesnika mjesec dana nakon operacije bile su statistički značajno veće u odnosu na kontrolnu skupinu ( $p<0,05$ ). Usporedbom očnih tlakova mjesec dana poslije operacije između bolesnika sa ablacijom i bolesnika sa dijabetičkom retinopatijom nije utvrđena statistički značajna razlika ( $p=0,331$ ), ali se kvalitativnom analizom utvrdilo da je očni tlak mjesec

dana poslije vitrektomije za 2 mmHg viši kod bolesnika sa dijabetičkom retinopatijom. Rezultati pokazuju da nema razlike u otvorenosti kuta prije i poslije vitrektomije niti u jednoj skupini. Kod 18% bolesnika sa ablacijom mrežnice potvrđeno je emulzificirano ulje u kutu. U skupini bolesnika sa dijabetičkom retinopatijom, emulzifikacija u kutu je opažena kod 17% bolesnika, dok je kod 10% bolesnika opažen razvoj neovaskularizacija u kutu mjesec dana nakon vitrektomije. Porast tlaka u ranom poslijeoperacijskom razdoblju može biti uzrokovan instalacijom silikonskog ulja u vitrealnu šupljinu nakon vitrektomije. Emulzifikacija silikonskog ulja može utjecati na rani porast očnog tlaka, poglavito u dijabetičara kod kojih se razvijaju i neovaskularizacije u kutu koje mogu dodatno ubrzati razvoj sekundarnog glaukoma.