

Primary malignant fibrous histiocytoma of the spleen: recurrence eight years after splenectomy - report of a case and literature review

Rakić, Mislav; Pogorelić, Zenon; Lambaša, Smiljka; Patrlj, Leonardo; Perko, Zdravko; Rakić, Mladen; Mrklič, Ivana; Jukić, Miro

Source / Izvornik: *Collegium Antropologicum*, 2013, 37, 1007 - 1010

Journal article, Published version

Rad u časopisu, Objavljena verzija rada (izdavačev PDF)

Permanent link / Trajna poveznica: <https://urn.nsk.hr/urn:nbn:hr:105:085399>

Rights / Prava: [In copyright](#) / [Zaštićeno autorskim pravom](#).

Download date / Datum preuzimanja: **2024-09-29**



Repository / Repozitorij:

[Dr Med - University of Zagreb School of Medicine Digital Repository](#)



Primary Malignant Fibrous Histiocytoma of the Spleen: Recurrence Eight Years after Splenectomy – Report of a Case and Literature Review

Mislav Rakić¹, Zenon Pogorelić², Smiljka Lambaša³, Leonardo Patrlj¹, Zdravko Perko⁴, Mladen Rakić⁵, Ivana Mrklič⁶ and Miro Jukić²

¹ University of Zagreb, University Hospital Dubrava, Department of Surgery, Zagreb, Croatia

² University of Split, University Hospital Centre Split, Department of Pediatric Surgery, Split, Croatia

³ University of Zagreb, University Hospital Dubrava, Department of Pathology, Zagreb, Croatia

⁴ University of Split, University Hospital Centre Split, Department of Surgery, Split, Croatia

⁵ University of Split, University Hospital Centre Split, Department of Anesthesiology, Split, Croatia

⁶ University of Split, University Hospital Centre Split, Department of Pathology, Split, Croatia

ABSTRACT

Primary intraabdominal malignant mesenchymal tumors are very rare. There are just few cases of intraabdominal visceral malignant fibrous histiocytoma in the literature. We report a case of primary malignant fibrous histiocytoma of the spleen in a 57-year-old man, with a recurrence eight years after the splenectomy. After the initial surgery the patient was without complaints, and refused to receive chemotherapy or radiotherapy. Eight years after the surgery the patient reported due to general weakness and malaise when the diagnosis of disease relapse was established. Radical surgery was performed although the tumor involved large curvature of the stomach, left crus of the diaphragm, splenic flexure of the colon and tail of pancreas. Four months after the surgery patient died. To the best of our knowledge, to date, only 18 cases have been reported in the literature, describing malignant fibrous histiocytoma of the spleen.

Key words: malignant fibrous histiocytoma, sarcoma, spleen, surgery

Introduction

Malignant fibrous histiocytoma (MFH) is distinct and pleomorphic form of sarcoma which was originally described by Ozellio 1963¹ and was established by O'Brien and Stout 1964². It usually affects soft tissue, especially the extremities and retroperitoneum². MFH can be found in heart³, brain⁴, bones⁵, larynx⁶, lung⁷, kidney⁸, breast⁹, eye¹⁰, spermatic cord¹¹, and even aorta¹². Case with multiple synchronous primary sites of myxoid MFH has also been described¹³. It most commonly occurs in the fifth to seventh decade of life, but can be found even in the children^{4,14}. About 30–40% of patients with MFH develop distant metastases, with the most common site being the lung¹³. Metastatic disease in the absence of lung metastases is highly unusual¹³.

Primary intra-abdominal MFH is a very rare disease, and few cases are reported in English literature^{14–34}.

Splenic location is very rare according to the few case reports, which have been published. Since the first description of MFH of the spleen by Govoni et al. only 18 cases have been reported in the literature^{14–31}.

Because it is such a rare tumor, little is known about the optimal therapy. Here we report a case of local recurrence of the MFH of the spleen, eight years after the splenectomy, treated with radical surgery.

Case Report

A 57-year-old man was referred to the hospital because of anorexia associated with a weight loss of 10 kg, abdominal pain, weakness and dizziness. Eight years before splenectomy was performed in the local hospital be-

cause of tumor of the spleen. At that time pathohistological diagnosis was based on haematoxylin-eosin staining only and finding was consistent with leiomyosarcoma. After the splenectomy the patient was without complaints and refused to receive chemotherapy or radiotherapy. On physical examination, weak, poorly nourished, in mild distress, afebrile and his vital signs were all well within normal limits. Abdomen was soft, non-tender and painful in left upper quadrant. Bowel sounds were presented. Microcytic anemia was found in blood analysis (erythrocyte: $2.22 \times 10^{12}/L$, normal range: $4.4\text{--}5.7 \times 10^{12}/L$; hemoglobin: 52 mmol/L, normal range: 138–175 mmol/L; hematocrit 0.163 L/L, normal range: 0.415–0.530 L/L; MCV: 73.2 fL, normal range: 86–100 fL). Serum levels of carcinoembryonic antigen (CEA), alpha-fetoprotein (AFP) and carbohydrate antigen 19–9 (CA 19–9) were within normal limits. Gastroduodenoscopy was performed and showed rigid tumor on the large curvature of the stomach. Multislice computed tomography of abdomen showed a large solitary tumor (15 cm x 11 cm) in the left upper abdomen, relating to large curvature of the stomach, left crus of the diaphragm, splenic flexure of colon and pancreatic tail (Fig. 1a). None of the imaging examinations showed findings in the lungs, liver or retroperitoneum.

At laparotomy a large solitary mass (20 cm in the diameter) in the left upper abdomen was noted, relating to an upper part of a large curvature of the stomach, left crus of the diaphragm, splenic flexure of colon and pancreatic tail. Macroscopically there were no intra-abdomi-

nal metastasis and un-block resection of the tumor was performed (Fig. 1b). Gastrectomy, partial resection of the left crus of diaphragm, distal pancreatectomy and left hemicolectomy were performed.

Gross examination revealed solid, gray-white firm tumor, measuring 20 cm x 18 cm x 11 cm. Microscopically the tumor was composed of spindle cells arranged in short cellular fascicles showing a storiform pattern with occasional giant multinucleated cells. The mitotic rate was moderate. Chronic inflammatory cells were scattered sparsely throughout the tumor (Fig. 1c). Immunohistochemically tumor cells expressed CD68 (Fig. 1d) and were negative for desmin, SMA, EMA, CD117 and S-100. In summary, the diagnosis of malignant fibrous histiocytoma was made. Paraffin embedded tissue blocks obtained on the previous operation were reexamined and identical morphological and antigenic characteristics were confirmed. Finding was in accordance with diagnosis of MFH, storiform-pleomorphic subtype. During the early postoperative period patient had a left subphrenic abscess which was treated by several ultrasound guided punctions. After seven weeks of hospitalization patient was discharged in good condition. For months after the surgery the patient died.

Discussion

Malignant fibrous histiocytoma is a sarcoma of mesenchymal origin, accounts over 30% of all soft tissue sarcomas^{13,35,36}. The major locations of MFH are the deep

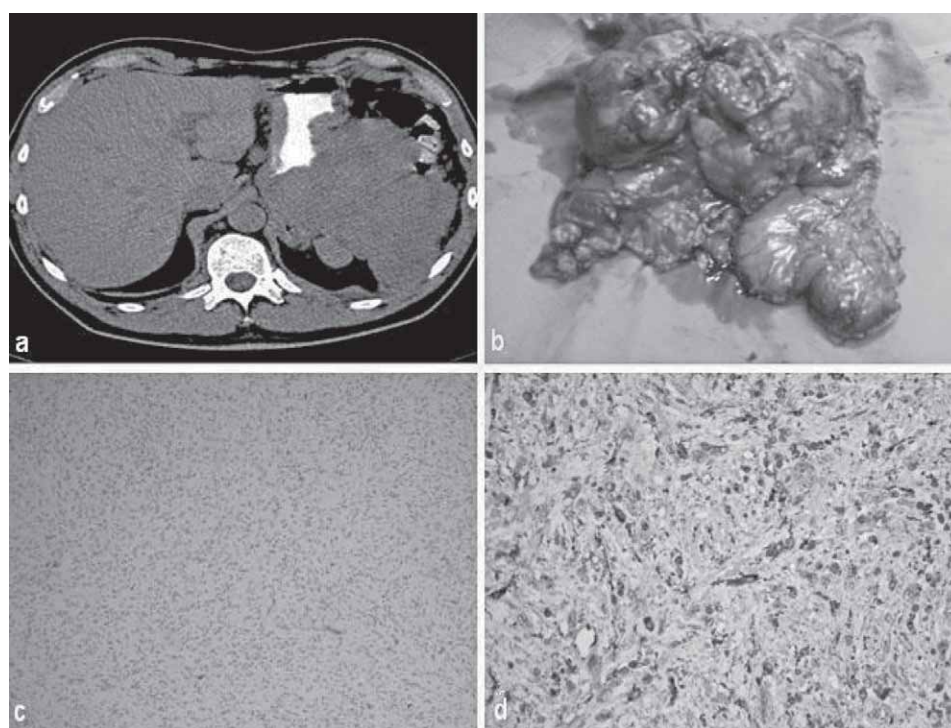


Fig. 1. (a) Abdominal CT: large solitary tumor in the left upper abdomen. (b) Un-block resection of the tumor. (c) Pathological findings: tumor is composed of spindle cells arranged in short fascicles and pleomorphic multinuclear cells. Chronic inflammatory cells are scattered throughout tumor (HEx100). (d) Tumor cells retain immunoreactive for CD68 antibody (IHCx400).

tissue of the extremities, trunk and retroperitoneum^{2,11,16,21}. It very rarely affects intraperitoneal organs^{11,13–35}. Men are affected more frequently than women^{14,6,35}. The incidence of MFH increases with age, with the majority of patients being over 50 years of age^{13,14,35}. The local recurrence rate for MFH is 28–51%^{13,37,38}. The rate of distant metastasis varies from 30 to 46%^{37,38}. The most common site of distant metastasis was by far the lung (63–91%), followed by lymph nodes (10%) and bone (3–8%), taken as a proportion of all metastatic sites^{13,37,38}.

A number of prognostic factors have been examined in terms of their predictive significance for overall survival and recurrence in MFH by various investigators, in an attempt to better define different prognostic variables in this diverse group of soft tissue sarcomas. The mode of presentation of MFH depends on the primary site of the body affected by the tumor. The final diagnosis is based on the pathohistological examination which rely on several criteria, such as presence of typical spindle and polygonal cells arranged in a storiform pattern, multinucleated giant cells^{39,40} and immunohistochemical reactivity^{41,42}. There are five subtypes of MFH according to histology: storiform-pleomorphic, myxoid, giant cell, inflammatory, angiomatoid³⁶. MFH is an aggressive tumor (giant cell has the worst prognosis) with a high potential of metastasis to the other parts of the body, especially to the lung, approximately 2/3 of the patients develop lung metastasis^{36,37}. Factors that are believed to favorably influence recurrence rates and metastasis in myxoid MFH include: small size, superficial location, increased proportion of the myxoid component and low grade^{13,36–38}.

Advances in various techniques of chromosomal analysis have prompted many investigators to try and define MFH on a more basic molecular level. Several candidate genes implicated in the pathogenesis of MFH have been recently identified^{43–47}.

All reports support the thought that MFH indeed is a very rare tumor and might not be the most common soft tissue sarcoma. Intra-abdominal localization is very rare. This is supported by only 18 cases of MFH of the spleen, which have been reported in the world literature as far as we know^{14–31}. They included 10 men and 8 women. Pa-

tients' ages range s from 11 to 82 years, predominantly in the fourth or fifth decade of life. All tumors were located in spleen. Two patients had another tumor located in liver^{16,22}. One patient had a chronic myelogenous leukemia; the neoplasms were synchronous in their onset and evolution²¹. All tumors were large with an average diameter of 12 cm. The presenting symptoms are usually nonspecific, such as general fatigue, weight loss, fever, and abdominal pain. Spontaneous rupture of the tumor within spleen has been reported in one case³¹. The most common histologic subtype are inflammatory and pleomorphic subtype. All patients were treated by surgery, excluding one autopsy case²⁴. Because it is very rare condition survival rate is unknown, there are reports from 6 to 34 months, and only difference is in our case, where the patient died 100 months after the surgery.

The treatment for MFH is early and radical surgical excision with resection of regional lymph nodes³⁵. Despite radical excision of the tumor with free resection margins recurrence of the tumor or metastasis are not uncommon, especially with high grade tumor³⁶. Local recurrence is mainly dependent on the quality of surgical margins, this is most important factor for a metastasis-free and overall survival. Treatment for metastatic disease or recurrence of MFH is also surgical where it is possible⁴⁸. The effectiveness of adjuvant chemotherapy remains unclear. Some studies suggest that there is no improvement of chemotherapy or adjuvant radiotherapy in overall survival of the MFH patients⁴⁹. This patient did not receive any adjuvant therapy, and after surgery had survival period of 100 months.

Conclusion

Primary MFH of the spleen are extremely rare so there are no adequate data base for making a evidence based treating protocol. Despite this problem we recommend a radical surgical resection with a radical regional lymphadenectomy. In case of metastases, adjuvant chemotherapy can be considered in selected cases, but whether adjuvant therapy in this neoplasm is necessary or useful remains unclear.

REFERENCES

- OZZELLO L, STOUT AP, MURRAY MR, Cancer, 16 (1963) 331. DOI: 10.1002/1097-0142(196303)16:3<331::AID-CNCR2820160307>3.0.CO;2-F — 2. O'BRIEN JE, STOUT AP, Cancer, 17 (1964) 1445. DOI: 10.1002/1097-0142(196411)17:11<1445::AID-CNCR2820171112>3.0.CO;2-G — 3. INOUE H, IGURO Y, MATSUMOTO H, UENO M, HIGASHI A, SAKATA R, Surg Today, 39 (2009) 710. DOI: 10.1007/s00595-008-3920-6 — 4. FUJIMOURA N, SUGITA Y, HIROHATA M, NAOHISA M, TERASAKI M, TOKUTMI T, SHIGEMORI M, Paediatric Neurosurgery Basel, 37 (2002) 271. DOI: 10.1159/000066211 — 5. DEMIRALP B, ERLER K, OZTURAN EK, BEK D, OZDEMIR T, KURT B, J Am Podiatr Med Assoc, 97 (2007) 218. — 6. ANGHELINA F, IONITĂ E, CHIUTU L, MOGOANTĂ CA, CIOLOFAN S, IOSIF C, CEAUSU M, Rom J Morphol Embryol, 50 (2009) 481. — 7. MAEDA J, OHTA M, INOUE M, OKUMURA M, MINAMI M, SHIONO H, MATSUDA H, Surg Today, 37 (2007) 316. DOI: 10.1007/s00595-006-3369-4 — 8. SINGH SK, MANDAL AK, AGARWAL MM, DAS A, Int J Urol, 13 (2006) 1000. DOI: 10.1111/j.1442-2042.2006.01458.x — 9. AJISAKA H, MAEDA K, UCHIYAMA A, MIWA A, Surg Today, 32 (2002) 887. DOI: 10.1007/s005950200173 — 10. DIAS AC, PEREIRA LDE S, SAMESHIMA LM, REIS FA, VITAL FILHO J, Arq Bras Oftalmol, 72 (2009) 109. — 11. MARTÍN MARTÍN S, MÜLLER ARTEAGA C, GARCÍA LAGARTO E, SANZ RUIZ A, RIVERO MARTÍNEZ MD, FERNÁNDEZ DEL BUSTO E, Actas Urol Esp, 32 (2008) 745. — 12. RIEBELING V, LINNÉ R, BÜCKMANN FW, MARKGRAF R, WALTHER OE, SCHOLTEN T, Dtsch Med Wochenschr, 117 (1992) 216. DOI: 10.1055/s-2008-1062301 — 13. MULDER JH, PAULINO AF, ROULSTON D, BAKER LH, Sarcoma, 6 (2002) 51. DOI:10.1080/13577140220127567 — 14. YU JW, LAW KL, CHI CS, CHANG MC, HO WL, Zhonghua Yi Xue Za Zhi, 44 (1989) 271. — 15. GOVONI E, BAZZOCCHI F, PILERI S, MARTINELLI G, Histopathology, 6 (1982) 351. DOI: 10.1111/j.1365-2559.1982.tb02729.x — 16. COLOVIC N, CEMERIKIC-MARTINOVIC V, COLOVIC

- R, ZOGOVIĆ S, Medical Oncology, 184 (2001) 293. DOI: 10.1385/MO:18:4:293 — 17. YUAN JP, ZHAO B, LIN YX, YANG YH, Zhonghua Bing Li Xue Za Zhi, 35 (2006) 768. — 18. KATSUURA Y, ISHIDA H, KOMATSUDA T, FURUKAWA K, YAGISAWA H, YAMADA M, OHNO H, KOTANAGI H, MIYAUCHI T, SAITOH K, Abdom Imaging, 31 (2006) 453. DOI: 10.1007/s00261-005-0397-2 — 19. OZARAS R, MERT A, AVSAR S, MELIKOĞLU S, YILMAZ MH, OZDEN E, DERVISOĞLU S, SARIYAR M, Intern Med, 42 (2003) 1054. DOI: 10.2169/internalmedicine.42.1054 — 20. MALLIPUDI BV, CHAWDHERRY MZ, JEFFERY PJ, Eur J Surg Oncol, 24 (1998) 448. DOI: 10.1016/S0748-7983(98)92558-6 — 21. BONILLA F, PROVENCIO M, FERNANDEZ E, ESPAÑA P, Oncology, 51 (1994) 465. DOI: 10.1159/000227384 — 22. LIEU PK, HO J, NG HS, Ann Acad Med Singapore, 22 (1993) 390. — 23. SIEBER SC, LOPEZ V, ROSAI J, BUCKLEY PJ, Am J Surg Pathol, 14 (1990) 1061. DOI: 10.1097/0000478-199011000-00007 — 24. JINNO K, MORIWAKI S, Gan No Rinsho, 33 (1987) 736. — 25. WICK MR, SMITH SL, SCHEITHAUER BW, BEART RW, Am J Surg Pathol, 6 (1982) 229. DOI: 10.1097/0000478-198204000-00005 — 26. BRUNETON J, DRONILLARD J, ROGOPOULOS A, LAURENT F, Gastrointest Radiol, 13 (1988) 299. — 27. MOLONEY M, O'KELLY O, HENNESSY T, MCCARTHY D, WALLIS F, GUPTA R, Lancet Oncol, 5 (2004) 693. DOI: 10.1016/S1470-2045(04)01612-2 — 28. FENG JF, LIU H, LIU J, J Res Med Sci, 16 (2011) 963. — 29. HASHMI A, PODGAETZ E, RICHARDS ML, JSLs, 14 (2010) 426. — 30. MANTAS D, KARIDIS N, PAPACHRISTODOULOU A, Acta Chir Belg, 110 (2010) 558. — 31. HE L, ZHANG H, LI X, ZHOU J, DONG M, Med Oncol, 28 (2011) 397. DOI: 10.1007/s12032-010-9458-7 — 32. WADA Y, MATSUSHITA T, SARUMARU S, RYO J, ISOBE H, SATOH B, KANAYA S, KATAYAMA T, OHTOSHI M, Surg Today, 28 (1998) 296. DOI: 10.1007/s005950050125 — 33. KOTAN C, KOSEM M, ALICI S, ILHAN M, TUNCER I, HARMAN M, Surg Today, 32 (2002) 1091. DOI: 10.1007/s005950200221 — 34. KATO T, KOJIMA T, SHIMIZU T, SASAKI H, ABE M, OKUSHIBA S, KONDO S, KATO H, SATO H, Surg Today, 32 (2002) 81. DOI: 10.1007/s595-002-8121-z — 35. BOSMANS B, DE GRAAF EJR, TORENBEK R, TETTEROO GWM, Int J Colorectal Dis, 22 (2007) 549. DOI: 10.1007/s00384-006-0162-1 — 36. STERNHEIM A, JIN X, SHMOOKLER B, JELINEK J, MALAWER MM, Ann Surg Oncol, 15 (2008) 345. DOI: 10.1245/s10434-007-9637-8 — 37. LE DOUSSAL V, COINDRE JM, LEROUX A, HACE-NE K, TERRIER P, BUI NB, BONICHON F, COLLIN F, MANDARD AM, CONTESSO G, Cancer, 77 (1996) 1823. DOI: 10.1002/(SICI)1097-0142(19960501)77:9<1823::AID-CNCR10>3.3.CO;2-L — 38. GIBBS JF, HUANG PP, LEE JR, MCGRATH B, BROOKS J, MCKINLEY B, DRISCOLL D, KRAYBILL WG, Cancer Invest, 19 (2001) 23. DOI: 10.1081/CNV-100000071 — 39. TOS AP, Histopathology, 48 (2006) 51. DOI: 10.1111/j.1365-2559.2005.02289.x — 40. SCAPOLAN M, PERIN T, WASSERMANN B, CANZONIERI V, COLOMBATTI A, ITALIA F, SPESSOTTO P, Eur J Cancer, 44 (2008) 298. DOI: 10.1016/j.ejca.2007.10.012 — 41. ANAGNOSTOPOULOS G, SAKORAFAS GH, GRIGORIADIS K, KOSTOPOULOS P, Mt Sinai J Med, 72 (2005) 50. — 42. DE JONG ASH, VAN KESSEL-VAN MARK M, ALBUS LUTTER CE, Hum Pathol, 18 (1987) 298. DOI: 10.1016/S0046-8177(87)80013-8 — 43. SAKABE T, SHINOMIYA T, MORI T, ARIYAMA Y, FUKUDA Y, FUJIWARA T, NAKAMURA Y, INAZAWA J, Cancer Res, 59 (1999) 511. — 44. CHIBON F, MAIRAL A, FRENEAUZ P, TERRIER P, COINDRE JM, SASTRE X, AURIAS A, Cancer Res, 60 (2000) 6339. — 45. SIMONS A, SCHEPENS M, JEUKEN J, SPRENGER S, VAN DE ZANDE G, BJERKEHAGEN B, FORUS A, WEIBOLT V, MOLENAAR I, VAN DEN BERG E, MYKLEBOST O, BRIDGE J, VAN KESSEL AG, SUIJKERBUIJK R, Cancer Genet Cytogenet, 118 (2000) 89. DOI: 10.1016/S0165-4608(99)00178-8 — 46. MARTIGNETTI JA, GELB BD, PIERCE H, PICCI P, DESNICK RJ, Genes Chromosomes Cancer, 27 (2000) 191. DOI: 10.1002/(SICI)1098-2264(200002)27:2<191::AID-GCC11>3.3.CO;2-C — 47. CHIBON F, MARIANI O, DERRÉ J, MAIRAL A, COINDRE JM, GUILLLOU L, SASTRE X, PÉDEUTOUR F, AURIAS A, Genes Chromosomes Cancer, 40 (2004) 32. DOI: 10.1002/gcc.20012 — 48. HO MM, HOWARD TJ, LILLEMÖE KD, J Gastrointest Surg, 9 (2005) 934. DOI: 10.1016/j.gassur.2005.04.014 — 49. WILSON RE, WOOD WC, LERNER HL, ANTMAN K, AMATO D, CORSON JM, PROPPE K, HARMON D, CAREY R, GREENBERGER J, Arch Surg, 121 (1986) 1354. DOI: 10.1001/archsurg.121.11.1354.

Z. Pogorelić

Department of Pediatric Surgery, Split University Hospital Centre, Spinčićeva 1, 21000 Split, Croatia
e-mail: zenon@vip.hr

PRIMARNI MALIGNI FIBROZNI HISTIOCITOM SLEZENE RECIDIV OSAM GODINA NAKON SPLENEKTOMIJE

SAŽETAK

Primarni intraabdominalni mezenhimski tumori su vrlo rijetki. U literaturi postoji svega nekoliko opisanih slučajeva malignog fibroznog histiocitoma koji zahvaća visceralne intraabdominalne organe. Prikazujemo slučaj 57-godišnjeg bolesnika sa primarnim malignim fibroznim histiocitomom slezene, te recidivom 8 godina nakon splenektomije. Nakon primarne operacije bolesnik se dobro osjećao, bio je bez tegoba, te je odbio primati kemoterapiju i radioterapiju. Osam godina nakon operacije bolesnik se javio liječniku zbog opće slabosti i malaksalosti te mu je dijagnostičkom obradom utvrđen recidiv bolesti. Učinjen je radikalni operacijski zahvat iako je proces zahvatio veliku krivinu želuca, lijevi dio ošita, lijenalnu fleksuru debelog crijeva i rep gušterače. Četiri mjeseca nakon operacije bolesnik je umro. Prema našim saznanjima, do danas je u literaturi objavljeno samo 18 slučajeva koji opisuju maligni fibrozni histiocitom slezene.