

# Cardiac arrest in a patient with Ebstein's anomaly without accessory pathways

---

**Pezo Nikolić, Borka; Lovrić, Daniel; Puljević, Davor; Miličić, Davor; Buljević, Bruno; Skorić, Boško; Šeparović Hanževački, Jadranka**

*Source / Izvornik:* **Collegium Antropologicum, 2013, 37, 1357 - 1359**

**Journal article, Published version**

**Rad u časopisu, Objavljena verzija rada (izdavačev PDF)**

*Permanent link / Trajna poveznica:* <https://um.nsk.hr/um:nbn:hr:105:362578>

*Rights / Prava:* [In copyright](#) / [Zaštićeno autorskim pravom.](#)

*Download date / Datum preuzimanja:* **2024-05-12**



*Repository / Repozitorij:*

[Dr Med - University of Zagreb School of Medicine  
Digital Repository](#)



# Cardiac Arrest in a Patient with Ebstein's Anomaly without Accessory Pathways

Borka Pezo Nikolić, Daniel Lovrić, Davor Puljević, Davor Miličić, Bruno Buljević, Boško Skorić and Jadranka Šeparović Hanževački

University of Zagreb, School of Medicine, University Hospital Centre Zagreb, Department for Cardiovascular Diseases, Zagreb, Croatia

## ABSTRACT

*We describe a case report of a patient with cardiac arrest and Ebstein's anomaly. This case report shows us necessity for arrhythmia evaluation and sudden death risk stratification even in asymptomatic patients. Prophylactic ICD implantation in this patient population is limited to observational studies and the selection of patients is impeded by the absence of randomized trials and weak predictors.*

**Key words:** Ebstein anomaly, ventricular fibrillation, cardiac arrest, implantable cardiac defibrillator

## Introduction

Ebstein's anomaly (EA) is a rare congenital heart disorder accounting for <1% of all congenital heart defects. It is characterized by apical displacement of the septal and posterior tricuspid valve leaflets, leading to atrialization of the right ventricle with a variable degree of malformation and displacement of the anterior leaflet. The abnormal development of the tricuspid valve in patients with Ebstein's anomaly results in several activation abnormalities including delayed intraatrial conduction, right bundle branch block (RBBB), and ventricular preexcitation<sup>1</sup>.

## Case Report

26 years old woman was brought to the emergency department (ED) in a state of extreme cyanosis without measurable blood pressure or signs of spontaneous breathing. Upon arrival in the ED ventricular fibrillation was registered and the patient was defibrillated to sinus rhythm at the first attempt. After restoring sinus rhythm ECG revealed right bundle branch block (RBBB) without other pathological findings. The patient was intubated and endovenous access was established. The ED staff was informed that she has had pulseless arrest for more than 10 minutes before admittance and she was admitted to the coronary care unit.

Sixty minutes upon resuscitation, moderate hypothermia was initiated. The goal temperature of 33 °C was achieved within 4 hours and hypothermia was maintained for 18 hours. Rewarming of the patient occurred subsequently during 24-hour period, without adverse events. After rewarming she was breathing spontaneously without overt signs of neurological damage. The brain CT scan was normal. Her sister explained that she was diagnosed with EA in her childhood, but there was no history of syncope or palpitations. She was clinically asymptomatic, in New York Heart Association (NYHA) class I, with regular follow up performed by her cardiologist. Echocardiography exams were performed every two years.

Transthoracic echocardiography exam was performed and showed neither pericardial effusion, nor left ventricular (LV) hypertrophy or left ventricular segmental wall motion abnormalities. The LV ejection fraction was normal. A typical echocardiographic finding for EA was present comprising of massively dilated right heart chambers, malposition of the anterior and septal tricuspid valve leaflets, »atrialization« of the right ventricle and mild tricuspid regurgitation (Figure 1). Cardiac MRI with a Magnetom 3T (Siemens AG, Munich, Germany) was performed without any pathological findings outside of the presence of EA.

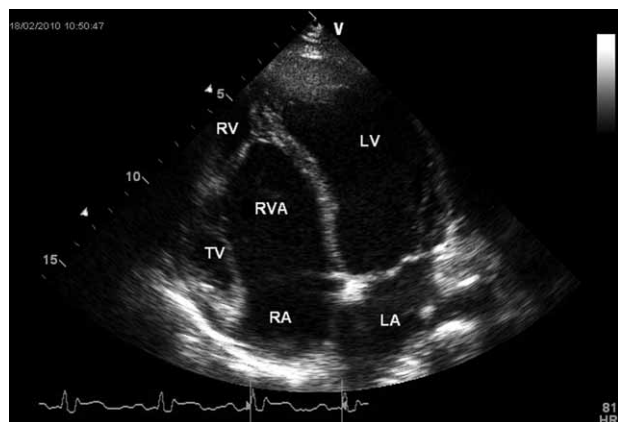


Fig. 1. Example of an echocardiogram (apical 4-chamber view) of a patient with Ebstein's anomaly. The functional RV is small, replaced by the large RVA. RV – right ventricle; RVA – atrialized right ventricle; TV – tricuspid valve; LA – left atrium; LV – left ventricle; RA – right atrium.

The patient underwent electrophysiology study with catheters placed in the high right atrium, the bundle of His, right ventricular apex, and in the left atrium via patent foramen ovale. The baseline intervals were normal: AH 90 ms and HV 50 ms. A dual AV-physiology was present. The electrophysiology study showed no evidence of accessory pathway. Also, no ventricular tachycardia was induced by programmed ventricular stimulation using Wellens protocol before and after isoproterenol administration.

Implantation of implantable cardioverter defibrillator was performed to provide secondary prevention and patient was released from the hospital.

## Discussion

We are reporting a case of cardiac arrest with a documented ventricular fibrillation in a female patient with EA. There is an emerging question about the etiology and the nature of the arrest in our patient. The assessment and diagnostic workup did not reveal any abnormality that could be brought in connection with the event. Theoretically, the arrest could be the consequence

of 1) a ventricular tachycardia that degenerated to ventricular fibrillation, 2) primary ventricular fibrillation, 3) a bradycardia that elicited secondary tachyarrhythmia, or 4) some non-cardiac cause. All possible reasons have been described in the literature in a variety of patients. In most cases an arrhythmic death was assumed. Even more, in one cohort of patients that underwent surgical correction of the anomaly the majority suffered sudden cardiac death<sup>2</sup>.

Presumably, tachyarrhythmias are the most frequent cause of death in such patients. Due to the developmental changes that displace the leaflets, the fibrous tissue in trigonum fibrosum can also be changed. It is well known that patients with Ebstein's anomaly commonly even have multiple accessory pathways. One third of patients with Ebstein's anomaly and symptomatic tachyarrhythmias have minimal or absent ECG features of ventricular preexcitation. In these patients, the absence of RBBB pattern is a strong predictor of an AP. It is also known that most of them having RBBB do not have accessory pathway. In accordance with that, our reported patient had RBBB and no evidence of accessory pathway in electrophysiological study. In a small number of patients ventricular tachycardia was reported<sup>3</sup>.

There are also case reports in the literature with patients in whom bradyarrhythmias were detected, especially atrial standstill. Although ventricular tachycardia / ventricular fibrillation is not often in EA patient comparing with other congenital heart defects, this case report shows the necessity for arrhythmia evaluation and sudden death risk stratification even in asymptomatic patients<sup>4</sup>. Current experience with implantable cardioverter defibrillators in this patient population is limited to observational studies and the selection of patients for prophylactic implantable cardioverter defibrillator implantation is impeded both by the absence of randomized trials and weak predictors. Catheter ablation of ventricular tachycardia has emerged as a promising therapy for abolishing or reducing the burden of arrhythmia but experience is still limited and the impact on long-term outcome uncertain. Future studies will have to focus on improving risk stratification of patients with congenital heart disease<sup>5</sup>.

## REFERENCES

1. ITURRALDE P, NAVA S, SÁLICA G, MEDEIROS A, MARQUEZ MF, COLIN L, VICTORIA D, DE MICHELI A, GONZALES MD. J Cardiovasc Electrophysiol, 17 (2006) 1332. DOI: 10.1111/j.1540-8167.2006.00617.x. — 2. HUANG CJ, CHIU IS, LIN FY, CHEN WJ, LIN JL, LO HM, WU MH, CHU SH, Thorac Cardiovasc Surg, 48 (2000) 347. DOI: 10.

1055/s-2000-8348. — 3. OBIOHA-NGWU O, MILLIEZ P, RICHARDSON A, PITTARO M, JOSEPHSON ME, Circulation, 30 (2001) 104. DOI: 10.1161/hc4301.098011. — 4. WALSH EP, Circulation, 115 (2007) 3224. DOI: 10.1161/. — 5. YAP SC, HARRIS L, Expert Rev Cardiovasc Ther, 7 (2009) 1605. DOI: 10.1586/erc.09.153.

B. Pezo Nikolić

University of Zagreb, School of Medicine, University Hospital Centre Zagreb, Department for Cardiovascular Diseases, Kišpatićeva 12, Zagreb 10000, Croatia  
e-mail: borkapezo@yahoo.com

## **SRČANI AREST KOD BOLESNICE S EBSTEINOVOM ANOMALIJOM**

### **S A Ž E T A K**

Opisali smo slučaj srčanog aresta kod bolesnice s Ebsteinovom anomalijom. Ovaj slučaj nam ukazuje na nužnost evaluacije aritmija te stratifikacije rizika iznenadne srčane smrti čak i kod asimptomatskih pacijenata. U skupini ovakvih bolesnika profilaktička ugradnja ICD-a ograničena je samo na opservacijske studije dok je izbor bolesnika otežan zbog nedostatka randomiziranih istraživanja te nedovoljno definiranih predskazatelja rizika.

