

Leiomyosarcoma of the spermatic cord with scalp metastasis: case report and literature review

Šoipi, Šoip; Vučić, Majda; Ulamec, Monika; Tomas, Davor; Krušlin, Božo; Spajić, Borislav

Source / Izvornik: **Collegium Antropologicum, 2014, 38, 763 - 766**

Journal article, Published version

Rad u časopisu, Objavljena verzija rada (izdavačev PDF)

Permanent link / Trajna poveznica: <https://um.nsk.hr/um:nbn:hr:105:395245>

Rights / Prava: [In copyright](#)/[Zaštićeno autorskim pravom.](#)

Download date / Datum preuzimanja: **2025-04-01**



Repository / Repozitorij:

[Dr Med - University of Zagreb School of Medicine
Digital Repository](#)



Leiomyosarcoma of the Spermatic Cord with Scalp Metastasis: Case Report and Literature Review

Šoip Šoipi¹, Majda Vučić^{2,3}, Monika Ulamec^{2,3}, Davor Tomas^{2,3}, Božo Krušlin^{2,3} and Borislav Spajić^{1,3}

¹ University of Zagreb, University Hospital Centre »Sestre Milosrdnice«, Department of Urology, Zagreb, Croatia

² University of Zagreb, University Hospital Centre »Sestre Milosrdnice«, Department of Pathology, Zagreb, Croatia

³ University of Zagreb, School of Medicine, Zagreb, Croatia

ABSTRACT

Herein we present 82-year-old man with leiomyosarcoma arising from the spermatic cord with scalp metastasis, five years after primary surgical treatment. Complete surgical excision is required in such cases, as well as precise evaluation of further therapy. Paratesticular leiomyosarcoma is a rare entity, malignant mesenchymal tumor of smooth muscle differentiation. Although leiomyosarcomas of different localizations have well-known metastatic potential, cutaneous metastases are extremely rare with only 16 cases described in the literature. To our knowledge there are no reported cases of the paratesticular leiomyosarcoma metastatic to the skin. This article reviews the literature regarding paratesticular leiomyosarcoma presentation, diagnosis and treatment.

Key words: spermatic cord tumors, leiomyosarcoma, metastases, skin

Introduction

Primary spermatic cord and paratesticular tumors are rare yet clinically significant urologic lesions that affect patients of all ages¹. Their true incidence has actually never been established. Most tumors are benign, usually lipomas. Approximately 25% of primary spermatic cord tumors are sarcomas originating from the mesoderm layer of the embryo (Wolffian duct)². Among the paratesticular sarcomas, leiomyosarcoma is the second most common sarcoma in frequency preceded by liposarcoma. Tumors in this region generally present as asymptomatic, slow growing, firm and palpable paratesticular masses. Radical inguinal orchiectomy and high ligation of the cord is the standard primary surgical procedure. The extent of surrounding soft tissue excision is required and the role of adjuvant radiotherapy remains controversial. There is not much data in the literature about this issue. Although leiomyosarcoma has well-known metastatic potential, skin metastases are remarkably uncommon³. We report a leiomyosarcoma of the spermatic cord in an 82-year-old man who developed scalp cutaneous metastases five years after diagnosis of primary tumor.

Case Report

82-year-old man presented with 9-month history of enlarged inguinal region. Patient complained on intermittent abdominal pain. He denied any history of trauma and any lower urinary tract symptoms, 10 years ago patient operated on both sided groin hernias. Ultrasonographic scan revealed normal left testicle and extratesticular, well circumscribed large mass of heterogeneous echogenicity with prominent vascularity in the left groin region. Computed tomography of abdomen and pelvis with intravenous contrast revealed oval, solid, contrast enhancement tumor mass with central calcifications (Figure 1a). Retroperitoneal and inguinal lymph nodes were not enlarged. Levels of α -fetoprotein and β human chorionic gonadotropin were within normal limits, as were results of routine blood investigations. Plain chest X-ray was normal.

The physical examination of the scrotum and inguinum showed a large, oval, non tender, firm mass measured up to 10 cm in diameter. A radical left orchiectomy with high cord ligation and tumor extirpation was performed. On gross examination the resected specimen showed lobulated, oval tumor mass attached to sper-

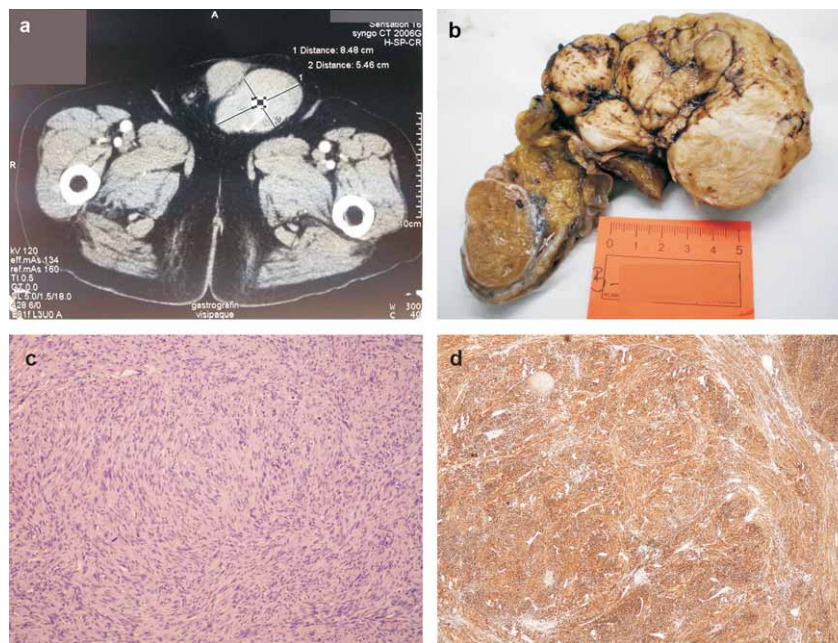


Fig. 1. a) CT scan, paratesticular, relatively well circumscribed tumor, up to 9 cm. b) Macroscopic view of the funicular tumor. c) Microscopically, sheets and cords of polymorphous spindle shaped cells, (100xHE). d) Immunohistochemically tumor cells are positive for smooth muscle actin (40xSMA).

matic cord that measured 12.5x8.5x6.5 cm (Figure 1b). Cut surface of tumor was gray, firm and whorled. The tumor mass was completely located outside the tunica albuginea, not infiltrative to testis or epididymis. Microscopic examination revealed a tumor composed of slender, elongated tumor cells arranged in interlacing fascicles. Tumor cells showed marked nuclear pleomorphism and up to 10 mitoses per 10-high power fields, without necrosis (Figure 1c). The testis and epididymis were free of tumor. Immunohistochemistry revealed positive staining of tumor cells for smooth muscle actin (SMA) (Figure 1d) and negative for S100. The histology and immunohistochemical findings were diagnostic of leiomyosarcoma. Postoperative course was uneventful and the patient received no adjuvant therapy. During regular follow up, 5 years after initial presentation, clinical examination revealed nodule measuring up to 2 cm in diameter, on the skull skin. Patient underwent excision biopsy and microscopic examination showed a well circumscribed dermal nodule, on high-power it was cellular tumor composed of atypical spindled cells with a woven, lobulated histological pattern and a high mitotic ratio. Further immunohistochemical staining was positive for SMA and confirmed the diagnosis of metastatic leiomyosarcoma. One month later staging computer tomography of the chest and abdomen showed multiple lung metastases. Regarding patient's age he didn't receive any adjacent chemo or radiotherapy and after 3 months is still alive.

Discussion

Leiomyosarcoma is a rare testicular and paratesticular neoplasm, with about 110 cases reported⁴. There

have been other reports of leiomyosarcoma in the genitourinary system, including urethra, renal capsule and epididymis. These tumors have a higher incidence after the sixth decade of life⁴. Although the exact origin is unknown, it is speculated that they most likely originate from the smooth muscle of different cord structure areas, such as the vas deferens, canal wall, blood vessels and cremasteric muscle⁵. Some authors suggested that leiomyosarcomas of spermatic cord arise as a result of malignant degeneration from previously existing benign leiomyomatous tumors^{5,6}. The role of hormonal stimulation has also been linked to leiomyosarcoma carcinogenesis. Interestingly, some spermatic cord leiomyosarcomas have been found to produce β human chorionic gonadotropin causing a paraneoplastic syndrome^{6,7}.

Most spermatic cord malignancies originate just below the external inguinal ring and grow as scrotal rather than inguinal masses. Since they may appear as scrotal masses, the preoperative clinical diagnosis may be challenging given that it may be difficult to determine the exact location of the tumor. Paratesticular sarcomas usually have a heterogeneous pattern and are seen as hypervascular tumors on Doppler sonography⁸. Computed tomography scan and magnetic resonance imaging may be helpful in refining tumor location, morphologic features, and tissue characteristics, as well as determining the extent of the mass into the neighboring tissues. Computed tomography is helpful in distinguishing a primary spermatic cord tumor from a retroperitoneal process extending into the scrotum^{8–10}.

Leiomyosarcoma of the cord structures are known to spread by local invasion, lymphatic dissemination and

hematogenous metastases. The route of lymphatic spread involves the external iliac, hypogastric, common iliac and paraaortal nodes. Lung is the most common metastatic site and is almost always involved in metastatic disease. The curative treatment of choice is radical orchietomy with high cord ligation and wide excision of surrounding soft tissue structures within the inguinal canal. Patients with inadequately resected tumor should undergo re-operative procedure for wide inguinal re-excision. It has been estimated that approximately 50% of these tumors recur loco-regionally following definitive surgery. Pathologic features that convey a higher risk of local recurrence include large tumor size, inguinal location, narrow or positive margins and prior intralesional surgery. Loco-regional relapse may occur in the cord, scrotum, or adjacent pelvis, with or without involvement of the regional lymph nodes¹⁻⁶.

Retroperitoneal lymph node dissection is not regularly recommended for patients with spermatic cord leiomyosarcoma. Retroperitoneal lymphadenectomy is recommended when there is preoperative evidence of retroperitoneal lymph node metastases. Adjuvant treatments, such as radiotherapy and chemotherapy, have shown little efficacy, except in the management of patients with local recurrence¹⁰. Some data suggest that patients who underwent postsurgical radiotherapy have better prognosis¹¹. Our patient underwent radical orchidectomy with high cord ligation, no further treatment was given. Long-term follow up is recommended due to high recurrence rates. Patients may also present with signs and symptoms of distant metastases 15 years or more after first resection^{4,10,11}.

Sarcoma metastases to the skin are rare, in published literature series reported prevalence was between 1% and 2.6%. Skin metastases are usually late events in sarcoma clinical progression and carry a poor prognosis. Lung metastases may occur in patient either simultaneously or within a short period after skin metastases. The majority of sarcoma patients developed skin me-

tastases distant to the site of primary origin which is in contrast to many types of carcinomas where regional skin metastases are common presentation. The scalp is frequently involved anatomic site, perhaps because of the highly vascular nature and immobility of this region¹¹. In the English-spoken literature only 16 cases of leiomyosarcoma metastatic to the skin have been reported³. The uterus is the overall most common site of origin metastasizing to the skin. Moreover, primary tumors of the genitourinary system account for more than half of the cases. Other sites of primary tumors include gastrointestinal tract, heart, breast and the retroperitoneum. Only one patient in the reported series developed a single, isolated skin metastasis. The mean reported interval between the time of diagnosis of primary leiomyosarcoma and the development of cutaneous metastases is 3 years¹¹⁻¹³. To our knowledge there are no reported cases of the paratesticular leiomyosarcoma metastatic to the skin.

Prognosis is highly variable, more recently a five-year survival of 50–80% has been reported, possibly reflecting the advances in diagnosis and management of these tumors¹³⁻¹⁵. The wide range in the five-year survival rate might be due to the variations in tumor stage and grade at the time of diagnosis as well as the diversity of therapies involved. A recent review disclosed a mean survival of 138 months for patients with leiomyosarcoma, but the mean survival after the occurrence of cutaneous metastases in the present series was just 10 months¹⁶.

Conclusion

Although leiomyosarcoma is a rare neoplasm, it can present as an extremely large primary tumor. It seems to have low metastatic potential but metastases may be seen many years after the primary tumor. Management is largely surgical. The need for adjuvant therapy is in question; reports of spermatic cord leiomyosarcoma provide limited data on postoperative recurrence.

REFERENCES

- RODRIGUES D, OLUMI AF, *Ther Adv Urol*, 4 (2012) 325. DOI: 10.1177/1756287212447839
- FOLPE AL, WEISS SW, *Semin Diag Pathol*, 17 (2000) 307.
- VANDERGRIF T, KRATHEN RA, ORENGO I, *Dermatol Surg*, 33 (2007) 634. DOI: 10.1111/j.1524-4725.2007.33127.
- KYRATZI I, LOLIS E, ANTYP A, LIANO MA, EXARHOS D, *World J Radiol*, 3 (2011) 114. DOI: 10.4329/wjr.v3.i4.114
- YUEN VTH, KIRBY SC, WOO YC, *Can Urol Assoc J*, 5 (2011) 121. DOI: 10.5489/cuaj.11008
- CELIK U, UNLU G, *Asian J Androl*, 15 (2013) 843. DOI: 10.1038/aja.2013.88
- OU SM, LEE SS, PENG YJ, SHEU NS, CHANG SY, *J Androl*, 27 (2013) 643. DOI: 10.2164/jandrol.106.000224.
- AKBAR SA, SAYYED TA, JAFRI SZ, HASTE H, NEILL JS, *Radiographics*, 23 (2003) 1461. DOI: 10.1148/rg.236025174.
- WOODWARD PJ, SCHWAB CM, SESTERHENN IA, *Radiographics*, 23 (2003) 215. DOI: 10.1148/rg.231025133.
- VARZANEH FE, VERGHESE M, SHMOOKLER BM, *Urology*, 60 (2002) 1112. DOI: 10.1016/S0090-4295(02)02076-9.
- PETERSON AC, PORTER M, PORTER J, *Urology*, 59 (2002) 294. DOI: 10.1016/S0090-4295(01)01524-2.
- DANGLE P, BASAVARAJ DR, BHATTARAI S, PAUL AB, BIYANI CS, *Can Urol Assoc J*, 1 (2007) 55.
- CORCORAN S, HOGAN AM, NEMETH T, SULLIVAN FJ, KHAN W, BARRY K, *Diagn Pathol*, 18 (2012) 85. DOI: 10.1186/1746-1596-7-85.
- WANG WL, BONES-VALENTIN RA, PRIETO VG, POLLOCK RE, LEV DC, LAZAR AJ, *Cancer*, 118 (2012) 2900. DOI: 10.1002/cncr.26590.
- LEE G, LEE SY, SEO S, JEON S, LEE H, CHOI H, JEONG BC, *Korean J Urol*, 52 (2011) 669. DOI: 10.4111/kju.2011.52.10.669.
- ENOCH S, WHARTON SM, MURRAY DS, *World J Surg Oncol*, 3 (2005) 3. DOI: 10.1186/1477-7819-3-23.

B. Spajić

*University of Zagreb, University Hospital Centre »Sestre Milosrdnice«, Department of Urology, Vinogradska 29,
10000 Zagreb, Croatia
e-mail: borislav.spajic@kbcsm.hr*

LEIOMIOSARKOM SJEMENOG SNOPA S METASTAZOM U KOŽI LUBANJE: PRIKAZ SLUČAJA I PREGLED LITERATURE

S A Ž E T A K

Leiomiosarkom paratestikularnog tkiva je veoma rijedak maligni mezenhimalni tumor koji pokazuje glatkomišićnu diferencijaciju. Iako leiomiosarkomi različitih sijela imaju dobro poznatu sposobnost metastaziranja, kožne metastaze su izrazito rijetke, sa samo 16 opisanih slučajeva u literaturi. Do sada nije opisan nijedan slučaj metastaze leiomiosarkoma sjemenog snopa s metastazama u kožu. Donosimo opis 82-godišnjeg bolesnika s bezbolnom masom u lijevom hemiskrotumu, leiomiosarkom sjemenog snopa s metastatskom bolesti koja se manifestirala nakon pet godina kao kožni tumor te zatim i metastazama u pluća. U takvim slučajevima potrebno je potpuno kirurško odstranjenje tumorske mase te precizna procjena određivanja daljnje terapije. U ovom radu donosimo prikaz literaturnih navoda koji se bave opisanom problematikom prezentacije, dijagnoze i liječenja paratestikularnih leiomiosarkoma.