

Psychiatric manifestations of multiple sclerosis and acute disseminated encephalomyelitis

Habek, Mario; Brinar, Marko; Brinar, Vesna V.; Poser, Charles M.

Source / Izvornik: **Clinical Neurology and Neurosurgery**, 2006, 108, 290 - 294

Journal article, Accepted version

Rad u časopisu, Završna verzija rukopisa prihvaćena za objavljivanje (postprint)

<https://doi.org/10.1016/j.clineuro.2005.11.024>

Permanent link / Trajna poveznica: <https://um.nsk.hr/um:nbn:hr:105:126738>

Rights / Prava: [In copyright](#) / [Zaštićeno autorskim pravom](#).

Download date / Datum preuzimanja: **2024-09-08**



Repository / Repozitorij:

[Dr Med - University of Zagreb School of Medicine
Digital Repository](#)





Središnja medicinska knjižnica

Habek, M., Brinar, M., Brinar, V. V., Poser, C. M. (2006) *Psychiatric manifestations of multiple sclerosis and acute disseminated encephalomyelitis*. *Clinical Neurology and Neurosurgery*, 108 (3). pp. 290-294.

<http://www.elsevier.com/locate/issn/0303-8467>

<http://www.sciencedirect.com/science/journal/03038467>

<http://medlib.mef.hr/245>

University of Zagreb Medical School Repository

<http://medlib.mef.hr/>

**Psychiatric manifestations of multiple sclerosis and acute disseminated
encephalomyelitis**

Mario Habek^a, Marko Brinar^b, Vesna V. Brinar^a and Charles M. Poser^c

^aUniversity Department of Neurology, Zagreb School of Medicine and University
Hospital Center Zagreb, Kišpatićeva 12, Zagreb, Croatia

^bUniversity Department of Internal Medicine, Zagreb School of Medicine and
University Hospital Center Zagreb, Kišpatićeva 12, Zagreb, Croatia

^cDepartment of Neurology, Harvard Medical School, Boston, MA, USA

Abstract

It is unusual for acute disseminated encephalomyelitis and multiple sclerosis to present as purely psychiatric disorders. We report five patients with such demyelinating diseases and symptoms of psychosis, depression or anxiety. The importance of excluding demyelination as the basis for these psychiatric disturbances is emphasized, especially in the presence of unexplained neurologic findings. The possible relationship between psychiatric symptoms and demyelinating disorders is explored.

Keywords: Disseminated encephalomyelitis; Multiple sclerosis; Psychosis; Depression; Generalized anxiety disorder

Introduction

A purely psychiatric syndrome may, on rare occasions, be the clinical presentation of multiple sclerosis (MS) and of acute disseminated encephalomyelitis (ADEM). These patients are often admitted to a psychiatric facility [1], [2] and [3], the presence of demyelinating lesions on MRI causes them to be referred for neurological evaluation. Depression, general anxiety disorder, bipolar disease, frank psychosis and personality disorders are not quite as rare as generally believed and may dominate the clinical picture [4]. Depression, as well as minor depressive symptoms and anxiety are the most commonly reported psychiatric manifestations [5] and [6].

We describe five patients with ADEM or MS whose first symptoms were those of psychiatric illness.

Case reports

1. In April 2004, a previously healthy 39-year old secretary became fatigued and anxious; she had mood fluctuations, reduced short-term memory and learning ability. During the past 4 months she has lost 10 kg of weight. She denied any history of psychiatric illness, substance abuse, seizures, head injury, or exposure to poisons or toxins. In June, she visited a psychiatrist and was prescribed sertraline and alprazolam, but after 1 month she was admitted to a hospital because of deterioration of her mental state. During that period she became disoriented to time and place, confused, complaining of severe headaches, she had a blunted affect, but normal thought processes and content, and concerned about her illness. She had visual hallucinations. Suicidal ideation or intent was not present, nor was she aggressive. Neurological status was normal. Brain MRI showed very large, multiple, patchy, deep

and subcortical white matter, parieto-occipital and temporal lesions bilaterally, more extensive on the right. CSF analysis revealed 104/3 lymphocytes, total protein level of 69 mg per 100 ml and elevated intrathecal gamma globulin synthesis with positive oligoclonal bands. HIV and hepatitis B and C serology were negative. The diagnosis of ADEM was made and she was treated with IV methylprednisolone with only mild improvement of cognitive function.

In July 2004, she was still disoriented to time and place. The most striking deficits were reduced short-term memory and inability to learn new information. She had no insight into her illness and had constant delusions and hallucinations. After consultation with a psychiatrist, she was given first, olanzapine and haloperidol, then promazine and zolpidem. Laboratory tests including: ACE, immunological tests (ASTA, ANF, ANCA, ENA, RF, Jo-1, anticardiolipin antibodies), complement levels, serum and CSF viral serology (CMV, EBV), serum and CSF toxoplasma, borrelia and fungal serology and cultures were all normal. Free T4 and TSH levels, and thyroid ultrasound were normal. Visual evoked potential latencies were prolonged bilaterally. Repeat brain MR T2 weighted images showed very large, patchy hyperintense, periventricular white matter lesions, with confluence in both occipital lobes (Fig. 1). Significant improvement of her mental state occurred after treatment with IV immunoglobulin and methylprednisolone together with psychiatric drugs; she no longer had delusions or hallucinations, but still had significant difficulty with recent memory and learning. Follow-up MRI in September showed improvement, no signs of new or enhancing lesions.

2. A 44-year-old electrician was admitted to a psychiatric service in October 2002. He had been described by his family as acting strangely, disoriented, confused, and thinking he was the Pope. There was no history of psychiatric illness or substance

abuse. Mental status revealed anxiety with expansive affect. Speech was spontaneous and elaborative. Thought process was characterized by looseness of association, flight of ideas and racing, and thought content was characterized by grandiose and religious delusions. Suicidal ideation or intent was absent. Neurological examination showed right spastic-ataxic hemiparetic gait. Brain MRI revealed hyperintense lesions in the insula. In April 2003, he again had delusions and was readmitted to a psychiatric service. CSF examination was performed and revealed a total protein level of 49 mg per 100 ml and positive oligoclonal bands. Serology tests for *Borrelia* and viruses (Herpes simplex 1 and 2, mumps, coxsackie, adeno, echo, polio, Central European) were negative. Visual evoked potentials were normal. He was diagnosed with ADEM and prescribed olanzapine.

In July 2003, he was admitted to a neurology service. His neurological exam and mental status were normal. Immunological tests (CRP, AST, RF, ANF, ENA, ANCA, anticardiolipin antibodies) and thyroid function tests were normal. Brain MRI showed two non-enhancing lesions in the left periventricular frontal white matter (Fig. 2A). One year later, he was without symptoms and brain MRI performed in July 2004 showed no changes.

3. A 53-year-old woman had a 5-year history of MS based on transient gait difficulty without signs of pyramidal tract involvement, but with periventricular demyelination on MRI (Fig. 3A). She was admitted in March 2001 because of progressive gait disturbances, demanding corticosteroid therapy. Because signs of pyramidal lesion were absent and she expressed paranoid ideation, she was treated with saline infusions. During hospitalization, she developed the full-blown picture of paranoid psychosis. Her mental status was characterized by partial orientation in time, flat affect, short attention span, persecutory delusions (“my ex-boss is stalking me”), and

frightening auditory and tactile hallucinations. During the interview speech was halted, often stopping in midsentence and then picked up a moment later. Suicidal ideation or intent was absent, and she was not aggressive. Brain MRI revealed two demyelinating enhancing lesions in the right parietal cortex ([Fig. 3B](#)). There were no changes in the previously reported lesions. Antipsychotic treatment was initiated with risperidone, olanzapine and haloperidol. There was improvement of her mental status and of her gait, but the antipsychotic drugs affected her liver enzymes. Immediately after discontinuation of the treatment, she again developed walking difficulties with very peculiar leg movements, and expressed fear of walking. Her mental state also deteriorated. After treatment with quetiapin her neurological exam returned to normal. Her diagnosis was confirmed as MS.

4. In October 1998, 6 months after giving birth, a previously healthy, 34-year-old woman architect, became depressed, stopped eating and breastfeeding her child, and had sleep disturbances. She was admitted to a psychiatric hospital and diagnosed with a major depression, but after 9 days, she voluntarily left the hospital, taking alprazolam and maprotilin. Brain MRI revealed multiple demyelinating lesions in the subcortical and periventricular white matter and in the brain stem ([Fig. 2B](#)). Her only symptoms were occasional paresthesiae of the right arm. Neurological examination revealed vertical nystagmus, instability in the Romberg position and tandem gait, and incoordination of the left arm and leg. The family history was positive for depression. CSF examination revealed 11/3 lymphocytes, a total protein level of 29 mg per 100 ml, and elevated intrathecal gamma globulin synthesis with positive oligoclonal bands. Serum viral serology (polio, ECHO, coxsackie, mumps, varicella), serum and CSF *Borrelia* serology and serum *Mycoplasma* serology, immunologic tests (AST, ASTA, ANF, anti-dsDNA, RF, anticardiolipin antibodies), ACE, thyroid function

tests were all normal or negative. Visual evoked potential latencies were prolonged on the left. She was diagnosed as having MS. Re-examination in July 2000 was unchanged, but she was still depressed.

5. In October 2001, a previously healthy woman teacher was seen because of a history of anxiety symptoms, insomnia, poor concentration, fatigue, hypervigilance, palpitations and sweating, for the past 7 months. She noted the onset of gait instability, and had had one episode of syncope, in the previous 2 weeks.

Demyelinating lesions in the parietal periventricular and in left crus cerebri were noted on MRI (Fig. 2C). CSF examination revealed a total protein level of 21 mg per 100 ml and positive oligoclonal bands. The serum level of ACE (69 U/l; normal 8-52) was elevated, and positive titer of ANF (1:16) was found. Serum viral serology revealed a highly positive IgG EBV-EBNA, indicative of a past EBV infection, but other viral titers (Adeno, ECHO, coxsackie, varicella, parotitis, Borrelia) were normal. Visual evoked potential latencies were normal. Thyroid function tests were normal. She was diagnosed as having ADEM.

Discussion

During last decade considerable attention has been devoted to cognitive and psychiatric impairment in MS, however these aspects have been ignored in regard to ADEM. Diaz-Olavarrieta et al. [7] evaluated 44 MS patients who were stable between relapses and found neuropsychiatric symptoms in 95% of them, the most common being depression (79%), agitation (40%), anxiety (37%), irritability (35%), apathy (20%), euphoria (13%), disinhibition (13%), hallucinations (10%), aberrant motor behavior (9%), and delusions (7%). Asghar-Ali et al. [8] described two patients,

without a previous history of psychiatric disorders, were first thought to have bipolar disorder, but were diagnosed as MS after brain MRI and CSF examinations. Another interesting finding is that the percentage of psychiatric patients with white matter abnormalities recorded by MRI consistent with MS is almost 15 times the reported prevalence of MS in the United States [9]. The significance of these figures is open to question since MRI interpretation so frequently does not differentiate between MS and ADEM [10] and [11]. It has not been possible to verify if all the cases cited below truly have MS or may be instances of ADEM. There appears to be only a single report of a psychotic state as the presenting manifestation of a clearly identified case of ADEM [12].

The nature of the relationship between psychiatric problems and demyelinating lesions on MRI is still unresolved. While a causative link may exist, it is also possible that the two are unrelated and purely coincidental. Data from our patients are highly suggestive of a causative link. The fact that our first three patients had only psychiatric disturbances without any neurological abnormalities makes us favor the former.

Treatment of psychosis in ADEM or MS is another unresolved issue. Published reviews suggest that clozapine should be the treatment of choice, although some authors suggest ziprasidone, one of the newer antipsychotic agents [13] and [14]. Our two patients with psychosis were treated with olanzapine, and patient 2 responded best to that drug.

Depression is the most common psychiatric symptom of MS, but there are some reasons to believe it may be the result of demyelination: depression is more common in MS patients than in other neurological and non-neurological diseases [6] and [15], MS patients with brain lesions have more depressive symptoms than those with

predominant spinal cord involvement [16], in many MS patients, depression precedes and accompanies the attacks, and wanes during remissions [17], and several studies have shown a correlation between depression in MS patients and lesions in specific areas of the brain [18] and [19].

The etiological mechanism of the depression in MS is still unclear, but there are some reports that indicate that cortical-subcortical disconnection in the projections areas of the limbic system may be responsible [20]. Correlation with lesion load in the temporal regions has also been suggested [21]. The type of clinical course does not influence the affective or cognitive state of MS patients [22], but depression is one of the strongest predictor of reduced quality of life [23], although as a rule the symptoms respond well to standard treatment [24].

Although in many patients anxiety is merely a reactive response to the disability due to the underlying disease, the clinical picture of our patient 5 suggests that a causative link may exist between anxiety and MS. Anxiety and the association between anxiety and brain MRI changes in MS have not been studied as extensively as depression.

Most published studies found similar levels of anxiety among MS patients and normal controls, and no correlation between the symptoms of anxiety and either brain MRI abnormalities or clinical variables [20] and [25]. However, Riether emphasizes that anxiety is frequently overlooked in MS patients, especially that induced by treatment with corticosteroids [26].

Conclusion

These cases demonstrate that both MS and ADEM represent a small, but significant proportion of all psychiatric patients. Clinicians should keep this in mind, especially

in regard to patients presenting with psychiatric symptoms associated with unexplained neurological findings. Neuroimaging and other studies may reveal underlying demyelination requiring specific diagnostic work-up and therapy.

References

- [1] Nasr J, Andriola M, Coyle P. ADEM: literature review and case report of acute psychosis presentation. *Pediatr Neurol* 2000;2:8–18.
- [2] Spieker S, Petersen D, Rolfs A, et al. Acute disseminated encephalomyelitis following Pontiac fever. *Eur Neurol* 1998;40:169–72.
- [3] Wang P, Fuh J, Liu H, Wang S. Acute disseminated encephalomyelitis in middle-aged or elderly patients. *Eur Neurol* 1996;36:219–23.
- [4] Stevens J. Schizophrenia and multiple sclerosis. *Schizophr Bull* 1998;14:231–41.
- [5] Sadovnick A, Remick R, Allen J, et al. Depression and multiple sclerosis. *Neurology* 1996;46:628–32.
- [6] Minden S, Schiffer R. Affective disorder in multiple sclerosis review and recommendations for clinical research. *Arch Neurol* 1990;47:98–104.
- [7] Diaz-Olavarrieta C, Cummings J, Velazquez J, et al. Neuropsychiatric manifestations of multiple sclerosis. *J Neuropsychiat Clin Neurosci* 1999;11:51–7.
- [8] Asghar-Ali A, Taber K, Hurley R, et al. Pure neuropsychiatric presentation of multiple sclerosis. *Am J Psychiat* 2004;161:226–31.
- [9] Lyoo I, Seol H, Byun H, et al. Unsuspected multiple sclerosis in patients with psychiatric disorders: a magnetic resonance imaging study. *J Neuropsychiat Clin Neurosci* 1996;8:54–9.
- [10] Brinar V. Non-MS recurring demyelinating diseases. *Clin Neurol Neurosurg* 2004;106:197–210.

- [11] Poser C, Brinar V. The nature of multiple sclerosis. *Clin Neurol Neurosurg* 2004;106:159–71.
- [12] Moscovich D, Singh M, Eva F, et al. Acute disseminated encephalomyelitis presenting as an acute psychotic state. *J Nerv Ment Dis* 1995;183:116–7.
- [13] Chong S, Ko S. Clozapine treatment of psychosis associated with multiple sclerosis. *Can J Psychiat* 1997;42:90–1.
- [14] Davids E, Hartwig U, Gastpar M. Antipsychotic treatment of psychosis associated with multiple sclerosis. *Progr Neuro-Psychopharmacol Biol Psychiat* 2004;28:743–4.
- [15] Schubert D, Foliart R. Increased depression in multiple sclerosis patients: a meta-analysis. *Psychosomatics* 1993;34:124–30.
- [16] Schiffer R, Caine E, Bamford K, et al. Depressive episodes in patients with multiple sclerosis. *Am J Psychiat* 1983;140:1498–500.
- [17] Kroencke D, Denny D, Lynch S. Depression during exacerbations in multiple sclerosis: the importance of uncertainty. *Multiple Sclerosis* 2001;7:237–42.
- [18] Bakshi R, Czarnecki D, Shaikh Z, et al. Brain MRI lesions and atrophy are related to depression in multiple sclerosis. *Neuroreport* 2000;11:1153–8.
- [19] Di Legge S, Piattella M, Pozzilli C, et al. Longitudinal evaluation of depression and anxiety in patients with clinically isolated syndrome at high risk of developing early multiple sclerosis. *Multiple Sclerosis* 2003;9:302–6.
- [20] Berg D, Supprian T, Thomae J, et al. Lesion pattern in patients with multiple sclerosis and depression. *Multiple Sclerosis* 2000;6:156–62.
- [21] Zorzon M, de Masi R, Nasuelli D, et al. Depression and anxiety in multiple sclerosis. A clinical and MRI study in 95 subjects. *J Neurol* 2001;248:416–21.

- [22] Moller A, Wiedemann G, Rohde U, et al. Correlates of cognitive impairment and depressive mood disorder in multiple sclerosis. *Acta Psychiat Scand* 1994;89:117–21.
- [23] Fruehwald S, Loeffler-Stastka H, Eher R, et al. Depression and quality of life in multiple sclerosis. *Acta Neurol Scand* 2001;104:257–61.
- [24] Minden SL. Mood disorders in multiple sclerosis: diagnosis and treatment. *J Neurovirol* 2000;6(Suppl 2):S160–7.
- [25] Colombo G, Armani M, Ferruzza E, et al. Depression and neuroticism in multiple sclerosis. *Ital J Neurol Sci* 1988;9:551–7.
- [26] Riether A. Anxiety in patients with multiple sclerosis. *Semin Clin Neuropsychiat* 1999;4:103–13.

Figures

Fig. 1. Case 1: MRI, July 2004.

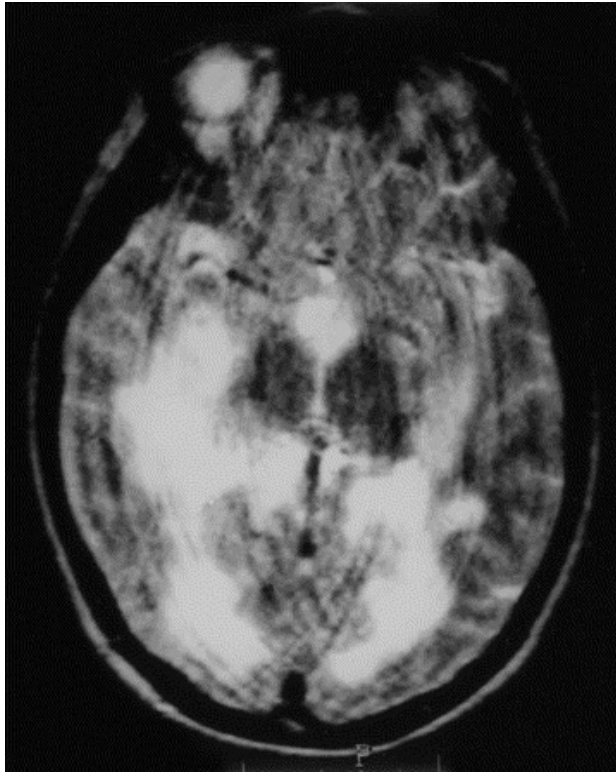


Fig. 2. (A) Case 2: MRI, July 2004; (B) Case 4: MRI, November 1999; (C) Case 5: MRI, April 2002.

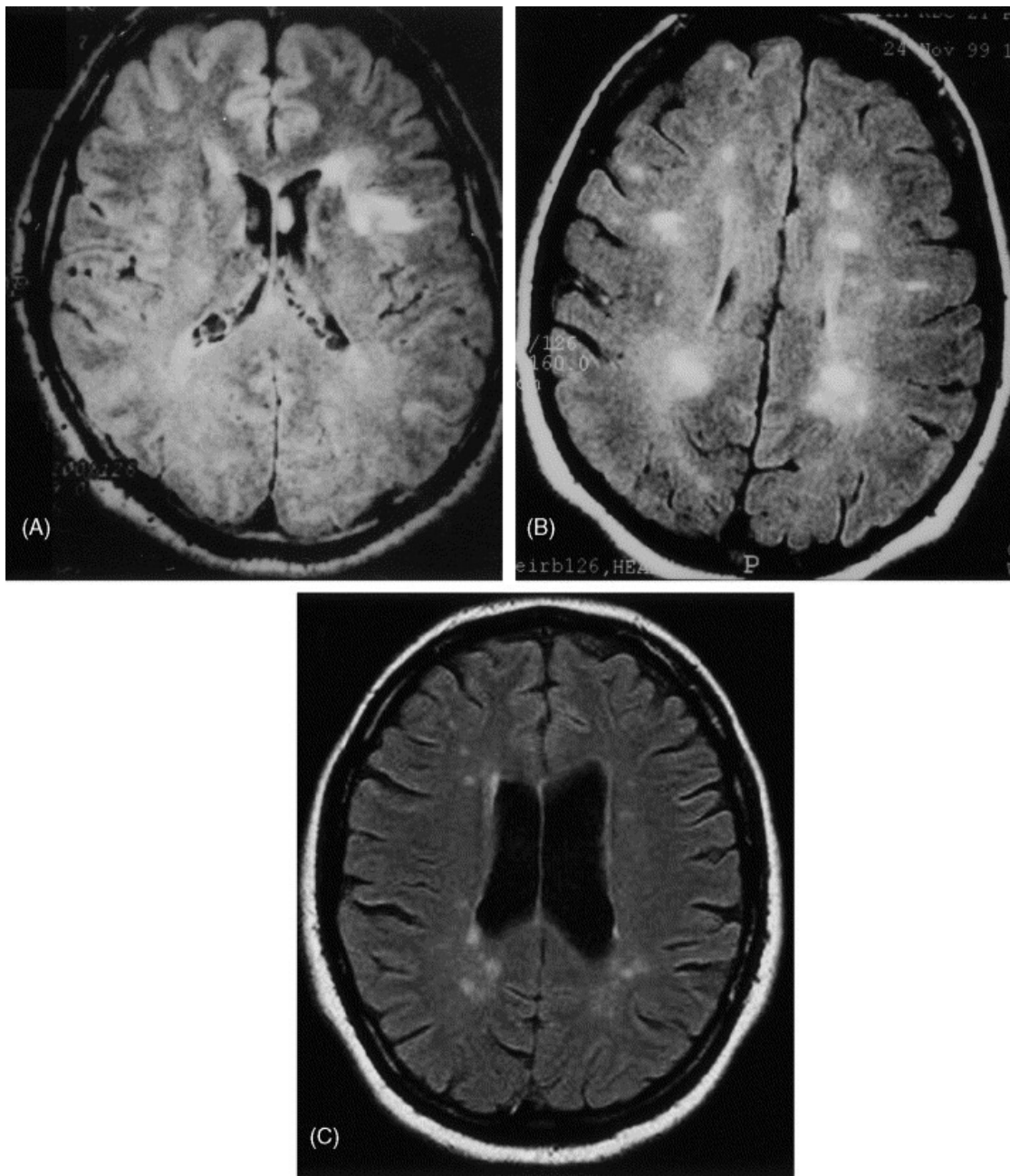


Fig. 3. Case 3: (A) MRI, November 2000; (B) MRI, October 2003.

