

Corticosteroid therapy in patients with non-arteritic anterior ischemic optic neuropathy

**Vidović, Tomislav; Cerovski, Branimir; Perić, Sanja; Kordić, Rajko;
Mrazovac, Danijela**

Source / Izvornik: **Collegium Antropologicum, 2015, 39, 63 - 66**

Journal article, Published version

Rad u časopisu, Objavljena verzija rada (izdavačev PDF)

Permanent link / Trajna poveznica: <https://um.nsk.hr/um:nbn:hr:105:241611>

Rights / Prava: [In copyright](#)/[Zaštićeno autorskim pravom.](#)

Download date / Datum preuzimanja: **2024-09-28**



Repository / Repozitorij:

[Dr Med - University of Zagreb School of Medicine
Digital Repository](#)



Corticosteroid Therapy in Patients with Non-arteritic Anterior Ischemic Optic Neuropathy

Tomislav Vidović, Branimir Cerovski, Sanja Perić, Rajko Kordić and Danijela Mrazovac

University of Zagreb, University Hospital Center Zagreb, Department of Ophthalmology, Zagreb, Croatia

ABSTRACT

Non-arteritic anterior ischemic optic neuropathy is one of the most common conditions affecting the optic nerve in the elderly. It may lead to severe visual loss. Typical symptoms are painless impairment of visual function accompanied by relative afferent pupillary defect, edema of the optic disc and visual field defects. Aim is to present 38 patients with non-arteritic anterior ischemic optic neuropathy who were treated with corticosteroid therapy. This prospective study involved 38 patients, 20 men and 18 women aged 60–75 years who were treated with corticosteroid therapy. The study included patients with visual acuity in the affected eye from 0.1 to 0.8 according to Snellen. Every patient underwent clinical examination, the Octopus 900 perimetry in G program, laboratory testing, while the compressive optic neuropathy was ruled out with MSCT of the brain and orbits. The most common forms of visual field defect are altitudinal defect and diffuse depression. Corticosteroid therapy led to recovery in 65% of patient, in 30% of patients did not change, while the deterioration occurred in 5% of patients.

Key words: optic nerve disease, optic neuropathy, methylprednisolone, perimetry

Introduction

Anterior ischemic optic neuropathy (AION) is damage to the optic nerve caused by insufficient blood supply. It is the result of infarction in the prelaminar portion of the optic nerve. This condition may be due to giant cell arteritis or not related to such condition. Therefore is generally divided into arteritic and non-arteritic anterior ischemic optic neuropathy. The pathogenesis of non-arteritic anterior ischemic optic neuropathy is not completely understood^{1–3}. It is supposed that occlusion of the short posterior ciliary arteries by thrombi and emboli with temporary hypoperfusion of the anterior portion of the optic nerve led to visual disturbances. Patients with crowded or small disc could be the risk factor for development such a condition. Hoyt pointed out that the optic discs of the patients with non-arteritic anterior ischemic optic neuropathy have small disc without physiologic cupping. In following studies were suggested that this optic disc morphology is the most important risk factor⁴. Many patients with this condition have predisposing factors such as arterial hypertension, diabetes mellitus, hyperlipidaemia and arteriosclerosis⁵.

Patients with non-arteritic ischemic optic neuropathy present with painless blurred vision in one eye, usually after awaking. They could feel some discomfort in affected eye. Those patients noticed dark shadow which obscurs

vision or loss of upper or lower part of visual field. Most of the patients have no progression, but minority of the patients can notice the worsening of visual impairment. Ophthalmoscopically edema of the optic disc is seen. Most of the patients have altitudinal, arcuate visual field defects, general constriction or diffuse depression of visual field^{6–8}.

It was thought that there was no accepted treatment for this condition. In the past, several types of therapy were used in order to reverse the damage and start visual recovery. Therapy with neuroprotective agents such as levodopa, optic nerve sheath fenestration, transvitreal optic neurotomy were used in treating non-arteritic anterior ischemic optic neuropathy were performed, but without significant success. Recent publications have suggested that systemic corticosteroid therapy and intravitreal injections of anti VGF therapy could be helpful to improve visual outcome^{9–11}.

The aim of this study is to present 38 patients with non-arteritic form of anterior ischemic optic neuropathy who were treated with corticosteroid therapy.

Material and Methods

This prospective study included 38 patients with non-arteritic anterior ischemic optic neuropathy. 18 patients

were female and 20 male. The mean age was 66.7. The diagnosis was established according to clinical criteria: painless visual impairment, optic disc edema, visual field defects, normal erythrocyte sedimentation level and normal level of c-reactive protein¹⁰. All patients were treated by oral corticosteroid Methylprednisolone 80 mg daily for 5 days followed by a tapering dose 64 mg for 5 days, 48 mg for 5 days, 32 mg 5 days, 16 mg for 5 days and 8 mg for 5 days. The independent ethics committee of the University of Zagreb, School of Medicine approved the study which was performed according to the tenets of the Helsinki declaration. All patients gave written informed consent. Subjects with established arteritic anterior ischemic optic neuropathy, ophthalmologic lesions leading to impaired visual function, such as blurred optic media, retinal detachment, glaucoma, inflammatory changes, degenerative chorioretinal changes, diabetic retinopathy, etc., were excluded. Patients with refraction error greater than 3 diopters were also excluded. Each examination began with taking history data, followed by ophthalmologic examination, and visual field testing by automated Octopus 900 perimetry. Ophthalmologic examination is consisted of visual acuity testing, biomicroscopy, aplanation tonometry and indirect ophthalmoscopy. Visual acuity was assessed by the subjective method using standard optotypes according to Snellen at 6-m distance. Vision field was tested on Octopus 900 perimeter using G program. On visual field testing, the parameters of mean defect (MD) and the pattern of visual field defects were analyzed. Visual field defects were categorised according to the pattern as follows:

1. arcuate defect
2. altitudinal defect
3. diffuse depression
4. central island of visual field
5. other defects

Clinical examination and Octopus perimetry were performed at admission and 6 month after the cessation of therapy. We analysed visual acuity (VA) and the values of mean defect (MD).

Statistical methods

For all the analyzed variables descriptive statistics was made. The level of significance of 5% in all tests was considered statistically significant. In order to show that there were no differences between age for both sexes we used Student’s T test. Differences between the VA and MD before and after treatment for both sexes we tested using repeated measure analysis of variance. A statistical analysis as well as graphics were made using STATISTICA.

Results

At the time of initial examination, mean visual acuity was. Visual acuity from 0.1 to 0.3 according to Snellen was found in 19 patients, visual acuity from 0.4 to 0.7 had 18 patients, and one patient had visual acuity 0.8 according to Snellen. In all patient edema of the optic disc was vis-

TABLE 1
DESCRIPTIVE STATISTICS

	\bar{X}	SD	\bar{X}	SD
	VA0		VA1	
female	0.27	0.09	0.38	0.16
male	0.27	0.11	0.40	0.07
	MD0		MD1	
female	11.80	2.10	10.01	1.93
male	11.76	1.93	10.18	1.13

VA0 – visual acuity at initial examination; VA1 – visual acuity at control examination; MD0 – mean defect at initial examination; MD1 – mean defect at control examination

ible with indirect ophthalmoscopy. Mean MD was 11.8 (Table 1). The most common visual field defects were altitudinal defect, which was found in 17 patients, and diffuse depression, which was found in 16 patients. Central island of visual field had 3 patient and other forms of defect 2 patients.

Every patient underwent control clinical examination and testing of the visual field six months after the cessation of therapy. On control clinical examination was found improvement of visual acuity as well as improvement of visual field.

The results of repeated measure ANOVA show that there is no statistically significant difference in VA and MD for both sexes. For measurements before and after there was a statistically significant difference. The interaction was not statistically significant, indicating that the changes behave the same in both sexes (Table 2).

On control examination mean visual acuity was 0.39 and mean MD was 10.1. Figure 1 is showing the comparisons of the result of visual acuity testing at initial and control examination. Figure 2 is showing the comparison of visual field testing between initial and control examination.

TABLE 2
RESULTS OF REPEATED MEASURE ANOVA

	VA			MD		
	MS	F	p	MS	F	p
Gender	0.00	0.15	0.704	0.05	0.01	0.923
Error a	0.02			5.49		
Time	0.18	19.68	<0.001	35.57	35.07	<0.001
Time*gender	0.00	0.17	0.681	0.13	0.13	0.720
Error b	0.01			1.01		

VA – visual acuity; MD – mean defect

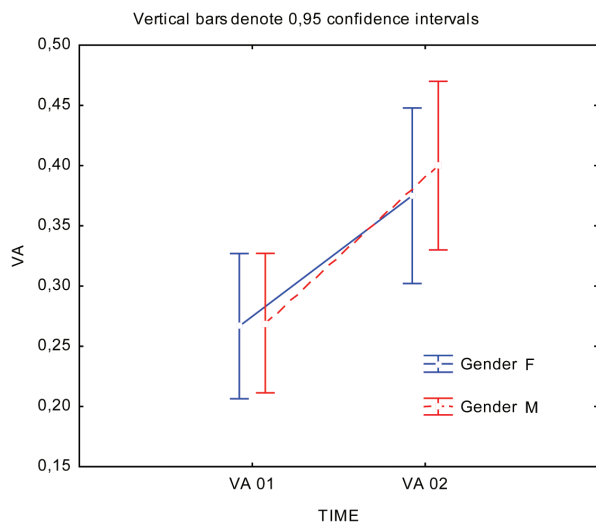


Fig. 1. Comparison of results of visual acuity testing between initial and control examination. VA 01 – results of visual acuity testing at initial examination, VA 02 – results of visual acuity testing at control examination.

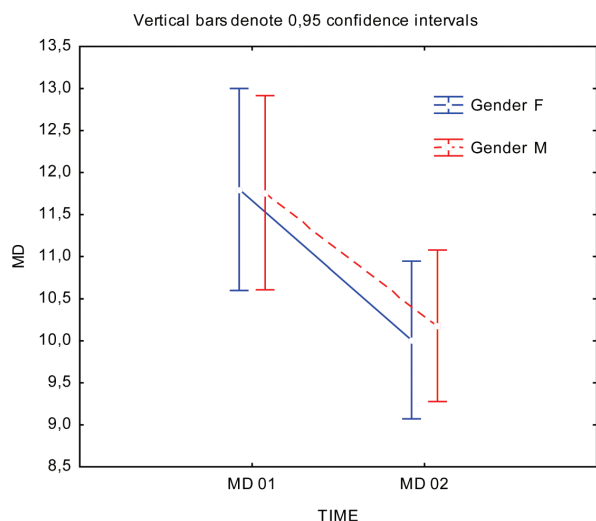


Fig. 2. Comparison of results of visual field testing between initial and control examination. MD 01 – results of mean defect of visual field testing at initial examination, MD 02 – results of mean defect of visual field testing at control examination.

Discussion

In this study we have presented the results of clinical evaluation and the results of therapy in 38 patients with non-arteritic anterior ischemic optic neuropathy. Mean visual acuity according to Snellen was 0.27. Octopus 900 perimetry in G program showed diffuse depression and altitudinal defects to be the most common visual field defect. Hayreh suggested that perimetry is the most important visual function test to detect visual loss, since some patients with such a condition had normal visual acuity. He also noted that a combination of a relative inferior al-

titudinal defect with absolute inferior nasal defect is most common visual defect pattern¹⁰. In our study most of the patients had altitudinal defects and diffuse depression. This difference could be due to smaller number of patients and different methods of visual field testing.

Hayreh noted that optic disc edema is main clinical finding at the onset of visual loss, which resolves spontaneously¹⁰. In all our patients we have found optic disc edema at initial examination. 4 patients had a few splinter hemorrhages on the optic disc. 6 months later edema has resolved and pallor of optic disc was seen on control examination.

The therapy of this condition is still controversial. In the past, many investigators tried various therapies to improve visual outcome in patient with non-arteritic anterior ischemic optic neuropathy. Multiple medical therapies were used, such as brimonidin, levodopa, anticoagulation, dyphenylhydantoin and norepinephrine. But they had no benefit on visual function⁴. Hyperbaric oxygen and optic nerve sheath decompression also had no benefit. It was reported that the use of intravitreal injection of triamcinolone resulted with visual function improvement. They suggested that intravitreal applied corticosteroids reduced optic disc edema and got better visual function^{4,11}. But we will have to wait for more reports and clinical studies in order to conclude whether this therapy is successful. Soheilian and coworkers reported that transvitreal optic neurotomy improved visual function in six out of seven patients with non-arteritic anterior ischemic optic neuropathy¹². More recently Hayreh and Zimmerman reported the treatment with systemic corticosteroid therapy. This study included 613 consecutive patients with non-arteritic anterior ischemic optic neuropathy. 312 patients were treated with oral prednisone. On the other hand 301 patients decided no treatment. Every patient underwent ophthalmic evaluation and Goldmann perimetry. They concluded that patients treated with corticosteroid therapy have higher probability of recovery of visual acuity and visual field. In our study we have treated 38 patients with oral corticosteroid Methylprednisolone 80 mg daily for 5 days followed by tapering doses. It is supposed that corticosteroid therapy relieves the pressure on the axons during the acute phase with edema of the optic disc, which could prevent further damage to the optic nerve.

Since perimetry is one of the most important test of visual function, we chose Octopus 900 perimetry in G program besides visual acuity testing to be the major method to follow the results of therapy. We have found statistically significant difference between mean visual acuity and mean MD prior and after the therapy. On the other hand, other authors have not supported systemic corticosteroid therapy in patients with non-arteritic anterior ischemic optic neuropathy, since this therapy is not based on any level I evidence and it is potentially dangerous¹⁵.

In conclusion, although we found improvement of visual function in patients with non-arteritic anterior ischaemic optic neuropathy treated with systemic corticosteroids, this study should complement with higher number of patients and with control group of patients with non-arteritic patient were treated with no systemic corticosteroids.

REFERENCES

1. MONTEIRO MLR, Arq Bras Oftalmolo, 69 (2006) 805. — 2. CEROVSKI B, Lijec Vjesn, 125 (2003) 265. — 3. PERIĆ P, CURKOVIC B, POTOCKI K, BABIC-NAGLIC D, PERIC S, CEROVSKI B, KEHLER T, VIDOVIC T, Coll Antropol, 31 (2007) 637. — 4. HO SF, DHAR-MUNSHI S, Curr Opin Ophthalmol, 19 (2008) 461. — 5. CHEN T, SONG D, SHAN G, WANG K, WANG Y, MA J, ZHONG Y, PLoS ONE, 23 (2007) 227. DOI: 10.1371/journal.pone0076653. — 6. ATHAPPILLY G, PELAK VS, MANDAVA N, BENNETT JL, Neurol Res, 30 (2008) 794. — 7. BUONO LM, FOROOZAN R, SERGOTT RC, SAVINO PJ, Curr Opin Ophthalmol, 13 (2002) 357. — 8. NEWMAN NJ, Neurology, 46 (1996) 315. — 9. HAYREH SS, Graefes Arch Clin Exp Ophthalmol, 251 (2013) 1873. DOI: 10.1007/s00417-013-2399-z. — 10. HAYREH SS, Indian J Ophthalmol, 59 (2011) 123. DOI: 10.4103/0301-4738.77024. — 11. LUNEAU K, NEWMAN NJ, BIOUSSE V, The Neurologist, 14 (2008) 341. — 12. SOHEILIAN M, KOOCHEK A, YAZDANI S, PEYMAN GA, Retina, 23 (2003) 692. — 13. HAYREH SS, ZIMMERMAN MB, Graefes Arch Clin Exp Ophthalmol, 246 (2008) 1029. — 14. KINORI M, BEN-BASSAT I, WASSERZUG Y, CHETRITA A, HUNA-BARON R, BMC Ophthalmology, 14 (2014) 62. — 15. LEE AG, BIOUSSE V, J Neuroophthalmol, 30 (2010) 193. DOI:10.1097/WNO.0b013e3181e1f71f.

T. Vidović

*University of Zagreb, University Hospital Center Zagreb, Department of Ophthalmology, Kišpatićeva 12,
10 000 Zagreb, Croatia
e-mail: tvidovic@hotmail.com*

KORTIKOSTEROIDI U LIJEČENJU BOLESNIKA S NEARTERITIČKOM PREDNJOM ISHEMIČKOM OPTIČKOM NEUROPATIJOM

SAŽETAK

Autori prikazuju 38 bolesnika s nearteritičkom prednjom ishemičkom optičkom neuropatijom koji su liječeni kortikosteroidima. U ovom prospektivno istraživanju sudjelovalo je 38 ispitanika, 20 muškaraca i 18 žena u dobi 60 do 75 godina, koji su liječeni kortikosteroidima. U istraživanje su uključeni bolesnici s vidnom oštrinom na zahvaćenom oku od 0,1 do 0,8 prema Snellenu. Svi su klinički pregledani uz Octopus 900 perimetriju u G programu i laboratorijsku opservaciju, dok se kompresivna optička neuropatija isključila MSCTom mozga i orbita. Najčešći oblici oštećenja vidnog polja bili su altitudinalni defekt i difuzna depresija mrežnične osjetljivosti. Kortikosteroidna terapija dovela je do oporavka u 65% bolesnika, u 30% bolesnika nije bilo promjena, dok je pogoršanje nastupilo u 5% bolesnika.