

# Is stapled hemorrhoidopexy safe for the male homosexual patient? Report of a case

---

**Kekez, Tihomir; Bulić, Krešimir; Smuđ, Dubravko; Majerović, Mate**

*Source / Izvornik:* **Surgery Today, 2007, 37, 335 - 337**

**Journal article, Accepted version**

**Rad u časopisu, Završna verzija rukopisa prihvaćena za objavljivanje (postprint)**

<https://doi.org/10.1007/s00595-006-3378-3>

*Permanent link / Trajna poveznica:* <https://um.nsk.hr/um:nbn:hr:105:633537>

*Rights / Prava:* [In copyright](#)/[Zaštićeno autorskim pravom.](#)

*Download date / Datum preuzimanja:* **2025-03-29**



*Repository / Repozitorij:*

[Dr Med - University of Zagreb School of Medicine  
Digital Repository](#)





### **Središnja medicinska knjižnica**

Kekez, T., Bulić, K., Smuđ, D., Majerović, M (2007) *Is stapled hemorrhoidopexy safe for the male homosexual patient? Report of a case.* Surgery Today, 37 (4). pp. 335-337.

The original publication is available at [www.springerlink.com](http://www.springerlink.com)  
<http://www.springerlink.com/content/2818119573727282/>

<http://medlib.mef.hr/264>

University of Zagreb Medical School Repository

<http://medlib.mef.hr/>

# Is Stapled Hemorrhoidopexy Safe for the Male Homosexual Patient?

Report of a Case.

Tihomir Kekez, Kresimir Bulic, Dubravko Smudj and Mate Majerovic

University Hospital Zagreb

Kispaticeva 12

Reprint requests to:

Tihomir Kekez

Karlovacka 135a

10 020 Zagreb

Croatia

Fax: 00385 1 2421 845

e-mail: [tkekez@mef.hr](mailto:tkekez@mef.hr)

Key words: hemorrhoidopexy, homosexual, sexually transmitted disease

Running title: Stapled Hemorrhoidopexy

## Abstract

Stapled hemorrhoidopexy is becoming a widely accepted surgical treatment for third and fourth degree hemorrhoids because it is followed by much less postoperative pain than open hemorrhoidectomy. After the procedure, a circular line of staples is left in the anal canal; therefore, there is a risk of penile injury or condom damage during anal intercourse, which increases the risk of exposure to sexually transmitted diseases.

We report the case of a male homosexual patient who engaged in anal intercourse after recovering from a stapled hemorrhoidopexy, which resulted in condom damage. We did not consider this possibility and neglected to discuss the issue with the patient. With an estimated 2.5% of the general population being exclusive male homosexuals, it is necessary to inform such patients to refrain from anal intercourse after hemorrhoidopexy, although there are no reports stating how long this restraint should last.

## Introduction

Stapled hemorrhoidopexy has emerged as a widely accepted alternative to open hemorrhoidectomy, offering much less postoperative pain with an outcome comparable to that of the Milligan-Morgan technique<sup>1</sup>. Although little is known about the fate of the circular staple line left in the anal canal after the procedure, it is assumed that the staples slough off or become buried in the mucosa in the months after surgery. Bearing in mind that about 10% of an estimated 525000 patients treated for hemorrhoids annually in the US alone<sup>2</sup> will require a surgical procedure, and that the remaining staples could rupture condoms or cause penile injury during an anal intercourse, the fate and dynamics of staple disappearance becomes a clinical concern, rather than a purely academic issue.

## Case Report

A 37-year old man attended a regular follow-up appointment at our out-patient clinic 2 months after undergoing a stapled hemorrhoidopexy (PPH procedure). He had been treated with rubber band ligation on several occasions for second degree hemorrhoids, but as his symptoms reappeared, he was offered surgical treatment with a PPH stapler. During the follow up examination, he admitted to having homosexual preference, and to having engaged in anal intercourse several days earlier. During the intercourse, his partner complained of an unpleasant ridge in patient's anal canal, and they noticed a tear in the condom close to the top. Fearing exposure to sexually transmitted diseases, they decided not to have further intercourse. He added that although he had a regular partner, he also had sexual relations with unknown partners on occasion. On rectal exam, the stapler line was palpable as a circular hardening. Metal clips were partially visible through the anoscope near the anterior midline, 3 cm above the dentate line. The rest of the clips were either buried within the mucosa, or overlaid with the mucosal folds. We recommended the patient to refrain from anal intercourse for a period of 3 months. At the next follow-up examination, 3 months later, the stapler line was still palpable, but no clips were visible anoscopically. He reported a slight discomfort during intercourse thereafter, which decreased with time, and no further condom tears were experienced.

## Discussion

Stapled hemorrhoidopexy removes a ring of redundant rectal mucosa above the anal canal, proximal to the hemorrhoids. The goal is to resuspend the prolapsing hemorrhoidal tissue back within the anal canal, as well as to interrupt the arterial inflow that traverses the excised segment. In contrast to conventional hemorrhoidectomy, skin tags and enlarged external hemorrhoids are not removed with the stapled technique.<sup>3</sup> Data show that stapled hemorrhoidopexy offers the benefits of less postoperative pain, less requirement for analgesia, and less pain at first bowel movement, providing similar control of symptoms 1 year after surgery as open hemorrhoidectomy<sup>4</sup>. The method is becoming widely favored by patients and physicians, although one study showed that in the medium- to long-term, stapled hemorrhoidopexy seemed to carry a higher risk of symptomatic external hemorrhoidal disease, needing further surgery<sup>5</sup>. There is very little information on the fate of the staples in the anal canal after a PPH procedure (Fig 1). It is assumed that they slough off or become buried in the mucosa within several months, during which time there is some degree of risk of penile injury during anal intercourse<sup>6</sup>. Unfortunately, there are no reports stating exactly how long recipients of this operation should refrain from anal intercourse and defining the risk of penile injury and subsequent exposure to sexually transmitted diseases. Based on the assumption that staples are sloughed off with time, we recommended sexual abstinence for 3 months to our patient at his first follow-up when he reported the incident, believing that would be sufficient time for the rest of staples to slough off (Fig 2). We chose the period of 3 months as the patient was reluctant to have monthly anosopic exams, and we felt uneasy recommending him to resume his sexual activities earlier without seeing the staples

disappear on anoscopy. However, seeing the staples visible on an X-ray of a patient 12 months after the PPH procedure (Fig 3.), we are no longer sure about how long the period of abstinence should be, or if the staple line buried under the mucosa represents a permanent risk for condom or penile injury. An estimated 525 000 patients are treated for symptomatic hemorrhoids annually in the US, approximately 10 % of whom will require surgical treatment<sup>2</sup>. Considering that homosexual men account for an estimated 2.5% of the general population<sup>7</sup>, this might become a cause for concern in proctologic practice, and an important medico legal issue, if it is not discussed with the patient. We plan to incorporate this possible complication in the standard informed consent form which is given to all our patients undergoing a stapled hemorrhoidopexy, regardless of their declared sexual preference



## References

1. Gravie JF, Lehur PA, Hutten N, Papillon M, Fantoli M, Descottes B, et al. Stapled hemorrhoidopexy versus milliganmorgan hemorrhoidectomy: a prospective, randomized, multicenter trial with 2-year postoperative follow up. *Ann Surg.* 2005;242:29-35.
2. Bleday R, Pena JP, Rothenberger DA, Goldberg SM, Buls JG. Symptomatic hemorrhoids: current incidence and complications of operative therapy. *Dis Colon Rectum.* 1992;35:477- 481.
3. Madoff RD, Fleshman JW; Clinical Practice Committee, American Gastroenterological Association. American Gastroenterological Association Technical Review on the Diagnosis and Treatment of Hemorrhoids. *Gastroenterology.* 2004;126:1463-1473.
4. Sengamore AJ, Singer M, Abcarian H, Fleshman J, Corman M, Wexner S, et al. Procedure for Prolapse and Hemorrhoids Multicenter Study Group. A prospective, randomized, controlled multicenter trial comparing stapled hemorrhoidopexy and Ferguson hemorrhoidectomy: perioperative and oneyear results. *Dis Colon Rectum.* 2004;47:1824-1836.
5. Van de Stadt J, D' Hore A, Duinslaeger M, Chasse E, Penninckx F; Belgian Section of Colorectal Surgery Royal Belgian. Long-term results after excision haemorrhoidectomy versus stapled haemorrhoidopexy for prolapsing haemorrhoids; a Belgian prospective randomized trial. *Acta Chir Belg.* 2005;105:44-52.
6. Corman ML, Gravie FJ, Hager T, Loudon MA, Mascagni D, Nystrom PO, et al. Stapled haemorrhoidopexy: a consensus position paper by an international working party - indications, contra-indications and technique. *Colorectal Dis.* 2003;5:304-310.

7. Black D, Gates G, Sanders S, Taylor L. Demographics of the gay and lesbian population in the United States: Evidences from data sources. *Demography* 2000;37:139-154.

## Figure legend

Fig 1. Appearance of the staple line 4 days after stapled hemorrhoidectomy, showing staples protruding through the mucosal ridge created by stapler.

Fig 2. Appearance of the anal canal 12 months after the stapled hemorrhoidectomy.

Fig 3. Pelvic X-ray of a patient 12 months after a stapled hemorrhoidectomy showing visible staples (within the white circle).

Fig 1.

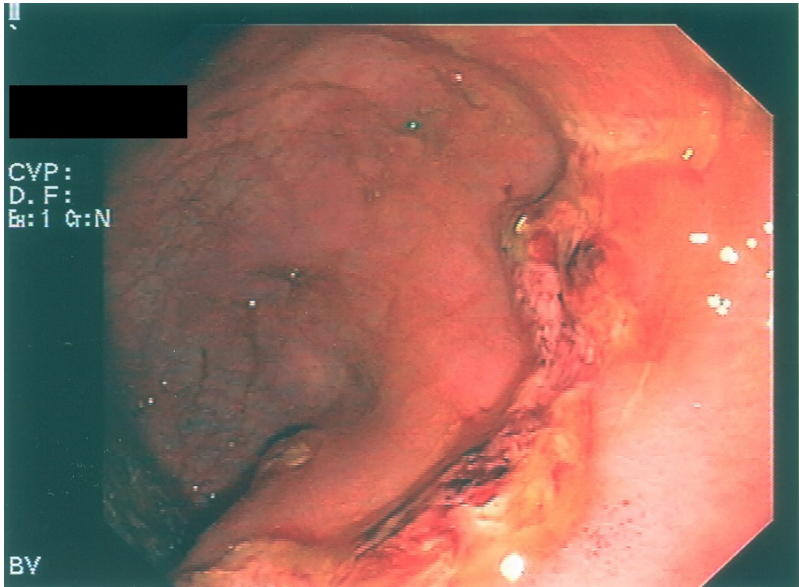


Fig 2.

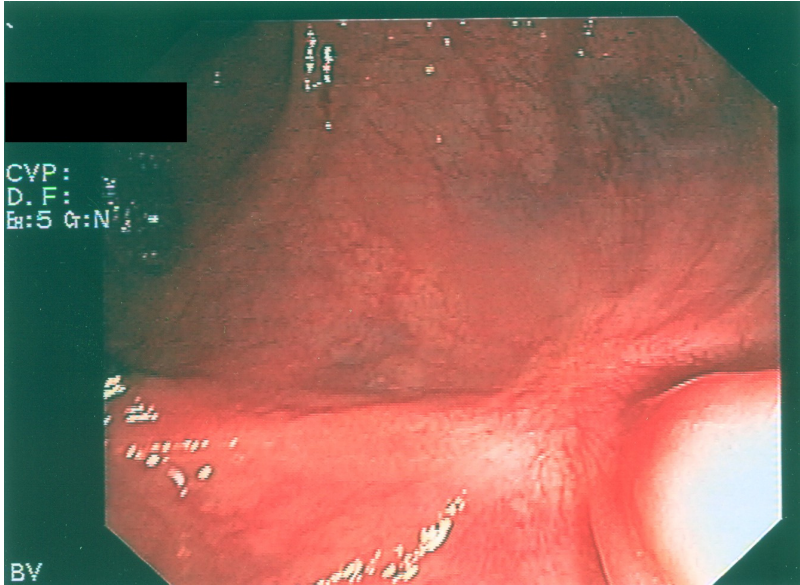


Fig 3.

