

Incorrect catheter placement for drainage of malignant pericardial effusion

Muršić, Davorka; Koršić, Marta; Badovinac, Sonja; Muršić, Miroslav; Jakopović, Marko; Samaržija, Miroslav

Source / Izvornik: **The Lancet Oncology, 2016, 17**

Journal article, Accepted version

Rad u časopisu, Završna verzija rukopisa prihvaćena za objavljivanje (postprint)

[https://doi.org/10.1016/S1470-2045\(16\)30445-4](https://doi.org/10.1016/S1470-2045(16)30445-4)

Permanent link / Trajna poveznica: <https://urn.nsk.hr/urn:nbn:hr:105:157095>

Rights / Prava: [In copyright](#) / [Zaštićeno autorskim pravom.](#)

Download date / Datum preuzimanja: **2025-01-28**



Repository / Repozitorij:

[Dr Med - University of Zagreb School of Medicine
Digital Repository](#)





Središnja medicinska knjižnica

Muršić D., Koršić M., Badovinac S., Muršić M., Jakopović M., Samaržija M. (2016) *Incorrect catheter placement for drainage of malignant pericardial effusion*. *The Lancet Oncology*, 17 (10). pp. e467. ISSN 1470-2045

<http://www.elsevier.com/locate/issn/14702045>

<http://www.sciencedirect.com/science/journal/14702045>

[https://doi.org/10.1016/S1470-2045\(16\)30445-4](https://doi.org/10.1016/S1470-2045(16)30445-4)

<http://medlib.mef.hr/2764>

University of Zagreb Medical School Repository

<http://medlib.mef.hr/>

Incorrect catheter placement for drainage of malignant pericardial effusion

Davorka Muršić¹, Marta Koršić¹, Sonja Badovinac¹, Miroslav Muršić², Marko Jakopović¹,
Miroslav Samaržija¹

¹University Hospital Centre Zagreb, Clinic for Lung Diseases Jordanovac, Jordanovac 104,
10000 Zagreb, Croatia

²University Hospital Centre Zagreb, Department of Diagnostic and Interventional Radiology,
Kišpatićeva 12, 10000 Zagreb, Croatia

Davorka Muršić, davorka.mursic@gmail.com, telephone number: +38512385145, fax
number: +38512385388

A 43-year-old woman, who was a non-smoker and who had been previously identified as having malignant pericardial effusion and a PET scan suggestive of a primary malignant tumour in the left upper lobe of the lung with mediastinal lymphadenopathy was referred to the emergency department at the University Hospital Centre Zagreb in December, 2012, because of progressive dyspnoea. Chest radiography obtained on admission showed substantial enlargement of the cardiac silhouette. Echocardiography pointed to pre-tamponade. The patient underwent pericardial drainage and 2000 mL of haemorrhagic fluid was evacuated. After 24h, the patient had a substantial loss of red blood cells and became hypotensive. Control echocardiogram showed the tip of the drainage pericardial catheter was inside the heart, in the right ventricle, with signs of pre-tamponade still present indicating erroneous placement of the catheter. Redrainage of the pericardium was done and a preoperative CT angiography scan revealed two drainage catheters, one positioned with its tip in the pericardium and the other entering the right ventricle of the heart, going through it and into the main pulmonary artery, with its tip located in the proximal segment of left main pulmonary artery (figure). The patient underwent surgery and the incorrectly positioned drainage pericardial catheter was removed with no complications. After clinical stabilisation of the patient, further pulmonary diagnostic tests led to the diagnosis of metastatic lung adenocarcinoma. An initial test of pericardial effusion showed adenocarcinoma cells that were CK7 and TTF-1 positive and CK20 negative, which is compatible with a diagnosis of primary pulmonary adenocarcinoma. Molecular testing showed positive EGFR mutation (exon 19 deletion). The patient received 150 mg erlotinib once-daily, and her overall survival was 30 months.

Contributors

DM, MK and SB were clinicians in management of the patient's malignant pericardial effusion. MM interpreted medical images. MJ and MS were consultants in the patient's care. All authors contributed to the preparation and writing of the manuscript and approved the final manuscript.

Declaration of interests

The authors declared no conflicts of interest.

Acknowledgments

There was no funding source. The corresponding author had full access to all the data in the study and had final responsibility for the decision to submit for publication.

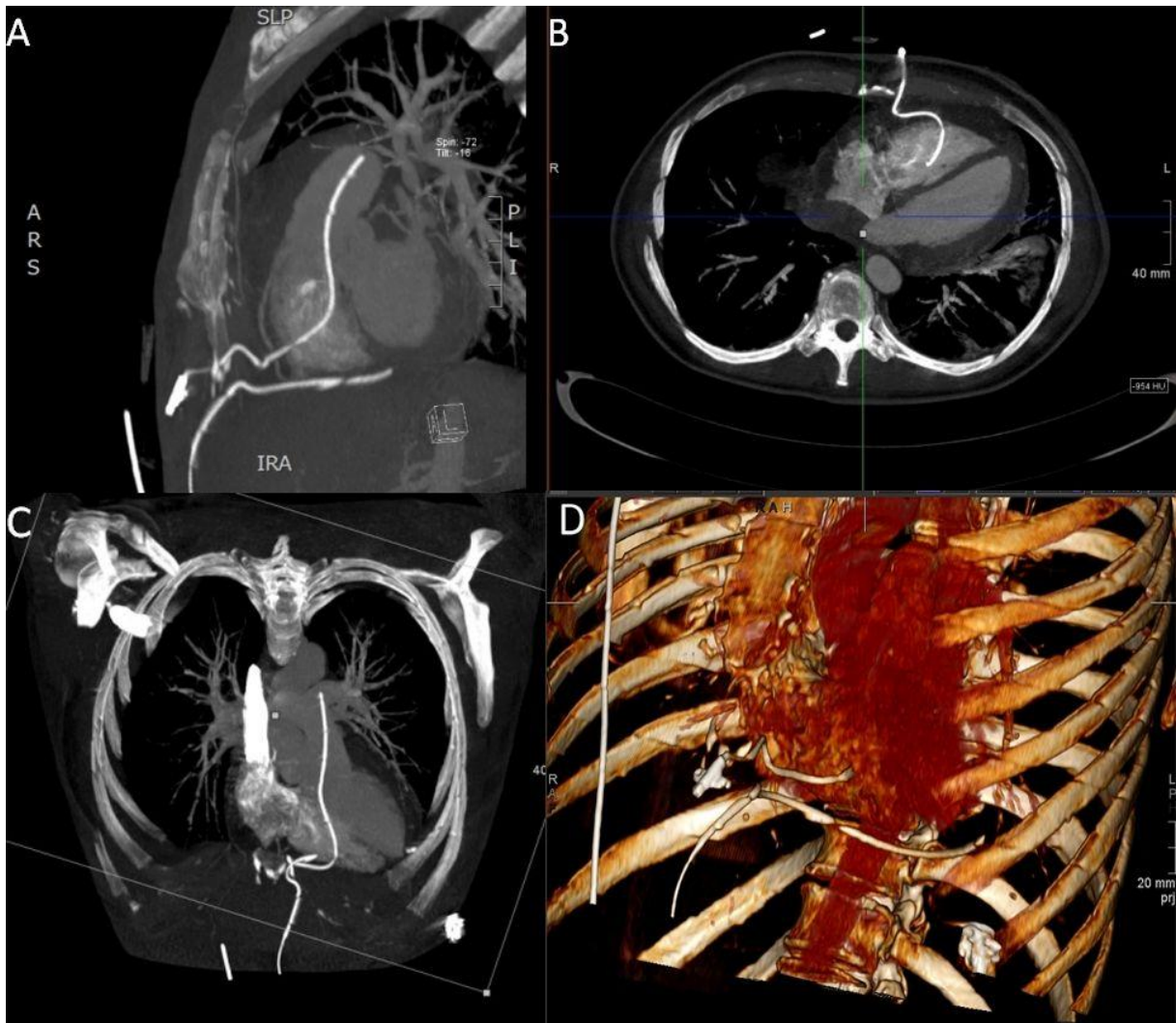


Figure: CT angiography scan

Two drainage catheters, one positioned with its tip in the pericardium, and the other one entering the right ventricle of the heart, going through it and in the main pulmonary artery, with its tip located in the proximal segment of left main pulmonary artery (Panel A shows the sagittal view, Panel B the axial view, Panel C the coronal view, and Panel D 3D volume rendered image)