

Croatian rotatory oblique three-dimensional osteotomy (CROTO) - a modified Wilson's osteotomy for adult hallux valgus intended to prevent dorsal displacement of the distal fragment and to reduce short ...

Kolundžić, Robert; Mađarević, Mladen; Trkulja, Vladimir; Crnković, Tomislav; Šmigovec, Igor; Matek, Daniel

Source / Izvornik: *Medicinski glasnik*, 2017, 14, 250 - 256

Journal article, Published version

Rad u časopisu, Objavljena verzija rada (izdavačev PDF)

<https://doi.org/10.17392/903-17>

Permanent link / Trajna poveznica: <https://um.nsk.hr/um:nbn:hr:105:460896>

Rights / Prava: [In copyright](#)/[Zaštićeno autorskim pravom.](#)

Download date / Datum preuzimanja: **2025-02-27**



Repository / Repozitorij:

[Dr Med - University of Zagreb School of Medicine Digital Repository](#)



Croatian rotatory oblique three-dimensional osteotomy (CROTO) – a modified Wilson’s osteotomy for adult hallux valgus intended to prevent dorsal displacement of the distal fragment and to reduce shortening of the first metatarsal bone

Robert Kolundžić^{1,5}, Mladen Mađarević², Vladimir Trkulja³, Tomislav Crnković^{4,5}, Igor Šmigovec², Daniel Matek²

¹Department of Trauma surgery, University Hospital Centre “Sestre Milosrdnice”, ²Department of Orthopaedic Surgery, University Hospital Centre, ³School of Medicine, Zagreb University; Zagreb, ⁴Department of Orthopaedic and Trauma Surgery, County General Hospital, Požega, ⁵School of Medicine, Josip Juraj Strossmayer University Osijek, Osijek; Croatia

ABSTRACT

Aim To evaluate biomechanical and clinical outcomes of a newly developed modification of the Wilson’s osteotomy for hallux valgus: a three-dimensional subcappital correction of the metatarsal head position with a simultaneous lateral and plantar shift with derotation intended to reduce displacement of the distal fragment and shortening of the first metatarsal bone.

Methods Thirty four feet (28 female patients) underwent the new procedure and were evaluated before and 12 to 84 months (median=25.5) after the surgery.

Results Plantar shift of the distal fragment was achieved in all feet. Shortening of the first metatarsal was moderate: ≤6 mm in 32/34 feet, 7 and 10 mm in the remaining two. Median difference in metatarsal index post- vs. pretreatment was -4.0. The hallux valgus angle, intermetatarsal and distal metatarsal articular angles were reduced in all feet. The American Orthopaedic Foot and Ankle Society score improved in all feet (median increase= 51.5).

Conclusion The method allows for a lateral and plantar shift with derotation of the distal fragment and a mild/moderate shortening of the first metatarsal bone.

Key words: hallux valgus, surgery, metatarsal

Corresponding author:

Robert Kolundžić
Department of trauma surgery, University Hospital Centre “Sestre Milosrdnice”
Draškovićeva 19 10000 Zagreb, Croatia
Phone: +385 98 382 519;
+3851 4697000;
Fax: +385 1 4610 365;
E-mail: robert.kolundzic@zg.t-com.hr
ORCID: <http://www.orcid.org/0000-0001-7008-6979>

Original submission:

21 March 2017;

Revised submission:

31 March 2017;

Accepted:

27 June 2017.

doi: 10.17392/903-17

Med Glas (Zenica) 2017; 14(2): 250-256

INTRODUCTION

Hallux valgus is a common clinical problem (1-4). More than 130 different surgical methods have been described for correction of hallux valgus since the first description of surgery of bunions in 1871, and osteotomies of the first metatarsal bone have been described in various ways and sites (5-10). However, there has been no compelling evidence of advantages of any of these methods over any other particular type of surgery (11).

Metatarsalgia is one of the late complications of osteotomy procedures caused by a shift of the forefoot load distribution towards the lesser metatarsals, which is attributed to shortening of the first metatarsal and dorsal displacement of the distal fragment (5,6). Osteotomy of the first metatarsal bone as described by Wilson is an established procedure for the treatment of the adult hallux valgus. It is fast and easy to perform, and we have been using it for a number of years. A drawback of Wilson's osteotomy is shortening of the first metatarsal bone (3). Here we describe and present the first results of a modified technique – a three-dimensional subcapital correction of the metatarsal head position with a simultaneous lateral and plantar shift with derotation that we developed with the intention to prevent dorsal displacement of the distal fragment and to reduce shortening of the first metatarsal bone and its consequences, while keeping the procedure simple.

PATIENTS AND METHODS

Patients

The study included 34 feet in 28 consecutive female patients presented at the Department of Orthopaedic Surgery, University Hospital Centre Zagreb, in the period between January 2004 and June 2007 who gave a written consent to be treated by the new method after being informed about the details of the procedure. Ethics Committee at the University Hospital Centre Zagreb approved the use of the method.

Surgical treatment was indicated when the following criteria were cumulatively met: hallux valgus angle >20 degrees, intermetatarsal angle >10 degrees, negative metatarsal index and pain due to pressure over the medial side of the first metatarsophalangeal joint.

Methods

Operative procedure and postoperative care.

All surgeries were performed by the same surgeon under spinal anaesthesia with a pneumatic high-thigh tourniquet. For the procedure, a short (3 to 5 cm) medial longitudinal skin incision was made over the head of the first metatarsal bone. The capsule was incised medially in a U fashion, with the capsule flap based distally. A bunion was removed using chisel. Oblique osteotomy of the metatarsal head was performed through the metaphysis using a thin 2.5 mm bade on air powered oscillator (Synthes, Switzerland). The osteotomy was made from the medial distal part of the bone towards the lateral proximal part, as seen in the horizontal plane, at an angle of 25 degrees on the line perpendicular to the metatarsal shaft (Figure 1). At the same time, in the sagittal plane, the osteotomy was made from the distal dorsal towards the proximal plantar part of the bone at an angle of 15 degrees (Figure 1A). Therefore, it allowed for a correction of the metatarsal head position with a simultaneous plantar shift (Figure 1B) and the distal fragment could be rotated if necessary (Figure 1C).

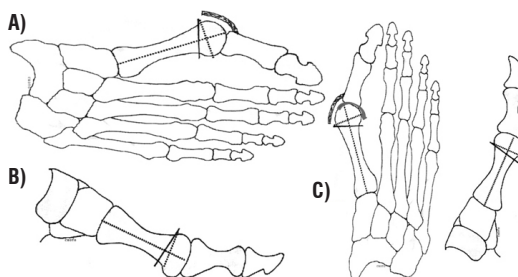


Figure 1. First metatarsal bone osteotomy scheme in A) horizontal and B) sagittal plane and C) the way of derotation. Dotted lines represent diaphyseal lines, full lines represent osteotomy (Kolundžić R., 2004)

The amount of shift was set as the width of a plantar cortex. Osteotomy angles were set arbitrarily. The fragments were fixed using one Kirschner wire inserted from distal to proximal in a paraosteal position in relation to the hallux and the head of the first metatarsal and then into the dorsomedial part of the medullary canal of the first metatarsal bone, driven as far as the base of the first metatarsal for better stabilization (Figure 2). The head position and the osteotomy site checked and capsulorrhaphy was performed followed by a skin suture. Elastic bandage was applied. Three days postoperatively, the bandage

was removed and replaced by plaster boots with heels adjusted for walking that were used for the next five weeks. After the plaster boot removal, Kirschner wire was removed and range-of-movement (ROM) exercises of metatarsophalangeal joints commenced. Gradually, full weight bearing was allowed after eight weeks.

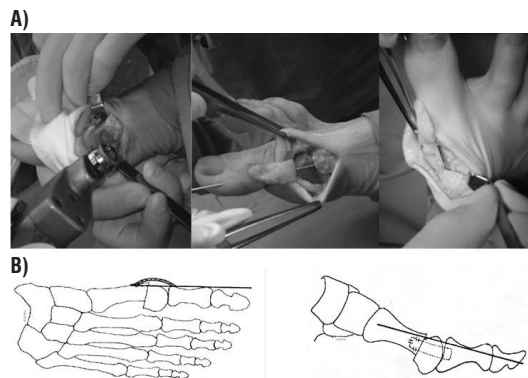


Figure 2. A) Intra-operative photographs: oscillator used to perform the osteotomy (left), Kirschner wire in place, lateral view (middle), Kirschner wire in place, anteroposterior view (right); B) Schematic representation of postoperative correction with Kirschner wire in place in horizontal and sagittal plane (Kolundžić R., 2004)

Patient evaluation. All patients and feet were evaluated radiologically and clinically before and minimum 12 months after the treatment by the same observer. The technique used for securing standardized X-rays was anteroposterior, lateral and sesamoid skyline views.

Anteroposterior (AP) weight bearing views were obtained with the patient standing on a shallow inverted wooden tray placed on the floor, just big enough to contain and protect the grid cassette, with feet 3 cm apart. With a source-to-film distance of 100 cm, the ray is directed 15 degrees backward, towards the hindfoot and is centered midway between the navicular bones. Non-weight bearing lateral oblique views were taken with the patient sitting on the standard couch with the foot rolled 15 degrees inward on a grid cassette placed on the floor. The beam is directed vertically at the centre of the cuboid from a source positioned 100 cm away. For the radiological assessment, pre- and postoperative radiographs of the forefoot were scanned and analysed using custom-designed computer software (Delphi, Visual Pascal – Borland Software Corporation, Austin, Texas, USA). The following parameters were determined: length of the first metatarsal,

hallux valgus angle, first intermetatarsal angle, metatarsal index, distal metatarsal articular angle, position of the sesamoid bone and the amount of the sagittal shift (in millimeters) (only postoperatively). The axes of the first metatarsal, second metatarsal and the proximal phalanx were drawn by bisecting the diameters of their bases and joining the central points (12). Length of the first metatarsal on AP radiographs was determined by measuring the first metatarsal axis from the base to the tip of the metatarsal head. Hallux valgus angle (HVA) and first intermetatarsal angle (IMTA) were measured as described by Millner (13) and Schneider et al. (14,15). Metatarsal index (MTI) is a measurement of relative metatarsal protrusion on AP radiographs. It was determined by measurements in arcs centered on the transverse tarsal line as described by Hardy and Clapham (16). Distal metatarsal articular angle (DMA) was measured as described by Gudas and Marcinko (17). The position of the sesamoid bone was classified into 4 levels according to Smith et al. (18). The amount of the sagittal shift was measured on lateral radiographs as a distance between 2 parallel lines, one drawn on the dorsal cortex of the proximal and the other drawn on the dorsal cortex of the distal fragment of first metatarsal bone. For clinical evaluation, the status of the forefoot was assessed using the American Orthopaedic Foot and Ankle Society (AOFAS) classification, i.e. the Hallux Metatarsophalangeal-Interphalangeal Scale system (Table 1) (19).

Table 1. Preoperative and postoperative values (median, range) of radiological findings and of the American Orthopaedic Foot and Ankle Society (AOFAS) scores and differences between postoperative and preoperative (“post-pre”) values with 95% confidence intervals (CI) (N= 34)

Parameter	Preoperatively	Postoperatively	Difference (95% CI)*	p
Length of 1st metatarsal bone (mm)	64 (55 to 70)	60 (52 to 66)	-4.0 (-4.5 to -3.0)	<0.001
Hallux valgus angle (degrees)	35 (20 to 50)	15.5 (0 to 35)	-18.5 (-22.5 to -15)	<0.001
Intermetatarsal angle (degrees)	15 (10 to 22)	5 (2 to 15)	-9.0 (-10 to -7.5)	<0.001
Metatarsal index	-2 (-6 to 4)	-4 (-10 to -1)	-4.0 (-4.5 to -3.0)	<0.001
Distal metatarsal articular angle (degrees)	15 (1 to 30)	9 (1 to 25)	-6.0 (-8.5 to -3.0)	<0.001
AOFAS score	44 (14 to 78)	95 (64 to 95)	51.5 (45.5 to 59.0)	<0.001

*Median difference with two-sided p-value from the Wilcoxon signed ranks test

Statistical analysis

Individual data and summary statistics on patients' demographics and pre- and postoperative radiological and clinical findings are presented. Differences between the postoperative and preoperative ("post – pre" difference) radiological parameters and clinical status scores are shown as median differences with the approximate 95% (exact 97.6%) confidence intervals (CI) calculated using the binomial method.

RESULTS

Thirty-four feet in 28 patients were operated-on (median age at surgery 44 years, range 19 to 58) and were evaluated before surgery and after a median follow-up of 25.5 months (range 12 to 84) at median age of 46 years (range 20 to 60). The sagittal shift of the first metatarsal was achieved in all feet and varied from 1-9 mm (median 3 mm). The first metatarsal was shorter after than before the operation in all feet with a median difference of -4 mm (Table 1), but the shortening never exceeded 10 mm. Distribution of feet regarding the shortening was: -1 mm, n=5; -2 mm, n=6; -3 mm, n=4; -5 mm, n=7; -6 mm, n=6; -7 mm, n=1 and -10 mm, n=1. The foot with a 10 mm (excessive) shortening of the first metatarsal (patient No. 14, foot No. 16) presented with an overall "fair" clinical status based on the AOFAS score at follow-up. It was painful with limitation of activities and motion restriction in the first metatarsophalangeal joint (Figure 3A). At follow-up, the metatarsal index was lower than before the treatment in 31/34 feet and the median "post-pre" difference was -4.0 (Table 1). The hallux valgus angle and the intermetatarsal angle were reduced by the surgery in all feet, with median "post-pre" differences being -18.5 and -9 degrees, respectively (Table 1). Typical pre-operative and post-operative X-ray findings are depicted in Figure 4. The AOFAS score illustrating clinical status was higher at follow-up than before treatment in all feet, with a median "post-pre" difference of 51.5 points (Table 1). Clinical status level improved in 33/34 feet, most frequently from "poor" to "excellent" (Table 2). The clinical status was graded "fair" only for the mentioned foot with a 10 mm shortening of the first metatarsal. In one foot for which the clinical status level remained "poor", the AOFAS score improved from 49 to 64 points. The "poor" result was due to metatar-

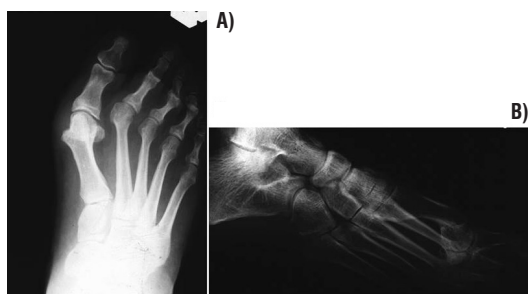


Figure 3. Postoperative complication: A) excessive shortening of the first metatarsal bone (Patient No. 14, foot No. 16), B) metatarsal head dislocation (Patient No. 22, foot No. 26) (Kolundžić R., 2008)

Table 2. Pre- to post-surgical "transition" of the overall clinical status and sesamoid bone position by foot (N= 34)

AOFAS clinical status		Position of the sesamoid bone					
Pre-surgery	n	Post-surgery	n	Pre-surgery	n	Post-surgery	n
Poor	33 →	Excellent	25	Severely rotated	15 →	No rotation	4
		Good	6			Slightly rotated	10
		Fair	1			Moderately rotated	1
		Poor	1	Moderately rotated	9 →	No rotation	9
Fair	1 →	Excellent	1	Slightly rotated	10 →	Slightly rotated	8
						No rotation	2
Total	34		34		34		34

AOFAS, American Orthopaedic Foot and Ankle Society

tively (Table 1). Typical pre-operative and post-operative X-ray findings are depicted in Figure 4. The AOFAS score illustrating clinical status was higher at follow-up than before treatment in all feet, with a median "post-pre" difference of 51.5 points (Table 1). Clinical status level improved in 33/34 feet, most frequently from "poor" to "excellent" (Table 2). The clinical status was graded "fair" only for the mentioned foot with a 10 mm shortening of the first metatarsal. In one foot for which the clinical status level remained "poor", the AOFAS score improved from 49 to 64 points. The "poor" result was due to metatar-

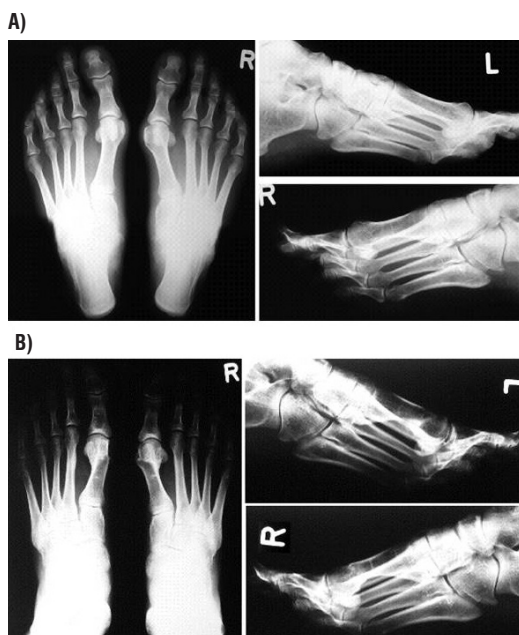


Figure 4. A) X-ray of both feet under load before corrective osteotomy of the first metatarsal bone (Patient No. 11, feet 11 and 12); B) X-ray of both feet under load 5 years postoperatively (Patient No. 11, feet 11 and 12) (both feet left, right left feet right above, right feet right below) (Kolundžić R., 2011)

sal head dislocation followed by a malunion (patient No. 22, foot No. 26) (Figure 3B).

There were no infections and no nonunions at the osteotomy site. We observed delayed union in one patient. Superficial skin irritation by the Kirschner wire occurred in one foot. A variable level of derotation of the sesamoid bone was achieved in all feet (Table 2).

DISCUSSION

A number of techniques (with a variety of modifications) are available for surgical treatment of the adult hallux valgus, but it appears that there is no equivocal evidence of advantages of any of these methods over any other particular type of surgery (11). Metatarsalgia and calluses are apparently the major late complications of surgical procedures and are due to a shift of the forefoot load distribution towards the lesser metatarsals, which is attributed to shortening of the first metatarsal and dorsal displacement of the distal fragment (5-11, 20). Merkel has suggested that the first metatarsal shortening greater than 10 mm is likely to result in a higher degree of patients' dissatisfaction and an increased frequency of metatarsalgia (20). Wilson's osteotomy is an established procedure for treatment of the adult hallux valgus. It is fast and easy to perform and we have been using it routinely for a number of years. It does, however, result in a shortening of the first metatarsal (13, 21-25). We have developed a simple modified technique that includes a three-dimensional subcapital correction of the metatarsal head position with a simultaneous plantar shift intended to prevent dorsal displacement of the distal fragment and to compensate for the metatarsal shortening. Magnan and Pezze described a similar percutaneous technique (26). Their method allows for a good lateral displacement of the first metatarsal head but does not allow for a plantar shift of the distal fragment. Xarchas et al. have described a similar method of the lateral and plantar shifting, but without the derotation of the head of the metatarsal bone (8). They also use a K-wire for fixation, but so that the wire is placed through the head of the metatarsal bone into the diaphysis. The advantage of our technique is that we place the K-wire in parallel with the proximal phalanx and over the surface after the bunionectomy. Furthermore, with the derotation of the head of the metatarsal bone we achieve additional balancing of the muscles and

of the ligamentous-sesamoid complex. The present data suggest that our open osteotomy indeed allows for a plantar shift and the amount of the first metatarsal shortening achieved in the present series could be considered moderate – it was ≤ 6 mm in 32/34 feet (7 mm and 10 mm in the remaining two), with a median shortening of 4 mm. Madarevic et al. reported a mean shortening of 5.5 mm in 28 feet treated by the standard Wilson's procedure (24). A similar mean shortening (5.1 mm, range 1 to 11.5 mm) with this method (but with a reduced osteotomy angle) was reported for a series of 46 feet by Yildirim et al. (25). Klosok et al. (23) reported an average 10 mm (range 6 to 20 mm) shortening in a series of 37 feet, whereas Klaeskov et al. (22) reported a mean shortening of 8 mm in a 77-feet series and Pouliart et al. (27) reported a 8.5 mm mean shortening in a 32-feet series. Grace et al. (21) summarized three older studies on Wilson's osteotomy (published prior to 1981) and calculated an overall mean shortening of 7.8 mm for a total of 118 feet.

Taking into account the mentioned published data that refer to a total of 338 feet, an n-weighted mean shortening of 7.6 mm could be calculated. An approximate comparison to the median shortening of 4 mm reported in the present series (the mean value was 3.97 mm) suggests that the described method apparently achieved its main purpose of reducing the first metatarsal shortening. The method also appears to perform well in respect to standard clinical (AOFAS score and clinical status) and other radiological (relevant angles) criteria. A single "poor" result according to AOFAS score in one patient was due to metatarsal head dislocation followed by a malunion, whilst a single "fair" result according to AOFAS score in another patient was due to excessive (10 mm) shortening of the first metatarsal bone. However, whether or not this method indeed confers radiological (primarily the first metatarsal shortening) and clinical benefits (reduced incidence and/or severity of metatarsalgia) over other established methods is yet to be evaluated in prospective randomized trials.

FUNDING

No specific funding was received for this study.

TRANSPARENCY DECLARATION

Conflicts of interest: None to declare

REFERENCES

1. Coughlin M. Hallux valgus. *J Bone Joint Surg Am* 1998; 78:932-66.
2. Donley BG, Tisdell CL, Sferra JJ, Hall JO. Diagnosing and treating hallux valgus: a conservative approach for a common problem. *Cleve Clin J Med* 1997; 64:469-74.
3. Kilmartin TE, Wallace WA. The etiology of hallux valgus: a critical review of the literature. *Foot* 1993; 3:157-67.
4. Vanore JV, Christensen JC, Kravitz SR, Schubert JM, Thomas JL, Wei LS, Zlotoff HJ, Mendicino RW, Couture SD. Clinical practice guideline. First metatarsophalangeal joint disorders. Joint disorders panel of the American college of foot and ankle surgeons. Diagnosis and treatment of first metatarsophalangeal joint disorders. Section 1: Hallux valgus. *J Foot Ankle Surg* 2003; 42:112-23.
5. Helal B. Surgery for adolescent hallux valgus. *Clin Orthop* 1981; 157:50-63.
6. Helal B, Gupta SK, Gojasević P. Surgery for adolescent hallux valgus. *Acta Orthop Scand* 1974; 45:271-95.
7. Guler O, Yilmaz B, Mutlu S, Cerci MH, Heybeli N. Distal oblique metatarsal osteotomy for hallux valgus deformity: a clinical analysis. *J Foot Ankle Surg* 2017; 56:497-504.
8. Xarchas KC, Mavroliadis D, Kyriakopoulos G. Modified Wilson's Osteotomy for hallux valgus deformity. A new approach. *Open Orthop J* 2014; 8:361-7.
9. Ben-Ad R. Fixation updates for hallux valgus correction. *Clin Podiatr Med Surg* 2014; 31:265-79.
10. Chandler LM. First metatarsal head osteotomies for the correction of hallux abducto valgus. *Clin Podiatr Med Surg* 2014; 31:221-31.
11. Ferrari J, Higgins JP, Prior TD. Interventions for treating hallux valgus (abductovalgus) and bunions. *Cochrane Database Syst Rev* 2004; 1:CD000964.
12. Venning P, Hardy RH. Sources of error in the production and measurement of standard radiographs of the foot. *Br J Radiol* 1951; 24:18-26.
13. Miller JW. Distal first metatarsal displacement osteotomy: its place in the schema of bunion surgery. *J Bone Joint Surg Am* 1974; 56-A:923-31.
14. Schneider W, Csepan R, Knahr K. Reproducibility of the radiographic metatarsophalangeal angle in hallux surgery. *J Bone Joint Surg Am* 2003; 85-A:949-59.
15. Schneider W, Knahr K. Metatarsophalangeal and intermetatarsal angle: different values and interpretation of postoperative results dependent on the technique of measurement. *Foot Ankle Int* 1998; 19:532-36.
16. Hardy RH, Clapham JCR. Observations on hallux valgus. *J Bone Joint Surg Br* 1951; 33:376-91.
17. Gudas CJ, Marcinko DE. The complex deformity known as hallux abductor valgus. In: Marcinko DE, ed. *Comprehensive textbook of hallux valgus reconstruction*. St Louis: Mosby 1992, 1-17.
18. Smith RW, Reynolds JC, Stewart MJ. Hallux valgus assessment: report of Research Committee of American Orthopaedic Foot and Ankle Society. *Foot Ankle* 1984; 5:92-103.
19. Kitaoka HB, Alexander IJ, Adelaar RS, Nunley JA, Myerson MS, Sanders M. Clinical rating system for the ankle-hindfoot, midfoot, hallux and lesser toes. *Foot Ankle Int* 1994; 15:349-53.
20. Merkel KD, Katoh Y, Johnson EW Jr, Chao EY. Mitchell osteotomy for hallux valgus: Long term follow-up and gait analysis. *Foot Ankle* 1983; 3:189-96.
21. Grace D, Hughes J, Klenerman LA. A comparison of Wilson and Hohmann osteotomies in the treatment of hallux valgus. *J Bone J Surg Br* 1988; 70-B: 236-41.
22. Klareskov B, Dalsgaard S, Gebuhr P. Wilson shaft osteotomy for hallux valgus. *Acta Orthop Scand* 1988; 59:307-9.
23. Klosok JK, Pring DJ, Jessop JH, Maffulli N. Chevron or Wilson metatarsal osteotomy for hallux valgus. A prospective randomized trial. *J Bone J Surg Br* 1993; 75-B:825-29.
24. Madarević M, Kolundžić R, Matek D, Šmigovec I, Crnković T, Trkulja V. Mitchell and Wilson metatarsal osteotomies for the treatment of hallux valgus: comparison of outcomes two decades after the surgery. *Foot Ankle Int* 2006; 27:877-82.
25. Yildirim Y, Saygi B, Aydin N, Cabukoglu C, Bautista S. Components of the Wilson osteotomy that are effective on hallux valgus repair. *J Foot Ankle Surg* 2007; 46:21-6.
26. Magnan B, Pezze L, Rossi N, Bartolozzi P. Percutaneous distal metatarsal osteotomy for correction of hallux valgus. *J Bone J Surg Am* 2005; 87:1191-99.
27. Pouliart N, Haentjens P, Opdecam P. Clinical and radiographic evaluation of Wilson osteotomy for hallux valgus. *Foot Ankle* 1996; 17:388-94.

Hrvatska modifikacija Wilsonove osteotomije za liječenje haluks valgusa u odraslih: rotatorna kosa trodimenzionalna osteotomija u svrhu prevencije doraznog pomaka distalnog ulomka i skraćanja prve metatarzalne kosti

Robert Kolundžić^{1,5}, Mladen Mađarević², Vladimir Trkulja³, Tomislav Crnković^{4,5}, Igor Šmigovec², Daniel Matek²

¹Klinika za traumatologiju, Klinički bolnički centar "Sestre milosrdnice, Zagreb, ²Klinika za ortopediju, Klinički bolnički centar "Zagreb", Zagreb, ³Medicinski fakultet Sveučilišta u Zagrebu, Zagreb, ⁴Odjel za ortopediju i traumatologiju, Županijska opća bolnica Požega, Požega, ⁵Medicinski fakultet Sveučilišta Josip Juraj Strossmayer, Osijek; Hrvatska

SAŽETAK

Cilj Procijeniti biomehaničke i kliničke rezultate nove modifikacije Wilsonove osteotomije za liječenja haluks valgusa: trodimenzionalne subkapitalne korekcije položaja glave prve metatarzalne kosti s istodobnim lateralnim i plantarnim pomakom s derotacijom u svrhu prevencije pomaka distalnog ulomka i skraćanja prve metatarzalne kosti.

Metode Novom su metodom operirana 34 stopala u 28 žena, a evaluirana su prije operacije i 12 do 84 mjeseca nakon operacije (medijan=25.5 tjedana).

Rezultati Plantarni pomak distalnog fragmenta ostvaren je u svim stopalima pri čemu je skraćanje prve metatarzalne kosti bilo umjereno: ≤6 mm u 32/34 stopala i 7 i 10 mm u preostala dva. Medijan-razlika metatarzalnog indeksa, nakon zahvata u odnosu na stanje prije zahvata, iznosio je -4.0. Kut haluks valgusa, intermetatarzalni kut i kut distalnog metatarzalnog zgloba smanjeni su u svim stopalima. Skor Američkog društva za stopalo i skočni zglob povećan je u svim stopalima (medijan povećanja=51.5).

Zaključak Metoda omogućuje plantarni i lateralni pomak distalnog ulomka, uz derotaciju i blago do umjereno skraćanje prve metatarzalne kosti.

Ključne riječi haluks valgus, operacija, metatarzalna kost