

Successful treatment of genotype 3 hepatitis C infection in a noncirrhotic HIV infected patient on chronic dialysis with the combination of sofosbuvir and velpatasvir

Begovac, Josip; Krznarić, Juraj; Bogdanić, Nikolina; Močibob, Loris; Zekan, Šime

Source / Izvornik: **Medicine, 2018, 97**

Journal article, Published version

Rad u časopisu, Objavljena verzija rada (izdavačev PDF)

<https://doi.org/10.1097/MD.0000000000013671>

Permanent link / Trajna poveznica: <https://urn.nsk.hr/urn:nbn:hr:105:507305>

Rights / Prava: [In copyright](#) / [Zaštićeno autorskim pravom.](#)

Download date / Datum preuzimanja: **2024-10-14**



Repository / Repozitorij:

[Dr Med - University of Zagreb School of Medicine Digital Repository](#)



Successful treatment of genotype 3 hepatitis C infection in a noncirrhotic HIV infected patient on chronic dialysis with the combination of sofosbuvir and velpatasvir

A case report

Josip Begovac, MD, PhD^{a,b,*}, Juraj Krznarić, MD^a, Nikolina Bogdanić, MD^a, Loris Močibob, MD^a, Šime Zekan, MD^{a,b}

Abstract

Rationale: Data on anti-HCV therapy in patients on dialysis is still evolving. Sofosbuvir is mainly eliminated through the renal route and there is controversy about its use in these patients.

Patient concerns: We describe a 53-year-old male patient with HCV genotype 3 and human immunodeficiency type 1 (HIV) infection on chronic dialysis. HIV infection was diagnosed in 1987 and since July 2007 the patient was compliant with his antiretroviral therapy (ART) and had an undetectable plasma HIV viral load on all follow-up measurements. The patient was known to have HCV infection since 1997 but has never been treated for chronic hepatitis C. Because of progressive renal impairment dialysis started in 2005.

Diagnosis: Before anti-HCV treatment commenced the patient liver transient elastography (FibroScan) indicated F3 fibrosis (stiffness, 11.6 kPa) and his HCV RNA viral load was 320,798 IU/mL (Abbott RealTime HCV assay).

Intervention: Fixed dose combination of sofosbuvir/velpatasvir (400 mg/100 mg) for 11 weeks.

Outcomes: Twelve weeks after treatment cessation HCV RNA was undetectable, hence the patient achieved a sustained virologic response. The drugs were well tolerated and the patient did not report any side effects.

Lessons: Sofosbuvir/velpatasvir may be an option for HCV genotype 3 infection in patients coinfecting with HIV on long-term dialysis.

Abbreviations: ART = antiretroviral therapy, HCV = hepatitis C virus, HIV = human immunodeficiency virus, PCR = polymerase chain reaction, RNA = ribonucleic acid, SVR12 = sustained virological response 12 weeks after treatment.

Keywords: dialysis, hepatitis C, HIV, sofosbuvir, velpatasvir

1. Introduction

With direct-acting antivirals, hepatitis C virus (HCV) infection can be successfully treated in almost 100% of persons. Limited clinical experience with the use of sofosbuvir in patients with

HCV genotype 1 with impaired renal function or on dialysis has been previously reported.^[1–4] The real-world longitudinal HCV-TARGET study evaluated the use of sofosbuvir-containing regimens in patients with mild to severe renal dysfunction and sustained virological response 12 weeks after treatment (SVR12) was similar in all groups (82%–83%).^[5] However, in this study only 5 patients were on dialysis, velpatasvir was not used and none of the patients were coinfecting with human immunodeficiency virus (HIV). Hence, data on the safety and efficacy of anti-HCV therapy in patients on dialysis is still evolving, particularly for the treatment of HCV genotype 3 in HIV coinfecting persons.

2. Case report

We describe a 53-year-old HIV positive male on chronic hemodialysis, coinfecting with HCV genotype 3 who was successfully treated for hepatitis C using the combination of sofosbuvir/velpatasvir. The diagnosis of HIV infection was made in 1987 and HCV infection was documented in May 1997. His first HCV viral load was done in April 2000, the patient had 536,000 IU/mL HCV RNA (Cobas Amplicor HCV Monitor test, v2.0, Roche Switzerland). Antiretroviral combination therapy (ART) with stavudine, lamivudine, and indinavir was initiated in December 1999. However, the patient had a gap in care from

Editor: N/A.

Funding: This study was partially supported by the Croatian Science Foundation (project no. IP-2014–09–4461 principal investigator: Josip Begovac).

The authors have no conflicts of interest to disclose.

^a University Hospital for Infectious Diseases “Dr. Fran Mihaljević”, ^b University of Zagreb School of Medicine, Zagreb, Croatia.

* Correspondence: Josip Begovac, University of Zagreb School of Medicine and University Hospital for Infectious Diseases “Dr. Fran Mihaljević”, Zagreb, Croatia, Mirogojska 8, 10000, Zagreb. (e-mail: jbegovac@bfm.hr, josip.begovac@gmail.com).

Copyright © 2018 the Author(s). Published by Wolters Kluwer Health, Inc. This is an open access article distributed under the terms of the Creative Commons Attribution-Non Commercial-No Derivatives License 4.0 (CCBY-NC-ND), where it is permissible to download and share the work provided it is properly cited. The work cannot be changed in any way or used commercially without permission from the journal.

Medicine (2018) 97:51(e13671)

Received: 10 August 2018 / Accepted: 21 November 2018

<http://dx.doi.org/10.1097/MD.0000000000013671>

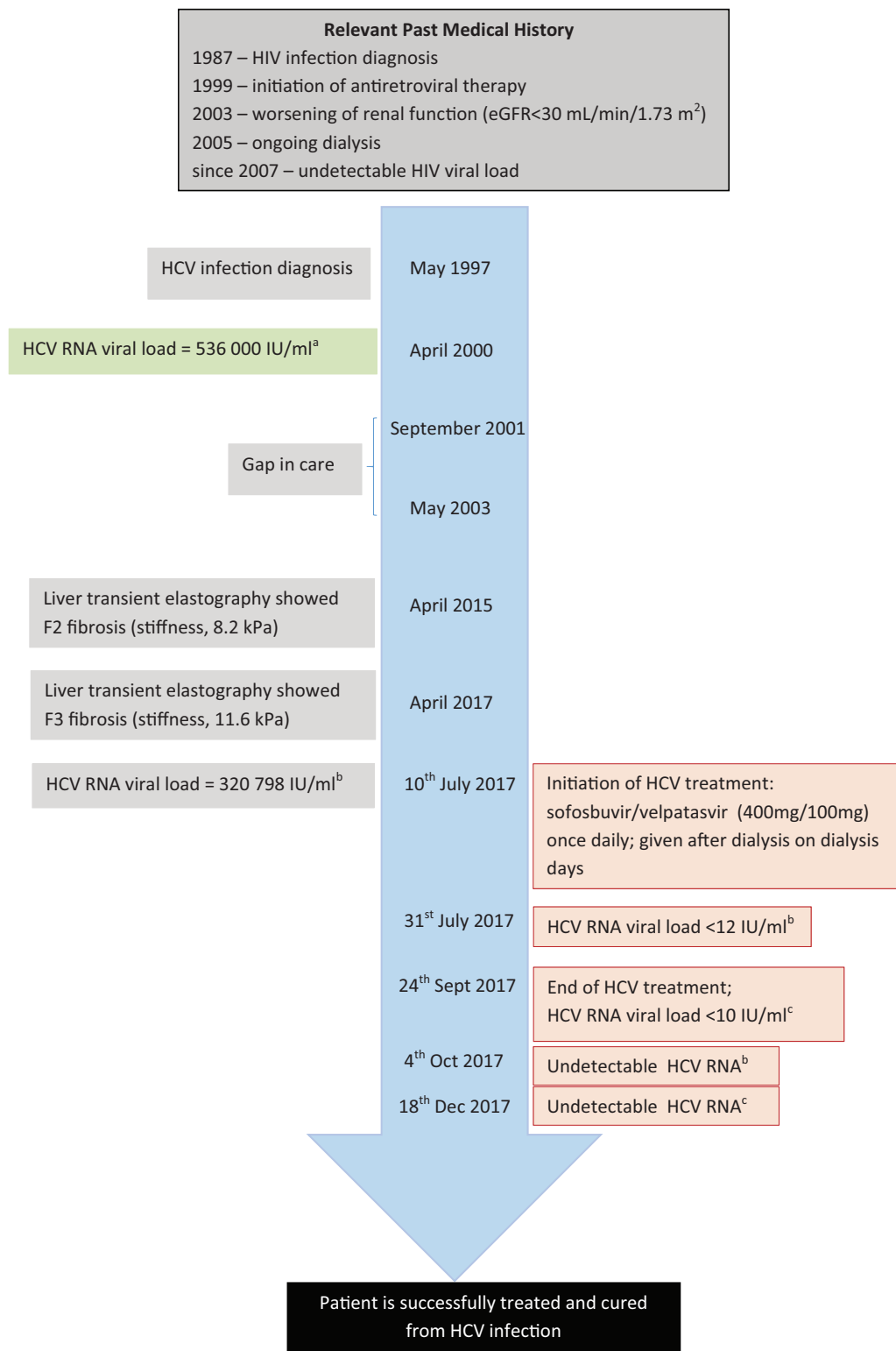


Figure 1. The timeline summary of the case. HCV= hepatitis C virus, HIV= human immunodeficiency virus, RNA= ribonucleic acid. ^aCobas Amplicor HCV Monitor test, v2.0, Roche Switzerland, ^bAbbott RealTime HCV assay, ^cXpert HCV Viral Load.

September 2001 to May 2003 when ART was reintroduced with a combination of stavudine, lamivudine and lopinavir/ritonavir. The patient became fully compliant with his ART in October 2006 and since July 2007 had an undetectable HIV viral load on all occasions (measurements were done 2 to 3 times per year).

The patients’ past history included treatment with steroids for immune thrombocytopenia in 2000, avascular necrosis of the left hip (hip replacement was done in 2007 and 2016) and secondary hyperparathyroidism for which he underwent subtotal parathyroidectomy in 2015.

The estimated glomerular filtration rate (eGFR) calculated by the modification of diet in renal disease equation was normal up to January 1998 (111.9 mL/min/1.73 m²). It gradually worsened and became < 30 mL/min/1.73 m² in May 2003. The patient started chronic dialysis in January 2005. He had no history of substance abuse nor was he ever treated for substance dependence. The liver function tests (aspartate and alanine aminotransferases) were within normal limits throughout the years of follow-up. Liver transient elastography (FibroScan) was done in April 2015 and April 2017 indicating F2 (stiffness, 8.2 kPa) and F3 (stiffness, 11.6 kPa) fibrosis respectively. The patient has never been treated for HCV infection. It was decided to commence treatment with a fixed dose combination of once daily sofosbuvir/velpatasvir (400 mg/100 mg; Epclusa) on the 10th of July 2017. On dialysis days, Epclusa was given after dialysis. The patient's ART at that time was lopinavir/ritonavir monotherapy. His pretreatment HCV RNA viral load was 320798 IU/mL (Abbott RealTime HCV assay). On the first follow-up visit 3-weeks after introduction of anti-HCV therapy (31st of July 2017) the serum quantitative real time polymerase chain reaction (PCR) showed <12 IU HCV RNA per mL. Therapy with sofosbuvir/velpatasvir ended on 24th of September 2017. The total duration of treatment was about 11 weeks since the patient misinterpreted instruction on how to take the drug and he took Epclusa twice daily during the first week of treatment. At end of HCV treatment (25th of September 2017) the HCV RNA quantitative real time PCR showed <10 IU HCV RNA per mL of serum (Xpert HCV Viral Load, Cepheid, Sunnyvale, CA) and on a follow up sample (4th of October 2017) HCV RNA was undetectable (Abbott RealTime HCV assay). Twelve weeks after treatment cessation (18th of December 2017) HCV RNA was undetectable (Xpert HCV Viral Load) and the patient is now considered cured from HCV infection. The patient did not report any drug side effects. The timeline summary for this case is shown on the Figure 1. Written permission to publish this case report was obtained from the patient.

3. Discussion

Several studies have reported treating HCV infection in patients with severe renal impairment or on hemodialysis with sofosbuvir-based regimens with sustained virologic response at 12 weeks (SVR12) of 80% to 100%.^[1-5] Patients with advanced chronic kidney disease (eGFR ≤45 mL/min/1.73 m²) had more frequently anemia, worsening of renal function and serious adverse effects than patients with no or less severe renal impairment.^[2,5] Nevertheless, in a report of 62 patients on maintenance dialysis sofosbuvir was well tolerated and increased use of erythropoietin was observed only when ribavirin was given.^[4] Sofosbuvir is mainly eliminated by the renal route and plasma concentrations of its renally excreted metabolite GS-331007 are significantly higher in patients with renal impairment compared to those without.^[6] However, Desnoyer et al^[7] reported that sofosbuvir or its inactive metabolite sofosbuvir-331007 did not accumulate in plasma of patients on hemodialysis. In HIV/HCV coinfecting patients, sofosbuvir/velpatasvir may be given with most antiretrovirals, with the exception of efavirenz, etravirine and nevirapine,^[8,9] and Wyles et al reported it was a safe regimen that provided SVR12 in 95% patients with HIV/HCV pan-genotypic coinfection.^[10]

Glecaprevir/pibrentasvir is a highly efficacious new treatment option for patients with HCV genotype 3 infection.^[11] The EXPEDITION-4 trial evaluated that regimen in patients with

severe kidney disease or undergoing dialysis who had HCV genotype 1–6 infection and also had compensated liver disease and reported an SVR12 rate of 98%.^[12] However, glecaprevir/pibrentasvir was not available in Croatia at the time of initiation of anti-HCV treatment in our patient. Also, cure of HCV-infection is a prerequisite for kidney transplantation in Croatia. Although sofosbuvir is not licensed and recommended for use in patients with severe renal impairment^[8] mainly because of safety concerns^[5,8] its use with velpatasvir for genotype 3 infection in patients on dialysis is an option when other drug combinations are not available. To our knowledge, this is the first report of a patient with HIV/HCV genotype 3 coinfection undergoing dialysis, who was successfully treated with sofosbuvir/velpatasvir regimen.

Author contributions

Conceptualization: Josip Begovac, Juraj Krznarić, Nikolina Bogdanić, and Šime Zekan.

Data curation: Josip Begovac, Juraj Krznarić, Nikolina Bogdanić, and Loris Močibob.

Funding acquisition: Josip Begovac.

Supervision: Šime Zekan.

Validation: Josip Begovac.

Writing – original draft: Josip Begovac, Juraj Krznarić, Nikolina Bogdanić, and Loris Močibob.

Writing – review & editing: Josip Begovac, Juraj Krznarić, Nikolina Bogdanić, Loris Močibob, and Šime Zekan.

References

- [1] Bhamidimarri KR, Czul F, Peyton A, et al. Safety, efficacy and tolerability of half-dose sofosbuvir plus simeprevir in treatment of Hepatitis C in patients with end stage renal disease. *J Hepatol* 2015;63:763–5.
- [2] Shin HP, Park JA, Burman B, et al. Efficacy and safety of sofosbuvir-based regimens for treatment in chronic hepatitis C genotype 1 patients with moderately impaired renal function. *Clin Mol Hepatol* 2017;23:316–22.
- [3] Nazario HE, Ndungu M, Modi AA. Sofosbuvir and simeprevir in hepatitis C genotype 1-patients with end-stage renal disease on haemodialysis or GFR <30 mL/min. *Liver Int* 2016;36:798–801.
- [4] Agarwal SK, Bagchi S, Yadav RK. Hemodialysis patients treated for hepatitis C using a sofosbuvir-based regimen. *Kidney Int Rep* 2017;2:831–5.
- [5] Saxena V, Korashy FM, Sise ME, et al. Safety and efficacy of sofosbuvir-containing regimens in hepatitis C-infected patients with impaired renal function. *Liver Int* 2016;36:807–16.
- [6] Lawitz E, Landis CS, Maliakkal BJ, et al. Safety and efficacy of treatment with once-daily ledipasvir/sofosbuvir (90/400 mg) for 12 weeks in genotype 1 HCV-infected patients with severe renal impairment. *Hepatology* 2017;66(Suppl 1):848A.
- [7] Desnoyer A, Pospai D, Le MP, et al. Pharmacokinetics, safety and efficacy of a full dose sofosbuvir-based regimen given daily in hemodialysis patients with chronic hepatitis C. *J Hepatol* 2016;65:40–7.
- [8] European Association for the Study of the Liver/EASL Recommendations on Treatment of Hepatitis C 2018. *J Hepatol* 2018;69:461–511.
- [9] Mogalian E, Stamm LM, Osinusi A, et al. Drug-drug interactions studies between HCV antivirals sofosbuvir/velpatasvir and boosted and unboosted HIV antiretroviral regimens in healthy volunteers. *Clin Infect Dis* 2018;67:934–40.
- [10] Wyles D, Bräu N, Kottlilil S, et al. Sofosbuvir and velpatasvir for the treatment of hepatitis C virus in patients coinfecting with human immunodeficiency virus type 1: an open-label, phase 3 study. *Clin Infect Dis* 2017;65:6–12.
- [11] Zeuzem S, Foster GR, Wang S, et al. Glecaprevir-pibrentasvir for 8 or 12 weeks in HCV genotype 1 or 3 infection. *N Engl J Med* 2018;378:354–69.
- [12] Gane E, Lawitz E, Pugatch D, et al. Glecaprevir and pibrentasvir in patients with HCV and severe renal impairment. *N Engl J Med* 2017;377:1448–55.