

# Digital dermatoscopy as a useful tool for evaluating therapeutic efficacy in a patient with eruptive keratoacanthomas

---

**Jurakić Tončić, Ružica; Jerković Gulin, Sandra; Radoš, Jaka; Štulhofer Buzina, Daška; Kostović, Krešimir; Argenziano, Giuseppe**

*Source / Izvornik:* **Dermatology Practical & Conceptual, 2018, 8, 204 - 207**

**Journal article, Published version**

**Rad u časopisu, Objavljena verzija rada (izdavačev PDF)**

*Permanent link / Trajna poveznica:* <https://urn.nsk.hr/urn:nbn:hr:105:960321>

*Rights / Prava:* [In copyright](#) / [Zaštićeno autorskim pravom.](#)

*Download date / Datum preuzimanja:* **2025-03-10**



*Repository / Repozitorij:*

[Dr Med - University of Zagreb School of Medicine  
Digital Repository](#)



# Digital dermatoscopy as a useful tool for evaluating therapeutic efficacy in a patient with eruptive keratoacanthomas

Ruzica Jurakic Tonicic<sup>1</sup>, Sandra Jerkovic Gulin<sup>2</sup>, Jaka Rados<sup>1</sup>, Daska Stulhofer Buzina<sup>1</sup>, Kresimir Kostovic<sup>1</sup>, Giuseppe Argenziano<sup>3</sup>

1 Department of Dermatology and Venereology, University Hospital Centre Zagreb, Zagreb School of Medicine, Zagreb, Croatia

2 Department of Infectious Diseases, Dermatology, and Venereology, General Hospital Sibenik, Sibenik, Croatia

3 Dermatology Unit, University of Campania, Naples, Italy

**Key words:** digital dermoscopy follow-up, keratoacanthoma, eruptive keratoacanthomas, treatment response to acitretin

**Citation:** Jurakic Tonicic R, Jerkovic Gulin S, Rados J, Stulhofer Buzina D, Kostovic K, Argenziano G. Digital dermoscopy as useful tool for evaluating therapeutic efficacy in a patient with eruptive keratoacanthomas. *Dermatol Pract Concept*. 2018;8(3):204-207. DOI: <https://doi.org/10.5826/dpc.0803a11>

**Received:** September 25, 2017; **Accepted:** March 7, 2018; **Published:** July 31, 2018

**Copyright:** ©2018 Jurakic Tonicic et al. This is an open-access article distributed under the terms of the Creative Commons Attribution License, which permits unrestricted use, distribution, and reproduction in any medium, provided the original author and source are credited.

**Funding:** None.

**Competing interests:** The authors have no conflicts of interest to disclose.

All authors have contributed significantly to this publication.

**Corresponding author:** Ruzica Jurakic Tonicic, MD, Department of Dermatology and Venereology, University Hospital Centre Zagreb, Salata 4, 10000, Zagreb, Croatia. Email: [rjtoncic@gmail.com](mailto:rjtoncic@gmail.com).

## Introduction

Digital dermoscopy follow-up (DDFU) has proved its place in the monitoring of patients with multiple moles. The main indications for DDFU are a large number of nevi, a personal/familial history of melanoma, and patients with lesions where excision would lead to disfiguring scars. DDFU includes short-term (3-6 months) and long-term (6-12 months) follow-up strategies [1,2]. Keratoacanthoma (KA) is a relatively common, rapidly growing low-grade tumor that originates in the pilosebaceous glands and closely resembles squamous cell carcinoma (SCC) [3]. Some authors regard KA as a variant of SCC [4]. KA rapidly grows within few weeks/months, followed by spontaneous resolution within few months. Rarely, cases of KA progressing to invasive/metastatic carcinoma have been reported. Trauma, human papilloma virus, genetic factors, immunosuppression, professional exposure to carcinogens, and some drugs have been considered in

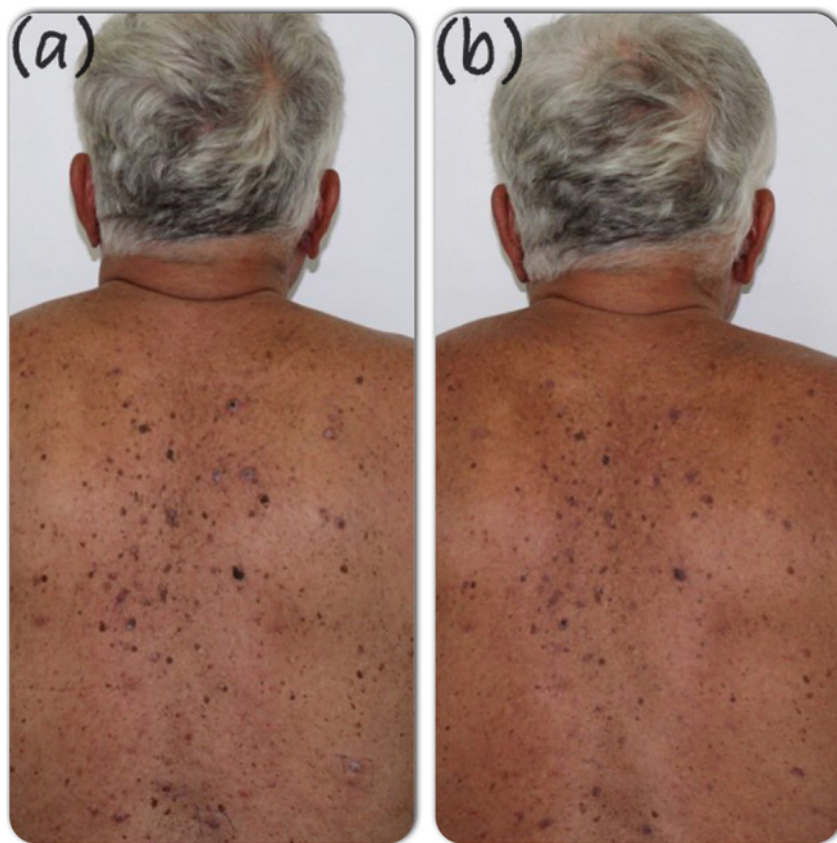etiology of KA [3,5]. Infrequently, KA presents as multiple tumors, and there are few described syndromes with multiple KAs including Grzybowski syndrome (generalized eruptive KA; hundreds of papules in middle-aged adults) [6], Muir-Torre/Lynch syndrome (skin tumors in association with visceral cancer) [7], Ferguson-Smith syndrome (rare autosomal dominant disorder characterized by the sudden appearance of multiple self-healing recurrent skin tumors resembling well-differentiated SCC/KA in young age) [8], and KA centrifugum marginatum [9]. Authors speculate that multiple KA might belong to the spectrum of keratinocytes maturation abnormalities, giving a clue for acitretin therapy [10].

## Case Presentation

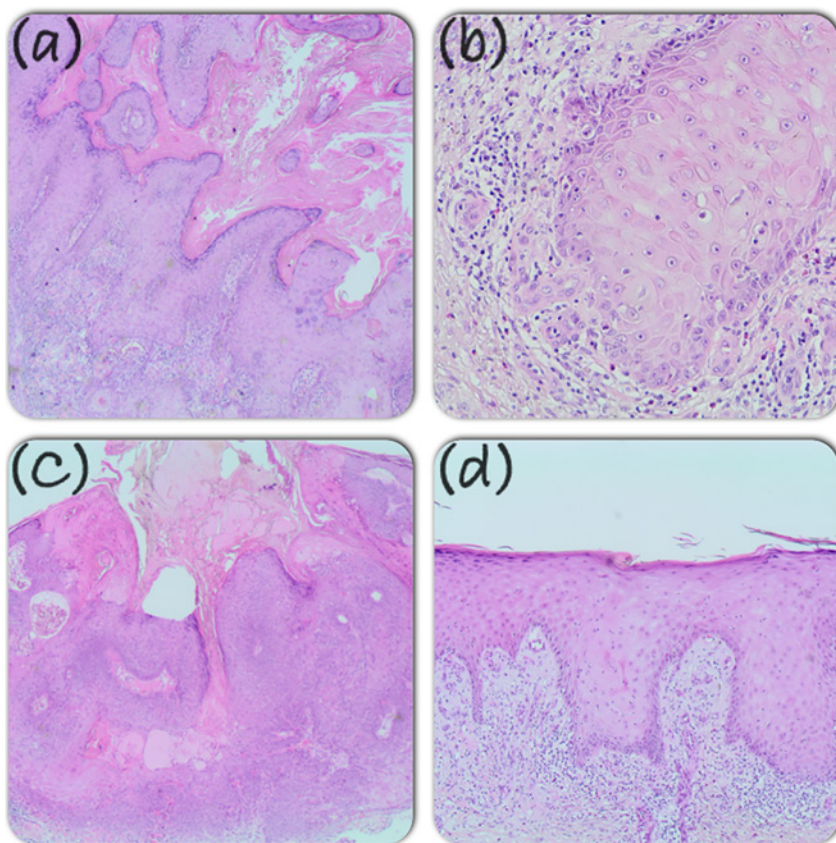
We report a case of a 78-year-old man with multiple eruptive KA-like tumors generalized on the body. Face, palms, soles,

and mucosa were spared. The patient reported the occurrence of tumors within 3 months before the first visit. His family members did not present with skin tumors. Physical examination revealed the presence of up to 50 well-demarcated, dome-shaped nodules with a rolled, mildly erythematous border and central hyperkeratotic plug (Figure 1). Most of the lesions were less than 0.5 cm in diameter with only a few more than 1 cm in diameter. Dermatoscopy revealed a central mass of yellow-white keratin with some hemorrhages, peripheral arrangement of hairpin vessels, linear vessels, and, less commonly, glomerular vessels. Biopsy of several lesions was done, and in most we confirmed KA and in just 4 cases we confirmed SCC (Figure 2). All histologically proven SCC underwent complete surgical excision.

After surgery, acitretin 50 mg/day was administered, subsequently reduced to 30 mg/day after a month due to nonspecific bone/muscle pain.

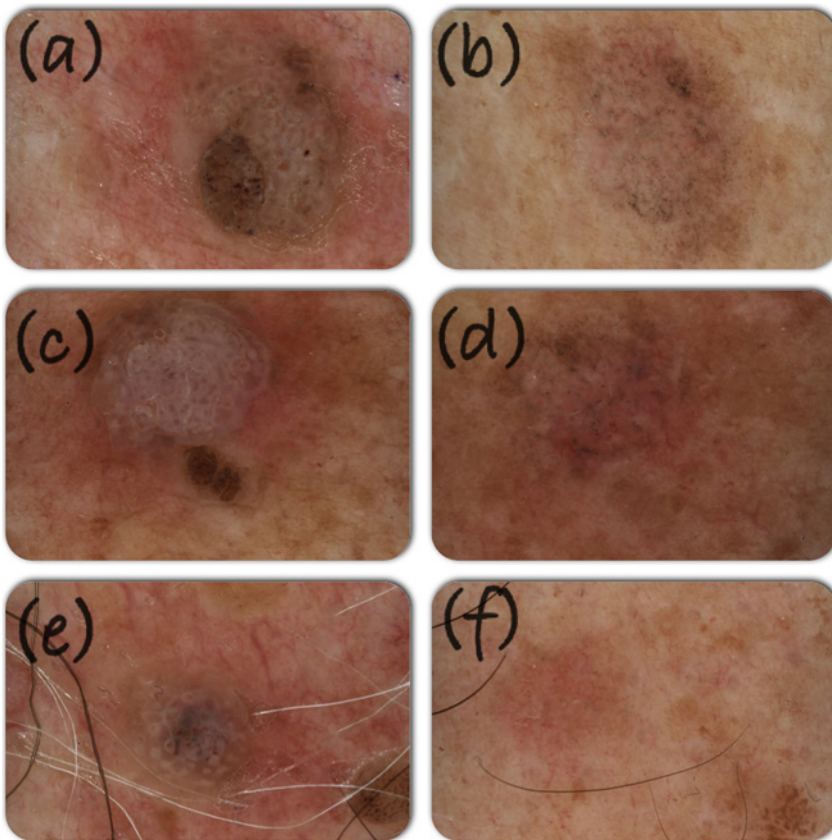


**Figure 1.** Clinical findings. (A) A large number of well-demarcated, dome-shaped nodules with a rolled, mildly erythematous border and central hyperkeratotic plug on the back (before the treatment). (B) The total count of lesions was reduced and signs of regression were present, resulting in loss of palpability. [Copyright: ©2018 Juracic Tonic et al.]



**Figure 2.** Histopathology of lesions before and during acitretin treatment. (A) and (B) Lesions excised before acitretin treatment. Well-differentiated squamous cell carcinoma (medium power photomicrograph, hematoxylin and eosin [H&E] stain  $\times 4$ ), intradermal tumor islands of pleomorphic keratinocytes at the base of tumor accompanied by a marked inflammatory infiltrate with eosinophils (high-power photomicrograph, H&E stain  $\times 20$ ). (C) Lesions excised before acitretin treatment. Small and well-demarcated lesion with characteristic crateriform architecture with symmetrical overhanging edges of epidermal hyperplasia and central keratin plug (H&E stain  $\times 2$ ). (D) Regressing/resolving phase of keratoacanthoma under treatment. Histopathology revealed flattening of cup shape of the lesion, irregular hyperplastic epidermis without atypia of keratinocytes, solitary dyskeratotic keratinocytes, fibrosis, and angioplasia with mixed infiltrate of inflammatory cells reminiscent on scar tissue (medium power photomicrograph, H&E stain  $\times 4$ ). Biopsy was done during the treatment. [Copyright: ©2018 Juracic Tonic et al.]





**Figure 3.** Dermatoscopic images taken with digital dermoscopy system VisioMed microDERM D120, equipped with full-body documentation system with SLR camera Canon EOS 1200 D. (A), (C), and (E) Lesions before the acitretin treatment. (A) Hyperkeratotic, verrucous lesion with nonspecific vessels with the adjunction of seborrheic keratosis in the lower part. Atypical vessels and hyperkeratotic lesions are present in other lesions before treatment. (B), (D), and (F) The same lesions at 2-month follow-up, during treatment. Almost complete regression of the lesions along with loss of nodularity and signs of regression (peppering sign and nonspecific erythema) are observed. Loss of atypical vessels, loss of keratin structures, and the presence of melanophages/peppering structures present phenomena detected in other lesions after the treatment. [Copyright: ©2018 Jurakic Tonic et al.]

An excellent therapeutic response was seen very quickly, after only 10 days of therapy, with good resolution of all tumors after 2 months. Resolution of the lesion was histologically proven (Figure 2). Full-body photography and dermatoscopic images of most of the lesions were taken before the treatment. At the 2-month follow-up, an excellent treatment response was observed. Observation found no new lesions and signs of regression in all lesions, resulting in loss of palpability, loss of atypical vessels, loss of keratin structures, and the presence of melanophages/peppering structures (Figure 3). This is comparable to the finding seen in histology report of the regressed lesion (Figure 2).

Upon submission of the article, acitretin treatment was still ongoing, and the patient was being closely monitored, dermoscopically and clinically, with dermatoscopic documentation completed every 2 months. Detailed diagnostic investigations had been excluded visceral malignancy until now. At the time of submission, the patient was on a regimen of acitretin 25 mg/day, but with few new lesions observed. We decided to keep the patient on this dosage because he could not stand the pain that came with a higher dosage. The complete duration of the therapy was 6 months at the time of submission of the article. The patient was monitored from the aspect of skin and visceral tumors,

and the examinations were repeated on a 6-month basis.

## Conclusions

DDFU has proven efficacy in the follow-up of patients with multiple nevi. In our case, DDFU proved to be very useful because it allowed documentation of the efficacy of acitretin therapy, regression of the previously observed lesions, and follow-up of the possible occurrence of new lesions. As the patient developed new lesions on a lowered dose, we suggest that DDFU can also be used as an additional tool for finding the lowest and most optimal dose that might be used to prevent the development of new lesions.

## References

1. Moscarella E, Tion I, Zalaudek I, et al. Both short-term and long-term dermoscopy monitoring is useful in detecting melanoma in patients with multiple atypical nevi. *J Eur Acad Dermatol Venerol.* 2017;31(2):247-251. doi: 10.1111/jdv.13840.
2. Longo C, Borsari S, Benati E, Moscarella E, Alfano R, Argenziano G. Dermoscopy and reflectance confocal microscopy for monitoring the treatment of actinic keratosis with ingenol mebutate gel: report of two cases. *Dermatol Ther (Heidelb).* 2016;6(1):81-87. doi: 10.1007/s13555-016-0094-9.
3. Kwiek B, Schwartz RA. Keratoacanthoma (KA): an update and review. *J Am Acad Dermatol.* 2016;74(6):1220-1233. doi: 10.1016/j.jaad.2015.11.033.
4. Ogita A, Ansai SI, Misago N, Anan T, Fukumoto T, Saeki H. Histopathological diagnosis of epithelial crateriform tumors: keratoacanthoma and other epithelial crateriform tumors. *J Dermatol.* 2016;43(11):1321-1331. doi: 10.1111/1346-8138.13390.
5. Sinha R, Larkin J, Gore M, Fearfield L. Cutaneous toxicities associated with vemurafenib therapy in 107 patients with BRAF V600E mutation-positive metastatic melanoma, including recognition and management of rare presentations. *Br J Dermatol.* 2015;173(4):1024-1031. doi: 10.1111/bjd.13958.

6. Laaff H, Mittelviehhaus H, Wokalek H, Schöpf E. Grzybowski type eruptive keratoacanthomas and ectropion. A therapeutic problem. *Hautarzt*. 1992;43(3):143-147.
7. Hartig C, Stieler W, Stadler R. Muir-Torre syndrome. Diagnostic criteria and review of the literature. *Hautarzt*. 1995;46(2):107-113. doi: 10.1007/s001050050218.
8. Robertson SJ, Bashir SJ, Pichert G, Robson A, Whittaker S. Severe exacerbation of multiple self-healing squamous epithelioma (Ferguson-Smith disease) with radiotherapy, which was successfully treated with acitretin. *Clin Exp Dermatol*. 2010;35(4):e100-e102. doi: 10.1111/j.1365-2230.2009.03668.x.
9. Divers AK, Correale D, Lee JB. Keratoacanthoma centrifugum marginatum: a diagnostic and therapeutic challenge. *Cutis*. 2004;73(4):257-262.
10. Farro P, Zalaudek I, Ferrara G, et al. Unusual association between acrokeratosis verruciformis of Hopf and multiple keratoacanthomas. Successful therapy with acitretin. *J Dtsch Dermatol Ges*. 2004;2(6):440-442.