

RE: complications attributable to the use of rhBMP-2 inside the femoral ring allograft during anterior lumbar interbody fusion

Smoljanović, Tomislav; Pećina, Marko

Source / Izvornik: **The Spine Journal, 2008, 8, 413 - 414**

Journal article, Accepted version

Rad u časopisu, Završna verzija rukopisa prihvaćena za objavljivanje (postprint)

<https://doi.org/10.1016/j.spinee.2007.11.004>

Permanent link / Trajna poveznica: <https://um.nsk.hr/um:nbn:hr:105:358343>

Rights / Prava: [In copyright](#) / [Zaštićeno autorskim pravom.](#)

Download date / Datum preuzimanja: **2024-09-29**



Repository / Repozitorij:

[Dr Med - University of Zagreb School of Medicine
Digital Repository](#)





Središnja medicinska knjižnica

Smoljanović, T., Pećina, M. (2008) *RE: complications attributable to the use of rhBMP-2 inside the femoral ring allograft during anterior lumbar interbody fusion.* The Spine Journal, 8 (2). pp. 413-414.

<http://www.elsevier.com/locate/issn/1529-9430>

<http://dx.doi.org/10.1016/j.spinee.2007.11.004>

<http://medlib.mef.hr/330>

University of Zagreb Medical School Repository

<http://medlib.mef.hr/>

Letters

Complications Attributable to the Use of rhBMP-2 Inside the Femoral Ring Allograft during Anterior Lumbar Interbody Fusion

Tomislav Smoljanovic, MD,* Marko Pecina, MD, PhD*

*Department of Orthopaedic Surgery, School of Medicine, University of Zagreb, Zagreb, Croatia

Tomislav Smoljanovic, MD (corresponding author)

Department of Orthopaedic Surgery

School of Medicine

University of Zagreb

Salata 7

10000 Zagreb

Croatia

E-mail: drsmoljanovic@yahoo.com

Phone: +385-1-4818833

Fax: +385-1-4818810

To the Editor:

Complications Attributable to the Use of rhBMP-2 Inside the Femoral Ring Allograft during Anterior Lumbar Interbody Fusion

We read with great interest the prospective analysis of interbody fusion rates by Slosar et al. [1] in which the exceptionally excellent results concerning the use of femoral ring allografts (FRA) with rhBMP-2 during anterior lumbar interbody fusion (ALIF) in addition with posterior pedicle screw fixation were reported. Namely, the rhBMP-2 group had a 100% fusion rate in all levels attempted (n=103), there were no complications attributable to the use of rhBMP-2 and no osteolysis or fragmentations of the allografts were observed. But, there was no mention of the subsidence which is defined as a fusion device sinking into one or both of the adjacent vertebral bodies [2] and end-plate erosions.

On the other side, Vaidya et al. [3] who used machined allograft spacers centrally filled with rhBMP-2 and additional posterior pedicle screw fixation during ALIF and also had 100% fusion rate, found that 70% (14 of 20) of levels had signs of early lucency and underwent significant (> 10%) graft subsidence of a mean of 27% (13% to 42%). CT scans obtained from patients who received allograft/rhBMP-2 revealed two phenomena that may have contributed to subsidence. First, early lucency and incorporation of the allograft were noted, which may have resulted in a loss of structural support. Secondly, there was significant end-plate erosion in each rhBMP-2 case, an appearance that was not evident in patients treated without rhBMP-2.

End-plate erosions have been observed by CT during the first months of follow up in 3 of 4 published studies concerning the use of FRA or similarly shaped allografts and rhBMP-2 during ALIF [3-5] with [3,4] or without additional posterior instrumentation [5]. The only

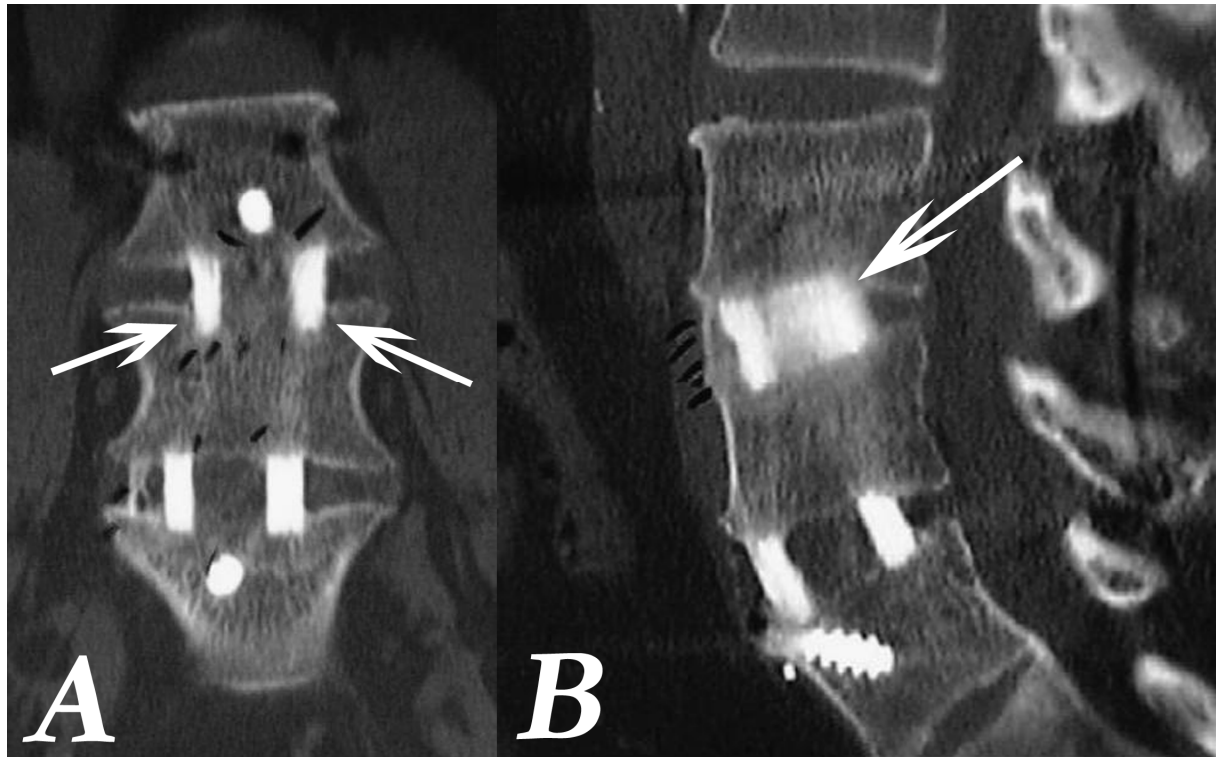
study, beside the one of Slosar et al., which didn't report end-plate erosion, was the case report by Lee et al. [6]. It was even expected as the CT was not used during the follow up. By the way, Lee et al. reported about histological analysis of a displaced femoral ring allograft spacer filled with rhBMP-2 soaked collagen sponge in a patient who also had additional posterior instrumentation 6 months after the surgery

The total doses of rhBMP-2 used per level of fusion were similar among mentioned studies (from 2 mg to 4,2 mg) (Joon Y. Lee, MD, written communication, September, 2007) [3,4,6] including Slosar et al. who used 3 mg of rhBMP-2 [1]. Only Pradhan et al. used higher dose of rhBMP-2 per level of fusion, i.e. 12 mg (Ben B. Pradhan, MD, MSE, written communication, September, 2007) [5].

As the subsidence and end-plate erosion have not been mentioned at all in the entire manuscript of Slosar et al. [1], not even as possibilities of unanticipated adverse events related to the use of rhBMP-2, it is probable that authors have not been aware of these disorders at the time. The probability was confirmed when an overlooked subsidence of FRA allograft 6 months following surgery at Figure 1 and 2 was noticed in the study of Slosar et al. (Figure 1) [1]. In the light of the presented findings, we kindly ask the authors to evaluate once again the CT scans from the patients involved in the study obtained 6 months after the operation concerning the subsidence and end-plate erosions and to inform reading audience about the results.

Figure Legend

Figure 1. From the Slosar et al study. The arrows point the overlooked subsidence of femoral ring allograft into vertebral body 6 months following surgery, A) anterior view, B) lateral view.



Reference

1. Slosar PJ, Josey R, Reynolds J. Accelerating lumbar fusions by combining rhBMP-2 with allograft bone: a prospective analysis of interbody fusion rates and clinical outcomes. *Spine J.* 2007;7:301-307.
2. Williams AL, Gornet MF, Burkus JK. CT evaluation of lumbar interbody fusion: current concepts. *AJNR Am J Neuroradiol.* 2005;26:2057-2066.
3. Vaidya R, Weir R, Sethi A, Meisterling S, Hakeos W, Wybo CD. Interbody fusion with allograft and rhBMP-2 leads to consistent fusion but early subsidence. *J Bone Joint Surg Br.* 2007;89:342-345.
4. Hansen SM, Sasso RC. Resorptive response of rhBMP2 simulating infection in an anterior lumbar interbody fusion with a femoral ring. *J Spinal Disord Tech.* 2006;19:130-134.
5. Pradhan BB, Bae HW, Dawson EG, Patel VV, Delamarter RB. Graft resorption with the use of bone morphogenetic protein: lessons from anterior lumbar interbody fusion using femoral ring allografts and recombinant human bone morphogenetic protein-2. *Spine.* 2006;31:E277-284.
6. Lee JY, Zeiller S, Voltaggio L, Lim MR, Hilibrand AS, Vaccaro AR, et al. Histological analysis of a displaced femoral ring allograft spacer filled with a recombinant human bone morphogenetic protein-2-soaked collagen sponge. A case report. *J Bone Joint Surg Am.* 2005;87:2318-2322.