

# Myocardial bridging as one of the causes of atypical chest pain in young women

---

Jukić, Mladen; Pavić, Ladislav; Bitunjac, Ivan; Jukić, Tena; Milošević, Milan; Lovrić, Dražen; Lovrić Benčić, Martina

Source / Izvornik: **The Egyptian Heart Journal, 2017, 69, 235 - 239**

Journal article, Published version

Rad u časopisu, Objavljena verzija rada (izdavačev PDF)

<https://doi.org/10.1016/j.ehj.2017.03.005>

Permanent link / Trajna poveznica: <https://urn.nsk.hr/urn:nbn:hr:105:597573>

Rights / Prava: [In copyright](#) / [Zaštićeno autorskim pravom.](#)

Download date / Datum preuzimanja: **2025-02-03**



Repository / Repozitorij:

[Dr Med - University of Zagreb School of Medicine  
Digital Repository](#)





Egyptian Society of Cardiology  
The Egyptian Heart Journal

www.elsevier.com/locate/ehj  
www.sciencedirect.com



ORIGINAL ARTICLE

# Myocardial bridging as one of the causes of atypical chest pain in young women



M. Jukić<sup>a</sup>, L. Pavić<sup>a</sup>, I. Bitunjac<sup>b,\*</sup>, T. Jukić<sup>c</sup>, M. Milošević<sup>d</sup>, D. Lovrić<sup>a</sup>,  
M. Lovrić Benčić<sup>e</sup>

<sup>a</sup> *Sunce Clinics, Trnjanska cesta 106, 10000 Zagreb, Croatia*

<sup>b</sup> *General Hospital "Dr. Josip Benčević", Andrije Štampara 42, 35000 Slavonski Brod, Croatia*

<sup>c</sup> *Primary Care Office, Zagreb East, 10000 Zagreb, Croatia*

<sup>d</sup> *University of Zagreb, School of Medicine, Andrija Stampar School of Public Health, Department for Occupational and Environmental Health, Rockefeller Street No 4, 10000 Zagreb, Croatia*

<sup>e</sup> *University of Zagreb, School of Medicine, Šalata 2, 10000 Zagreb, Croatia*

Received 21 February 2017; accepted 21 March 2017

Available online 12 April 2017

## KEYWORDS

Coronary computed tomography angiography;  
Myocardial bridging;  
Atypical chest pain

**Abstract** *Introduction:* Myocardial bridging is congenital anomaly which usually has benign prognosis but there are also reports suggesting that it can be associated with ischemic clinical syndromes presenting with chest pain. Coronary computed tomography angiography is a well-established method for detecting myocardial bridging. However, clinical significance of this anomaly still remains unclear.

*Methods:* We studied 977 patients who presented with recurrent typical or atypical chest pain in outpatient clinic. All patients have undergone detailed clinical examination, ECG stress testing and coronary computed tomography angiography.

*Results:* Highest positive prediction for having myocardial bridging was for patients presenting with atypical chest pain with negative ECG stress test and who were younger women.

*Conclusion:* Coronary computed tomography angiography may be preferable method for evaluation of chest pain in younger women presenting with atypical chest pain.

© 2017 Egyptian Society of Cardiology. Production and hosting by Elsevier B.V. This is an open access article under the CC BY-NC-ND license (<http://creativecommons.org/licenses/by-nc-nd/4.0/>).

## 1. Introduction

Myocardial bridging (MB) is a congenital coronary artery anomaly with unclear clinical relevance.<sup>1</sup> Because it presents a common finding at autopsy of normal subjects, it is usually regarded to be a benign anatomic variation.<sup>1,2</sup> However, there

are reports suggesting that at least in some cases MB can produce myocardial ischemia, arrhythmias, coronary thrombosis, myocardial infarction, and even sudden cardiac death.<sup>3–12</sup>

In the last decade, coronary computed tomography angiography (CCTA) has been introduced as an efficient, effective and safe method for evaluation of chest pain in patients with low or intermediate risk for coronary artery disease,<sup>13</sup> including patients with atypical symptoms suggestive of coronary artery disease.<sup>14</sup> Furthermore, it probably presents the best

\* Corresponding author.

E-mail address: [ivan@bitunjac.com](mailto:ivan@bitunjac.com) (I. Bitunjac).

Peer review under responsibility of Egyptian Society of Cardiology.

<http://dx.doi.org/10.1016/j.ehj.2017.03.005>

1110-2608 © 2017 Egyptian Society of Cardiology. Production and hosting by Elsevier B.V.

This is an open access article under the CC BY-NC-ND license (<http://creativecommons.org/licenses/by-nc-nd/4.0/>).

non-invasive modality for diagnosing congenital coronary artery anomalies, since it can show up to 95% of all coronary artery segments.<sup>12,18–21</sup> With its cross-sectional view, multi-slice computed tomography (MSCT) seems to be superior also to invasive coronary angiography (ICA) in this respect.<sup>22</sup> Moreover, an increasing number of case reports have been published regarding the reliability of CCTA for diagnosing myocardial bridging as the cause of recurrent chest pain,<sup>15,16</sup> especially in women.<sup>17</sup>

For these reasons, we wanted to investigate the incidence of MB in our patients who underwent CCTA for chest pain, and also to investigate whether there could be any pre-test specificity in the clinical presentation that could differentiate patients with MB and those with CAD. We are not aware of any similar research published so far.

## 2. Methods

### 2.1. Patient selection

The study included all patients undergoing CCTA for chest pain in our institution during one year period. Patients were eligible for the study if CAD was suspected but not previously diagnosed. After completing the structured interview with cardiologist, all patients underwent ECG stress testing and CCTA. Signed informed consent was obtained from all patients before the investigation. The study design was approved by the ethics committee of Sunce Clinic, Zagreb, Croatia.

### 2.2. Pain evaluation

The patient data about pain characteristics was obtained before ECG stress testing using a structured patient questionnaire. Patient chest pain was categorized according to the presence of substernal chest pain or discomfort that was provoked by exertion or emotional stress and was relieved by rest and/or nitroglycerin. Chest pain was classified as “typical” angina if all 3 descriptors were present and as “atypical” if < 3 descriptors were present, as defined by the American College of Cardiology/American Heart Association 2002 Guideline Update on Exercise Testing.<sup>23</sup>

Pain evaluation and ECG stress testing findings were administered by the same cardiologist for each patient in the study, with the data subsequently entered into a clinical database.

### 2.3. ECG stress testing

Exercise testing was performed according to the Bruce protocol, with the heart rate, blood pressure, and 12-lead electrocardiogram recorded before, during, and after exercise. Exercise was terminated for limiting cardiac symptoms or for > 2 mm horizontal or downsloping ST-segment depression measured 80 ms after the J-point for  $\geq 3$  consecutive beats. The result was considered positive if angina or ischemia (horizontal or descending ST segment depression  $\geq 1$  mm, or ST-segment elevation), or inotropic failure appeared (fall of systolic arterial blood pressure [SBP] > 10 mmHg).<sup>24</sup>

The test was considered negative if the peak heart rate  $\geq 85\%$  of the expected rate for age was reached without angina or ischemia.

The result was defined as inconclusive if the criteria above were not met. The ECG stress test was interpreted as inconclusive when the peak heart rate  $\geq 85\%$  of the expected rate for age could not be achieved (e.g. due to beta-blockade) or with the occurrence of intermediate ECG changes (e.g. T-wave changes without ST segment shift) but without pain.

### 2.4. CT procedure

Patients who met the following criteria were eligible for the study: history of “typical” or “atypical” angina as defined earlier above, regardless of ECG stress findings.

They were scanned on a 64-slice dual-source CT scanner (Somatom Definition, Siemens Medical Solutions, Forchheim, Germany). The detailed CT scan protocol was followed as described elsewhere.<sup>25,26</sup>

Scanning parameters were detector collimation  $2 \times 32 \times 0.6$  mm<sup>3</sup>, slice collimation  $2 \times 64 \times 0.6$  mm<sup>3</sup> by means of a z-flying focal spot, gantry rotation time 330 ms, and pitch of 0.2–0.5 depending on the heart rate. For reduction in radiation dose exposure, an electrocardiographically gated modulation of the tube current was used in patients with stable sinus rhythm. Images were reconstructed in the mid-diastole with individually optimized position of the reconstruction window. Additional image reconstructions were performed in the end-systole if required. A data set of axial slices, multiplanar reformations, and thin-slab maximum intensity projections (5-mm thickness, 1-mm increment) was used for the analysis. To lower the heart rate, up to 4 doses of 5 mg metoprolol were administered intravenously to patients with the heart rate  $\leq 60$  beats/min. All patients with a systolic blood pressure of at least 100 mm Hg received nitroglycerin 0.8 mg sublingually for coronary vasodilatation. Images for calcium scoring were not acquired routinely. Contrast timing was tested by an initial timing bolus scan using 20 mL of contrast (Iopamiro 370, Bracco S.p.a, Milan, Italy), iodine content 370 mg/mL, followed by a 50 mL saline chaser. The contrast-enhanced scan was obtained using 80–140 mL of contrast individually adapted to the selected table feed and scan range at a rate of 4–5 mL/s followed by a 50 mL saline chaser.

Interpretation of all CCTA images was performed by the same radiologists with more than 5 years of experience in CCTA and other MSCT vascular imaging procedures. MB was defined as a segment of a major epicardial coronary artery coursing intramurally through the myocardium, beneath the muscle bridge.<sup>27</sup>

For the purpose of this study we did not differentiate between different thickness-variants of the bridging myocardial layer.

### 2.5. Statistical methods

Differences between investigated groups were analyzed with  $X^2$  test. Binary logistic regression was performed to assess the impact of a number of factors on the likelihood that patients have symptoms. All *P* values below 0.05 were considered significant. Data analysis software system STATISTICA

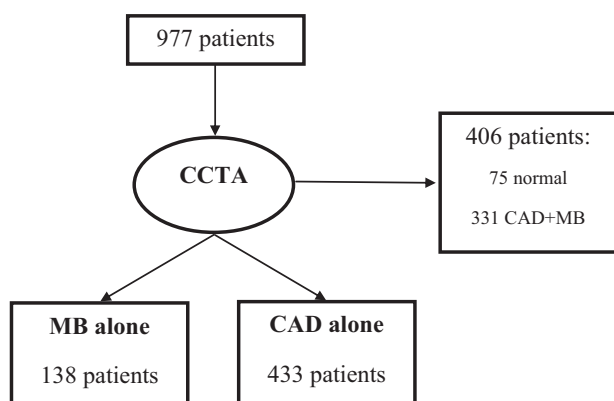
(StatSoft, Inc., version 10.1., [www.statsoft.com](http://www.statsoft.com)) was used in statistical procedures.

### 3. Results

#### 3.1. Study population and incidence of MB

During 1 year period we performed CCTA in 1025 patients, due to chest pain. In 48 patients, one or more major coronary arteries were not fully available to analysis due to the technical problems and artifacts, so these patients were not included in further analysis. There were 977 patients available for further study among whom 469 (48%) had myocardial bridging, either alone or in combination with CAD. More specifically, 138 (14.12%) had only MB and 433 (44.31%) had only CAD (see [Flow chart 1](#)).

Patients' characteristics and incidence of MB and CAD are shown in [Table 1](#). There were significant differences in all investigated parameters indicating that only-MB group was significantly younger, with more females, atypical symptoms,



**Flow chart 1** Patients' classification based on CCTA findings of coronary artery disease (CAD) and myocardial bridging (MB).

negative and inconclusive ECG stress test findings ( $P < 0.001$ ).

#### 3.2. Association of pre-test characteristics with MB

Binary logistic regression model was performed to assess the impact of different factors on the likelihood that patient have MB. The model contained four independent variables (sex, age, ECG stress test findings and symptoms groups) while dependent variable was dichotomized to MB compared to CAD.

The full model containing all predictor variables was statistically significant,  $X^2$  test = 377.2,  $df = 5$ ;  $P < 0.001$ , indicating that the model was able to distinguish between patients who have and do not have MB. The model as a whole explained 72.3% of depended variable variance (Nagelkerke R squared), and correctly classified 91.0% of cases.

As shown in [Table 2](#), all predictor variables, controlled to each other, made a statistically significant contribution to the model (prediction of belonging to only-MB compared to only-CAD group). Highest positive prediction was having atypical symptoms (OR = 31.91, 95% CI = 14.07–72.39) – indicating that patients who had atypical symptoms compared to those with typical symptoms have 31.9 times more chance to have MB, controlled for all other factors in the regression model. Negative ECG stress test findings compared to referent values (positive ergometry) increased chances of having MB 25.5 times (OR = 25.49, 95% CI = 11.06–58.74), although inconclusive ECG stress test elevated chances for 5.1 (OR = 5.06, 95% CI = 2.11–12.13) times. Female gender, compared to male gender had more than three times more chance of having MB (OR = 3.59, 95% CI = 1.80–7.15). Older age lowered chance to have MB (OR = 0.90, 95% CI = 0.87–0.93).

### 4. Discussion

The reported frequency of MB varies considerably regarding the method of evaluation, making any reasoning of the clinical

**Table 1** Clinical and demographic differences between only-MB and only-CAD groups:  $X^2$  test.

		MB <i>N</i> = 138		CAD <i>N</i> = 433		$X^2$ test results
		<i>N</i>	%	<i>N</i>	%	
Age groups	≤45	44	31.9%	24	5.5%	$X^2 = 92.58$ $df = 4$ $P < 0.001$
	46–55	38	27.5%	81	18.7%	
	56–65	43	31.2%	169	39.0%	
	66–75	10	7.2%	114	26.3%	
	≥76	3	2.2%	45	10.4%	
Gender	Male	59	42.8%	282	65.1%	$X^2 = 21.78$ $df = 1$ $P < 0.001$
	Female	79	57.2%	151	34.9%	
Symptoms	Typical	10	7.2%	312	72.1%	$X^2 = 178.74$ $df = 1$ $P < 0.001$
	Atypical	128	92.8%	121	27.9%	
Ergometry findings	Positive	11	8.0%	264	61.0%	$X^2 = 180.22$ $df = 2$ $P < 0.001$
	Negative	96	69.6%	60	13.9%	
	Inconclusive	31	22.5%	109	25.2%	

**Table 2** Prediction of MB in comparison with CAD: binary logistic regression.

	B	S.E.	Wald	df	OR	95% CI		P
						Lower	Upper	
Age (years)	-0.11	0.02	39.52	1.00	0.90	0.87	0.93	<0.001
Female gender	1.28	0.35	13.15	1.00	3.59	1.80	7.15	<0.001
Positive ergometry (referent value)			60.00	2.00				<0.001
Negative ergometry	3.24	0.43	57.82	1.00	25.49	11.06	58.74	<0.001
Inconclusive ergometry	1.62	0.45	13.23	1.00	5.06	2.11	12.13	<0.001
Atypical symptoms	3.46	0.42	68.64	1.00	31.91	14.07	72.39	<0.001

importance of this condition rather complex and unreliable. In this respect, pathologic studies have found a mean frequency of MB of 25%, ranging from 5% to 86%, which is similar to that observed in studies on MSCT.<sup>1,2,28–31</sup> In one pathologic study, specifically, the incidence was 50 percent, which is close to ours.<sup>9</sup>

Studies on ICA have, on the other hand, found considerably different findings.<sup>32</sup> Among patients undergoing ICA for chest pain, the reported prevalence of myocardial bridging is 1.7%, ranging from 0.5% to 16%.<sup>1,2,7,33–37</sup>

For these reasons, we believe that the most important result in our study was considerably high incidence of MB in patients with chest pain, particularly as compared with incidence reported at ICA. Namely, almost half (48%) of our patients with chest pain had MB, either in combination with CAD (33.9%), or alone (14.1%). Having in mind technological superiority of MSCT over ICA in detection of MB, we believe this study provides more accurate insight into actual frequency of MB in patients with chest pain.

In this respect, our results also suggest MB as possibly common cause of chest pain, especially in patients with more “atypical” presentation. Further on, patients with atypical chest pain, negative or inconclusive ECG stress test, especially female and younger ones, have significantly higher likelihood for having MB than CAD as a plausible cause of their symptoms.

## 5. Conclusion

In conclusion, we can roughly estimate that typical MB patient, compared to CAD patient has atypical symptoms, with negative or inconclusive ECG stress test findings and probably is a young woman. Having in mind low sensitivity of invasive coronary angiography (ICA) for detecting myocardial bridging, we believe that ICA might not present the most adequate diagnostic option and that CCTA may be preferable method for this sub-category of patients: young women presenting with atypical chest pain with low or intermediate risk for coronary artery disease.

## Conflicts of interest

The authors report no relationships that could be construed as a conflict of interest.

## References

- Alegria JR, Herrmann J, Holmes Jr DR, Lerman A, Rihal CS. Myocardial bridging. *Eur Heart J* 2005;**26**:1159–68, Epub 2005 Mar 11.
- Möhlenkamp S, Hort W, Ge J, Erbel R. Update on myocardial bridging. *Circulation* 2002;**106**:2616–22.
- Daoud EM, Wafa AA. Does isolated myocardial bridge really interfere with coronary blood flow? *Egypt Heart J* 2013;**65**:65–70.
- Riezzo I, Monciotti F, Pomara C, Fineschi V. Myocardial bridging of the right coronary artery and emotional stress: a fatal link? *Int J Cardiol* 2007;**115**:e99–e101.
- De Giorgio F, Grassi VM, Polacco M, Pascali VL, d'Aloja E, Arena V. Myocardial bridging and sudden cardiac death: is the actual classification exhaustive? *Int J Cardiol* 2014;**172**:E383–4.
- Noble J, Bourassa MG, Petitclerc R, Dyrda I. Myocardial bridging and milking effect of the left anterior descending coronary artery: normal variant or obstruction? *Am J Cardiol* 1976;**37**:993.
- Faruqui AM, Maloy WC, Felner JM, et al. Symptomatic myocardial bridging of coronary artery. *Am J Cardiol* 1978;**41**:1305.
- Morales AR, Romanelli R, Boucek RJ. The mural left anterior descending coronary artery, strenuous exercise and sudden death. *Circulation* 1980;**62**:230.
- Ishikawa Y, Akasaka Y, Suzuki K, et al. Anatomic properties of myocardial bridge predisposing to myocardial infarction. *Circulation* 2009;**120**:376.
- Utuk O, Bilge A, Bayturan O, et al. Thrombosis of a coronary artery related to the myocardial bridging. *Heart Lung Circ* 2010;**19**:481.
- Hostiuc S, Curca GC, Dermengiu D, et al. Morphological changes associated with hemodynamically significant myocardial bridges in sudden cardiac death. *Thorac Cardiovasc Surg* 2011;**59**:393.
- Husmann L, Nkoulou R, Wolfrum M, Kaufmann PA. Myocardial bridging causing infarction and ischaemia. *Eur Heart J* 2011;**32**:790.
- Prazeres CE, Cury RC, Carneiro AC, Rochitte CE. Coronary computed tomography angiography in the assessment of acute chest pain in the emergency room. *Arq Bras Cardiol* 2013;**101**:562–9.
- Dewey M, Rief M, Martus P, et al. Evaluation of computed tomography in patients with atypical angina or chest pain clinically referred for invasive coronary angiography: randomised controlled trial. *bmj* 2016;**355**:i5441.
- Abdou M. Myocardial bridging causing ischemia and recurrent chest pain: a case report. *Int Arch Med* 2011;**4**:1.
- Zeina AR, Shefer A, Sharif D, Rosenschein U, Barmeir E. Acute myocardial infarction in a young woman with normal coronary arteries and myocardial bridging. *Brit J Radiol* 2014.
- Afzal A, Korniyenko A, Haq S. A bridge to a woman's heart as the cause of recurrent chest pain: a case on myocardial bridge. *Am J Ther* 2016;**23**:e273–5.
- Montaudon M, Latrabe V, Iriart X, Caix P, Laurent F. Congenital coronary arteries anomalies: review of the literature and multidetector computed tomography (MDCT)-appearance. *Surg Radiol Anat* 2007;**29**:343–55. <http://dx.doi.org/10.1007/s00276-007-0217-1>.
- Schmitt R, Froehner S, Brunn J, et al. Congenital anomalies of the coronary arteries: imaging with contrast-enhanced, multidetector



- computed tomography. *Eur Radiol* 2005;**15**:1110–21. <http://dx.doi.org/10.1007/s00330-005-2707-z>.
20. Hamoir XL, Flohr T, Hamoir V, et al. Coronary arteries: assessment of image quality and optimal reconstruction window in retrospective ECG-gated multislice CT at 375-ms gantry rotation time. *Eur Radiol* 2005;**15**:296–304. <http://dx.doi.org/10.1007/s00330-004-2541-8>.
  21. Taylor AJ, Cerqueira M, Hodgson JM, Mark D, Min J, O’Gara P. ACCF/SCCT/ACR/AHA/ASE/ASNC/NASCI/SCAI/SCMR 2010 appropriate use criteria for cardiac computed tomography. *Circulat* 2010;**122**:e525–55.
  22. Romano S, Morra A, Del Borrello M, Greco P, Daliento L. Multi-slice computed tomography and the detection of anomalies of coronary arteries. *J Cardiovasc Med* 2008;**9**:187–94.
  23. Gibbons RJ, Balady GJ, Bricker JT, et al. American College of Cardiology/American Heart Association task force on practice guidelines (committee to update the 1997 exercise testing guidelines). ACC/AHA 2002 guideline update for exercise testing: summary article. *Circulation* 2002;**106**:1883–92.
  24. Miller TD. Exercise treadmill test: estimating cardiovascular prognosis. *Cleve Clin J Med* 2008;**75**:424–30.
  25. Leschka S, Scheffel H, Desbiolles L, et al. Image quality and reconstruction intervals of dual-source CT coronary angiography: recommendations for ECG pulsing windowing. *Invest Radiol* 2007;**42**:543–9. <http://dx.doi.org/10.1097/RLL.0b013e31803b93cf>. Medline: 17620936.
  26. Hausleiter J, Meyer T, Hadamitzky M, et al. Non-invasive coronary computed tomographic angiography for patients with suspected coronary artery disease: the Coronary Angiography by Computed Tomography with the Use of a Submillimeter resolution (CACTUS) trial. *Eur Heart J* 2007;**28**:3034–41. <http://dx.doi.org/10.1093/eurheartj/ehm150>. Medline:17540851.
  27. Angelini P, Trivellato M, Donis J, Leachman RD. Myocardial bridges: a review. *Prog Cardiovasc Dis* 1983;**26**:75–88.
  28. Hongo Y, Tada H, Ito K, et al. Augmentation of vessel squeezing at coronary-myocardial bridge by nitroglycerin: study by quantitative coronary angiography and intravascular ultrasound. *Am Heart J* 1999;**138**:345.
  29. Iskandrian AE, Nallamothu N, Heo J. Nonatherosclerotic causes of myocardial ischemia. *J Nucl Cardiol* 1996;**3**:428.
  30. La Grutta L, Runza G, Lo Re G, et al. Prevalence of myocardial bridging and correlation with coronary atherosclerosis studied with 64-slice CT coronary angiography. *Radiol Med* 2009;**114**:1024.
  31. Hwang JH, Ko SM, Roh HG, et al. Myocardial bridging of the left anterior descending coronary artery: depiction rate and morphologic features by dual-source CT coronary angiography. *Korean J Radiol* 2010;**11**:514.
  32. Myocardial bridging of the coronary arteries. <<http://www.uptodate.com/contents/myocardial-bridging-of-the-coronary-arteries>> .
  33. Ge J, Erbel R, Rupprecht HJ, et al. Comparison of intravascular ultrasound and angiography in the assessment of myocardial bridging. *Circulation* 1994;**89**:1725.
  34. Ge J, Jeremias A, Rupp A, et al. New signs characteristic of myocardial bridging demonstrated by intracoronary ultrasound and Doppler. *Eur Heart J* 1999;**20**:1707.
  35. Angelini P, Velasco JA, Flamm S. Coronary anomalies: incidence, pathophysiology, and clinical relevance. *Circulation* 2002;**105**:2449.
  36. Kramer JR, Kitazume H, Proudfit WL, Sones Jr FM. Clinical significance of isolated coronary bridges: benign and frequent condition involving the left anterior descending artery. *Am Heart J* 1982;**103**:283.
  37. Sorajja P, Ommen SR, Nishimura RA, et al. Myocardial bridging in adult patients with hypertrophic cardiomyopathy. *J Am Coll Cardiol* 2003;**42**:889.