

Magnetic resonance spectroscopy and measurement of tau epitopes of autopsy proven sporadic Creutzfeldt-Jakob disease in a patient with non-specific initial EEG, MRI and negative 14-3-3 immunoblot

Šarac, Helena; Hajnšek, Sanja; Bašić, Silvio; Henigsberg, Neven; Radoš, Marko; Šimić, Goran

Source / Izvornik: *Collegium Antropologicum*, 2008, 32, 199 - 204

Journal article, Accepted version

Rad u časopisu, Završna verzija rukopisa prihvaćena za objavljivanje (postprint)

Permanent link / Trajna poveznica: <https://um.nsk.hr/um:nbn:hr:105:105343>

Rights / Prava: [In copyright](#)/[Zaštićeno autorskim pravom.](#)

Download date / Datum preuzimanja: **2024-07-17**



Repository / Repozitorij:

[Dr Med - University of Zagreb School of Medicine Digital Repository](#)





Središnja medicinska knjižnica

Šarac, H., Hajnšek, S., Bašić, S., Henigsberg, N., Radoš, M., Šimić, G. (2008)
*Magnetic resonance spectroscopy and measurement of tau epitopes of autopsy
proven sporadic Creutzfeldt-Jakob disease in a patient with non-specific initial EEG,
MRI and negative 14-3-3 immunoblot.* Collegium Antropologicum, 32 (Suppl. 1).
pp. 199-204.

<http://medlib.mef.hr/372>

University of Zagreb Medical School Repository

<http://medlib.mef.hr/>

Magnetic Resonance Spectroscopy and Measurement of Tau Epitopes of Autopsy Proven Sporadic Creutzfeldt-Jakob Disease in a Patient with Non-Specific Initial EEG, MRI and Negative 14-3-3 Immunoblot

Helena Šarac¹, Sanja Hajnšek², Silvio Bašić², Neven Henigsberg¹, Marko Radoš¹ and Goran Šimić¹

¹Croatian Institute for Brain Research, School of Medicine, University of Zagreb, Zagreb and Diagnostic Center »Neuron«, Zagreb, Croatia

²Department of Neurology, University Hospital Centre »Zagreb« and School of Medicine, University of Zagreb, Zagreb, Croatia

ABSTRACT

Limited potential of electroencephalogram (EEG), magnetic resonance images (MRI) and cerebrospinal fluid (CSF) test for 14-3-3 protein in the clinical diagnosis of sporadic Creutzfeldt-Jakob disease (sCJD) resulted in developments in diagnostic premortem techniques. Recent studies provided evidence that magnetic resonance spectroscopy (MRS) and measurement of total- tau (T-tau) and phospho-tau (P-tau) may be useful to identify patients with CJD. We combined detected metabolic changes in the brain by MRS and measured T-tau and tau-pT181 by ELISA, and tau-pT231 by Western blot in a patient with autopsy proven sCJD. Our results show that in contrast to negative CSF 14-3-3 protein, nonspecific EEG and MRI, MRS revealed metabolic alterations in regions of the brain that has appeared normal on MRI, and tau tests has shown measurable levels of phosphorylated and non-phosphorylated isoforms in CSF. We conclude that rapidly progressive dementia with negative 14-3-3 test and non-specific initial EEG and MRI must still be considered in the differential diagnosis of the sCJD. Combination of serial functional MRI along with MRS study and measurement of tau ratio could improve the early diagnosis of sCJD. The current case is the first attempt to study results of the use of MRS and tau tests in a case of sCJD with diagnostic dilemma.

Key words: sporadic Creutzfeldt-Jakob disease, magnetic resonance spectroscopy, tau-protein test

Introduction

Although the diagnosis of the sporadic Creutzfeldt-Jakob disease (sCJD) is primarily based upon the evolution of clinical symptoms such as dementia, ataxia and myoclonus, many diagnostic techniques including electroencephalogram (EEG), magnetic resonance imaging (MRI) and cerebrospinal fluid (CSF) 14-3-3 test are accepted in the premortem diagnostic criteria^{1,2}. Due to limited potential of these methods, some authors recently have concluded that diagnostic criteria for CJD may need revision and reliable diagnostic methods are required³. Magnetic resonance spectroscopy (MRS) selectively indicates neuronal destruction and the cell type most severely affected in sCJD and has already been included in the investigation of suspected CJD⁴. Although neuronal damage in sCJD may correspond with other dementia disorders, including new variant CJD (vCJD), Alzheimer's disease (AD) and human immunodeficiency virus (HIV), specific metabolic alteration may be seen in sCJD using MRS⁵. Raised concentrations of tau protein (T-tau) and hyperphosphorylated tau (P-tau) in CSF may be found in sCJD as well as in a variety of neurodegenerative processes. Concentration of CSF T-tau is several magnitudes higher in CJD than other dementia because of massive neuronal destruction⁶. In conditions associated with neurofibrillary tangles (NFT) or tau inclusions such as AD and FTD, but not in CJD, tau proteins get hyperphosphorylated³ and increased CSF concentration of P-tau may be found⁷. Riemenschneider et colleagues⁸ showed that simultaneous measurement of T-tau and P-tau by ELISA and calculation of P-tau/T-tau ratio discriminate CJD from other dementia processes completely. Zetterberg and colleagues³ reported usefulness of the opposite ratio calculation, and showed that T-tau/P-tau ratio were much higher in CJD, than in other dementia disorders. In a recent study, Goodall et colleagues⁹ showed that T-tau/P-tau ratio may be of diagnostic value in distinguishing between sCJD and vCJD but does not improve the diagnostic accuracy of tau protein alone in the diagnosis of sCJD⁹. We reported results of the MRS and tau tests including ELISA and Western blot immunoassay in a patient with autopsy proven sCJD.

Case Report

A 63-year-old woman, member of the negative history family, has been admitted in October 2005 to the Neurology Department due to memory loss, walking disturbances, visual loss, and speech difficulty, rapidly deteriorating over two months. Neurological examination revealed dementia (Mini Mental State Examination was 5), ataxia, akinetic mutism, visual loss and sensory hypersensitivity. Mental and neurological status deteriorated rapidly with a fatal outcome ten days after admission. Blood processing has shown elevated concentrations of the neuron specific enolase (NSE 20.74 µg/L) and normal level of S-100 protein. Sample of CSF was acquired via lumbar puncture at 9 AM according to the routine protocol and collected in polypropylene tubes in 1 mL aliquot. Aliquot was centrifuged at 4 °C at 10,000 g for 10 minutes and stored at -80°C until analysis. Analysis of the CSF has shown elevated glucose 4.00 mmol/L, proteins 0.87 g/L, high level of NSE 160 µg/L, S-100 protein 11.2 µg/L and negative 14-3-3 protein. By using monoclonal antibodies specific for amino acid threonine phosphorylated at 231 site, Western blot immunoassay was performed. Monoclonal antibody was generous gift from Peter Davies (Albert Einstein College of Medicine, Bronx, NY). Western blot immunoassay showed us a presence of relatively large amount of tau-phosphorylated at threonine231 (tau-pT231) protein in CSF sample. On the resulting membrane our protein is represented by strong black band at the height of approximately 70 kDa. The other bands visible on the membrane represent non-specific bindings (Figure 1). Simultaneously, mean concentration of CSF T-tau and tau phosphorylated at threonine-181

(tau-pT181) were measured using enzyme-like immunosorbent assay (ELISA), (Biosource Invitrogen kits). We measured concentration of both total tau protein and tau-pT181 according to the manufacturer's instructions. Extremely high concentration of total-tau was detected (12,100 pg/mL vs 234±92 pg/mL) and relatively low concentration of tau phosphorylated at threonine-181 (<20 pg/mL vs 54±33 pg/mL). We also included calculation of T-tau/ptau-pT181 ratio and tau-pT181/T-tau ratio in the CSF investigation. The tau-pT181/T-tau protein ratio was 0.0016 in our case and was significantly lower than cut-off for AD>0.33. The first EEG examination has shown non-specific slow activity 3 Hz diffusely along with periodic spike and wave complexes (PSWC) (Figure 2). Subsequent, preterminal EEG has shown one-per second three phases spike and wave pattern, which is specific for sCJD (Figure 3). Structural and functional imaging results were not consistent with the diagnosis of sCJD in the presented case. Initial and subsequent MRI scans showed diffuse high signal intensity over white matter without Gd-enhancement on T1 MRI, that was misconceived to demyelination lesions of the vascular type of dementia. The last MRI scan verified just slightly increased T2 and FLAIR MRI signal in caudate nuclei and putamen along with diffuse, cortico-subcortically distributed high signal of white matter (Figure 4). The subarachnoidal space was mildly enlarged without significant cortical atrophy characteristic for any dementia disorder. Magnetic resonance spectroscopy (MRS) has been measured in basal ganglia, parietal white matter and grey matter in frontal, occipital and cerebella locations. The MRS in the striatum exhibited moderate reduction in N-acetylaspartate (NAA) indicating loss of neuronal vitality, decreased NAA relative to creatines (Cr) up to 50% and slightly increased level of myoinositol (mI) up to 25% (Figure 5). The similar metabolite changes have been found in the insular cortex. The spectra of hippocampus showed severe reduction in NAA/Cr ratio up to 60%, decreased Cho/Cr ratio 20%, while the level of mI was within the normal range (Figure 6). The metabolite pattern in occipital grey matter and white matter showed low decrease in NAA up to 20%. (Figure 7). At autopsy, neuropathology and immunohistochemistry analysis confirmed sCJD. Spongiform changes and gliosis were seen microscopically throughout the gray matter, dominantly in the left temporal lobe. Immunohistochemical verification by using the antibody 12F10 has shown an immunoreactivity pattern suggestive of CJD with widespread pathological prion protein (PrP) deposits in both cerebral and cerebella cortices in a diffuse synaptic pattern. There are no changes suggestive of variant CJD PrP-fluoride plaques, neither unicentric nor multicentric. Sequencing of the prion protein gene (PRNP) to exclude mutations and characterize the polymorphism at codon 129 has not been made without informed consent of relatives.

Discussion

Difficulties in establishing the clinical diagnosis of the sCJD, especially early in the course of the disease require application of the expanded set of diagnostic techniques. In the recent years detection of MRS10 metabolic alterations of the brain and tau tests¹¹ take place in the clinical investigation of sCJD. Here, we reported the diagnostic accuracy of the measurement of tau epitopes and MRS of sCJD in a patient with unspecific EEG, MRI and negative CSF 14-3-3 protein. We combined Western blot immunoassay by using monoclonal antibodies specific for tau-pT231 and measurement CSF concentrations of T-tau and tau-pT181 using ELISA. Calculation of T-tau/tau-p181 ratio and tau-pT181/T-tau ratio were also performed to discriminate sCJD from vCJD and other dementia. Western blot immunoassay showed us a presence of large amount of CSF tau-phosphorylated at threonine 231 (tau-pS231) in CSF. Tau-phosphorylated at threonine 231 detected by using antibody specific for aminoacid

threonine phosphorylated at 231 site and is represented by strong black band at the height of approximately 70 kDa suggesting that the diagnosis of AD was highly likely, but not sCJD. Furthermore, we measured significantly raised concentration of CSF T-tau (12.100 pg/mL, normal value is 215 pg/mL \pm 75) by using ELISA (Biosource Invitrogen kits). On the other hand, concentration of tau-phosphorylated at threonine 181 was slightly raised and was less than 20 pg/mL. To reach the best result for distinguishing CJD from other diagnoses, we used cut-off values for T-tau in sCJD12 (>1300 pg/mL) and cut-off values for tau-pT181 in sCJD9 (>50 pg/mL), and combined tests for T-tau, T-tau/tau-pT181 ratio and tau-pT181/T-tau (<60) ratio that were previously described⁹. Riemenschneider et al. previously demonstrated that calculation of P-tau/T-tau ratio in CSF may be a useful maker to discriminate CJD from other neurodegenerative diseases⁸. Calculation of tau-pT181/T-tau was 0.0017 and is several times smaller than cut-off for AD diagnosis (>0.33)¹³. Calculation of T-tau/tau-pT181 ratio was 605. It is much higher than cut-off value for CJD, and discriminates this case of sCJD from other non-CJD dementia disorders. Comparing to previous studies tau-pT181/T-tau separated this patient from other dementia including AD with a high sureness⁹. Lower concentrations of tau-pT181 may reflect a lower extent of phosphorylation at the threonine 181 and suggests that neurofibrillary tangles (NFT) are low or absent in sCJD14 in opposite to the AD. Other CSF biomarkers NSE and S-100 protein were extremely high several and were several magnitudes higher than in cut-off for other dementia. However, these markers show less sensitivity and specificity. EEG, MRI and CSF 14-3-3 test result were not consistent with the diagnoses in sCJD patients. Initial EEG examination showed diffuse slow waves bilaterally. Subsequent EEG has shown non-specific periodical sharp wave complexes (PSWC). This pattern may be seen early in the disease course in about 75% cases of sCJD15, but it could also be seen in metabolic encephalopathies, hereditary leukoaryosis, infectious encephalitis. Only preterminal EEG has shown one-per second sharp wave pattern, typical EEG changes that occurs most often in patients with sCJD and have average sensitivity and specificity of 92%¹⁵ in comparison to vCJD. However, this case confirms that EEG has limited diagnostic potential in sCJD because specific EEG pattern does not appear until the last phase of the disease. The view that CSF 14-3-3 protein represents reliable marker of extensive brain destruction and is highly sensitive and specific in sCJD and vCJD16–20 has recently been challenged. Geschwind et al. recently found that only 17 of 32 patients with autopsy-proven CJD had a positive result for the 14-3-3 test²¹. False negative results in autopsy-proven, sCJD, and false positive results in other neurological disorders including AD, FTD, viral encephalitis, amyotrophic lateral sclerosis, multiple sclerosis, stroke, vascular dementia, paraneoplastic syndromes¹⁷ limit the potential of this marker. Negative 14-3-3 test in this case does not exclude the diagnosis of CJD as only one CSF 14-3-3 protein test was performed at later stage of the disease. Positive CSF 14-3-3 protein could be found in almost all cases of sCJD within one year from first symptoms of disease, but it could be negative after one year from the onset^{12,22,25,26}. Structural and functional imaging results were not consistent with the diagnosis in this patient. MRI showed diffuse high signal intensity of white matter, without characteristic signal change within basal ganglia or thalami, cortical atrophy, occipital cortical high signal intensity, high signal intensity over white matter^{20,23–25}. Previous studies showed that initial MRI scans shows signal change within basal ganglia in high proportion of sCJD patients (70%), and subsequent MRI scans usually demonstrate low signal intensity of basal ganglia, increased T2 signals within the white matter and diffuse cortical atrophy^{20,23–25}. Cortico-subcortical hyperintensities over white matter usually develop in the later stage of the disease, and are linked with slow clinical course and longer duration of illness²⁵. Serial MR scans in our case may be foolproof of these findings. In contrast to MRI findings, MRS showed results consistent with the diagnosis of sCJD. We have found a

significant reduction in NAA/Cr ratio in regions of the brain that appeared normal on MRI (lack of T2/FLAIR/DWI signal changes). Decreased NAA represents a robust but nonspecific marker for neuronal loss or dysfunction^{26,27}. In previous studied cases, NAA/Cr ratio was normal in spite of the obvious FLAIR/DWI changes, that might indicate spongiform changes of still viable cells²⁸. Studies showed that these metabolic changes occur early in the natural history of CJD, and may not be found during the period of incubation or before disease onset. However, MRS metabolic changes occur earlier than MRI changes. Decreased NAA (neuronal-axonal marker) up to 50% was detected in all measured voxels, increased mI/Cr ratios were found in basal ganglia (striatum) and insular cortex, along with normal level of Cr, and slightly reduced Cho/cr ratio for 10–20%. Increased level of mI occurs early in the history of CJD and AD, but not in other dementia and healthy subjects. While NAA/Cr ratio is more or less reduced in all measured voxels in CJD, decreased NAA/Cre ratio may be found only in hippocampus in early stage of AD and additionally in primary cortex in the later stages of the AD. The increased mI/Cr ratios were calculated in basal ganglia (caudate nucleus and putamen) and insular cortex. The most prominent increased level of mI may be found in AD (hippocampus and cerebral cortex), in vCJD (pulvinar thalami) as well as in herpes simplex encephalitis, neuro-cysticercosis and occasionally in progressive multifocal leucoencephalopathy. The severe reduction in NAA/Cr ratio in all measured voxels and increased level of mI exclusively in striatum show promise as an early biomarker for sCJD. At autopsy, immunohistochemistry using the antibody 12F10 has shown an immunoreactivity pattern suggestive of sCJD. There were no PrP-plaques suggestive of variant CJD (vCJD). Verification of the PrP by Western blot immunoassay is the most reliable diagnostic marker for all forms of CJD²⁹. Sequencing of the prion protein gene (PRNP) has not been made due to a lack of informed consent of relatives. By using appropriate immunohistochemical techniques, false-positive results are not found.

Conclusion

The case presented suggests that patients with rapidly progressive dementia, ataxia and myoclonus, along with non-specific MRI, EEG and negative CSF 14-3-3 protein, must still be considered in the differential diagnosis of sCJD. Serial fMRI, MRS and combined tau tests may represent powerful diagnostic methods for CJD in a patients with unspecific diagnostic criteria. Detection of the decreased NAA/Cr ratio in all regions of the brain along with increased level of mI within the striatum may discriminate between sCJD and other dementia disorders including vCJD with a high sureness. Using monoclonal antibodies specific for tau-pT231, Western blot immunoassay detects but does not precisely measured concentration of tau-pT231 in CSF. Only the quantification of tau epitopes may improve detection and differential diagnosis of dementia disorders. Present case supports recent study that using of monoclonal antibodies, measurement of T-tau and tau-pT181 by ELISA and calculation of tau-pT181/T-tau and T-tau/tau-pT181 ratios may discriminate sCJD from other dementia. At the same time, these tests do not improve the diagnostic accuracy of tau protein alone in distinguishing between sCJD and vCJD. Proton spectroscopy showed specific metabolic alterations in the areas of the brain affected by neuronal destruction and could be of diagnostic value in distinguishing between sCJD and vCJD, as well as other dementia disorders.

REFERENCES

1. ZERR I, POSER S, *APMIS*, 110 (2002) 88. —
2. WORLD HEALTH ORGANIZATION: Human transmissible spongiform encephalopathies. *Wkly Epidemiol Rec*, 47 (1998) 361. —
3. ZETTERBERG H, BLENNOW K, *Neurol Sci*, 25 (2004) 301. —
4. BRUHN H, WEBER T, THORWIRTH V, FRAHM J, *The Lancet*, 337 (1991) 1610. —
5. CECIL KM, LENKINSKI RE, *Neuroimaging Clin N Am*, 8 (1998) 863. —
6. BUERGER K, OTTO M, TEIPEL SJ, ZINKOWSKI R, BLENNOW K, DeBERNARDIS J, KERKMAN D, SCHRODER J, SCHONKNECHT P, CEPEK L, McCULLOCH C, MOLLER HJ, WILTFANG J, KRETZSCHMAR HA, HAMPEL H, *Neurobiol Aging*, 27 (2006) 10. —
7. SJOGREN M, DAVIDSSON P, TULLBERG M, MINTHON L, WALLIN A, WIKELSO C, GRANERUS AK, VANDERTICHELE H, VANMECHELEN E, BLENNOW K, *J Neurol Neurosurg Psychiatry*, 70 (2001) 624. —
8. RIEMENSCHNEIDER M, WAGENPFEIL S, VANDERSTICHELE H, OTTO M, WILTFANG J, KRETZSCHMAR H, VANMECHELEN E, FÖRSTL AND KURZ A, *Molecular Psychiatry*, (2003); 343.—
9. GOODALL CA, HEAD MW, EVERINGTON D, IRONSIDE JW, KNIGHT RSG, GREEN AJE, *J Neurol Neurosurg Psychiatry* 77 (2006) 89. —
10. SHYU WC, LEE CC, HSU YD, LIN JC, LEE JT, LEE WH, TSAO WL, *J Neurol Sci*, 138 (1996) 157. —
11. EVERBROECK B, GREEN AJ, VANMECHELEN E, VANDERSTICHELE H, PALS P, SANCHEZ-VALLE R, CORRALES NC, MARTIN JJ, CRAS P, *J Neurol Neurosurg Psychiatry*, 73 (2002) 79. —
12. BLENNOW K, JOHANSSON A, ZETTERBERG H, *Int J Mol Med*, 16 (2005) 1147.—
13. HU JJ, HE SS, WANG X, DUAN QH, GRUNDKE-IQBAL I, IQBAL K, WANG J, *Am J Pathol*, 160 (2002) 1269. —
14. SAIZ A, GRAUS F, DALMAU J, *Ann Neurol*, 46 (1999) 774. —
15. BROWN P, GIBBS CJ, RODGERS- JOHNSON P, ASHER DM, SULIMAMP, BACOTE A, GOLDFARB LG, GAJSUDEK DC, *Ann Neurol*, 35 (1994) 513. —
16. BEAUDRY P, COHEN P, BRANDEL JP, DELASNERIE-LAUPRETRE N, RICHARD S, LAUNAY JM, LAPLANCHE JL, *Dement Geriatr Cogn Disord*, 10 (1999) 40. —
17. JOHNSON RT, GIBBS CJ Jr, *N Eng J Med* 339 (1998) 1994. —
18. HSICH G, KENNEY K, GIBBS CJ, LEE KH, HARRINGTON MG, *N Engl J Med*, 335 (1996) 924. —
19. ZEIDLER M, STEWART GE, BARRACLOUGH CR, BATEMAN DE, BATES D, BURN DJ, COLCHESTER AC, DURWARD W, FLETCHER NA, HAKINS SA, MACKENZIE JM, WILL RG, *Lancet*, 350 (1997) 903. —
20. ZERR I, SHULZ-SCHAEFFER WJ, GIESE A, BODEMER M, SCHROTER A, HENKEL K, TSCHAMPA HJ, WINDL O, PFAHLBERG A, STEINHOFF BJ, GEFELLER O, KRETZSCHMAR HA, POSER S, *Ann Neurol*, 48 (2000) 323. —
21. GESSHWIND MD, MARTINDALE J, MILLER D, DeARMOND SJ, UYEHARA-LOCK J, GASKIN D, KRAMER JH, BARBARO NM, MILLER BL, *Arch Neurol* 60 (2003) 813. —
22. VAN EVERBROECK B, BOONS J, CRAS P, *J Neurol Neurosurg Psychiatry*, 107 (2005) 355. —
23. GIBBS Jr CJ, GAJDUSEK DC, ASHER DM, ALPERS MP, BECK E, DANIEL PM, MATTHEWS WB, *Science*, 161 (1998) 388. —

24. TAKAMIYA K, IWASAKI Y, KINOSHITA M, J Neurol Sci, 149 (1997) 197. —
25. KOVANEN J, ERKINJUNTTI T, LIVANAINEN M, KETONEN L, HALTIA M, SULKAVA R, SIPPONEN, J Comput Assist Tomogr, 9 (1985) 125. —
26. JESSEN F, BLOCK W, TRABER F, KELLER E, FLACKE S, PAPASSOTIROPOULOS A, LAMERICHS R, HEUN R, SCHILD HH, Neurology 55 (2000) 684.—
27. MILLER BL, MOATS RA, SHONK T, ERNST T, WOOLEY S, ROSS BD, Pediatrics, 101 (1998) 7. —
28. OPPENHEIM C, ZUBER M, GALANAUD D, DETILLEUX M, BOLGERT F, MAS JL, CHIRAS J, MEDLER JF, J Neurol, Neurosurg and Psychiatry, 75 (2004) 1066. —
29. HAYWARD PAR, BELL JE, IRONSIDE JW, Neuropathol Appl Neurobiol, 20 (1994) 375.

H. Šarac

Croatian Institute for Brain Research, School of Medicine, University of Zagreb, Diagnostic Center »Neuron«,

Šalata 12, HR-10000, Croatia

e-mail: helenasarac@hi.t-com.hr

Legends

Fig. 1. Western blot immunoassay shows strong black band at the height of approximately 70 kDa representing large amount of phospho-tau₂₃₁ protein detected by antibody specific for aminoacid threonin phosphorylated at 231 site.

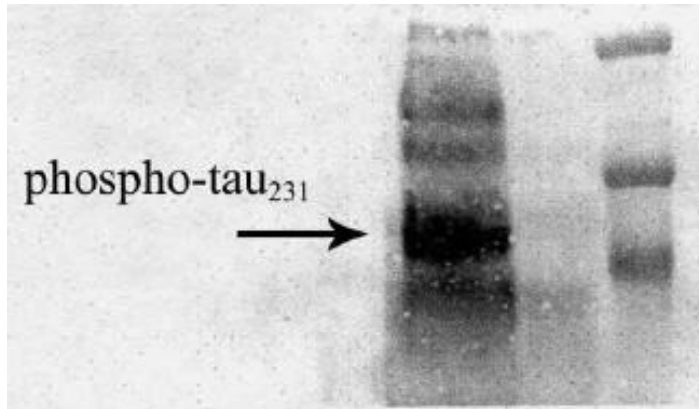


Fig. 2. Initial EEG examination shows non-specific slow activity 3 Hz diffusely and periodic spike and wave complexes (PSWC). EEG – electroencephalogram.

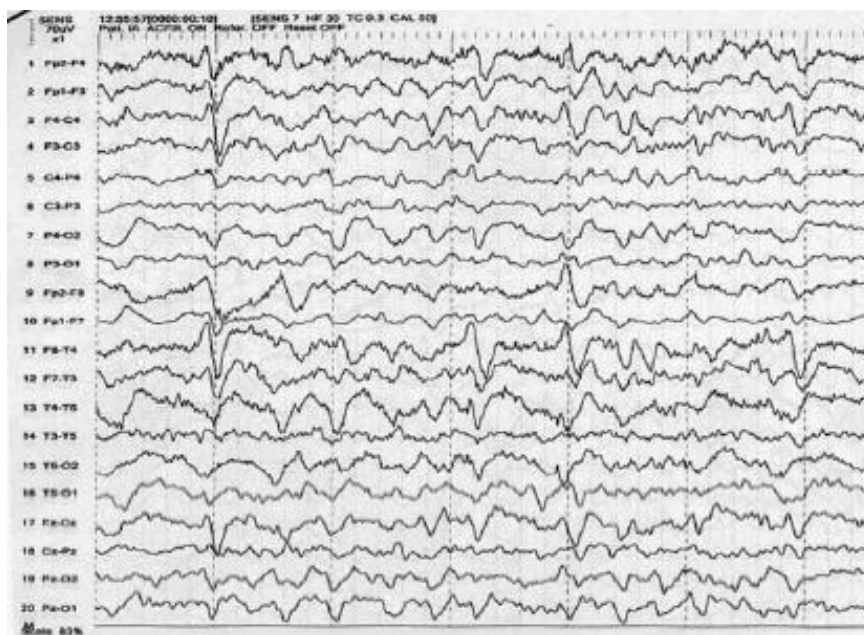

Fig. 3. Preterminal EEG (7 days after initial EEG) shows one per second three phase spike and wave pattern, the most specific for sCJD. (sCJD – sporadic Creutzfeld-Jakob disease).

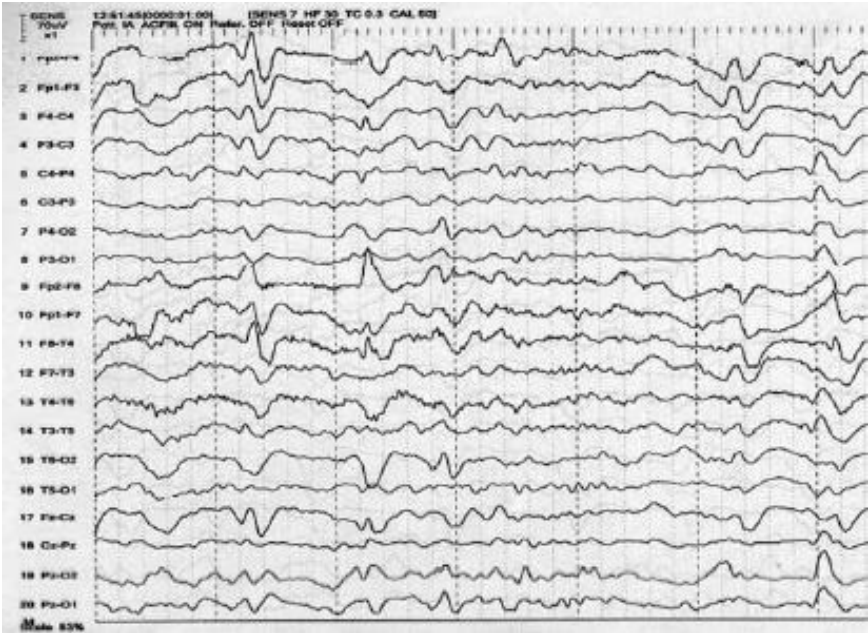


Fig. 4. Axial T2WI and FLAIRWI MRI show increased signal intensity in caudate nuclei and more prominent, diffusely distributed, cortico-subcortical hyperintensities of white matter. (MRI – magnetic resonance imaging).

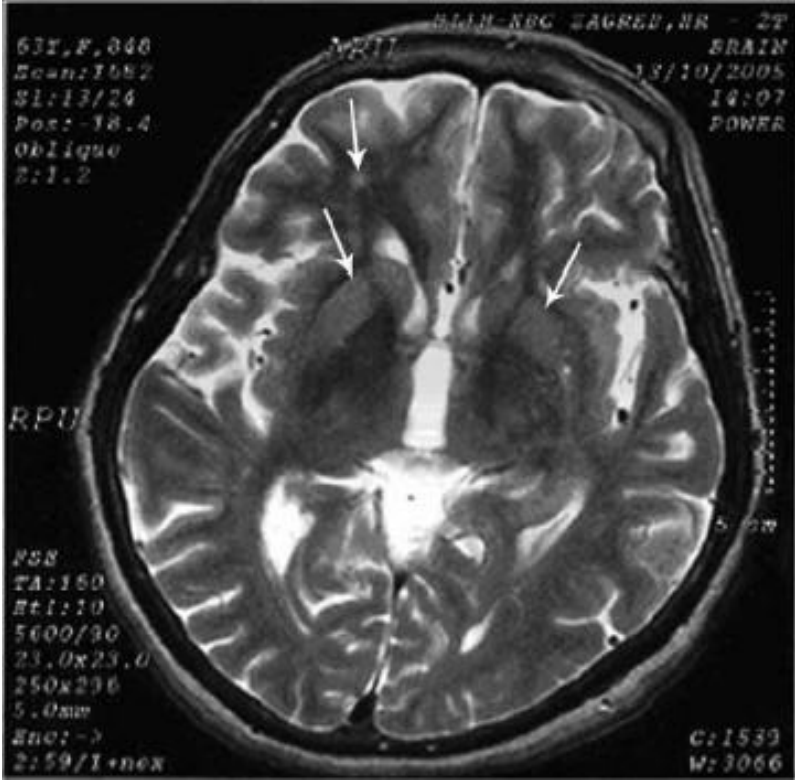


Fig. 5. MR spectroscopy in all examined regions of the brain shows reduced NAA/Cr ratio up to 40%. Levels of Cho and mI were within the normal range. (MRS-magnetic resonance spectroscopy, NAA – N – acetylaspartate, Cr – creatine, Cho – choline, mI – myo-inositol)

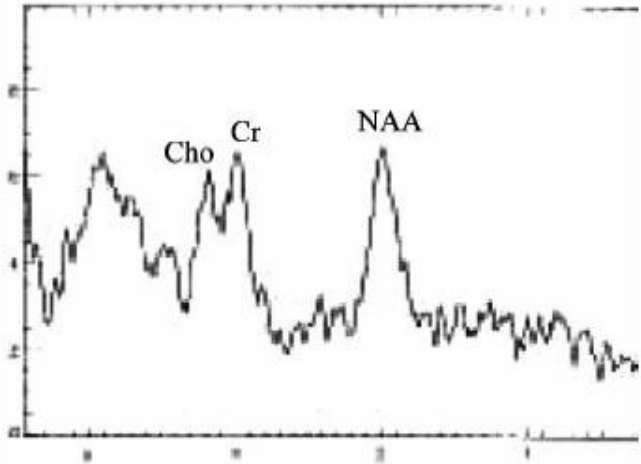


Fig. 6. MRS of the hippocampus showed reduced NAA/Cr and Cho/Cr ratio, and normal mI level.

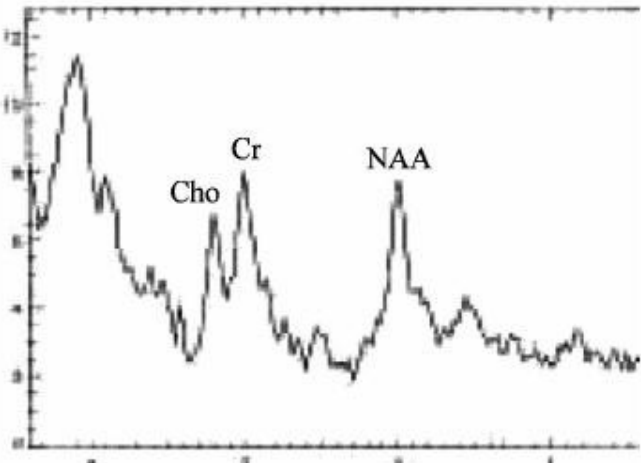
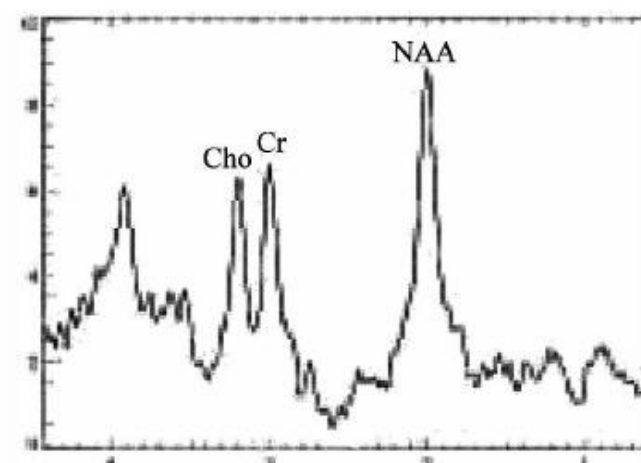


Fig. 7. MRS of the occipital grey matter showed solely less prominent decrease in NAA.



SPEKTROSKOPIJA MAGNETSKOM REZONANCIJOM I MJERENJE TAU EPITOPA U DIJAGNOSTICI SPORADIČNOG OBLIKA CREUTZFELDT-JAKOBOVE BOLESTI U PACIJENTICE S NESPECIFIČNIM EEG, MRI I NEGATIVNIM 14-3-3 TESTOM U CEREBROSPINALNOM LIKVORU

SAŽETAK

Ograničene mogućnosti elektroencefalografije (EEG), magnetske rezonancije (MRI) i testa na 14-3-3 protein u cerebrospinalnom likvoru (CSL) utjecale su na razvitak novih dijagnostičkih metoda u dijagnostici sporadičnog oblika Creutzfeldt-Jakobove bolesti (sCJB) premortalno. Novije studije pokazale su da spektroskopija magnetskom rezonancijom (MRS) i mjerenje koncentracije tau epitopa mogu u CSL koristiti u identificiranju oboljelih of sCJB. Mi smo simultano određivali metaboličke promjene mozga koristeći MRS i mjerili koncentracije ukupnog i fosforiliranog tau proteina (tau-pT181) u CSL koristeći ELISA metodu, te odredili prisutnost tau-pT231 proteina metodom Western blot u CSL pacijentice sa obdukcijom dokazanom sCJB. Naši rezultati pokazuju da usprkos negativnom nalazu 14-3-3 proteina u CSL, nespecifičnim promjenama na inicijalnom EEG-u i MRI, protonska spektroskopija je otkrila specifične metaboličke promjene i u regijama mozga koje su se doimale normalnim na MRI, a tau testovi su pokazali povišene vrijednosti nefosforiliranog i fosforiliranog tau proteina u CSL. Zaključujemo da kod brzo progresivne demencije sa negativnim 14-3-3 testom u CSL, uz nespecifične EEG i MRI promjene, ne treba isključiti sCJB. Kombinacija serijskog funkcionalnog MRI (fMRI), protenske spektroskopije i MRS uz mjerenje koncentracije nefosforiliranog i ukupnog tau proteina u CSL može unaprijediti dijagnostiku sCJB. Prema našim spoznajama, ova studija po prvi put opisuje istovremenu primjenu MRS tehnike i tau testova u identifikaciji dijagnostički dvojbenog oblika sCJB.