

# Third Nerve Palsy

---

**Habek, Mario; Brinar, Vesna V.; Ozretić, David**

*Source / Izvornik:* **The Journal of Emergency Medicine, 2010, 39, e131 - e133**

**Journal article, Accepted version**

**Rad u časopisu, Završna verzija rukopisa prihvaćena za objavljivanje (postprint)**

<https://doi.org/10.1016/j.jemermed.2007.12.037>

*Permanent link / Trajna poveznica:* <https://um.nsk.hr/um:nbn:hr:105:477786>

*Rights / Prava:* [In copyright](#)/[Zaštićeno autorskim pravom.](#)

*Download date / Datum preuzimanja:* **2024-07-18**



*Repository / Repozitorij:*

[Dr Med - University of Zagreb School of Medicine  
Digital Repository](#)





### **Središnja medicinska knjižnica**

Habek, M., Brinar, V. V., Ozretić, D. (2008) *Third Nerve Palsy*. The Journal of Emergency Medicine, [Epub ahead of print, Corrected Proof].

<http://www.elsevier.com/locate/issn/0736-4679>

<http://dx.doi.org/10.1016/j.jemermed.2007.12.037>

<http://medlib.mef.hr/419>

University of Zagreb Medical School Repository

<http://medlib.mef.hr/>

## **Third nerve palsy**

Mario Habek, MD<sup>1</sup>, Vesna V. Brinar, MD, PhD<sup>1</sup>, David Ozretić, MD<sup>2</sup>

From the:

<sup>1</sup>Referral Center for Demyelinating Diseases of the Central Nervous System, University Department of Neurology, Zagreb School of Medicine and University Hospital Center, Zagreb, Croatia

<sup>2</sup>Department of Radiology, Zagreb School of Medicine and University Hospital Center, Zagreb, Croatia

Word count: 497

References No.: 6

**Key words:** Third nerve palsy, internal carotid artery, occlusion

## **Case report**

A 75-year old patient presented to our emergency department because of pain behind the left eye, double vision and left ptosis. His medical history, beside arterial hypertension which was well controlled with lisinopril, was unremarkable. Neurological examination revealed left complete ptosis, left pupil was midriatic with no reaction to light stimuli or accommodation and consensual reaction was absent. The left eye was positioned to the left side and down (Figure 1). This finding was consistent with complete third nerve palsy. The rest of neurological examination was normal.

On admission emergency multi-slice computed tomography (MSCT) and angiography (MSCTA) were performed and revealed total occlusions of both internal carotid arteries (Figure 2). Revascularization on the right side was over the supraclinoid segment of the ophthalmic artery, and on the left side opacification of the cavernous and supraclionid segment was visible with revascularization from posterior communicating, left posterior cerebellar and ophthalmic arteries (Figure 3). Brain MRI revealed preexisting vascular lesion in the vascularization area of the posterior branch of the middle cerebral artery, which was clinically silent.

Electrocardiogram revealed atrial fibrillation. An echocardiogram showed concentric hypertrophy of the left ventricle, akinesia of the inferior wall, ejection fraction (EF) of 50% and aortic insufficiency without gradient (15 mmHg). Laboratory analysis showed elevated cholesterol level 7.3 mmol/l (normal values 0-5.0). Blood glucose levels were repeatedly normal.

The anticoagulation therapy was started with warfarin, and therapy with simvastatin was started. On follow up visits one and six months later the patient was without new symptoms, but complete third nerve palsy persisted.

## **Discussion**

According to the recently published guidelines on managing of third nerve palsy, acute, complete internal and external affection of the oculomotor nerve represent the highest risk for cerebral aneurysm of the posterior communicating artery (3), and emergency neuroimaging is recommended. Therefore, in our patient we performed emergency MSCTA in searching for cerebral aneurysm. An incidental finding was occlusion of both internal carotid arteries. There are couple of more cases of isolated third nerve palsy associated with carotid artery stenosis in the literature.(1,2) The most interesting paper that suggests causality of third nerve palsy and carotid artery stenosis is by Balcer and colleagues, who showed complete recovery of third nerve palsy after emergent carotid endarterectomy was performed. (1) The presumed mechanism of this association is consistent with the known blood supply to the oculomotor nerve within the cavernous sinus. Most of the published reviews dealing with the imaging of patients with isolated third nerve palsy do not recommend color Doppler of the carotid arteries as a routine procedure (4). Although our patient had hypertension, which is a known risk factor for vascular lesion of the oculomotor nerve, both internal and external functions of the nerve were equally involved, implying involvement of oculomotor nerve artery at its origin. Based on our case report and literature review we suggest that every patient with isolated

complete third nerve palsy in whom the mass lesion is excluded with appropriate neuroimaging, should then undergo evaluation for occlusion of the carotid arteries.

## References

- 1) Balcer LJ, Galetta SL, Yousem DM, Golden MA, Asbury AK: Pupil-involving third-nerve palsy and carotid stenosis: rapid recovery following endarterectomy. *Ann Neurol* 1997;41:273-6.
- 2) Kapoor R, Kendall BE, Harrison MJ: Permanent oculomotor palsy with occlusion of the internal carotid artery. *J Neurol Neurosurg Psychiatry* 1991;54:745-6.
- 3) Lee AG, Hayman LA, Brazis PW: The evaluation of isolated third nerve palsy revisited: an update on the evolving role of magnetic resonance, computed tomography, and catheter angiography. *Surv Ophthalmol* 2002;47:137-57.
- 4) Lee AG, Onan HW, Brazis PW, Prager TC: An imaging guide to the evaluation of third cranial nerve palsies. *Strabismus* 1999;7:153-68.

## Figures

Figure 1. A picture of ocular findings in presented patient. Note that only abduction of the left eye is possible. Abbreviations: l - left; r - right; u - up; d - down.

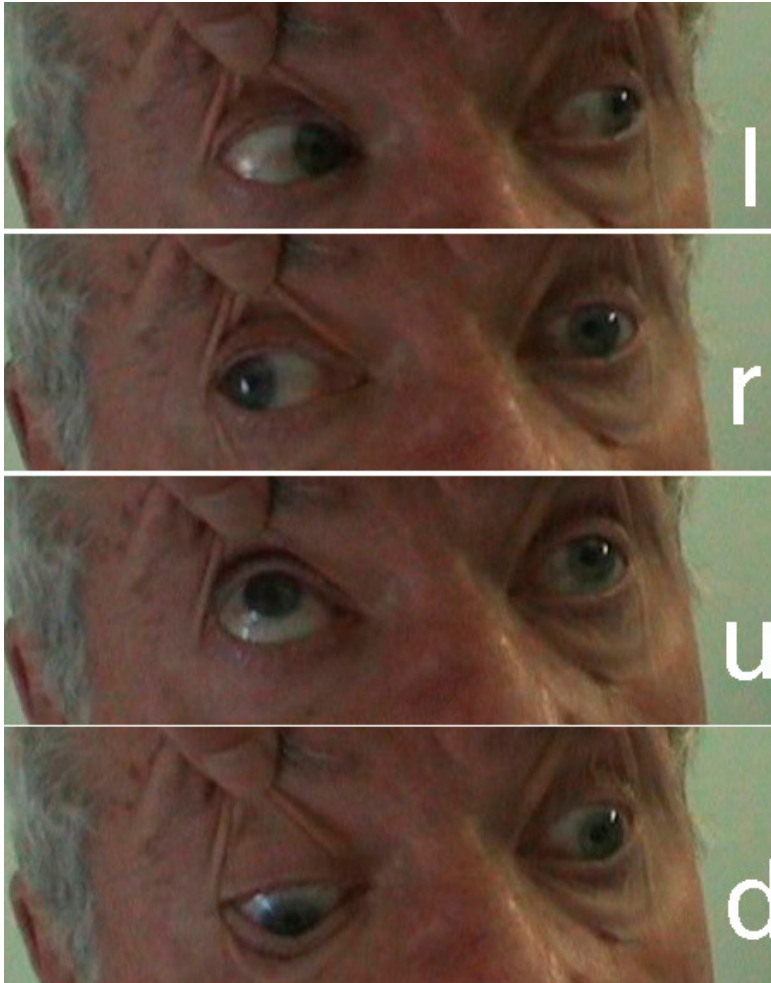




Figure 2. Multi-slice computed tomography angiography showing lack of contrast in both internal carotid arteries (aci) in cavernous sinus (cs) segment; note the contrast in the cavernous sinus.

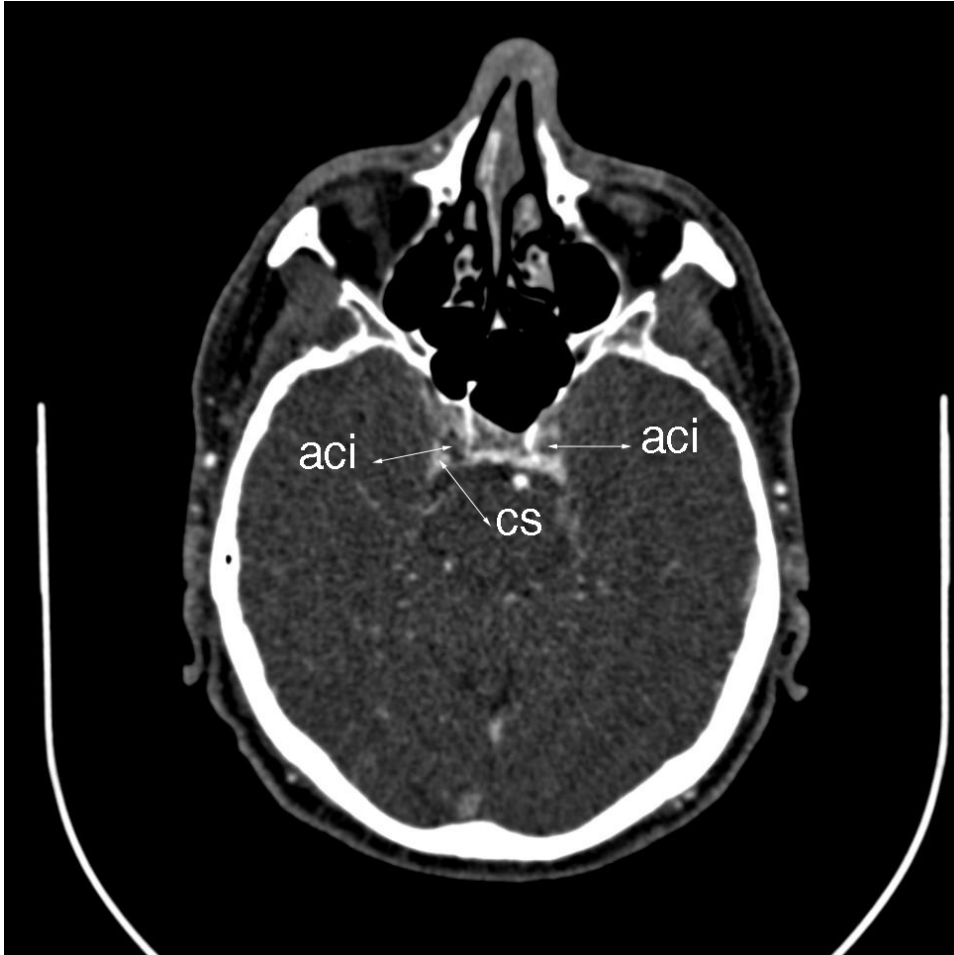

Figure 3. MSCT angiography reconstruction. A) antero-posterior view; B) latero-lateral view; C) transversal section. See text for description. Abbreviations: aci – internal carotid artery; ao – ophthalmic artery; acoa – anterior communicating artery; acop – posterior communicating artery; acm – medial cerebral artery; aca – anterior cerebral artery; acp – posterior cerebral artery

