

The analysis of walk cycle in patients with spastic cerebral palsy after surgical management on the lower extremity

Šakić, Šimun; Šakić, Katarina; Buković, Nevia; Buković, Damir; Zlojtro, Marija; Pavić, Mato

Source / Izvornik: **Collegium Antropologicum, 2007, 31, 781 - 786**

Journal article, Published version

Rad u časopisu, Objavljena verzija rada (izdavačev PDF)

Permanent link / Trajna poveznica: <https://urn.nsk.hr/urn:nbn:hr:105:601957>

Rights / Prava: [In copyright](#) / [Zaštićeno autorskim pravom.](#)

Download date / Datum preuzimanja: **2025-02-02**



Repository / Repozitorij:

[Dr Med - University of Zagreb School of Medicine
Digital Repository](#)



The Analysis of Walk Cycle in Patients with Spastic Cerebral Palsy After Surgical Management on the Lower Extremity

Šimun Šakić¹, Katarina Šakić², Nevia Buković³, Damir Buković⁴, Marija Zlojtro⁴ and Mato Pavić⁴

¹ Department of Orthopedic Surgery, University Hospital Center »Zagreb«, School of Medicine, University of Zagreb, Zagreb, Croatia

² Department of Anesthesiology, Reanimatology and Intensive Care, University Hospital Center »Zagreb«, School of Medicine, University of Zagreb, Zagreb, Croatia

³ Croatian Institute of Retirement Insurance, Zagreb, Croatia

⁴ University Hospital for Gynecology and Obstetrics, Zagreb, Croatia

ABSTRACT

Gait pattern is a frequent problem in cerebral palsy. The aim of the investigation is the evaluation of proximal femur normalization and/or pelvis normalization after surgical correction and simultaneous operations on soft tissues of lower limbs, as well as walk analysis. From 1980. to 2000. were operated 856 patients, 476 male and 380 female, between 1–51 years. Basic walk parameters were analyzed: step length, speed and the number of steps in one minute (cadence). 75.25% of patients had good results with improved of centrum collum diaphysis (CCD) and angle of anteversion (AV) or ante-torsion (AT) for 70%, and more independent walking with contracture corrections and decreased spasticism. The best results were achieved with simultaneous two-side operations, with patients' age between 1 and 3, achieving independent walking. More operations at the same time significantly reduce spasticism – one anesthesia, one immobilization, and later same time post-operative physical therapy and satisfactory better results.

Key words: spastic cerebral palsy, hip surgery, gait analysis

Introduction

Gait pattern is a frequent problem in children with cerebral palsy. Due to unsatisfactory results after physical treatment in the process of curing infantile cerebral paresis of spastic type, there are still dilemmas regarding the indications for orthopedic-surgical corrective treatment to improve walking. Good results with walk improvements have been achieved with San Diego procedures. However, there are complications with avascular necrosis of the femoral head (1). Cornell MS et al. emphasize good results after adductor percutaneous tenotomies with open neurectomy of the superficial branch of the n. obturatorius in the prevention and treatment of hip subluxation and dislocation. A number of authors achieved good results through operations on soft tissues in hip area in spastic cerebral paresis (Spruit M. and Fabri G., Cottalorda J. et al.) with 20–92% improvement of clinical results^{2–6}.

The combination of simultaneous operations on soft tissues and skeleton or only on skeleton, even with degenerative changes of the skeleton in hip area, gave good results (researched by the following authors: Flynn JM and Miller F., Noonan K.J. et al., Schorle CM. and Monolikas G.). Karol L.A. emphasizes and confirms that simultaneous operations on lower limbs with spastic cerebral paresis – hip, knee, and foot (talocrural joint) lead to static and dynamic improvement of patients' walk^{7–11}. Grieve DM did not use Polgo goniometry to analyze the walk of the patient with brain lesion, neither did a number of other authors^{12,13}.

The goal of the investigation is to evaluate proximal femur and/or pelvic normalization after surgical correction and simultaneous operations on soft tissues of lower limbs, as well as walk analysis.

Materials and Methods

856 operated patients with cerebral palsy, 476 male and 380 female, were analyzed at the Department of Orthopedic Surgery (School of Medicine, University of Zagreb). The patients were between 1 and 51 years old, with the average age of operation 11.5. All patients or their guardians gave pre-operational consent for the operation. The biggest number of patients had spastic diparesis – 693 (80.95%), spastic hemiparesis 102 (11.91%), and the smallest number had spastic tetraparesis – 63 (7.35%). In the period of two decades, from 1980. to 2000. 3758 operations were performed, 308 of which were correctional proximal femur osteotomies, due to the anteversion and valgus or dislocation of the femur head. Other operations were performed mainly on soft tissues or were combined. The biggest number of operations was simultaneous two-side operations: open hip adductor tenotomy, elongation of knee flexor and Achilles tendon, also Achilles tenoplasty; 12.1% of operations were corrective osteotomies of proximal femur, with or without pelvis osteotomy (Salter, Penberton, Dega, triple osteotomy; open hip repositioning). Orthopedic-surgical procedures were done under general or regional anesthesia with sedation, as shown in Tables 1 and 2. Post-operative condition was supervised in the Post-Anesthesia Care Unit with Tramal analgesia, using VAS scale, and diazepam sedation according to the protocol.

Before operations routine x-ray of hips in anterior-posterior direction was done, as well as Ruppstein-Muller. Projected and real hip was measured AV(AT), as well as CCD angle. Walk analysis was conducted according to Fischer and Schneider, as well as Polgon goniometry, comparing the results with control group of healthy examinees^{13–18}. Basic walk parameters were tested: step length, walking speed, and the number of steps in one

TABLE 1
TYPES OF OPERATIONS ON SOFT TISSUES

Type of operation	Number of operations	Percentage %
A/ two-side open tenotomy of hip adductor, knee flexor elongation (ischio-crural muscles), and Achilles tendon elongation 3x2	2115/3758	56.27
B/ two-side elongation of Achilles tendon and knee flexor 2x2	532/3758	14.15
C/ two-side Achilles tendon plastic	402/3758	10.60
D/ one-side Achilles tendon plastic, knee flexor elongation, open hip adductor tenotomy 3x1	125/3758	3.30
E/ subspinal hip flexor tenotomy, transposition of m. iliopsoas	180/3758	4.78

TABLE 2
TYPE AND NUMBER OF ORTHOPAEDIC-SURGICAL TREATMENTS ON THE SKELETON

Type of operation	Number	Percentage %
A/ correctional osteotomy of proximal femur (varisation and derotation) with or without pelvic osteotomy -Salter, Penberton, Dega, Chiari, triple pelvic osteotomy	308/3758	8.19%
B/ open hip repositioning	29/3758	0.77%
C/ total hip endoprothesis	2/3758	
D/ proximal femur resection	2/3758	
E/ combination of the above	65/3758	1.70%

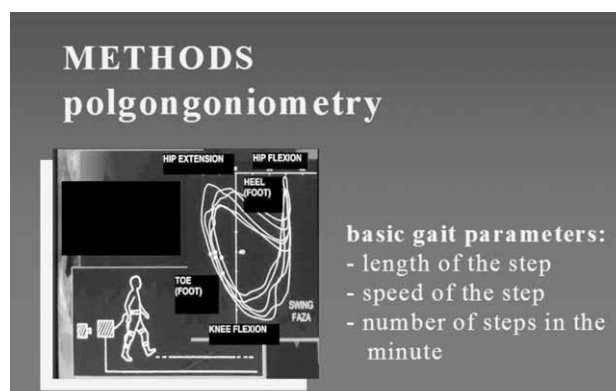


Fig. 1. Schematic description of a child connected to the machine – Polgon goniometer, and normal heart-shaped diagram.

minute (cadence). Figure 1 show a child connected to the machine – Polgon goniometer, and a normal heart-shaped diagram.

Intelligence Quotient (IQ) was average in most patients. 10% of patients had significant mental retardation.

The greatest number, 93.7%, had brain lesion perinatal – infantile cerebral paresis. Brain ultra sound, electroencephalography and computerized brain tomography (CT) confirmed the lesion.

Control group: 1–20, average age 10.3, shown in Table 3.

TABLE 3
FREQUENCY AND LENGTH OF PATIENTS CONTROL AFTER OPERATION (1–20 YEARS, AVERAGE AGE 11.3)

	Number of patients	Percentage %
a/ age: 1–5	157/856	18.30
b/ age: 6–10	197/856	23.00
c/ age: 11–15	412/856	48.00
d/ age: 16 +	90/856	10.51

Statistical methods

Data was analyzed using Mann-Whitney test, Pearsons chi-square test, canonical discriminatory function. The threshold for statistical significance was set at $P < 0.05$.

Results

Before surgical correction 409 patients (47.78%) with cerebral paralysis walked independently, 352 (41.12%) with help, and 95 (11.09%) did not walk. Parallel radiological analysis of control group shows there are no significant differences of proximal femur after corrective varisation and derotational operation of proximal femur and simultaneous operations on soft tissues of the hip and distally (Figure 2).

Projected and real angle were measured AV(AT), as well as CCD angle. Average projected angle AV(AT) was 52 , CCD angle 172 , real angle AV(AT) 67 , and CCD angle 163 . Hip dislocation in terms of the total number of patients was 3.53%.

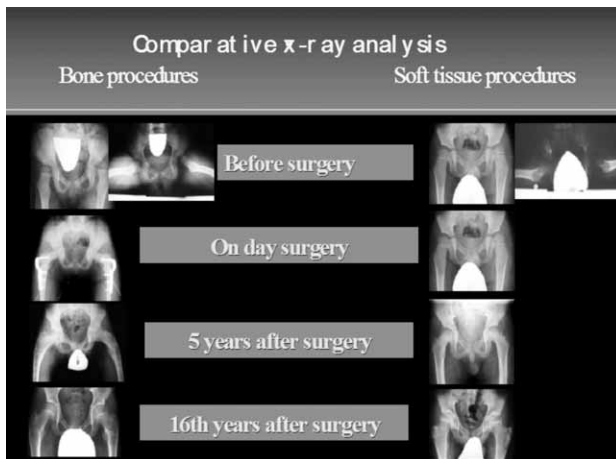


Fig. 2. Parallel radiological analysis of proximal femur operation. Control radiological analyses show that there are no significant differences in proximal femur after corrective varisation and derotation operation of proximal femur and simultaneous operations on soft tissues of the hip and distally ($p > 0.5$).

Applied clinical and radiological criteria for the evaluation of post-operative results have shown the improvement of CCD and AV(AT) angle for 70% and more, independent walking, correction of the contracture, decreased spasticism in 75.25% of patients; satisfactory condition, that is improved CCD and AV(AT) angle less than 50%, walking with help, partial correction of deformations, reduces spasticism and pain, instability in 21.76%; mild improvement in 0.5%; relapse in 2.7% of patients. Clinical and radiological evaluation of perioperational results in walk were analysed (Table 4, Figure 3). The best achieved post-operative results point to the concentration in the group »good« (Figure 4).

Discussion

During clinical and radiological controls were determined that after corrective osteotomies of proximal femur (varisation and derotation), and the improved connection between joint bodies – acetabulum and femur head, and after the pelvic osteotomies (Salter, Penberton, Dega, Chiari or triple pelvic osteotomy), colodiaphysal angle and anteversion angle in time deteriorate, as well as the congruency of joint bodies^{10,11,19}. That occurs with patients who have not been able to start walking – alone or with help. It usually starts 2–3 years after the operation or earlier, which depends on the degree of spasticism. Deterioration – revalgisation and anteversion, as well as the incongruity of joint bodies, is proportional to time (years) of monitoring – control. The improvement of colodiaphysal angle and anteversion angle after the operation on soft tissues of lower limbs occurs, though gradually. The condition for that occurrence is young age (1–3) when the operation is performed, with patients who have not had success with continual physical treatment, loss of function is present and there is a tendency of creating secondary contractures-deformities or they have already occurred. If there is medical indication, i.e. the presence of contractures on all three levels of lower limbs (spastic diparesis, spastic tetraparesis) simultaneous symmetric operations of soft tissue, hip, knee and foot need to be performed^{6,8} or, if necessary, more operations at the same time on the skeleton, during one anesthesia, one immobilization and one initial post-operative physical therapy.

TABLE 4
CLINICAL AND RADIOLOGICAL EVALUATION OF PERIOPERATIONAL RESULTS IN WALK ANALYSIS

Postoperative	Good	Satisfactory	Improvement	Relapse
Number of patients, %	650/856 (75.25%)	178/856 (21.76%)	8/856 (1.05%)	20/856 (2.7%)
CCD and AV(AT)	>70%	<50%		
Clinical results	Contracture correction, reduces spasticism	Partial correction of deformation, reduces spasticism and pain, instability		
Walk	Independent walk	Walk with a help		
Preoperatively Walk / Number / %	409/856 (47.78%)	352/856 (41.12%)		Did not walk 95/856 (11.09%)

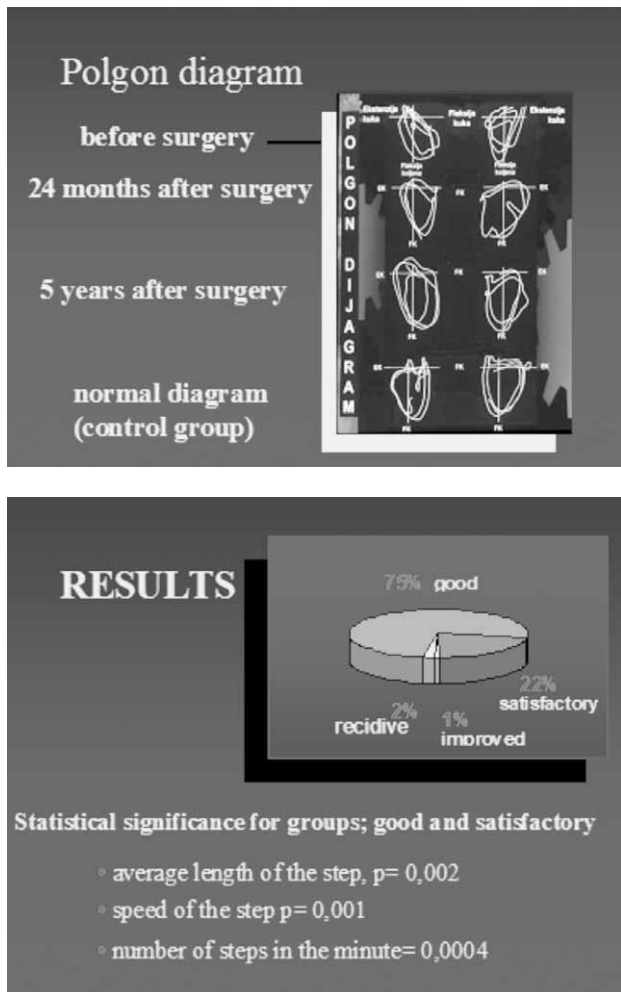


Fig. 3. Polgon diagram before and after 24 months and 5 years. Statistic significance for groups »good« and »satisfactory« confirmed with Polgon goniometry: average step length, $p=0.002$, speed, $p=0.001$, number of steps in one minute (cadence), $p=0.0004$.

That makes post-operative physical treatment easier, there are no compensational changes in the area of big joints of lower limbs. Reduction of all contractures of lower limbs, and if necessary upper limbs, with one or two surgical teams, prevents synergic reactions and complications. Reduction of contractures and new given functions prevent summation of damaging peripheral afferent impulses, and it is easier for a brain lesion to inhibit, control, regulate and coordinate them with the periphery, maintaining through complex neurological ways correction of the contracture, that is the new function. Both local (hip) and general spasticism is reduced, and a balance between agonist and antagonist muscles, and active and conscious movement – movement by order, is achieved. That causes on the one hand further normal development of proximal femur after good results at the early age of 1 (x-ray), or prevents pathological progression of proximal femur, valgus and anteversion, early hip luxation, which occurs with the spastic syndrome as a

paralytic phenomenon. Other authors also state the importance of the reduction of spastic muscles generally, as well as in the hip area^{2,4,6,20,21}. When talking about hip, that is lower limbs, if standing and walking is possible, one should keep in mind functional anatomy, i.e. biomechanics of lower limbs, the impact of gravity, when objective contractures of large leg joints deepen, and position abnormality act as contracture, which is further complicated with compensatory changes in the area of large leg joints^{22,23}. One should also keep in mind and recognize tonic foot reflexes which may persist during the entire childhood and induce contractures – due to the muscle cocontractions proximally with respect to foot-knee, hip.

Having in mind the hip area it is very important to establish, through physical treatment or operations, good active mobility of lower limbs large joints, especially hip extension. During walking, at the moment when the load is on the back of the leg, before step and knee flexion, i.e. in relative hip hyperextension, the proximal femur is in the front and is in firm contact with front iliofemoral ligament (Biegel) which acts as a derotational stress on proximal femur, head and neck²⁴ (Figure 5). Significant static and dynamic improvement, i.e. good independent walk after the operation will not lead to significant normalization of proximal femur, i.e. hip, if there is coincidence of local or general laxitas²⁴. In any case, together with the mentioned sagittal plane, the reduction of pathological conditions in frontal and horizontal plane is important.

It is known that proximal femur valgus is often with spastic syndrome of cerebral palsy. However, anteversion (antetorsion) is its characteristic. That explains the need for all segments of lower limbs to have the best possible function in particular phase of walk cycle, in order to maintain physiological order of proximal femur

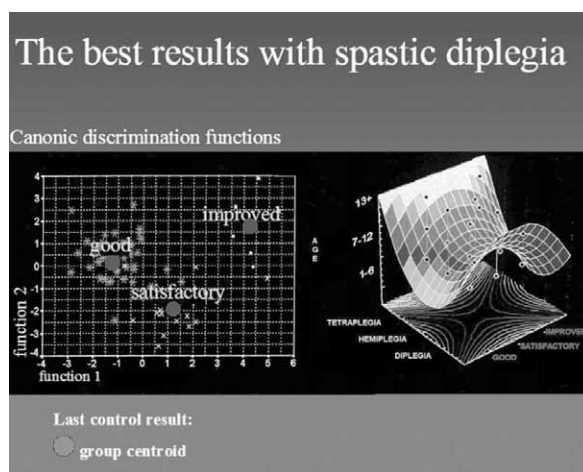


Fig. 4. Best results point to the concentration in »good« category. Pearson's chi-square test shows that there are significant differences in walk results of the last control among patients with diparesis, hemiparesis and tetraparesis (chi-square=13.21533; independence level = 4; $p=0.01027$).

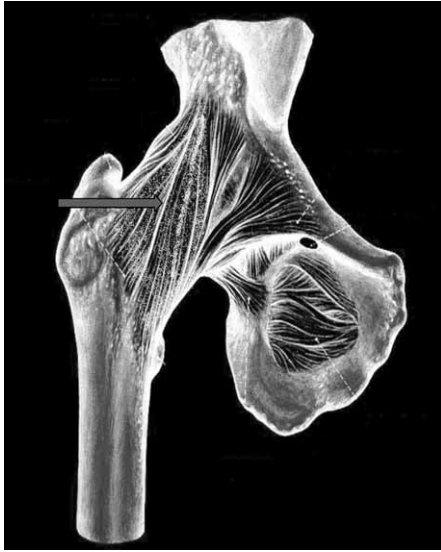

Fig. 5. Anterior iliofemoral (Bigelow's) ligament as derotational stress to proximal femur; head and neck sagittal plane, hip, knee, foot.

normalization. It noticed that even those patients who have not started walking with good active movements, hip flexion-extension, maintain satisfactory condition of hip joint, that is, proximal femur, throughout entire childhood, adolescence and later on. Only passive movements during physical therapy or after operation show false increase of movements, when in fact it is a case of extending, often thickening of spastic muscle tendons, when spastic muscle mass remains the same or is decreased, and patohistologically important changes point to muscle fibrosation, lower myofibril and other²⁴.

In order to achieve good results, generally and for hip area i.e. proximal femur, it is necessary to continually wear night orthosis-splint immediately after plaster immobilization has been removed. The period in which night orthoses is to be used is individual, ranging between several months, years, or entire childhood, depending on the achievement of active and strong movements of lower limbs. The opposite results in contracture relapse. It is well known that spastic muscle grows more slowly lengthwise than long tubular bone, and biarticular muscles and gravity make the situation on lower limbs more complex²⁵⁻²⁷. Although intelligent quotient is important for the final result, we have had good results with patients with mental retardation (IQ 70). The possibility to cooperate with the patient with spastic cerebral paresis is important, as well as his/her wish to walk and use hands. Children with IQ above average who are aware of their handicap are sometimes aggressive and do

not want to cooperate in post-operative treatment. That is the reason why relapse occurs, and their handicap and aggressiveness deepen. Pre-operative evaluation and preparation of the patient as well as the cooperation with the parent is important.

In this study we have used Polgon goniometry walk analysis in sagittal plane, having also in mind frontal and horizontal plane^{12,17,18,20}.

Polgon goniometry used in this investigation as a method of walk analysis was used for the first time with patients with brain lesion which resulted in spastic cerebral paresis – infantile cerebral paresis^{17,18}. Polgon diagram is more or less a heart-shaped diagram, which depends on the improvement of walk cycle. Every point can be analyzed on the diagram – from heel touching the ground, through knee and hip, to toes (thumb) in step position.

The best results were achieved with simultaneous two-sided operations /spastic diparesis/, with patients' age between 1 and 3, achieving independent walk. More operations at the same time significantly reduce spastic summation – one anesthesia, one immobilization and one irritation of the patient, which in turn enables better postoperative physical therapy and results. The primary report of proximal femur-hip deteriorates, i.e. relapse occurs, after the operation in hip area with patients who have not been able to achieve satisfactory active movement, specifically of the hip, independent walk or walk with a help. That is, if the possibility of coincidence of local or general laxitas is excluded.

Proximal femur normalization is achieved or maintained through good function of lower limbs during walk, especially in sagittal plane (anterior iliofemoral Bigelow ligament).

Simultaneous symmetrical operations of lower limbs are important for the correction or maintaining proximal femur normalization, as well as for the reduction of spastic summation.

Night orthoses are essential for maintaining good results achieved by operation of lower limbs, until active willful movement – movement by command – is achieved.

Pelvic stability after the operation on soft tissues of the hip and distally is achieved after 12–36 months, and after the corrective proximal femur and possibly pelvic osteotomy in 6–12 months after walk has been achieved.

Acknowledgements

The authors wish to thank the orthopedic and anesthesiological staff of the University Hospital Centre Zagreb in Zagreb for their assistance

REFERENCES

1. McNERNEY NP, MUBARAK SJ, WENGER DR, J Pediatr Orthop, 20 (2000) 93. — 2. CORNELL MS, HATRICK NC, BOYD R, BAIRD G, SPENCER JD, Clin Orthop Relat Res, 340 (1997) 165. — 3. SPRUIT M, FABRY G, Acta Orthop Belg, 63 (1997) 91. — 4. FLYNN JM, MILLER FJ, Am Acad Orthop Surg, 10 (2002) 198. — 5. PRESEDO A, OH CW, DABNEY KW, MILLER F, J Bone Joint Surg (Am), 87 (2005) 832. — 6. COTTALORDA J, GAUTHERON V, METTON G, CHARMET E, MAATOU-GUI K, CHAVRIER Y, Int Orthop, 22 (1998) 374. — 7. NOONAN KJ, WALKER TL, KAYES KJ, FEINBERG J, J Pediatr Orthop, 20 (2000) 771. — 8. SCHORLE CM, MANALIKAKIS G, Orthopade, 33 (2004) 1129. — 9. KAROL LA, J Am Acad Orthop Surg, 12 (2004) 196. — 10. OSEBOLD WR, LESTER EL, WATSON P, Iowa Orthop J, 22 (2002) 66. — 11. GORDON J, CAPELLI AM, STRECKER WB, DELGADO ED, SCHOENECCKER PL, J Bone Joint Surg (Am), 78 (1996) 1863. — 12. GRIEVE DW, Physioth, 2 (1969) 460. — 13. GRIEVE DW, Physiol, 1 (1969) 70. — 14. SCHNEIDER H, Zschr Orthop, 87 (1956) 250. — 15. RUSZKOWSKI I, (Eds) Ortopedija [In Croat] (Medicinska naklada, Zagreb, 1990). — 16. GAGE JR, Instruc Cour Lectur, 44 (1995) 507. — 17. MATASOVIC-GRABERSKI M, ŠAKIĆ Š, MARKOVAC Ž, MATOVINOVIĆ D, MATASOVIĆ T, Paediatr Croat, 40 (1996) 135. — 18. MATASOVIĆ T, ŠAKIĆ Š, BOBINAC-GEORGIEVSKI A, J Pediatr Orthop, 11 (1991) 436. — 19. JOZWIAK M, MARCINIAK W, PIONTEK T, PIETRZAK SJ, Pediatr Orthop, 9 (2000) 257. — 20. FABRY G, Clin Orthop Relat Res, 381 (2000) 295. — 21. STOTT NS, PIEDRAHITA L, Dev Med Child Neurol, 46 (2004) 628. — 22. JOHNSON DC, DAMIANO DL, J Pediatr Orthop, 17 (1997) 392. — 23. O'BYRNE JM, JENKINSON A, O'BRIEN TM, J Child Neurol, 13 (1998) 101. — 24. TARDIEU G, SCHNEIDER D, TABARY JC, LAITER N, TARDIEU C, Rev Neurol, 128 (1973) 70. — 25. ZIV I, BLACKBURN N, RANG M, KORESKA J, Develop Med Child Neurol, 26 (1984) 94. — 26. TARDIEU C, TABARY JC, TABARY C, TARDIEU G, J Physiol, 64 (1972) 131. — 27. MALNAR DRAGOJEVIĆ D, GRKOVIĆ I, BOBINAC D, DUJMOVIĆ M, NEMEC B, Coll. Antropol, 20 (1996) 111.

Š. Šakić

*Department of Orthopedic Surgery, University Hospital Center »Zagreb«, School of Medicine, University of Zagreb, Šalata 6, 10000 Zagreb, Croatia
e-mail: ksakic@mef.hr*

ANALIZA CIKLUSA HODA U BOLESNIKA SA SPASTIČNOM CEREBRALNOM PARALIZOM POSLIJE KIRURŠKOG POSTUPKA NA DONJIM EKSTREMITETIMA

SAŽETAK

Hod je česti problem u cerebralnoj paralizi. Svrha istraživanja je evaluacija normalizacije proksimalnog dijela bedrene kosti i/ ili normalizacije zdjelice poslije kirurške korekcije, te simultanih operacija na mekim tkivima kao i analiza hoda. Od 1980. do 2000. godine bilo je operirano 856 pacijenata, 476 muški i 380 ženski, u dobi od 1–51 godinu. Bili su analizirani bazični parametri hoda: dužina koraka, brzina hoda i broj koraka u minuti (cadence). 75,25% pacijenata imalo je dobar rezultat sa poboljšanjem kolodijafizarnog kuta (CCD) i kuta anteverzije (AV) odnosno antetorzijske (AT) za 70%, i poboljšanje samostalnog hoda sa ispravljenim kontrakturama, i smanjenim spasticitetom. Najbolji rezultati postignuti su sa simultanim obostranim operacijama, u pacijenata u životnoj dobi od 1 i 3 godine, koji su samostalno prohodali poslije operacije. Više istovremenih operacija u jednoj anesteziji, jednoj imobilizaciji znakovito snižava spazam i bol, olakšava poslijeoperacijsku fizikalnu terapiju i daje cjelokupno bolje rezultate i zadovoljstvo bolesnika.