

Mandibular Caffey's disease: case report

**Kovačić, Ksenija; Hajnžić, Tomislav F.; Rončević, Sanja; Hat, Josip;
Markičević-Ružičić, Karmen; Kusić, Zvonko**

Source / Izvornik: **Collegium Antropologicum, 2007, 31, 359 - 361**

Journal article, Published version

Rad u časopisu, Objavljena verzija rada (izdavačev PDF)

Permanent link / Trajna poveznica: <https://um.nsk.hr/um:nbn:hr:105:307692>

Rights / Prava: [In copyright](#)/[Zaštićeno autorskim pravom.](#)

Download date / Datum preuzimanja: **2024-07-20**



Repository / Repozitorij:

[Dr Med - University of Zagreb School of Medicine
Digital Repository](#)



Mandibular Caffey's Disease – Case Report

Ksenija Kovačić¹, Tomislav F. Hajnžić², Sanja Rončević¹, Josip Hat³,
Karmen Markičević-Ružičić² and Zvonko Kusić¹

¹ Department of Oncology and Nuclear Medicine, University Hospital »Sestre Milosrdnice«, Zagreb, Croatia

² Department of Pediatrics, University Hospital »Sestre Milosrdnice«, Zagreb, Croatia

³ Department of Diagnostic and Interventional Radiology, University Hospital »Sestre Milosrdnice«, Zagreb, Croatia

ABSTRACT

The case of a six-month old boy with mandibular Caffey's disease is described. Emphasis is placed on the role of bone scintigraphy, as a diagnostic method which would be, because of the clinical picture and the beginning of the disease (suspected osteomyelitis), one of the first methods performed. Highly characteristic scintigraphic image, when the mandible is involved, can play the most important role in further treatment, and its recognition can also spare many unnecessary procedures.

Key words: bone scan, Caffey's disease, infantile cortical hyperostosis, Zagreb, Croatia

Introduction

In spite of smaller degree of specificity, due to its sensitivity, simplicity of performance and availability, the bone scintigraphy has been one of the most performed nuclear medicine procedures for more than 30 years. Though it can not provide the diagnosis, it can very clearly show the lesion, before most other methods, their number, shape, intensity of accumulation, which could limit the differential diagnosis, and direct to other diagnostic procedures. Even more, according to the scan, one can put the mark on the skin, which enables directed needle biopsy. Bone scintigraphy in most cases leads on the shortest way to a correct diagnosis, meaning treatment as early as possible and follow up of its effect.

Case Report

V. I., a male infant was born after an ordinary pregnancy in September 2003. The disease began three months later, with the swelling of the right cheek, and conglomerate of the lymphonodes submandibulary on the same side, without fever or any other symptoms. The child was in a good general condition. One week later, the left cheek was also swollen. Tumefactions were found in the lower parts, hard and indurate, fixed to the underlying bones, forming a pear shaped face. On suspicion of sialoadenitis an ultrasound was conducted, but it revealed no

pathologic findings on the right parotis, and on the left a few lymph nodes were found. A needle biopsy under the ultrasound control was performed on both sides of the swollen cheeks. Some fat cells, fibrocytes and phagocytes were found on the left side, some particles of muscular tissue histiocytes, particles of connective stroma, osteoblasts and single mesenchymal cells on the right, but no malignant cells were found.

The erythrocyte sedimentation rate was elevated: 94; (for the first hour), as well as CRP values; 27 mg/L. Leucocytosis was found only at the beginning of the illness: $18.3 \times 10^9 / 1L$, with lymphocytosis –: 73%; 72%. in the differential blood picture. Due to the inflammatory parameters osteomyelitis was suspected, and antibiotic therapy was introduced. Swelling and tenderness temporary disappeared, but than reappeared.

Because of the suspected osteomyelitis, bone scintigraphy – »blood pool« and late static images – was performed after injection of 148 MBq (4 mCi) ^{99m}Tc-HMDP. »Blood pool« images of the head, neck and thorax were performed in the first 10 minutes. The increased accumulation of the radiopharmaceutical was seen in the region of the lower jaw. On the late images of the entire skeleton the pathologic finding is seen only in mandible, and reminds of the Paget disease. (Figures 1a and 1b).

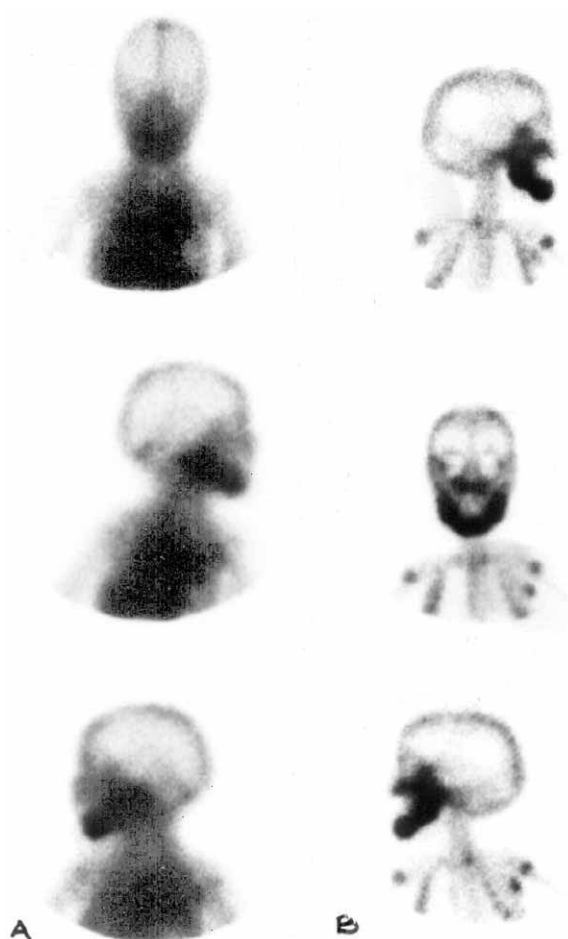


Fig. 1. a) Blood pool image – mild positive finding in the region of lower jaw b) Late static image revealed very intense accumulation of the radiopharmaceutical in the mandible which is voluminous and almost threefold thicker than the normal bone.

In differential diagnosis, this could have been the case of fibrous dysplasia, osteomyelitis or some other disease characterized by intense osteoblastic activity.

On the x-ray of the mandible, diffuse massive cortical thickening of mandible with hyperostosis and bone enlargement was seen. Other parts of skull showed normal radiological bone structure. (Figure 2).

A high resolution CT was made. The finding revealed thickening of the whole mandible with abundant hyperostotic changes of cortical and subcortical parts of the bone with loss of normal trabeculation, edema of the surrounding soft tissue and also indurations of the muscles.

Finally, a bone biopsy under general anesthesia was conducted. Pathohistological diagnosis confirmed Caffey's disease: particles of bone were found, built of normal bone trabecules, coated with osteoblasts and between the trabecules was good vascularized loosed cellular tissue.

Antibiotic therapy was withdrawn, the sedimentation rate, CRP and lymphocyte decline were on the half of their initial values. The local finding almost disappeared, and the child was discharged. Three months later, local

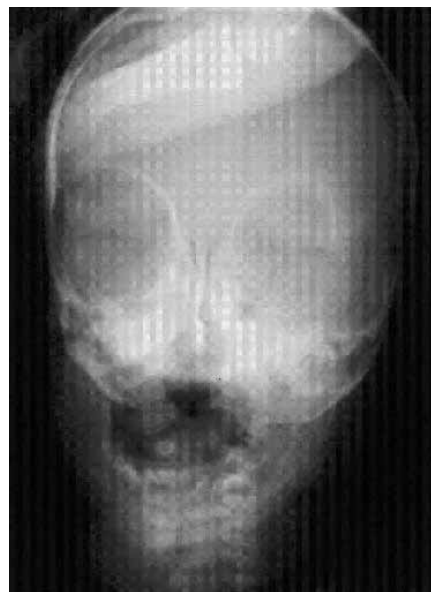

Fig. 2. Atypical A-P x-ray of the skull: Diffuse massive cortical thickening of mandible with hyperostosis and bone enlargement. Other parts of the skull show normal radiological bone structure.

finding disappeared and the child was in good general condition. Laboratory parameters were in normal limits too.

Discussion

The disease was first described by Georg Roske in 1930. John Caffey, American pediatrician, recognized this condition in 1939 and with William Aaron Silverman described it as a clinical entity in 1945. Independently, the disease was reported by Smyth et al. in 1946^{1,2}. The disease is of unknown cause affecting the skeleton and adjacent tissue. It is believed that the disorder is determined at least in part by genetic influences¹.

The autosomal recessive inheritance has been suggested for the prenatal form, but dominant inheritance is also possible³. Another possible cause is an infection by an agent with a long latency period, as has been suggested in Paget's disease⁴.

The disease manifests itself early in infancy (although it may be identifiable in utero), typically before the fifth month, more often in males than females. The disease is characterized by fever, irritability, swelling of soft tissue and cortical bone thickening. The most common sites are mandible (80%), followed by clavicles (50%), and then ulna, tibia, scapula and various ribs on one or both sides. Almost all of the bones could be involved except of phalanges and vertebrae. The bone ends of the long bones are also spared^{5,6}. Affected bones are thickened because of deposition of excessive amounts of subperiosteal new bone on their cortices. It could be mono or polyostotic disease, and the involvement tends to be migratory. In the mildest cases the condition may be limited to the jaw, and subsides after a few weeks. The polyostotic form

lasts several weeks or months, and is considered as a moderately severe case. Severe cases could last for years and swelling can recede and reappear again.

In histopathologic findings in the early stage, acute inflammatory changes can be found, followed by periosteal activity and edematous swelling of the adjacent soft tissue and infiltration by polymorphonuclear leukocytes. In the later stages of the disease, inflammatory changes no longer exist¹.

The prenatal form of the disease according to onset can be divided into two forms – severe with onset before 35 weeks of gestation with high lethality, and the mild form after 35th week without complications³. In the antenatal form, ultrasound plays a very important role, but one must have in mind that findings can lead to the incorrect diagnosis of osteogenesis imperfecta³.

Cortical hyperostosis was also described as a side effect of prostaglandin therapy – which is probably dose dependent⁷.

Our patient had all symptoms except irritability, and the clinical course was characteristic of the mildest case of Caffey's disease. There are many more descriptions in the literature of x-ray, CT or MR findings, although bone scintigraphy in most cases would be the first procedure performed, mainly because of suspicion on osteomyelitis, especially if the x-ray is negative, which could be the case

at the very early beginning of the disease. Bone scintigraphy (the whole body) should be performed even with positive x-ray finding, to distinguish mono from polyostotic disease. Some of the involved bones could be without symptoms (eg. without soft tissue swelling), and bone scan is the only method which can reveal all involved places.

The mandible is involved in almost all cases, and often is the only bone affected. The scintigraphic image is a rather characteristic, very intensive accumulation of the radiopharmaceutical in the bone, more pronounced on the late static image, so regardless of rare incidence (48/100 000) one must have it in mind⁸.

Conclusion

Because of the clinical course of Caffey's disease, bone scintigraphy would be one of the first methods performed. The characteristic image of the bone scan, especially of the mandible which is involved in more than 80% of cases, could help in diagnosis. In conjunction with radiological methods could spare the child from more aggressive procedures, even biopsy. Positive or negative finding of x-ray or other radiological methods must not be the reason for avoiding the bone scan. Scintigraphic follow up is estimated from case to case.

REFERENCES

1. JAFFE HL, Metabolic, Degenerative and Inflammatory Diseases of Bones and Joints. (Urban&Schwarzenberg, Munchen-Berlin-Wien, 1972). — 2. KERR R, Caffey's disease. In: The Encyclopaedia of Medical Imaging. (Vol III1, 2003). — 3. SCHWEIGER S, CHAOUI R, TENNSTEDT C, American Journal of Medical Genetics, 120 (2003) 547. — 4. BERNSTEIN R, ZALESKE J, Am J Orthop, 24 (1995) 777. — 5. ROSENTHAL L, LISBONA R, Infantile Cortical Hyperostosis (Caffey's Dis-

ease). In: Skeletal Imaging. (Appleton-Century-Crofts, Norwalk, 1984). — 6. GELFAND MJ, HARCCKE HT, Caffey's Disease (Infantile Cortical Hyperostosis). In: SILBERSTEIN EB (Ed): Bone Scintigraphy (Futura Publishing Company, New York, 1984). — 7. KALLOGHLIAN A K, FRA-YHA HH, DE MOOR MMA, Eur J Pediatr, 155 (1996) 173. — 8. HASEGAWA S, ICHIYAMA T, MATSUBARA T, Eur J Pediatr, 163 (2004) 175.

K. Kovačić,

Department of Oncology and Nuclear Medicine, University Hospital »Sestre Milosrdnice«, Vinogradska 29,
10000 Zagreb, Croatia
e-mail: zvonko.kusic@zg.htnet.hr

CAFFYEVA BOLEST DONJE ČELJUSTI – PRIKAZ SLUČAJA

SAŽETAK

Prikazan je slučaj šestomjesečnog dječaka sa Caffeyevom bolesti donje čeljusti. Naglasak je stavljen na scintigrafiju kosti kao metodu koja među prvima dolazi u obzir u dijagnostičkom postupku, obzirom da klinička slika i početak bolesti često imitiraju osteomielitis. Zahvaćena donja čeljust ima karakterističan scintigrafski nalaz. Njegovo prepoznavanje ima odlučujuću ulogu u daljnjem postupku, obzirom da bolesnika može poštedjeti nekih, čak i agresivnih metoda.