

Comparison of ultrasonographic and intraoperative findings in Achilles tendon rupture

Margetić, Petra; Miklić, Dina; Rakić-Eršek, Vera; Doko, Zoran; Lubina, Zvonimir Ivan; Brkljačić, Boris

Source / Izvornik: *Collegium Antropologicum*, 2007, 31, 279 - 284

Journal article, Published version

Rad u časopisu, Objavljena verzija rada (izdavačev PDF)

Permanent link / Trajna poveznica: <https://um.nsk.hr/um:nbn:hr:105:898496>

Rights / Prava: [In copyright](#)/[Zaštićeno autorskim pravom](#).

Download date / Datum preuzimanja: **2024-12-24**



Repository / Repozitorij:

[Dr Med - University of Zagreb School of Medicine Digital Repository](#)



Comparison of Ultrasonographic and Intraoperative Findings in Achilles Tendon Rupture

Petra Margetić¹, Dina Miklič¹, Vera Rakić-Eršek¹, Zoran Doko¹, Zvonimir Ivan Lubina¹ and Boris Brkljačić²

¹ Department of Radiology, University Hospital of Traumatology Zagreb, Zagreb, Croatia

² Department of Radiology, University Hospital Dubrava, Zagreb, Croatia

ABSTRACT

The purpose of the study was to assess the value of ultrasonography in the diagnosis of Achilles tendon rupture, by comparing initial ultrasonographic scans and direct intraoperative findings, as well as to follow up the healing process in operatively and conservatively treated patients. Ultrasound examination was performed in 100 patients (91 males and 9 females, with mean age of 46 years) with clinically suspicious Achilles tendon ruptures. Ultrasonographic findings were compared with intraoperative findings. Eighty-eight patients underwent surgery and twelve patients were treated conservatively. Complete ruptures were diagnosed by ultrasound in 88 patients, and partial ruptures in 12 patients. The length of the tendon (Pearson $r=0.973$, $p<0.001$, Spearman $\rho=0.972$, $p<0.001$) and the size of the rupture (Pearson $r=0.940$, $p<0.001$, Spearman $\rho=0.905$, $p<0.001$) measured before surgery by ultrasound and directly during surgery showed a high correlation. Out of 88 operatively treated patients, 86 had a complete rupture and two had a partial rupture. All patients were examined 3, 5, 8, and 12 weeks after injury or after surgery. In the first five weeks, there were statistically significant differences noted between these two groups. Operatively treated tendons healed more quickly, but after eight and twelve weeks this difference had disappeared. Our study showed that ultrasound is an excellent imaging method for confirming the clinical diagnosis of Achilles tendon rupture as well as for following up the process of tendon healing.

Key words: Achilles tendon, rupture, ultrasound

Introduction

Patients with Achilles tendon injury complain of calf pain and have a characteristic limp, because of the inability to do plantar flexion. A retromalleolar haematoma occurs in most cases. The acute rupture is characterized by a palpable interruption of the tendon, described in literature as »cou d'ache«. Thompson's test of squeezing the calf results in a failure to achieve plantar flexion in case of a rupture. Due to its close proximity to the skin, the Achilles tendon can be easily examined by ultrasound¹. The rupture is the most common Achilles tendon pathology^{2,3}. Acute partial and complete ruptures are seen as a break in the continuity of the tendon, i.e. as an echo-free area within the tendon. It is important to differentiate partial from complete ruptures in order to define whether the treatment should be surgical or conservative⁴.

In addition, ultrasound enables monitoring of the healing process of ruptured tendons, manifesting as alterations in tendon echogenicity and thickness. The purpose of this study was to assess the value of ultrasonography in diagnosis of Achilles tendon ruptures, by comparing preoperative ultrasound scans with direct intraoperative findings and to follow up the healing process in operatively and conservatively treated patients.

Material and Methods

One hundred patients (91 males, 9 females, mean age 46 years, age range 23–80 years) with a clinically suspicious Achilles tendon rupture were examined by ultra-

sound. The patients complained of calf pain, had a characteristic limp because of the inability to perform plantar flexion, and in most patients a retromalleolar haematoma was noted. Thompson's test was positive in all cases. Ultrasound examination was performed with a linear 7.5 MHz probe (KRANZBUCHLER Sonoscope 30). Patients were in the prone position, with the ankle in the neutral position. Both tendons were scanned in longitudinal and transverse projections in a static view, as well as in a dynamic view during flexion and extension of the ankle. On the longitudinal section the whole length of the tendon, its attachment to the calcaneus, as well as the gastrocnemius and soleus muscle, could be discerned. The transversal scan provided a cross-sectional view of the tendon and muscles, as well as their relations and thickness. The rupture was easily seen in the longitudinal scan as an echo-free or hypoechoic interruption of the tendon continuity, indicating the formation of haematoma at the site of the rupture. In all patients dynamic assessment was performed to evaluate the tear of the ruptured tendon parts.

Eighty-eight patients (81 males and 7 females) underwent surgery and 12 patients were treated conservatively. In all patients the foot was immobilized in the plantar flexion to allow better healing. Subsequently, the patients followed the appropriate rehabilitation program. All patients were followed by ultrasound during the rehabilitation period and ultrasound findings were

compared in operatively and conservatively treated patients. Ultrasound examination was performed 3, 5, 8 and 12 weeks after surgery or after injury in conservatively treated patients. For the analysis of differences in cases of acute, complete and partial ruptures the parametric McNamar χ^2 test was used. The Pearson parametric correlation coefficient and Spearman nonparametric correlation coefficient were used to analyze measured parameters – the length of the defect and the length of the tendon measured by ultrasound before surgery and with a ruler during surgery. These results were analyzed using the nonparametric Kolmogorov-Smirnov test.

Results

59.1% of the injuries in the study group were caused by sports activities, primarily football. The left tendon was slightly more often injured (53%) than the right one (47%). The most common location of the lesion was the distal third (49%) of the tendon. 88 lesions were diagnosed by ultrasound as complete (Figure 1) and 12 as partial tears (Figure 2). 88 patients were treated operatively (78 complete and 10 partial ruptures as confirmed by ultrasound). 12 patients were treated conservatively (10 complete and 2 partial ruptures as confirmed by ultrasound).

Eight of ultrasound examined partial lesions proved intraoperatively to be complete and only two were partial (Table 1). The difference between preoperative US scans and intraoperative findings of partial ruptures was tested with the McNamar χ^2 -test and proved to be statistically significant ($\chi^2=6.125$, $df=1$, $p=0.013$).

The length of the tendon and the size of the defect were measured on the preoperative ultrasound scans. The same parameters were measured directly during surgery and the results were compared. The average length of the tendon measured by ultrasound was 12.4 cm, and 12.8 cm by direct intraoperative measuring. The average length of the defect measured by US was 3.2 cm, and 3.3 cm during surgery (Table 2).

Then, we calculated the Pearson parametric correlation coefficient and the Spearman non-parametric corre-

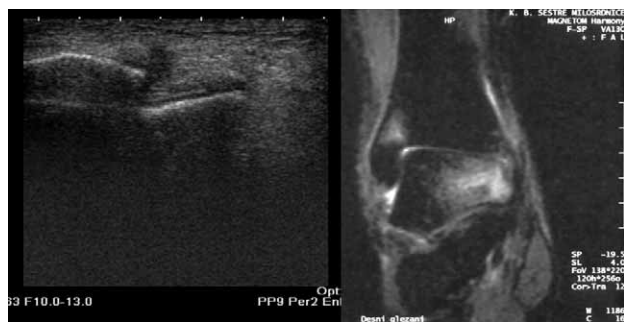

Fig. 1. Acute, complete Achilles tendon rupture, break of continuity is visible with formation of haematoma.

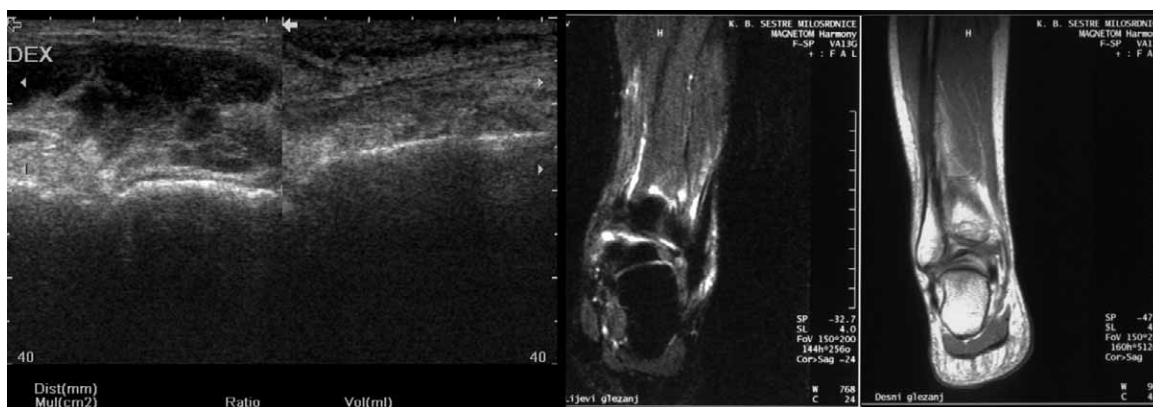


Fig. 2. Acute partial rupture (confirmed intraoperatively).

TABLE 1
COMPARISON OF ULTRASONOGRAPHY AND INTRAOPERATIVE FINDINGS OF COMPLETE AND PARTIAL RUPTURE

		Intraoperative findings		Total
		Complete rupture	Partial rupture	
Ultrasound findings	Complete rupture	78	0	78
	Partial rupture	8	2	10
Total		86	2	88

TABLE 2
COMPARISON OF ULTRASOUND AND INTRAOPERATIVE FINDINGS IN AVERAGE MEASUREMENT OF TENDON AND DEFECT LENGTH

	Ultrasound findings	Intraoperative findings
Average length of tendon (cm)	12.4	12.8
Average length of defect (cm)	3.2	3.3

lation coefficient. The length of the tendon and the size of the defect were highly correlated (Figure 3 and Figure 4). The Pearson parametric correlation coefficient was 0.973, $p < 0.001$ for measuring the tendon length and for measuring the size of defect it was 0.940, $p < 0.001$. The Spearman non-parametric correlation coefficient was 0.972, $p < 0.001$ for measuring the tendon size and 0.905, $p < 0.001$ for measuring the defect size.

During the first follow-up ultrasound examination (three weeks after surgery or after injury in conservatively treated patients) we observed that the conservatively treated tendon was thicker, haematoma was still visible in most of the cases, and the tendon was more hypoechoic than in surgically treated patients and some effusion in the paratenon could still be found (Figure 5). Five weeks after injury/surgery the difference between surgically and conservatively treated patients still persisted. The Achilles tendon was »darker« in conservatively treated patients and haematoma was still visible

(Figure 6). The tendon was thicker in conservatively treated patients (4mm), which proved to be statistically significant.

During the examination performed eight weeks later the difference was not so obvious. In both groups of patients the tendon was thicker than normal, iso- or hyperechoic, due to fibrous organization, and the function of the tendon was almost normal. Haematoma was visible in a minority of cases (in 22% of the surgically treated patients and in 30% of those treated conservatively). Effusion in the paratenon was visible in 12% of operatively treated patients and in 25% of conservatively treated patients. (Figure 7). The last follow-up examination at twelve-weeks after injury showed a homogenic but still hyperechoic and thickened tendon as compared to the uninjured side (approx. 1/3), without the typical lamellar distribution of tendon fibres. There were no signs of ei-

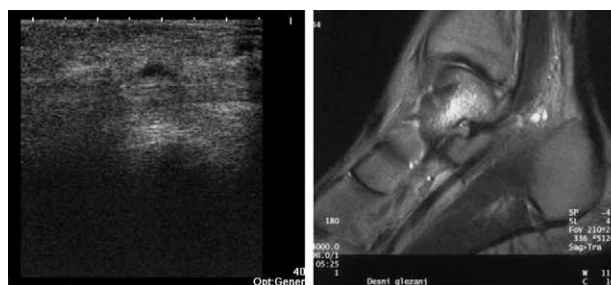


Fig. 4. Length of defect measured by ultrasound and intraoperatively is highly, almost linearly, related (Pearson $r=0.940$, $p < 0.001$, Spearman $p=0.90$, $p < 0.001$).

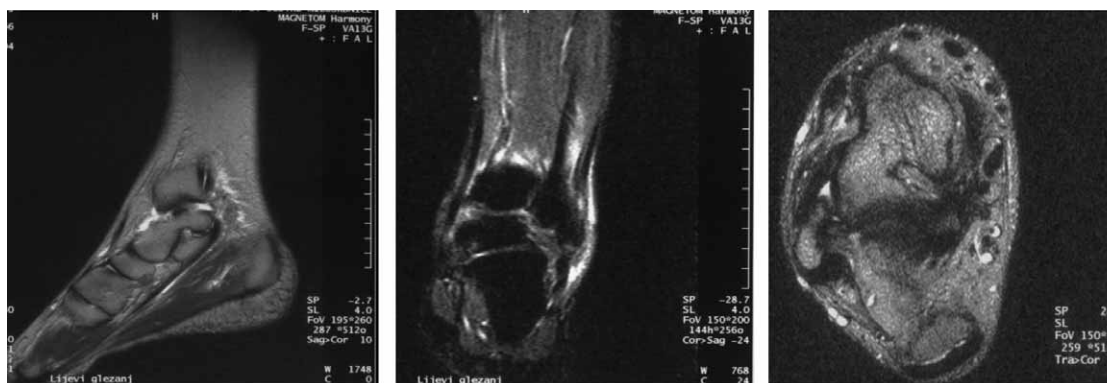

Fig. 3. Length of tendon measured by ultrasound and intraoperatively is highly, almost linearly, related (Pearson $r=0.97$; $p < 0.001$, Spearman $p=0.972$, $p < 0.001$).

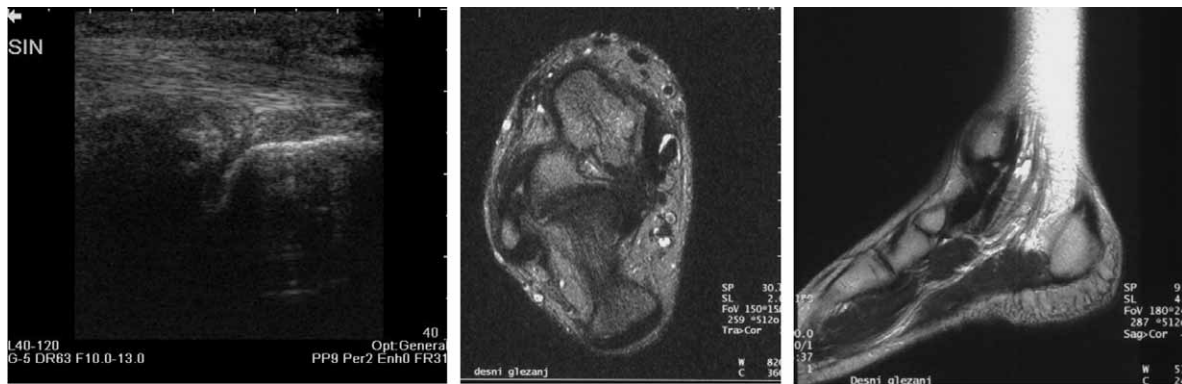


Fig. 5. Complete rupture in the distal third, three weeks after surgery, haematoma is still visible (25x11mm). Transversal scan (left), longitudinal scan (right).

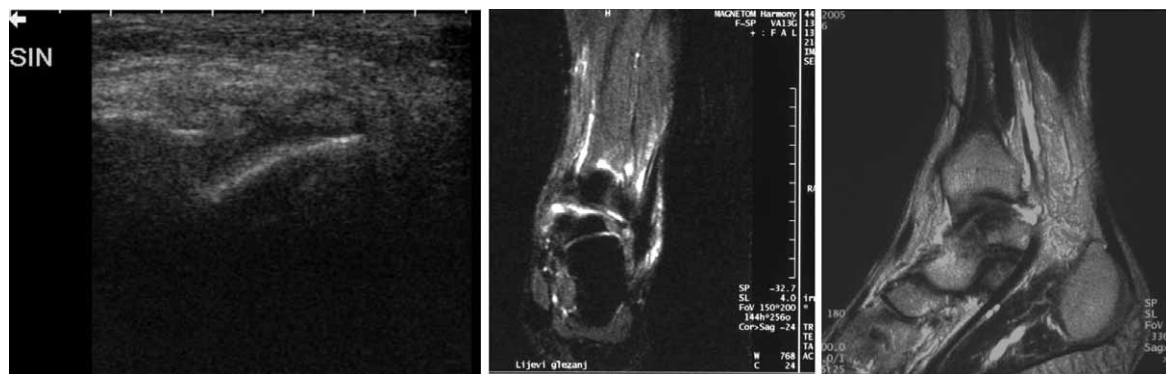

Fig. 6. Complete rupture five weeks after surgery. Echogenity is changed, tendon is thickened.

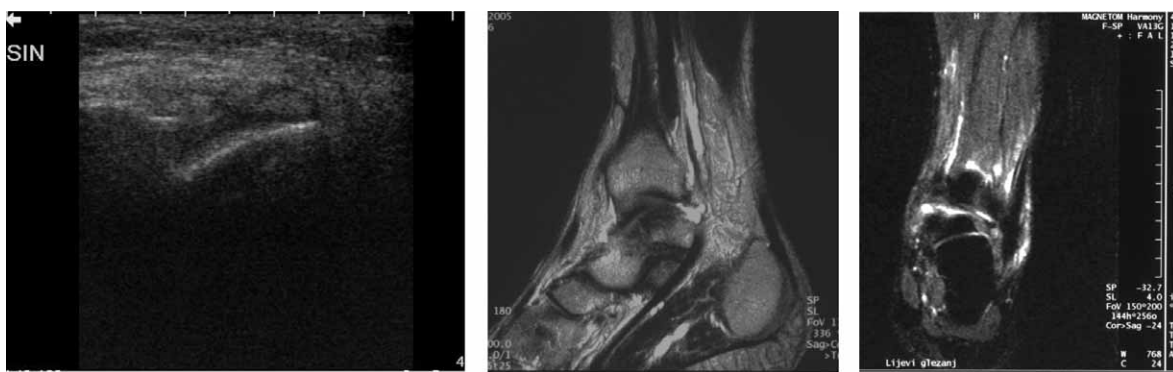


Fig. 7. Partial rupture eight weeks after surgery.

ther haematoma or paratenon effusion (Figure 8). Operatively and conservatively treated patients were compared using the non-parametric Mann-Whitney U test. The thickness of the tendon was measured. Three weeks after the injury or after surgery in the case of the operatively treated tendon, statistically significant differences were found between the two groups (more than 6 mm). Five weeks after the injury/surgery there were still statistically significant differences between these two groups (4 mm). During the next examination (8 weeks after injury/surgery) the difference was not statistically significant and during the last examination there were

no differences between operatively and conservatively treated groups. Ultrasound findings correlated with the clinical picture, too. In patients with a better clinical healing process, ultrasound findings were better than in the patients who developed complications – inflammation, re-rupture or some other clinical condition.

Discussion

The Achilles tendon is easily examined by ultrasound due to its superficial position⁵. The typical internal echo structure results from the reflection of sound waves,

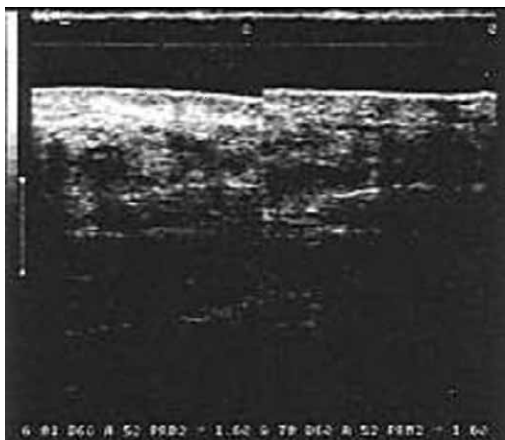


Fig. 8. Conservatively treated partial rupture, twelve weeks after injury.

which depends on an acoustic interface at the boundaries of the endotendineum septa and collagen bundles⁶. These border areas are orientated in a longitudinal direction. The endotendineum consists of loosely connected collagen tissue with mainly elastic fibres. It contains blood vessels and lymphatic and nerve endings⁵. The tendon has no synovial sheath but has a paratenon (dorsal and ventral) that appears hyperechoically from the central part. These structures are important as far as tissue nutrition is concerned. The repairing process after injury to the tendon also starts from here. The high frequency transducers are used to display the echogenicity and echo structure.

To avoid artefacts, it is important that the probe is perpendicular to the tendon surface. Angling of the transducer leads to artefacts, especially to alterations of the echo structure⁷. Many authors have described ultrasound changes in the Achilles tendon rupture⁸. Some authors have analyzed small group of patients, and Lehtinen et al. have concluded that ultrasound is a reliable method for diagnosing partial tears⁹. Comparing preoperative ultrasound scans and intraoperative findings, we have found that ultrasound is a highly specific and sensitive method for diagnosing ruptures. Ultrasound findings of complete ruptures were confirmed by the intraoperative finding in all cases.

Ultrasound proved to be less reliable in the case of a partial tear. Sometimes we could see discontinuity of the tendon fibres with localized edema and a focal sonolucency combined with local tendon thickening but without a visible break in the continuity of the paratenon. These are so-called partial ruptures. In most cases during surgery it was found that all tendon fibres were ruptured but some of them had impacted, which gave them an intact

appearance on ultrasound examination. Ultrasound was performed no more than 12 hours before operation and patient was hospitalized so there were no possibility of rerupture between ultrasound examination and surgery.

After injury, the repair process changes the echo texture. According to the literature, the normal longitudinal orientated structure cannot be detected during the first 6 months after injury³. The histological changes with the growth of the vascularized granulation tissue cause the disappearance of the longitudinal orientation of the collagen fibre bundles. The diameter of the tendon remained increased compared with the controls. An increase in the diameter seems to be an attempt to compensate for the poor mechanical characteristics of a less differentiated scar tissue. Comparison with the uninjured tendons of the contralateral leg enabled us to eliminate the possibility that degenerative changes of the tissue were responsible for the alterations of the sonographic patterns.

It is not possible to draw any conclusion from ultrasound as far as the histological differentiation of the tendon tissue in the injured area is concerned. Sonographic findings concerning the paratenon (ill-defined demarcation, thickening) can be regarded as resulting from scarring of the surrounding tissue. Our study showed that the torn tendon is still thickened three weeks after injury/surgery by almost $\frac{1}{2}$ in comparison with the opposite side. Perifocal edema is still visible, the echo structure is inhomogenic, mostly hypoechoic, and there is a morphological difference in the thickness and echo sonographic structures between surgically and conservatively treated patients which proved to be statistically significant^{10,11}.

Conclusion

Ultrasound proved to be an excellent imaging method in confirming the clinical diagnosis of Achilles tendon ruptures. Ultrasound findings of a complete Achilles tendon rupture were confirmed by the intraoperative findings in all cases. The length of the tendon and the size of the rupture measured sonographically before surgery and directly during the surgery proved to be highly related (almost linearly). However, ultrasound is statistically less reliable in distinguishing between partial and complete tears. Most of the lesions that seemed to be partial ruptures proved to be complete ruptures during surgery. Comparing operatively and conservatively treated patients by ultrasound, it was found that in the first five weeks there were statistically significant differences between these two groups. Operatively treated tendons healed more quickly, but after eight and especially twelve weeks these differences had disappeared.

REFERENCES

1. VANDERSCHUEREN GM, FESSEL DP, VAN HOLSBECK MT, Ankle. In: CHEM RK, CARDINAL E (Eds), Guidelines and Gamuts in Musculoskeletal Ultrasound (Wiley-Liss, New York, 1995). — 2. MAFFULLI N, WONG J, Clin Sports Med, 22 (2003) 290. — 3. ULREICH N, KAIN-

BERGER F, HUBER W, NEHRER S, Radiologe, 42 (2002) 811. — 4. HEYDE CE, KAYSER R, JUNGMICHEL D, MELZER C, Sportverletz. Sportschaden, 17 (2003) 39. — 5. HAŠPL M, PEČINA M, Diagnostic ultrasound of the knee and lower leg. In: MATASOVIĆ T (Eds), Diagnostic

ultrasound of the locomotor system. (Školska knjiga, Zagreb, 1990). — 6. THAIN LM, LEE SL, DOWNEY DB, Can Assoc Radiol J, 52 (2001) 325. — 7. RAWOOL NM, NAZARIAN LN: Ultrasound of the ankle and foot. Seminars in Ultrasound, CT and MR (Philadelphia, 2000). — 8. BUCKLEIN W, VOLLERT K, WOHHLGEMUTH WA, BOHNDORF K, Eur J

Radiol, 10 (2000) 290. — 9. LEHTINEN A, PELTOOKALLIO P, TAAVITSAINEN M, Ann Chir Gynaecol, 83 (1994) 322. — 10. BLEAKNEY RR, TALLON C, WONG JK, LIM KP, MAFFULLI N, Clin J Sport Med, 12 (2002) 273. — 11. MOLLER M, KALEBO P, TIDERBRANT G, MOVIN T, KARLSSON J, Knee Surg Sports Traumatol Arthrosc, 10 (2002) 49.

P. Margetić

*University Hospital of Traumatology Zagreb, Draškovićeva 19, 10000 Zagreb, Croatia
e-mail: margetic_petra@yahoo.com*

ULTRAZVUČNA DIJAGNOSTIKA RUPTURE AHILOVE TETIVE U USPOREDBI SA INTRAOPERACIJSKIM NALAZOM

S A Ž E T A K

Cilj rada bila je procjena vrijednosti ultrazvuka u dijagnostici rupture Ahilove tetive, komparirajući ultrazvučni i intraoperacijski nalaz, kao i praćenje procesa cijeljenja kirurški i konzervativno liječenih pacijenata. Ultrazvučno je pregledano 100 ozljeđenika (91-M, 9-Ž, prosječne dobi 46) pod kliničkom sumnjom na rupturu Ahilove tetive. Ultrazvučni nalaz kompariran je s intraoperativnim. 88 ozljeđenika je operirano, a 12 je liječeno konzervativno. Kompletna ruptura nađena je ultrazvukom u 88 ozljeđenika, a parcijalna u 12. Dužina tetive (Pearson $r=0.973$, $p<0.001$, Spearman $\rho=0.972$, $p<0.001$) i dužina defekta (Pearson $r=0.940$, $p<0.001$, Spearman $\rho=0.905$, $p<0.001$) mjerena ultrazvukom i intraoperativno bile su u visokoj korelaciji. Od 88 operativno liječenih ozljeđenika u njih 86 je intraoperativno nađena kompletna, a u 2 parcijalna ruptura. Svi su ispitanici pregledavani ultrazvukom 3, 5, 8 i 12 tjedana nakon operacije ili ozljede. U prvih pet tjedana nađena je statistički značajna razlika između te dvije grupe. Operativno liječene tetive cijelile su brže, ali nakon dvanaest tjedana ta razlika je nestala. Naš rad je pokazao da je ultrazvuk visoko senzitivna i specifična metoda za potvrdu kliničke dijagnoze i praćenje cijeljenja rupturu Ahilove tetive.