

Epilepsy due to malformations of cortical development: correlation of clinical, MRI and Tc-99mECD SPECT findings

Sporiš, Davor; Hajnšek, Sanja; Boban, Marina; Bašić, Silvio; Petrović, Ratimir; Radoš, Marko; Babić, Tomislav

Source / Izvornik: **Collegium Antropologicum, 2008, 32, 345 - 350**

Journal article, Published version

Rad u časopisu, Objavljena verzija rada (izdavačev PDF)

Permanent link / Trajna poveznica: <https://urn.nsk.hr/urn:nbn:hr:105:094883>

Rights / Prava: [In copyright](#) / [Zaštićeno autorskim pravom.](#)

Download date / Datum preuzimanja: **2024-07-16**



Repository / Repozitorij:

[Dr Med - University of Zagreb School of Medicine
Digital Repository](#)



Epilepsy Due to Malformations of Cortical Development – Correlation of Clinical, MRI and Tc-99mECD SPECT Findings

Davor Sporiš¹, Sanja Hajnšek¹, Marina Boban², Silvio Bašić¹, Ratimir Petrović³, Marko Radoš⁴ and Tomislav Babić⁵

¹ Department of Neurology, University Hospital »Zagreb«, Zagreb, Croatia

² School of Medicine, University of Zagreb, Zagreb, Croatia

³ Department of Nuclear Medicine and Radiation Protection, University Hospital »Zagreb«, Zagreb, Croatia

⁴ Department of Radiology, University Hospital »Zagreb«, Zagreb, Croatia

⁵ i3 Research, CNS Scientific Affairs, Maidenhead, UK

ABSTRACT

Malformations of cortical development (MCD) have been increasingly recognized as an important cause of intractable epilepsy. The aim of our study was to define epileptogenicity of MCDs by correlating MRI, EEG and semiology of epileptic attacks, and to determine the effect of MCD on drug resistant epilepsy. We also intended to reveal the utility of interictal single photo emission computed tomography (SPECT) in verification of MCD lesions and relative prevalence of different MCDs. Based on interictal EEG finding, semiology of the epileptic attacks and brain magnetic resonance imaging (MRI) »electroclinical epileptogenicity« of MCD was defined. Brain MRI revealed cortical dysplasia (CD) in nine patients, polymicrogyria in four patients, lissencephaly and schizencephaly in one patient each. Three patients had a combination of malformations. The localization of SPECT hypoperfusion corresponded to MCD lesion in ten (66.67%) patients. Electroclinically confirmed epileptogenicity of MCD overlapped with MR and interictal SPECT findings in fourteen (93.3%) and nine (60.0%) patients, respectively. Our study results demonstrated the MCD lesions to be highly epileptogenic and a frequent cause of intractability.

Key words: cortical malformations, intractable epilepsy, epileptogenicity, EEG, MRI, SPECT

Introduction

Malformations of cortical development (MCD) represent heterogeneous group of disorders and a common cause of epilepsy^{1,2}. The high incidence of dysplastic neurons in patients with drug resistant epilepsy has been increasingly recognized since a detailed report by Taylor et al. in 1971, who identified the disorientated or giant neurons in temporal cortex resected from patients with temporal lobe epilepsy³. High-resolution brain magnetic resonance imaging (MRI) can demonstrate these pathologies in most cases morphologically if T1, T2, and fluid-attenuated inversion recovery (FLAIR) images are investigated carefully^{4,5}.

There is a general consensus that MCDs can be highly epileptogenic^{6,7}. The intrinsic epileptogenicity of MCDs

has been reported by Palmieri et al using intraoperative electrocorticography¹. Ictal or continuous epileptogenic discharges were mostly recorded from electrodes overlying dysplastic gyri. Several studies confirm epileptogenicity of MCDs^{8,9}. Zilles et al reported an increased NMDA receptor binding in the dysplastic cortex¹⁰. Immunocytochemical studies examining the distribution of AMPA receptor proteins had shown predominant increase of GluR2/3 subunits in dysplastic neurons as well as decreased GluR1 and increased GluR4 mRNA expression in dysplastic neurons^{11–13}. Expression of GABA-A receptor beta-1, beta-2, alpha-1 and alpha-2 subunit mRNAs was decreased in dysplastic neurons¹³. Furthermore, the causal relationship between MCD and genesis of seizures

has been validated through the correlation of the extent of surgical resection with favorable seizure outcome in patients with chronic epilepsy¹⁴. It is well known that high seizure frequency, prolonged duration of seizures and episodes of epileptic status, which are commonly present in MCD patients, can lead to early cognitive decline. Moreover, a long period of poor seizure control produces disturbed psychosocial functioning and thus unsatisfactory quality of life¹⁵. Therefore, early treatment of intractable epileptic attacks in patients with MCD is crucial. Combination of many noninvasive as well as invasive diagnostic procedures may contribute to definition of MCDs as well as EZ¹⁶. Nuclear medicine imaging techniques may help in noninvasive definition of epileptogenic lesion and, therefore, in selecting appropriate patients for surgery¹⁷. Single photo emission computed tomography (SPECT) and positron emission tomography (PET) are nowadays routinely used in preoperative evaluation of selected patients with epilepsy¹⁸.

The aim of our study was to define the epileptogenicity of MCD by correlating MRI, EEG and semiology of epileptic attacks in epilepsy patients. We also assessed the occurrence of medical intractability in patients with epilepsy due to MCD. Furthermore, we intended to reveal utility of interictal single photo emission computed tomography (SPECT) in verification of MCD lesions seen on MRI and relative prevalence of different MCDs.

Patients and Methods

In this prospective study patients were selected among 1872 epilepsy patients examined during the year 2007 in Croatian Referral Centre for Epilepsy, Zagreb University Hospital Centre in Zagreb. The main inclusion criterion was the finding of MCD lesion on brain MRI. MRI findings were reviewed and classified according to the recent classification of MCD lesions¹⁹. All patients were on antiepileptic treatment for at least one year. Finally, thirteen female and two male patients were included in the study. The mean age of onset of epileptic attacks was 13.0 ± 9.1 years, whereas mean duration of epilepsy before admittance to our Center was 13.4 ± 6.7 years. The mean age at admission to our University Department was 26.4 ± 8.8 years. Three patients had onset of epileptic attacks after 21 years of age. Three patients had primary generalized epileptic seizures. Of the remaining twelve patients, eleven patients had partial epileptic seizure with secondary generalisation (complex partial seizures in nine and simple partial epileptic seizures in three patients) with secondary generalization (Table 1).

Based on interictal EEG finding, semiology of the epileptic attacks and brain MRI »electroclinical epileptogenicity« of MCD was defined. The »electroclinical epileptic zone« (EZ) could not be precisely defined without seizure registration by long term videoEEG monitoring (ictal EEG) or special subdural grid electrodes^{7,20}. The

TABLE 1
SUMMARY OF THE CLINICAL DATA, MRI, SPECT AND EEG FINDINGS

Pt.	Sex	Epilepsy onset / age (yr)	MRI (type / hemisphere / lobe)	Resistance	Semiology of attacks	SPECT (perfusion / hemisphere / lobe)	EEG
1.	M	10 / 34	Schizencephaly / L / F	R	SPS	HYPO- / L / F	L / FP
2.	F	15 / 22	CD / R / P	S	GM	HYPO- / R / TP	R / FTP
3.	F	16 / 20	CD / L / T	S	CPS→	HYPO- / R / T	L / T
4.	F	10 / 18	CD / R / T	S	CPS→	HYPO- / R / T	R / T
5.	F	5 / 17	Polymicrogyria / R / TO + heterotopia / R / TPO	R	CPS→	HYPO- / R / T	R / T
6.	F	24 / 33	Polymicrogyria / R / FT	R	CPS→	HYPO- / R / T	R / T
7.	M	5 / 18	CD / L / F	R	CPS→	HYPO- / L / F	L / T
8.	F	38 / 45	CD / R / T	R	GM	HYPO- / R / T	R / FT
9.	F	21 / 31	Polymicrogyria / L / T	S	CPS→	HYPO- / R / T	L / T
10.	F	8 / 17	CD / L / T	R	CPS→	HYPO- / L / T	L / T
11.	F	2 / 18	Lissencephaly / L / FP + agenesis of corpus callosum	R	SPS→	ISO	L / FP
12.	F	10 / 27	Polymicrogyria / R / FT + heterotopia / R / P	R	GM	HYPO- / R / FT	R / FT
13.	F	13 / 33	CD / L / FP	S	SPS→	HYPO- / L / TP	L / FP
14.	F	8 / 26	CD / L / T	R	CPS→	ISO	L / T
15.	F	10 / 37	CD / L / T	R	CPS→	ISO	L / T

Schi – schizencephaly, CD – cortical dysplasia, Po – polymicrogyria, H – heterotopia, Liss – lissencephaly, ACC – agenesis of corpus callosum, ISO – isoperfusion, HYPO – hypoperfusion, F – frontal, T – temporal, O – occipital, P – parietal, L / R – left/right, EEG – electroencephalogram, SPS – simple partial epileptic attacks; CPS – complex partial epileptic attacks, GM – generalized tonic-clonic seizure. → – partial seizure evolving to secondary GM

clinical details concerning patients' resistance to medical treatment, findings of MRI, interictal SPECT and »electroclinical epileptogenicity« of MCD are summarized in Table 1. Intractable epilepsy was defined as four or more attacks per 4-week period during the last 12 weeks despite two or more first-line antiepileptic drugs in therapy. Patients with well-controlled seizures were free from attacks in the same period. None of patients have undergone surgical treatment. An informed consent was obtained from all patients.

MRI was performed on a T MR scanner with standard techniques. T1-, T2-weighted and FLAIR images were obtained in multiple coronal, sagittal and axial planes. SPECT scans were performed interictally in all study patients and started 20 minutes after administration of 740 MBq of Tc-99m ECD in resting state, eyes closed and with low ambient noise. Axial, coronal and sagittal images generated by IRIX triple headed gamma camera, were analyzed on Odyssey FX820 work station semi-quantitatively using the region-of interest based method and normalized to the mean brain activity. Single slice thickness was about 8 mm. Three-dimensional reconstructions of the SPECT finding were obtained. Changes of regional cerebral blood flow (rCBF) seen on interictal SPECT were determined in comparison with rCBF in morphologically normal regions, as assessed by MRI. Finally, SPECT findings were divided in three major categories: scans with hypoperfusion area, hyperperfusion area and normal scans. All patients underwent several interictal scalp digital EEG recordings with international 10/20 system of electrodes analyzed on Nihon Kohden EEG-1100.

Results

According to neuroimaging findings, MCD lesions were divided into several groups (Tables 1 and 2). Cortical dysplasia (CD) was found in nine and polymicrogyria in four patients, while lissencephaly and schizencephaly were recorded in one patient each. Three patients had a combination of malformations: patient 5 and 12 had focal polymicrogyria accompanied by ipsilateral subcortical

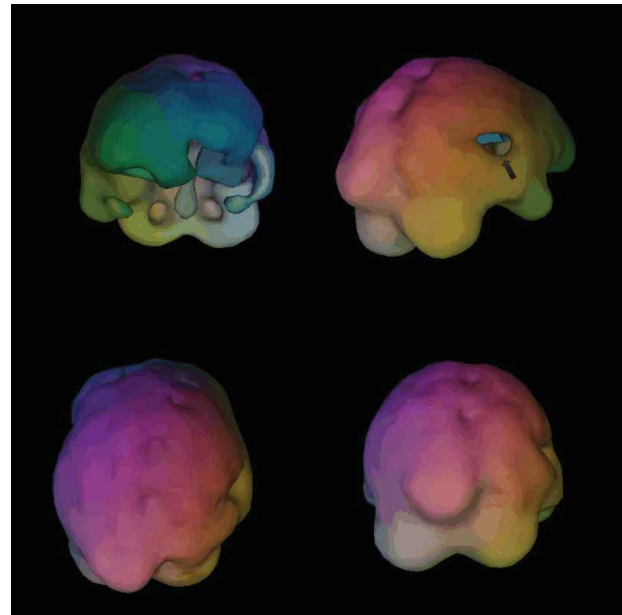


Fig. 1. Axial T2-weighted brain MRI image with nodular heterotopic gray matter in subcortical region and obliterated occipital horn of right lateral ventricle. The right occipito-temporal lobe is hypoplastic and shows changes typical for polymicrogyria. The posterior interhemispheric fissure is discretely displaced to the left (patient no. 5).

nodular heterotopia (Figures 1, 2 and 3), whereas patient 11 had lissencephaly accompanied by partial agenesis of corpus callosum. Megalencephaly/hemimegalencephaly or MCD associated with neoplasia were not found. In study patients, 73.3 % of lesions were unilobar, mostly located in temporal or frontal lobes (Table 2).

According to our definition of intractability presented in Patients and Methods section, ten patients had intractable epileptic attacks. The remaining five patients had well controlled epilepsy with no epileptic attacks over a 12-week period. Intractable epilepsy was found in five CD (55.6%) patients, three (75%) patients with polymicrogyria and one patient with schizencephaly and lissencephaly each (Table 1).

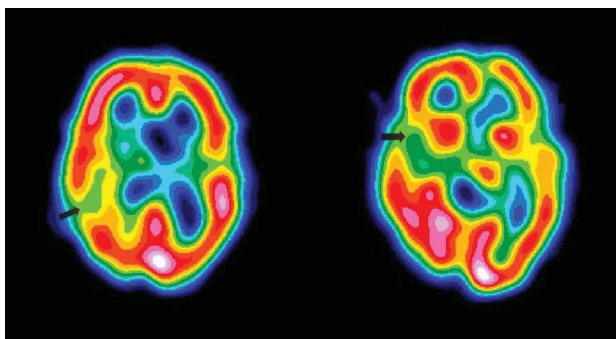


Fig. 2. Axial interictal SPECT section with decreased regional cerebral blood flow in the right temporal lobe cortico-subcortically (arrow) and evident hypoplasia of the right temporo-occipital lobe (patient no. 5).

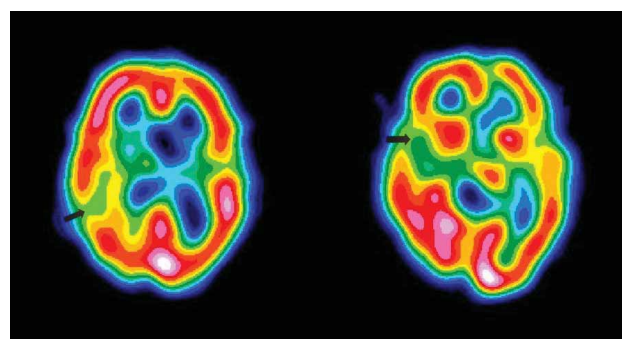


Fig. 3. Three-dimensional reconstruction of interictal SPECT with a »hole« in the right temporal lobe, which represents decreased cerebral blood flow. Temporo-occipital hypoplasia is also present (patient no. 5).

TABLE 2
MORPHOLOGICAL AND FUNCTIONAL CHARACTERISTICS OF MCD SUBGROUPS

MCD subgroups	No. of patients	Unilobar / multilobar	Temporal / frontal lobe involvement	SPECT hypoperfusion
Cortical dysplasia	9	8 / 1	6 / 2	7
Polymicrogyria	4*	3 / 2	2 / 1	4
Lissencephaly	1 [§]	0 / 1	1 / 2	0
Schizencephaly	1	1 / 0	0 / 1	1
Total	15	11 / 4	9 / 6	12

* In two patients (patient no. 5 and 12) with accompanying subcortical nodular heterotopia

Hypoperfusion on interictal Tc-99m ECD SPECT was found in 12 (80.0 %) patients without hyperperfusion. SPECT findings in other three (20%) patients were unremarkable (Table 1). Among various MCD subgroups, hypoperfusion was revealed in seven of nine (77.8 %) patients with cortical dysplasia and in all patients with polymicrogyria (Table 2).

The localization of hypoperfusion seen on interictal SPECT matched with MCD lesions found by MRI in ten (66.7 %) patients (Table 1). Three-dimensional reconstruction of SPECT findings showed a significantly restricted area of hypoperfusion in comparison to the extent of MRI finding. The localization of EEG changes, interictal SPECT hypoperfusion and brain CT lesions correlated with the MRI visible MCD lesion in fourteen, ten and four patients, respectively. Finally, electroclinically confirmed epileptogenicity of MCD overlapped with MR and interictal SPECT findings in fourteen (93.3%) and nine (60.0%) patients, respectively.

Discussion

MCDs are a group of developmental disorders of the cerebral cortex, which can differ in clinical presentation, imaging, genetic and pathologic findings. In forms that are currently recognizable *in vivo* by high resolution MRI, they are increasingly recognized as important causes of developmental delay, intractable epilepsy and other neurological disorders^{19,21}. The true incidence of MCD is even higher, because even high resolution MRI fails to detect some MCDs that are present on pathological inspection.

Recent classification of MCDs¹⁹ provides a useful and logical scheme which can help clinicians in patient classification²². According to MRI findings, cortical dysplasia, heterotopia, polymicrogyria and lissencephaly are among the most common MCD types presented to the tertiary hospital centers because of intractable epilepsy^{19,21,6,20,23}. In our study, nine patients were classified as cortical dysplasia. Such a high number could be explained with higher prevalence of intractable epilepsy in patients with cortical dysplasias and hence more common findings on MRI and in pathological specimens examined in tertiary hospital centers²². The incidence of MCD in the group of epilepsy patients examined during the last year at our Center (N=1875 patients) was 0.8%. MCDs were present

in 4% of patients with intractable epilepsy (n=375, 20%) examined in our Centre in 2007.

Because of higher morbidity and mortality rates, patients with intractable epilepsy represent major health problem. The high frequency and prolonged duration of seizures and episodes of epileptic status, which are commonly present in MCD patients, can cause early cognitive decline as well as psychosocial disturbances resulting in inappropriate quality of life¹⁵. In our study group, ten (66.7%) patients had intractable epileptic seizures with inadequate quality of life. Additionally, epilepsy caused by CD and lissencephaly is commonly refractory to drug treatment; CD is an important cause of focal motor status and *epilepsia partialis continua*. However, polymicrogyria is not invariably associated with epilepsy, and it may present as developmental delay or congenital hemiparesis²². However, in our study, only five (55.56%) CD patients and even three (75%) patients with polymicrogyria had intractable epileptic attacks. Therefore, our results were not concordant with previous reports.

In our study, the localization of MCD lesion visible on MRI matched with interictal EEG discharges in 93.3% of patients, showing that clinical presentation of epileptic attacks and EEG findings taken together highly indicated to the localization of MCD lesion, thus suggesting the high epileptogenicity of MCDs lesions. In contrast, the localization of interictal SPECT changes confirmed interictal EEG findings in only 60.0% of patients.

Based on the intrinsic epileptogenicity of MCD, surgery became the most important modality of treatment. Nowadays, preoperative evaluation is focused on the accurate localization of EZ, rather than the MRI visible lesion alone, because some MCDs may well exceed abnormality identified on MRI^{6,20,24}. Therefore, patients undergoing resective epilepsy surgery for focal MCD may have worse seizure outcome than those with epilepsy due to other focal lesions [16]. Conversely, the extent of MRI abnormalities may be more extensive than EZ. This was observed in patients with good postoperative outcome where total resection of MCD lesion apparent on MRI was not performed^{25–27}. Because of this discordance between MRI detectable lesion and EZ, the addition of other noninvasive as well as invasive techniques in preoperative evaluation is necessary. Functional methods are important because they are complementary to structural images, which show only morphology of the lesion

whilst being unable to demonstrate changes in metabolism and excitation in and around the MCD lesion. Therefore, the addition of functional imaging techniques, such as SPECT and PET has several benefits: it may confirm findings seen on MRI, and sometimes even lesions invisible on MRI. SPECT has several advantages over PET: it is relatively inexpensive to perform, widely available and more accessible. The utility of interictal SPECT in detecting the EZ in patient with MCD had been demonstrated in several studies^{28–30}. Results showed hypoperfusion in 44 % to 62%, and hyperperfusion in 4% of patients with cortical dysplasia^{28,29}. These percentages are surprisingly low, since focal cortical dysplasia lesions have previously been described as highly and intrinsically epileptogenic lesions³⁰. Our opinion is that the main reason for the low percentage lies in the SPECT technique. Ictal SPECT is the best technique to determine EZ, however we have ethical and financial problems related to the issue. In our study, interictal SPECT hypoperfusion was detected in seven (77.77%) of nine patients with focal cortical dysplasia without hyperperfusion. Additionally, in a study that included a heterogeneous group of MCD patients, interictal SPECT revealed hypoperfusion in 62% and hyperperfusion in 17% of 24 patients³¹. The

latter study is comparable to ours according to MCD heterogeneity and percentage of hypoperfusion on interictal SPECT.

The results of our study confirmed that MCDs are highly epileptogenic and therefore a common cause of intractable epilepsy. Our aim was not to define epileptogenic zone in MCD in preoperative evaluation, as it would require ictal SPECT, ictal EEG with long term monitoring and special cortical or other type of invasive EEG monitoring. The MCD types predominant in our study corresponded to MCD types reported in other studies conducted at tertiary medical centers. Interictal SPECT provides moderately useful information to localize MCD in patients with apparent MRI lesion and intractable epilepsy. However, in combination with clinical presentation, MRI and EEG, it represents basic diagnostic approach before using other ictal diagnostic techniques. Nowadays, only a multimodality approach can bring up good preoperative definition of EZ and postoperative outcome. Moreover, daily technological improvements will in the future enable better preoperative detection of EZ extent, which is the key for better postoperative outcome.

REFERENCES

1. PALMINI A, GAMBARDELLA A, ANDERMANN F, Ann Neurol, 37 (1995) 476. — 2. RAYMOND AA, FISH DR, SISODIYA SM, ALSANJARI N, STEVENS JM, SHORVON SD, Brain, 118 (1995) 629. — 3. TAYLOR DC, FALCONER MA, BRUTON CJ, ORSELLIS JA, J Neurol Neurosurg Psychiatry, 34 (1971) 369. — 4. MAZURKIEWICZ-BELDZINSKA M, SZMUDA M, MATHEISEL A, Folia Neuropathol, 44 (2006) 314. — 5. URBACH H, BINDER D, VON LEHE M, PODLOGAR M, BIEN CG, BECKER A, SCHRAMM J, KRAL T, CLÜSMANN H, Seizure, 16 (2007) 608. — 6. GÜNGÖR S, YALNIZOĞLU D, TURANLI G, SAATÇI I, ERDOĞAN-BAKAR E, TOPÇU M, Turk J Pediatr, 49 (2007) 120. — 7. SCHERRER C, SCHUELE S, MINOTTI L, CHABARDES S, HOFFMANN D, KAHANE P, Neurology, 65 (2005) 495. — 8. AVOLI M, BERNASCONI A, MATTIA D, OLIVIER A, HWA GG, Ann Neurol, 46 (1999) 816. — 9. MATHERN GW, CEPEDA C, HURST RS, FLORES-HERNANDEZ J, MENDOZA D, LEVINE MS, Epilepsia, 41(2000) 162. — 10. ZILLES K, QU M, SCHLEICHER A, Eur J Neurosci, 10 (1998) 3095. — 11. HILBIG A, BABB TL, NAJM I, Dev Neurosci, 21 (1999) 271. — 12. CHEN HX, XIANG H, ROPER SN, Epilepsia, 48 (2007) 141. — 13. CRINO PB, DUHAIME A, BALTUCH G, Neurology, 56 (2001) 906. — 14. ALEXANDRE V JR, WALZ R, BIANCHIN MM, VELASCO TR, TERRA-BUSTAMANTE VC, WICHERT-ANA L, ARAÚJO D JR, MACHADO HR, ASSIRATI JA JR, CARLOTTI CG JR, SANTOS AC, SERAFINI LN, SAKAMOTO AC, Seizure, 15 (2006) 420. — 15. KWAN P, BRODIE MJ, Seizure, 11 (2002) 77. — 16. NAJM I, YING Z, BABB T, Neurology, 62 (2004) 9. — 17. ASENBAUM S, BAUMGARTNER C, Nucl Med Commun, 22 (2001) 835. — 18. BINGAMAN WE, Neurology, 62 (2004) 30. — 19. BARKOVICH AJ, KUZNIECKY RI, JACKSON GD, GUERRINI R, DOBYNS WB, Neurology, 57 (2001) 2168. — 20. CHASSOUX F, LANDRE E, RODRIGO S, BEUVON F, TURAK B, SEMAH F, DEVAUX B, Epilepsia, 49 (2008) 51. — 21. LI LM, FISH DR, SISODIYA SM, SHORVON SD, ALSANJARI N, STEVENS JM, J Neurol Neurosurg Psychiatry, 59 (1995) 384. — 22. SISODIYA SM, Lancet Neurol, 3 (2004) 29. — 23. MONTENEGRO MA, CENDES F, LOPES-CENDES I, GUERREIRO CA, LI LM, GUERREIRO MM, Arq Neuropsiquiatr, 65 (2007) 196. — 24. WONG M, Epilepsia, 49 (2008) 8. — 25. SISODIYA SM, Brain, 123 (2000) 1075. — 26. PALMINI A, ANDERMANN F, OLIVIER A, Ann Neurol, 30 (1991) 741. — 27. KUZNIECKY R, MOUNTZ JM, WHEATLEY G, MORAWETZ R, Ann Neurol, 34 (1993) 627. — 28. OTSUBO H, HWANG PA, JAY V, Pediatr Neurol, 9 (1993) 101. — 29. MATSUDA K, MIHARA T, TOTTORI T, Epilepsia, 42 (2001) 29. — 30. MORIOKA T, NISHIO S, ISHIBASHI H, Epilepsy Res, 33 (1999) 177. — 31. MAEHARA T, SHIMIZU H, YAGISHITA A, KAITO N, ODA M, ARAI N, Brain Dev, 21 (1999) 407. — 32. ANDERMANN F, PALMINI AL: Epilepsy Surgery (New York: Raven Press, New York, 1992).

D. Sporiš

Department of Neurology, University Hospital Zagreb, Kišpatičeva 12, 10000 Zagreb, Croatia
e-mail: davor.sporis@zg.htnet.hr

**EPILEPSIJA UZROKOVANA MALFORMACIJAMA U KORTIKALNOM RAZVOJU
– KORELACIJA KLINIČKIH, MRI i Tc-99mECD SPECT NALAZA**

S A Ž E T A K

Malformacije kortikalnog razvoja (MKR) sve se više raspoznaju kao važan uzrok farmakorezistentne epilepsije. Cilj studije bio je utvrditi epileptogenost MKR korelirajući MRI, EET i simptomatologiju epileptičnih napada, te odrediti povezanost MKR na farmakorezistentnost epilepsije. Također je namjera bila utvrditi korisnost interiktalne pretrage SPECT-a za potvrdu proširenosti MKR i relativnu učestalost različitih tipova MKR. Simptomatologija epileptičnih napada i »elektroklinička epileptogenost« MKR prema nalazu MRI mozga utvrđene su na osnovi interiktalnih nalaza EEG. MRI mozga je otkrila kortikalnu displaziju u devetoro bolesnika, polimikrogiriju u četvero bolesnika, te lisencefaliju i shizencefaliju u po jednog bolesnika, dok je troje bolesnika imalo kombinaciju različitih malformacija. Lokalizacija hipoperfuzije na SPECT-u odgovarala je oštećenju MKR u desetoro (66,67%) bolesnika. Elektroklinički potvrđena epileptogenost MKR preklapala se s nalazima MRI i interiktalnog SPECT u četrnaestoro (93,3%) odnosno devetoro (60,0%) bolesnika. Naši su nalazi pokazali kako su MKR visoko epileptogena i čest razlog farmakorezistentnosti u bolesnika sa epilepsijom.