

Lipiodol ultra-fluid - foreign body in the cheek

Macan, Darko; Hat, Josip; Lukšić, Ivica

Source / Izvornik: **Dento Maxillo Facial Radiology, 2008, 37, 171 - 174**

Journal article, Accepted version

Rad u časopisu, Završna verzija rukopisa prihvaćena za objavljivanje (postprint)

<https://doi.org/10.1259/dmfr/51096684>

Permanent link / Trajna poveznica: <https://um.nsk.hr/um:nbn:hr:105:105539>

Rights / Prava: [In copyright](#)/[Zaštićeno autorskim pravom.](#)

Download date / Datum preuzimanja: **2024-07-23**



Repository / Repozitorij:

[Dr Med - University of Zagreb School of Medicine](#)
[Digital Repository](#)





Središnja medicinska knjižnica

Macan D., Hat J., Lukšić I. (2008) *Lipiodol ultra-fluid - foreign body in the cheek.* Dento Maxillo Facial Radiology, 37 (3). pp. 171-4. ISSN 0250-832X

<http://dmfr.birjournals.org/>

<http://dx.doi.org/10.1259/dmfr/51096684>

<http://medlib.mef.hr/713>

University of Zagreb Medical School Repository

<http://medlib.mef.hr/>

Lipiodol UF - foreign body in the cheek

Darko Macan,¹ Josip Hat² and Ivica Lukšić³

¹ Department of Maxillofacial and Oral Surgery, University Hospital Dubrava, School of Dental Medicine, University of Zagreb, Av. G. Šuška 6, 10000 Zagreb, Croatia.

² Department of Radiology, University Hospital "Sisters of Mercy", Vinogradska 29, 10000 Zagreb, Croatia.

³ Department of Maxillofacial and Oral Surgery, University Hospital Dubrava, School of Medicine, University of Zagreb, Av. G. Šuška 6, 10000 Zagreb, Croatia.

Correspondence: Prof.dr.sc. Darko Macan, Department of Maxillofacial and Oral Surgery, University Hospital Dubrava, School of Dental Medicine, University of Zagreb, Av. G. Šuška 6, 10000 Zagreb, Croatia. Tel: +385 91 4664 075; Fax: +385 1 2864 250; e-mail: darkom@kbd.hr

Running title: A foreign body in the cheek

Abstract

We report a case in which Lipiodol Ultra Fluid (UF) leaked from an iatrogenic perforation of Stensen's canal and constituted a foreign body in the cheek. The distribution of contrast medium near the lower border of the mandible seems unusual. Two years after sialography it was still not being resorbed. No radiological signs of reactive inflammatory changes of soft tissue were observed. We think that the contrast agent arrived beneath the skin but external to the platysma through a simple perforation in either the duct and/or the mucosa.

Keywords: sialography, complication; foreign body; cheek

Introduction

Yousem et al.¹ stated that sialography is reserved for the evaluation of chronic sialadenitides unrelated to sialolithiasis, one year later Weber² found that sialography is limited to the evaluation of the duct system for stones and inflammatory diseases. It is the only imaging modality for examining the fine anatomy of the salivary ductal system.³ Sialography is simple and inexpensive, and it has dose advantages over CT. It is still more accessible than MR imaging.⁴ MR sialography is increasingly replacing conventional sialography for the non-invasive visualisation of the ductal system of major salivary glands even though conventional sialography has a higher spatial resolution.⁵ Dynamic MR sialography in addition to MR sialography might be useful for the diagnosis of Sjögren's syndrome. It is a non-invasive diagnostic technique for the functional evaluation of the physiologic state of salivary glands.⁶ Although MRI appears to be an effective first line of

investigation of facial swelling, further studies are required to determine whether it can completely replace invasive sialography.⁷

It is known that iatrogenic rupture of Stensen's canal while performing sialography will cause leakage of the contrast medium into the cheek and cause tissue reaction against this foreign body. There has been a report of Lipiodol retention after sialography without resorption for approximately 6 years.⁸ We have found only one case report in the literature presenting this complication of sialography.⁹ The following report is of a case in which Lipiodol UF (ethyl diiodostearate, May & Baker Ltd., Dagenham, UK) leaked out, probably through an iatrogenic perforation of Stensen's canal, thereby causing a foreign body in the cheek. However, the distribution of contrast medium near the lower mandible seems unusual and we hypothesize that the contrast agent arrived in this location through a perforation of the mucosa. It was not resorbed during the two-year period of observation, and an occasionally troublesome swelling was probably due to the reaction consequent to the extravasated oil.

Case report

A 70-year-old woman visited an oral surgeon at another hospital in June 2003 complaining of a left preauricular swelling that arose periodically but only during food intake. Needle biopsy of the swelling showed salivary gland tissue. The swelling always disappeared after it was massaged.

A general practitioner referred her to an ENT (ear, nose and throat) specialist for clinical examination. At that time a localized swelling, 1 cm in diameter, near Stensen's orifice was observed. It was palpably tender and ampicillin was prescribed, but no

improvement was observed. In June 2003 ultra-sound examination showed diffuse enlargement with a heterogenic echo-structure of the left parotid gland with a hyperechogenic zone (suspected calculus). Dilatation of the duct was performed and the calculus was not identified. Two weeks later, corticosteroids were injected into Stensen's duct, and probably also into the gland. In January 2004, sialography was performed using Lipiodol UF; the patient reported only mild discomfort, not pain, during the sialography. In March 2004, a sialoscopy failed to locate a calculus. In May 2004, a CT scan was performed, and unfortunately the radiopacities in the vicinity of the mandibular lower border (Figure 1) were not recognized and the CT scan was described as normal.

In October 2004, the ENT specialist referred the patient to our Department with the same complaint of periodical swelling of the left parotid gland and periodic swelling of the lower part of the left cheek. A radiograph of the cheek on dental film in the vicinity of Stensen's duct, produced to investigate the presence of calculus, revealed radiopacities; these were the contrast medium that had leaked out of the duct after the iatrogenic rupture during sialography (Figure 2). A lateral craniogram demonstrated radiopacities from the vicinity of Stensen's duct to the lower border of the mandible (Figure 3). On the CT scan taken 11 months after sialography, numerous radiopacities that spread across the cheek over an area of 3 x 2 x 2.5 cm can easily be observed (Figures 4 and 5). There were no signs of reactive inflammatory changes of soft tissue. We planned to perform sialography using a water-based contrast medium, but the patient refused because of her previous experience with the procedure. Three years later the patient has still the same periodic swelling of the left parotid region and left cheek.

Discussion

Water-soluble rather than fat-soluble contrast agents are preferred for sialography because they permeate finer elements of the ductal system and are less likely to be retained in obstructive disease. In addition, their use results in less patient discomfort and few foreign body reactions have been precipitated by water-soluble media.¹⁰ Although the literature regarding the properties and side effects of contrast agents is extensive, the conclusions on these side effects are contradictory and controversial. Verhoeven concluded that a long-term clinical study is needed, so that an optimal agent may be selected.¹¹ Nevertheless, a comparative study of oil-based and water-based contrast agents revealed no adverse reactions or side effects with any of the contrast media.^{12,13} Nicholson¹⁴ has concluded that Urografin 290 (meglumine diatrizoate 52.1% w/v and sodium diatrizoate 7.9% w/v, Schering, Berlin, Germany) is the better contrast agent for sialography because of better filling of intragland ducts and greater clinical tolerance than with Lipiodol UF. However, for Kalk et al.¹⁵ the use of oil-based contrast fluid results in superior image quality, and for those authors sialography still has its use in the evaluation of Sjögren syndrome. Unfortunately, in the case of iodine allergy, alternative positive non-iodine contrast materials that are currently in use are not suitable for sialography.¹⁵

The cardinal rules are that the injection should be stopped when the gland is full, if the dye is extravasated or when the patient experiences mild discomfort. If there has been acinar filling with an oil-based medium, with a haze outlining the gland, there may have been secretory duct rupture with dye expressed into the adjacent connective tissue. If this is the case, the haze will remain for several days after the procedure. If larger excretory ducts

have ruptured and dye has been forced into the connective tissue, it will remain pooled in the area for weeks.¹⁰

Only if an iatrogenic "fausse route" is induced during contrast infusion, a less favorable tissue response to be expected from oil-based contrast medium; this is because in such situations the contrast agent remains in the gland parenchyma for a long time, inducing a chronic granulomatous inflammation, as opposed to the quick clearance of water-based contrast in the same situation. If the practitioner is uncertain about the ductal probing or is inexperienced with contrast sialography, it seems wise to use water-based contrast fluids. The risk of adverse tissue reaction from a possible fausse route or overfilling is thereby minimized.¹³ Thirty minutes after sialography in rabbits, most of the water-soluble media tested had been completely evacuated from both normally filled and overfilled glands. Suspensions and the oily media had longer retention times, and in the case of overfilled glands most of these media were retained for at least 7 days.¹¹

Pettini and Laforgia¹⁶ compared the use of oil-based Lipiodol UF and water-based Urovison for sialography in dogs. They concluded that Lipiodol is irritant, especially if it passes beyond the salivary excretory tree, but this was not enough to have it banned absolutely. After subcutaneous injection of contrast medium in rats, retention of contrast medium was radiographically visible to varying degrees with the suspensions and all oily media in skin tissue after 2 and 8 days.¹¹

With some oil-based contrast media, glandular overfilling and iatrogenic damage to Stensen's duct were followed by chronic inflammation and formation of lipogranuloma, extensive destruction of the parenchyma and formation of vacuoles filled with contrast medium.⁹ However, Baurmash¹⁷ suggested that the lipid material found in conjunction with the extravasated medium was not a pathological state, but rather remnants of the

environment in which the granulomatous reaction occurred. A diagnosis of foreign-body giant-cell granuloma rather than lipogranuloma should have been made.

Image intensifier fluoroscopy during sialography can be of value in the prevention of glandular overfilling and also helps to prevent a "fausse route".¹⁸

Digital subtraction sialography enables excellent vision of alterations within the parenchyma, changes that have an effect on the lumen and position of the canal, and eventual changes that are conditioned by external factors. The smallest canal structures are also shown by this method.¹⁹ Magnetic resonance sialography is useful for diagnosing sialolithiasis and sialadenitis. It allows diagnosis of sialadenitic changes, but digital subtraction sialography achieves a better diagnostic performance owing to higher spatial resolution.^{20,21}

In summary, "fausse route" of Stensen's canal should be considered if swelling of the cheek has occurred after sialography, and the patient should be informed of possible complications and soft-tissue reactions to a foreign body. In our patient, some of the contrast agent is apparently just beneath the skin but external to the platysma. We hypothesize that the contrast agent originated through a simple perforation of either the duct or the mucosa. The foreign-body reaction will occasionally cause benign facial swellings, but generally nothing more. An attempt to remove the agent is unnecessary and impossible because of the wide dispersion of the oil.

References

1. Yousem DM, Kraut MA, Chalian AA. Major salivary gland imaging¹. *Radiology* 2000; **216**: 19-29.
2. Weber AL. History of head and neck radiology: Past, present and future¹. *Radiology* 2001; **218**: 15-24.
3. Som PM, Brandwein M. Salivary glands. In: Som PM, Curtin HD (eds). *Head and neck imaging* (3rd edn). St. Louis: Mosby, 1996, pp 834-836.
4. Drage NA, Brown JE, Wilson RF. Pain and swelling after sialography: Is it a significant problem? *Oral Surg Oral Med Oral Pathol Oral Radiol Endod* 2000; **90**: 385-388 .
5. Faye N, Tassart M, Perie S, Deux JF, Kadi N, Marsault C. [Imaging of salivary lithiasis]. *J Radiol* 2006; **87**: 9-15.
6. Morimoto Y, Habu M, Tomoyose T, Ono K, Tanaka T, Yoshioka I et al. Dynamic magnetic resonance sialography as a new diagnostic technique for patients with Sjögren's syndrome. *Oral Dis* 2006; **12**: 408-414.
7. Browne RFJ, Golding SJ, Watt-Smith SR. The role of MRI in facial swelling due to presumed salivary gland disease. *Br J Radiol* 2001; **74**: 127-133.
8. Özdemir D, Polat NT, Polat S. Lipiodol UF retention in dental sialography. *Br J Radiol* 2004; **77**: 1040-1041.
9. Shigetaka Y, Masatsugu S, Yoshikuni F, Yoshihiro T. Parotid and pterygomaxillary lipogranuloma caused by oil-based contrast medium used for sialography: Report of a case. *J Oral Maxillofacial Surg* 1996; **54**: 350-353.

10. Reiskin AB, Lurie AG. Specialized Radiographic Techniques. In: Goaz PW, White SC. *Oral radiology* (2nd edn). St. Louis: Mosby, 1987, pp 369-376.
11. Verhoeven JW. Choice of contrast medium in sialography. *Oral Surg Oral Med Oral Pathol* 1984; **57**: 323-337.
12. Holtgrave E, Elke M, Lüthy H. Sialography with Telebrix 38. A comparative study with Lipiodol-UF in the diagnosis of salivary gland diseases. *Dentomaxillofac Radiol* 1973; **2**: 68-72.
13. Kalk WWI, Vissink A, Spijkervet FKL, Möller JM, Roodenburg JLN. Morbidity from parotid sialography. *Oral Surg Oral Med Oral Pathol Oral Radiol Endod* 2001; **92**: 572-575.
14. Nicholson DA. Contrast media in sialography: a comparison of Lipiodol Ultra Fluid and Urografin 290. *Clin Radiol* 1990; **42**: 423-426.
15. Kalk WWI, Vissink A, Spijkervet FKL, Bootsma H, Kallenberg CGM, Roodenburg JLN. Parotid sialography for diagnosing Sjögren syndrome. *Oral Surg Oral Med Oral Pathol Oral Radiol Endod* 2002; **94**: 131-137.
16. Pettini PL, Laforgia PD. [Reactions of the submandibular salivary gland caused by sialography. Experimental research in dogs]. *Minerva Stomatol* 1977; **26**: 175-184.
17. Baurmash H. Diagnosis and treatment of Lipiodol-induced foreign body reaction in the parotid gland. *J Oral Maxillofac Surg* 1996; **54**: 1041-1042.
18. Verhoeven JW, Sanderink GCH. Indirect radiography with the use of an image intensifier in dentomaxillofacial radiology. *Dentomaxillofac Radiol* 1979; **8**: 17-29.
19. Borković Z, Perić B, Ožegović I. The value of digital subtraction sialography in the diagnosis of diseases of the salivary glands. *Acta Stomatol Croat* 2002; **36**: 501-505.

20. Heverhagen JT, Kalinowski M, Rehberg E, Klose KJ, Wagner HJ. Prospective comparison of magnetic resonance sialography and digital subtraction sialography. *J Magn Reson Imaging* 2000; **11**: 518-524.
21. Kalinowski M, Heverhagen JT, Rehberg E, Klose KJ, Wagner HJ. Comparative study of MR sialography and digital subtraction sialography for benign salivary gland disorders. *AJNR Am J Neuroradiol* 2002; **23**: 1485-1492.

LEGEND

Figure 1. Axial CT scan – High density areas in the vicinity of the mandibular lower border were not recognized.

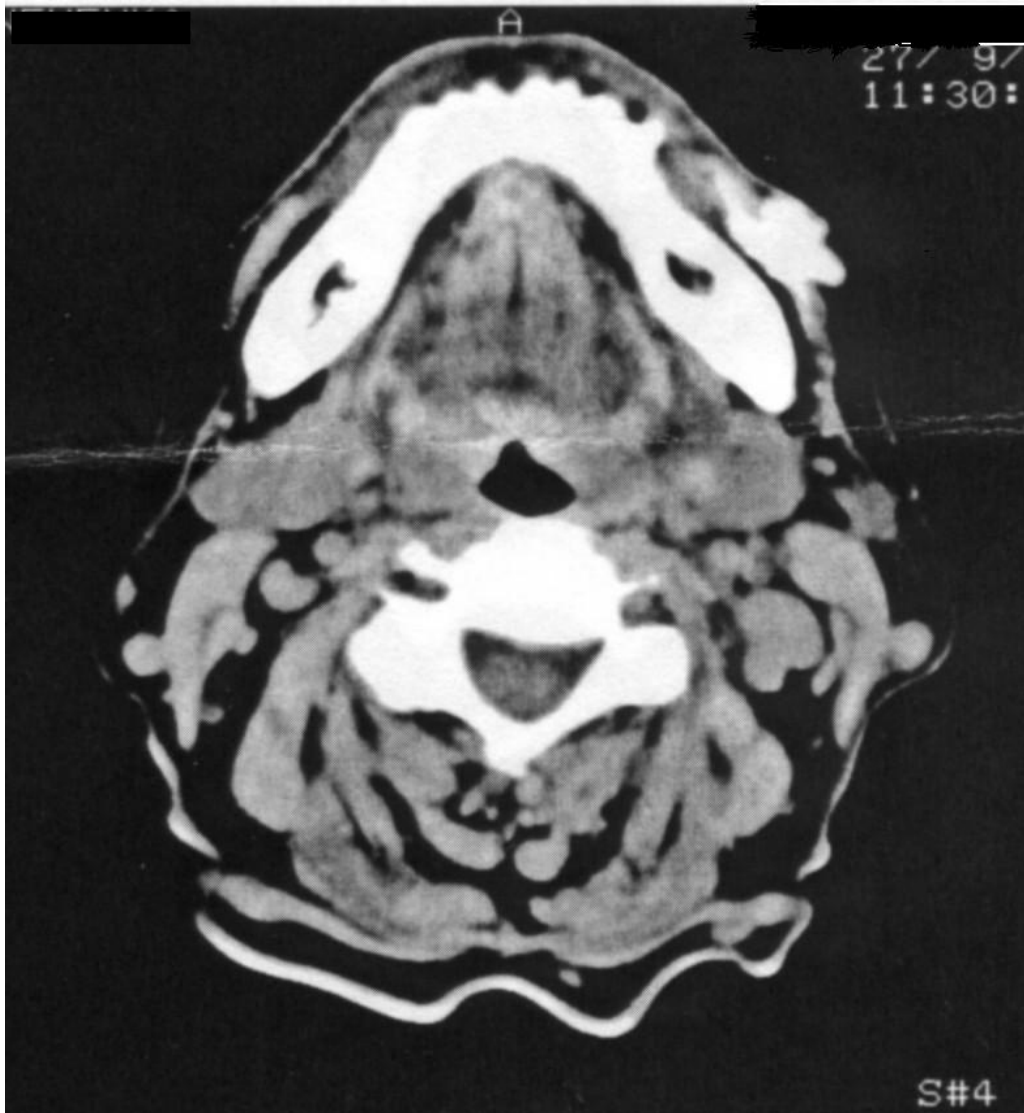

Figure 2. Radiograph of the cheek (dental film) in the vicinity of Stensen's duct demonstrated high density areas – the contrast medium.

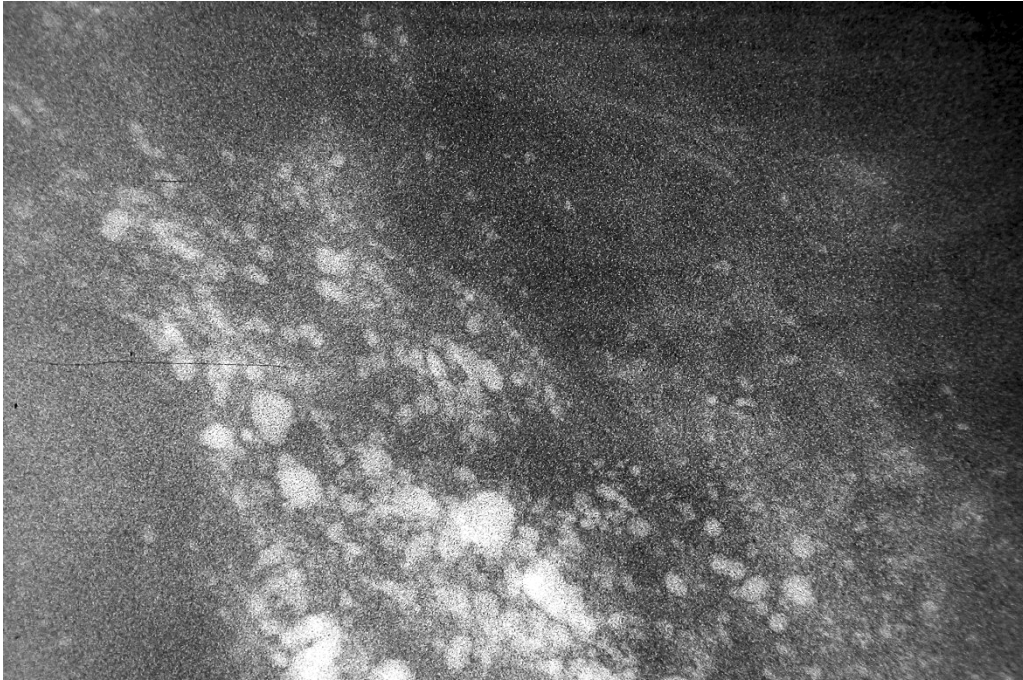


Figure 3. Lateral craniogram – high density areas from the Stensen's duct to the lower border of the mandible.

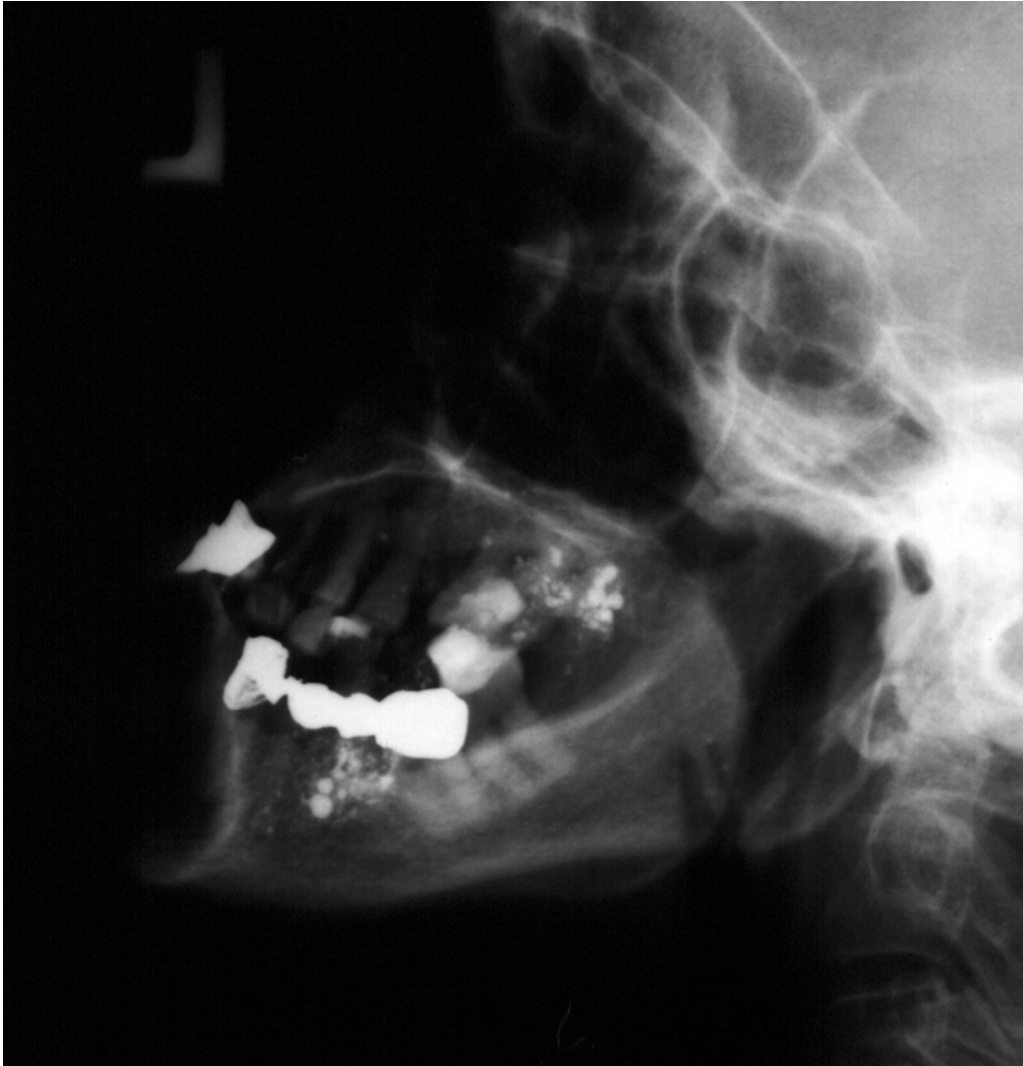

Figure 4. Axial CT scan 11 months after sialography – high density areas in the vicinity of the lower border of the mandible.

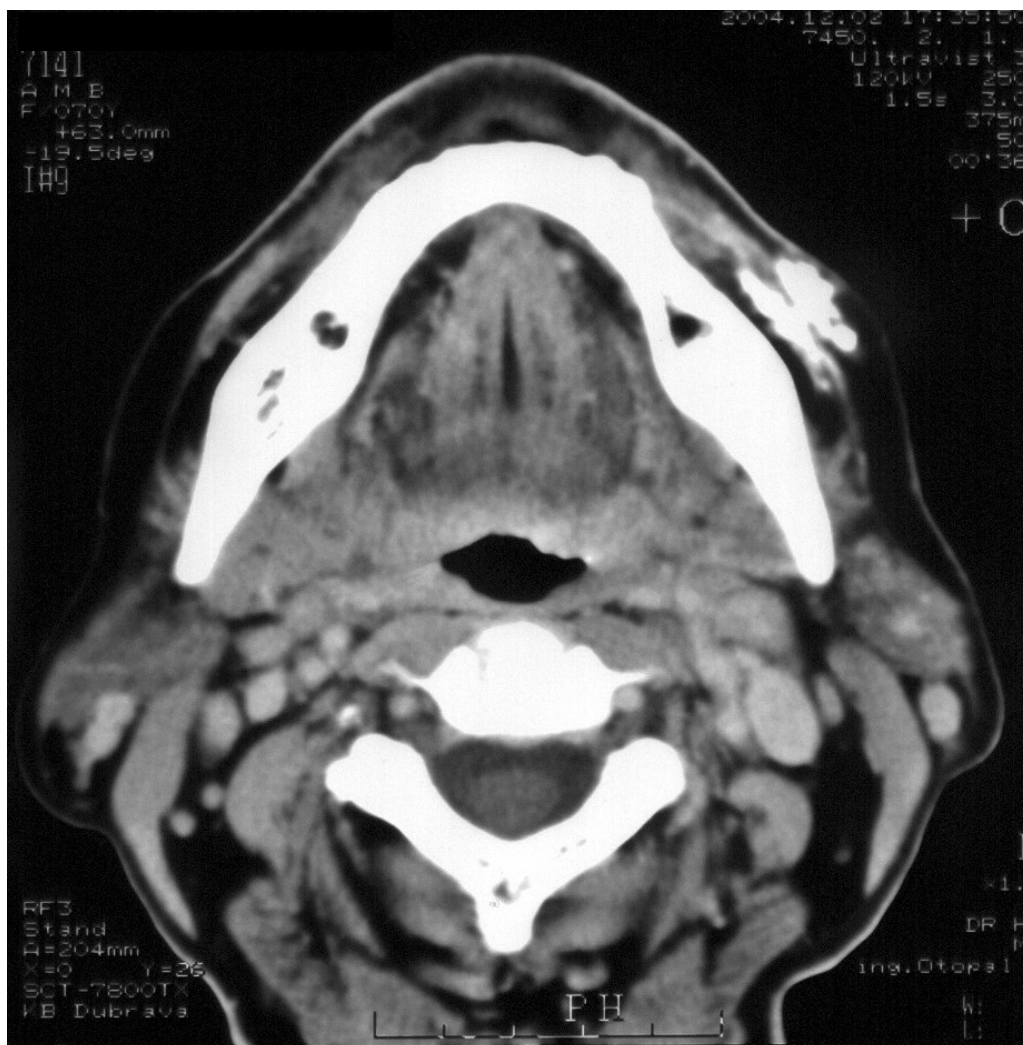

Figure 5. CT scan 11 months after sialography – numerous high density areas in the left cheek.

