



Središnja medicinska knjižnica

**Tomas D., Tomić K., Bekavac-Bešlin M., Jukić Z., Belicza M., Krušlin B.
(2006) *Primary glomangioma of the esophagus mimicking esophageal papilloma*. *Diseases of the Esophagus*, 19 (3). pp. 208-11. ISSN 1120-8694**

<http://www.wiley.com/bw/journal.asp?ref=1120-8694>

<http://www3.interscience.wiley.com/journal/118000485/home>

<http://dx.doi.org/10.1111/j.1442-2050.2006.00568.x>

<http://medlib.mef.hr/725>

University of Zagreb Medical School Repository

<http://medlib.mef.hr/>

**PRIMARY GLOMANGIOMA OF THE ESOPHAGUS MIMICKING
ESOPHAGEAL PAPILOMA**

**Davor Tomas¹, Karla Tomić¹, Miroslav Bekavac-Bešlin²,
Zoran Jukić³, Mladen Belicza¹, Božo Krušlin¹**

¹Ljudevit Jurak Department of Pathology and ²Department of Surgery, Sestre milosrdnice University Hospital, Zagreb, Croatia

³Department of Surgery, General Hospital Nova Gradiška, Nova Gradiška, Croatia

Corresponding author:

Davor Tomas, M.D., M.S.

Department of Pathology, Sestre milosrdnice University Hospital

Vinogradska 29, 10 000 Zagreb, Croatia

Tel: 385 1 3787 909, Fax: 385 1 3787 244, E-mail: dtomas@kbsm.hr

Authors' contribution to the paper:

Davor Tomas – substantial contributions to conception and design of the article, acquisition, analysis and interpretation of data, drafting, revising and final approval of the article

Karla Tomić - substantial contributions to conception and design of the article, acquisition of data, drafting and final approval of the article

Miroslav Bekavac-Bešlin - substantial contributions to conception and design of the article, acquisition of data, drafting and final approval of the article

Zoran Jukić - substantial contributions to conception and design of the article, acquisition of data, drafting and final approval of the article

Mladen Belicza - substantial contributions to conception and design of the article, analysis and interpretation of data, drafting and final approval of the article

Božo Krušlin – substantial contributions to conception and design of the article, analysis and interpretation of data, drafting, revising and final approval of the article

Running title: Primary glomangioma of the esophagus

ABSTRACT

We report a case of glomangioma of the esophagus in a 28-year-old woman who presented with a three years long history of vague discomfort, pain and heat in the neck. At initial gross examination, the tumor mimicked an esophageal papilloma. The resected esophageal specimen contained polypoid, whitishgray mass, which measured 3 cm in maximum diameter. Microscopically tumor was consisted of loosely, fibrovascular stroma heavily infiltrated with mononuclear inflammatory cells and covered with focally hyperkeratotic, parakeratotic and acanthotic squamous epithelium without atypia. In the deeper area immediately above true muscular layer of esophageal wall, microscopical examination revealed the neoplasm consisting of numerous, small-to-medium branched vessels covered by regular endothelium and filled with erythrocytes. The loosely stroma around vessels contained poorly circumscribed nests of small, round to oval cells with a uniform appearance. Immunohistochemically, the tumor cells were immunoreactive for smooth muscle actin and vimentin and non-immunoreactive for CD34, CD117, desmin, pan-cytokeratin, synaptophysin, neuron-specific enolase and S-100 protein. Despite its bland histology, infiltrative growth pattern was suggestive of aggressive behavior; thus, an appropriate clinical follow-up was recommended. An accurate diagnosis and an understanding of the behavior of these rare tumors, especially in an unusual location are crucial to its management and clinical outcome.

KEY WORDS: esophagus, glomangioma, immunohistochemistry

CASE REPORT

A 28-year-old woman presented with a three years long history of vague discomfort, pain and heat in the neck. The patient denied dysphagia, regurgitation, emesis, melanotic or bloody stool and weight loss. Upper endoscopy accompanied with biopsy was performed and demonstrated polypoid protrusion situated in esophagus two centimeters from gastroesophageal junction, which measured 0.5 cm. Multiple biopsies were non-diagnostic and revealed only hyperkeratotic, parakeratotic, acanthotic, squamous epithelium without atypia. The patient was treated conservatively with some improvement in symptoms. Two weeks before surgery dysphagia for solids with retrosternal heat and pain appeared and symptoms were rapidly worsening. Computed tomography and repeated endoscopy revealed polypoid tumor, which measured up to 3 cm and the patient underwent partial esophagectomy with gastroesophageal anastomosis.

The four centimeter long resected esophageal specimen contained polypoid, whitishgray mass that measured 3 cm in maximum diameter (Fig. 1). Microscopically, tumor was consisted of loosely, fibrovascular stroma heavily infiltrated with mononuclear inflammatory cells and covered with focally hyperkeratotic, parakeratotic and acanthotic squamous epithelium without atypia. Beneath the epithelium small focus of multinucleated giant cells was found. In the deeper area immediately above true muscular layer of esophageal wall microscopical examination showed a neoplasm consisting of numerous, small-to-medium branched vessels covered by regular endothelium and filled with erythrocytes. The loosely stroma between the vessels contained poorly circumscribed nests of small, round to oval uniform cells (Fig. 2). The nuclei were uniformly round and had no to minimal atypia with a vesicular chromatin

pattern and occasionally single nucleoli. The cytoplasm was moderate and densely eosinophilic. Spindle cells, tumor necrosis, perineural or intravascular invasion were not observed. The mitotic rate varied from 1 to 2 per 50 high-powered fields (HPF). The tumor had irregular borders and in few areas infiltrated muscular layer but did not penetrate into subserosa (Fig. 2). **During surgical procedure one lymph node from gastroesophageal junction was received on frozen section analysis. Lymph node measured 0.6 cm in diameter and was without tumor. No additional lymph nodes were found in surgical specimen.** Surgical margins were free of tumor.

Immunohistochemically, the tumor cells were immunoreactive for smooth muscle actin and vimentin (Fig. 3A, B). CD34 immunostains only highlighted the vascular network of the neoplasm. The tumor cells were negative for pan-cytokeratin, desmin, S-100 protein, CD117, synaptophysin and neuron-specific enolase. In addition, Ki-67 immunostain showed up to 5% labeling index in the neoplastic cells. These results established the diagnosis of a primary esophageal glomangioma.

The patient had an uneventful postoperative course and was discharged twelve days after surgery. Two weeks after discharge gastroesophageal reflux with nausea and vomiting appeared and the patient was again hospitalized. Control endoscopy revealed intact gastroesophageal anastomosis without signs of tumor, but also **delayed gastric emptying** with **slow** propulsion of gastric content through pylorus. The patient was conservatively treated with improvement in symptoms and discharged with recommendation of appropriate follow-up. **Six months after surgery the patient is well and shows no signs of tumor recurrence or spread.**

DISSCUSION

Glomangioma, a subset of glomus tumor originally described by Masson in 1924, is a distinct perivascular neoplasm that is believed to originate from modified smooth muscle cells that are present in the walls of specialized arteriovenous shunts included in thermoregulation.¹ Glomus tumor is composed of varying proportions of glomocytes, blood vessels and smooth muscle. On the basis of proportions of the components, glomus tumors are divided in three subgroups: glomus tumor proper, glomangioma and glomangiomyoma.² Glomus tumor occurs mostly in young adults (aged 20-40 years), typically as a solitary, exquisitely painful nodule, but can also occur in children. Women and man are equally affected. A majority of glomus tumors have been reported to occur in the skin of the hand, particularly in the subungual region.^{2,3} However, they have also been reported in the deep soft tissue, bone, lung and gastrointestinal tract, especially the stomach.²⁻⁶

Most glomus tumors are benign but rare cases of atypical and malignant glomus tumor with recurrences, metastases and death are on record.^{2,7,8} There have been attempts to separate malignant glomus tumor from those of uncertain malignant potential.^{2,7} Gould *et al.* classified the potentially malignant glomus tumors into locally infiltrative glomus tumors, glomangiosarcomas arising in a benign glomus, and de novo glomangiosarcomas.⁷ Folpe *et al.* retrospectively analyzed 52 cases of atypical glomus tumors of the peripheral soft tissue in an attempt to establish criteria of malignancy and proposed that atypical tumors be classified by use of the following four types: 1) malignant, 2) symplastic, 3) glomus tumors of uncertain malignant potential, and 4) glomangiomatosis.² Those authors also proposed that deep location, size larger than 2 cm, atypical mitotic figures, moderate-to high-grade nuclear atypia, and 5 or more

mitoses per 50 HPF should be considered as criteria for malignancy.² However, criteria for malignancy and behavior of glomus tumors arising in internal organs are not well known due to rarity of such cases and limited follow-up. To our knowledge, the current study is the third to document a glomus tumor within the esophagus in English literature.^{9,10}

Because of the rarity of glomus tumor in this location, several other tumors were included in the differential diagnosis. The main diagnostic considerations for esophageal glomus tumor include hemangiopericytoma, hemangioendothelioma, epithelioid leiomyoma (leiomyoblastoma), gastrointestinal stromal tumor (GIST), carcinoid tumor and paraganglioma.^{5,11-15} Glomus tumor can have a hemangiopericytomatous (staghorn) vascular pattern, but hemangiopericytomas are negative for actin and positive for CD34 and lack the uniform round cells that are seen in glomus tumor.¹¹ Features typical of hemangioendothelioma, such as intravascular tufting or intracytoplasmic lumina were also lacking in our case. The tumor was negative for desmine, excluding an epithelioid leiomyoma (leiomyoblastoma).¹³ The lack of CD117 positivity has also been described as a feature of glomus tumor of gastrointestinal origin, and this helps distinguish glomus tumors from GIST.⁵ Our case was negative for CD117. The presence of uniform cells with central nuclei, clear to eosinophilic cytoplasm, and occasional organoid growth pattern also suggests the diagnosis of carcinoid tumor or paraganglioma. The immunohistochemical staining pattern usually assists in differentiating these entities: glomus tumor shows positivity for actin, whereas tumors with neuroendocrine features show positivity for neuron-specific enolase and synaptophysin.^{14,15} Glomus tumors are usually negative for all neuroendocrine markers.³ In the case reported herein, both aforementioned

neuroendocrine stains and S-100 protein were negative ruling out carcinoid tumor and paraganglioma.

The overall histology and immunohistochemical features in our case were similar to only two other reported cases of primary glomangioma of the esophagus in the English literature.^{9,10} **Papla and Zielinski reported one case of glomus tumor of the esophagus in a 79-year-old women who underwent only palliative surgery and died 24 months after diagnosis. The exact reason of death was not established because the autopsy was not performed.⁹ Second case of a 41-year old female patient with incidentally diagnosed multiple glomus tumors of the esophagus and lung was reported by Altorjay et al.¹⁰ Thirty-six month after surgery the patient was well and symptom free.¹⁰**

In the present case, the benign cytohistologic features, including uniform appearance with minimal atypia, low mitotic rate and low Ki67 labeling index, as well as complete surgical removal should be expected to be associated with an excellent clinical outcome but appropriate clinical follow-up was suggested because of infiltrative growth pattern was observed with penetration of tumor cells in muscular layer of esophageal wall.

REFERENCES

1. Masson P. Le glomus neuromyoarterial des regions tactiles et ses tumeurs. Lyon Chir 1924; 2: 257-80.
2. Folpe A L, Fanburg-Smith J C, Miettinen M, et al. Atypical and malignant glomus tumor: analysis of 52 cases, with a proposal for the reclassification of glomus tumor. Am J Surg Pathol 2001; 25: 1-12.
3. Weiss S W, Goldblum J R. Perivascular tumors. In: Weiss S W, Goldblum J R (ed.) Enzinger soft tissue tumors, 4th edn. St Louis: Mosby, 2001; 985-1035.
4. Bahk W J, Mirra J M, Anders K H. Intraosseous glomus tumor of the fibula. Skeletal Radiol 2000; 29: 708-12.
5. Koss M, Hochholzer L, Moran C. Primary pulmonary glomus tumor: a clinicopathologic and immunohistochemical study of two cases. Mod Pathol 1998; 11: 253-8.
6. Miettinen M, Paal E, Lasota, J, Sobin L. Gastrointestinal glomus tumor: clinicopathologic, immunohistochemical and molecular genetic study of 32 cases. Am J Surg Pathol 2002; 37: 1237-40.
7. Gould E W, Manivel J C, Albores-Saavedra J, et al. Locally infiltrative glomus tumors and glomangiosarcomas. A clinical, ultrastructural, and immunohistochemical study. Cancer 1990; 65: 310-8.
8. Breathwaite C, Poppiti R. Malignant glomus tumor: a case report of widespread metastases in a patient with multiple glomus body hamartomas. Am J Surg Pathol 1996; 20: 233-8.
9. Pala B, Zelinski M. Glomus tumor of the oesophagus. Pol J Pathol 2001; 52: 133-5.

10. Altorjay A, Arato G, Adame M, *et al.* Synchronous multiple glomus tumors of esophagus and lung. *Hepatogastroenterology* 2003; 50: 687-90.
11. Espat N J, Lewis J J, Leung D, *et al.* Conventional hemangiopericytoma: modern analysis of outcome. *Cancer* 2000; 95: 1746-51.
12. Versaci A, Macri A, Scuderi G, *et al.* Epithelioid hemangioendothelioma of the stomach: clinical-pathological features, nosologic setting, and surgical therapy. Report of a case. *Surg Today* 2002; 32: 274-7.
13. Huang X F, Wang C M, Pan B R, *et al.* Pathological characteristics of gastric leiomyoblastoma. *World J Gastroenterol* 2004; 10: 3182-4.
14. Hoang M P, Hobbs C M, Sobin L H, Albores-Saavedra J. Carcinoid tumor of the esophagus: a clinicopathologic study of four cases. *Am J Surg Pathol* 2002; 26: 517-22.
15. Weinrach D M, Wang K L, Blum M G, Yeldandi A V, Laskin W B. Multifocal presentation of gangliocytic paraganglioma in the mediastinum and esophagus. *Hum Pathol* 2004; 35: 1288-91.

FIGURES

Fig. 1 The resected esophageal specimen contained polypoid, whitishgray tumor (arrows), which measured 3 cm in largest diameter covered by thickened mucosa.

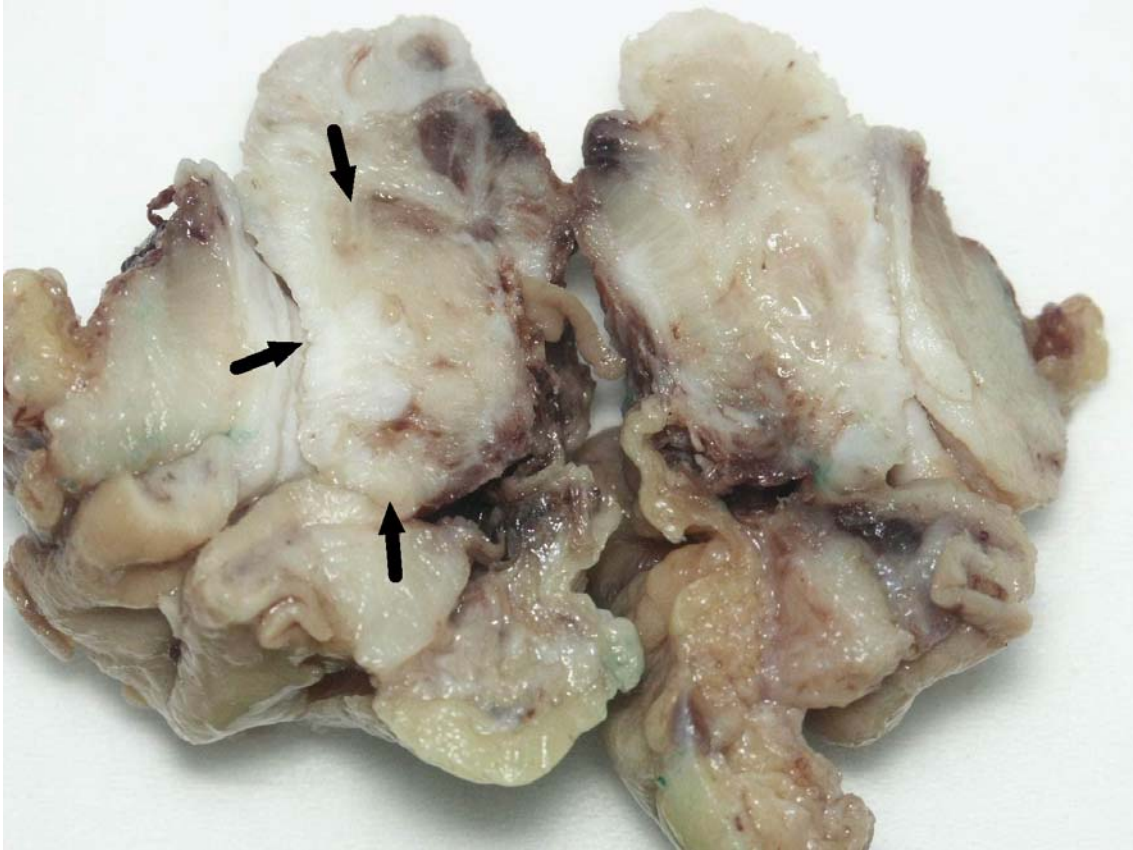

Fig. 2 The tumor consisted of numerous, small-to-medium branched vessels and, the loosely stroma with poorly circumscribed nests of small, round to oval uniform cells. The tumor cells infiltrate muscular layer but do not penetrate into subserosa (hematoxylin-eosin, original magnification X100).

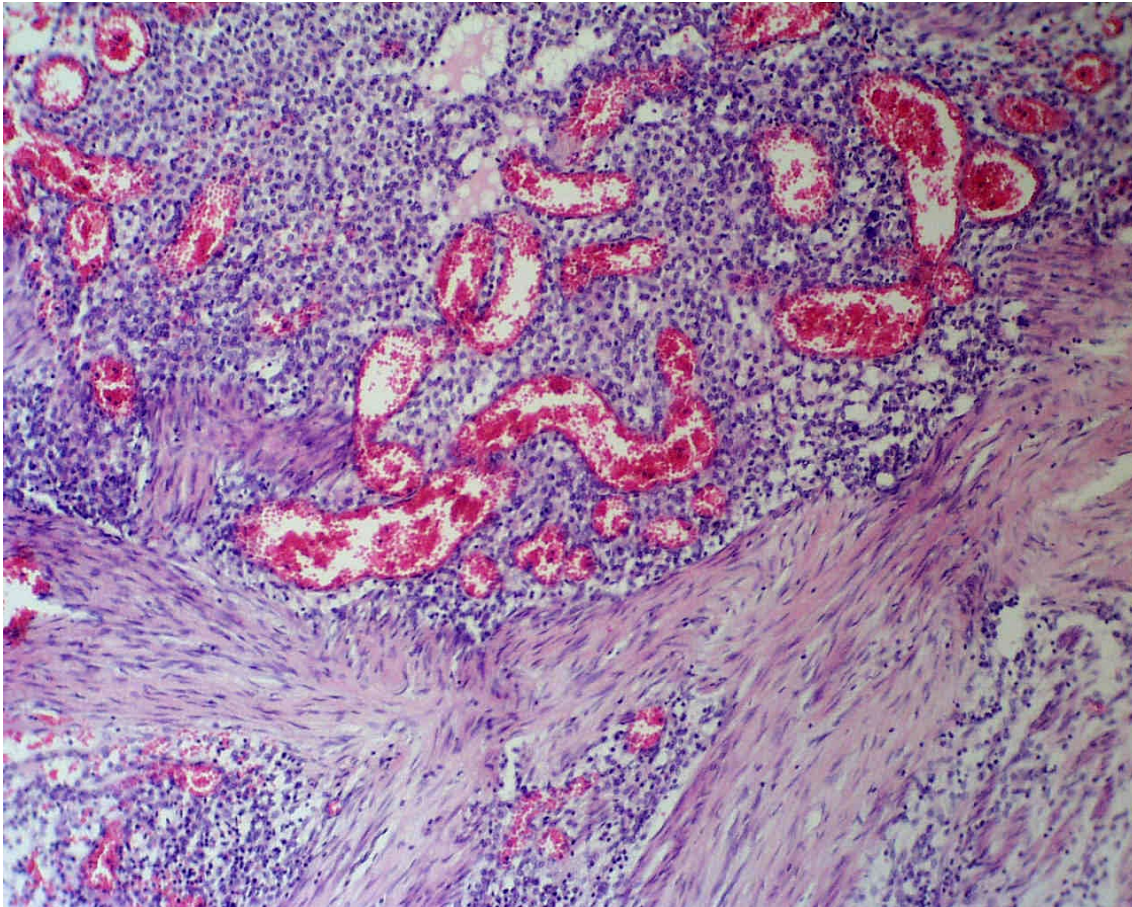


Fig. 3 Diffuse intense staining for smooth muscle actin (A) and vimentin (B) in tumor cells (smooth muscle actin and vimentin, original magnification X400).

