

# An unusual case of forehead post-transplant lymphoproliferative disease

---

**Bašić-Jukić, Nikolina; Kes, Petar; Bubić-Filipi, Ljubica; Ćorić, Marijana**

*Source / Izvornik:* **Kidney International, 2008, 73, 136 - 136**

**Journal article, Accepted version**

**Rad u časopisu, Završna verzija rukopisa prihvaćena za objavljivanje (postprint)**

<https://doi.org/10.1038/sj.ki.5002592>

*Permanent link / Trajna poveznica:* <https://um.nsk.hr/um:nbn:hr:105:838375>

*Rights / Prava:* [In copyright](#) / [Zaštićeno autorskim pravom.](#)

*Download date / Datum preuzimanja:* **2024-07-23**



*Repository / Repozitorij:*

[Dr Med - University of Zagreb School of Medicine  
Digital Repository](#)





## Središnja medicinska knjižnica

**Bašić-Jukić N., Kes P., Bubić-Filipi Lj., Ćorić M. (2008) *An unusual case of forehead post-transplant lymphoproliferative disease*. *Kidney International*, 73 (1). pp. 136. 0085-2538**

<http://www.nature.com/ki/>

<http://dx.doi.org/10.1038/sj.ki.5002592>

<http://medlib.mef.hr/728>

University of Zagreb Medical School Repository

<http://medlib.mef.hr/>

## **An unusual case of forehead post-transplant lymphoproliferative disease**

Nikolina Bašić-Jukić, Petar Kes, Ljubica Bubić-Filipi, Marijana Ćorić

Department of Dialysis, University Hospital Centre Zagreb, Kišpatićeva 12, Zagreb 10000, Croatia.  
nina\_basic@net.hr

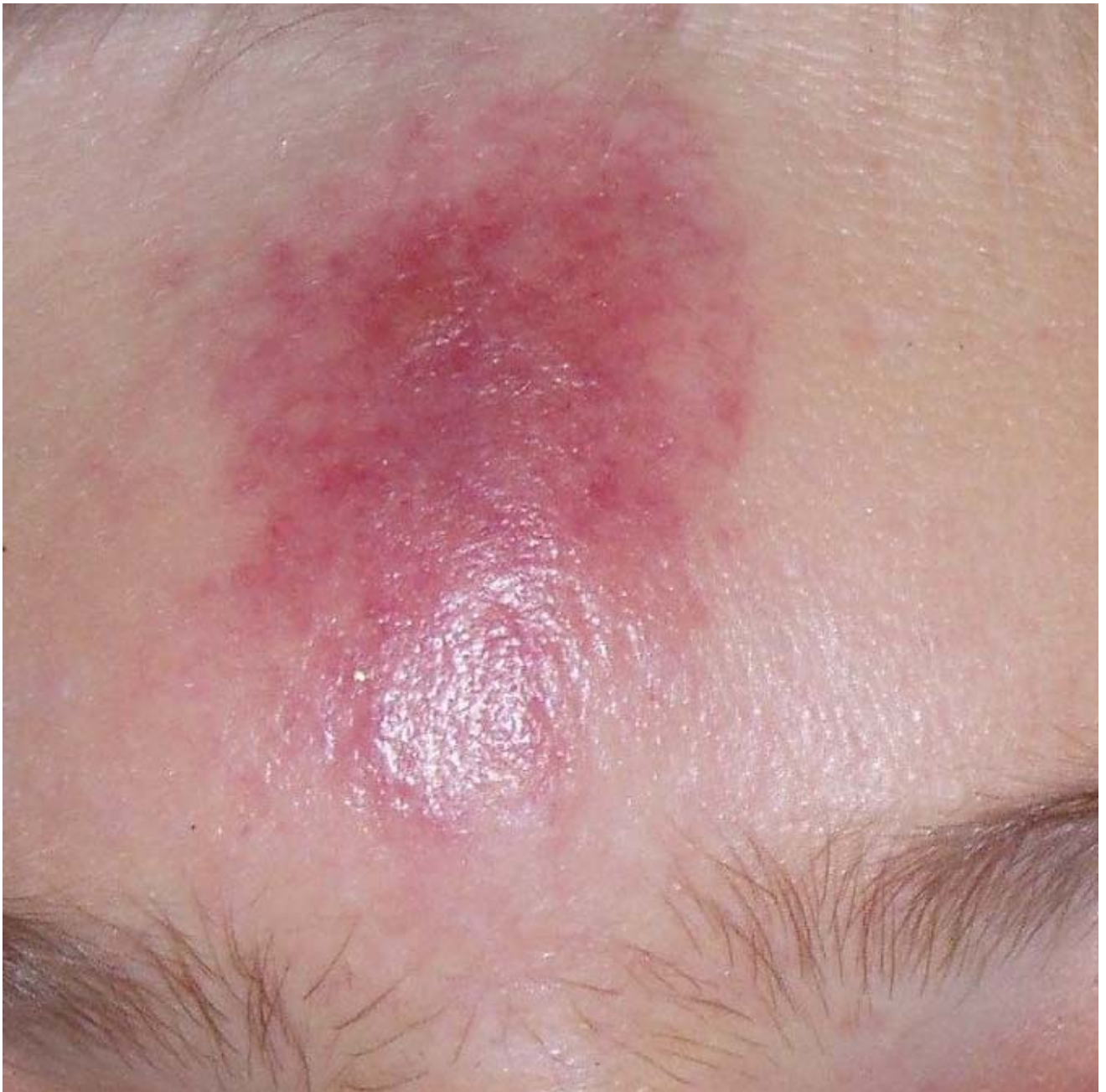A 37-year-old woman with end-stage kidney failure from vesicourethral reflux received her second cadaveric renal allograft in January 2006. The maintenance immunosuppressive protocol consisted of tacrolimus, mycophenolate mofetil and steroids. She had stable graft function with a serum creatinine of 110  $\mu\text{mol/l}$ . In August 2006, she noticed a mass on her forehead that was painless and movable. However, the tumor was fast-growing and 1 month later became purple and painful causing swelling of the periorbital area (Figure 1a). Computed tomography imaging revealed a subcutaneous soft tissue mass without bony invasion (Figure 1b). A biopsy of the mass was performed, which showed atypical lymphoid cells that were positive for CD20 antigen (Figure 1c) and negative for CD3, suggestive of post-transplant lymphoproliferative disease (PTLD). The patient had no systemic manifestations of lymphoma. Computed tomography of thorax and abdomen and sternal puncture excluded other sites of involvement by post-transplant lymphoproliferative disease. Tacrolimus and mycophenolate mofetil were reduced by 50%, and methylprednisolone was continued (10 mg/day). She received six cycles of CHOP (cyclophosphamide, doxorubicin, vincristine, and prednisone) followed by local irradiation. A computed tomography scan performed 2 months following the end of treatment demonstrated complete remission of post-transplant lymphoproliferative disease. Allograft function remained stable.

To our knowledge, this is the first case of B-cell post-transplant lymphoproliferative disease presenting as a subcutaneous mass and demonstrates that this diagnosis should be considered in working up such patients.

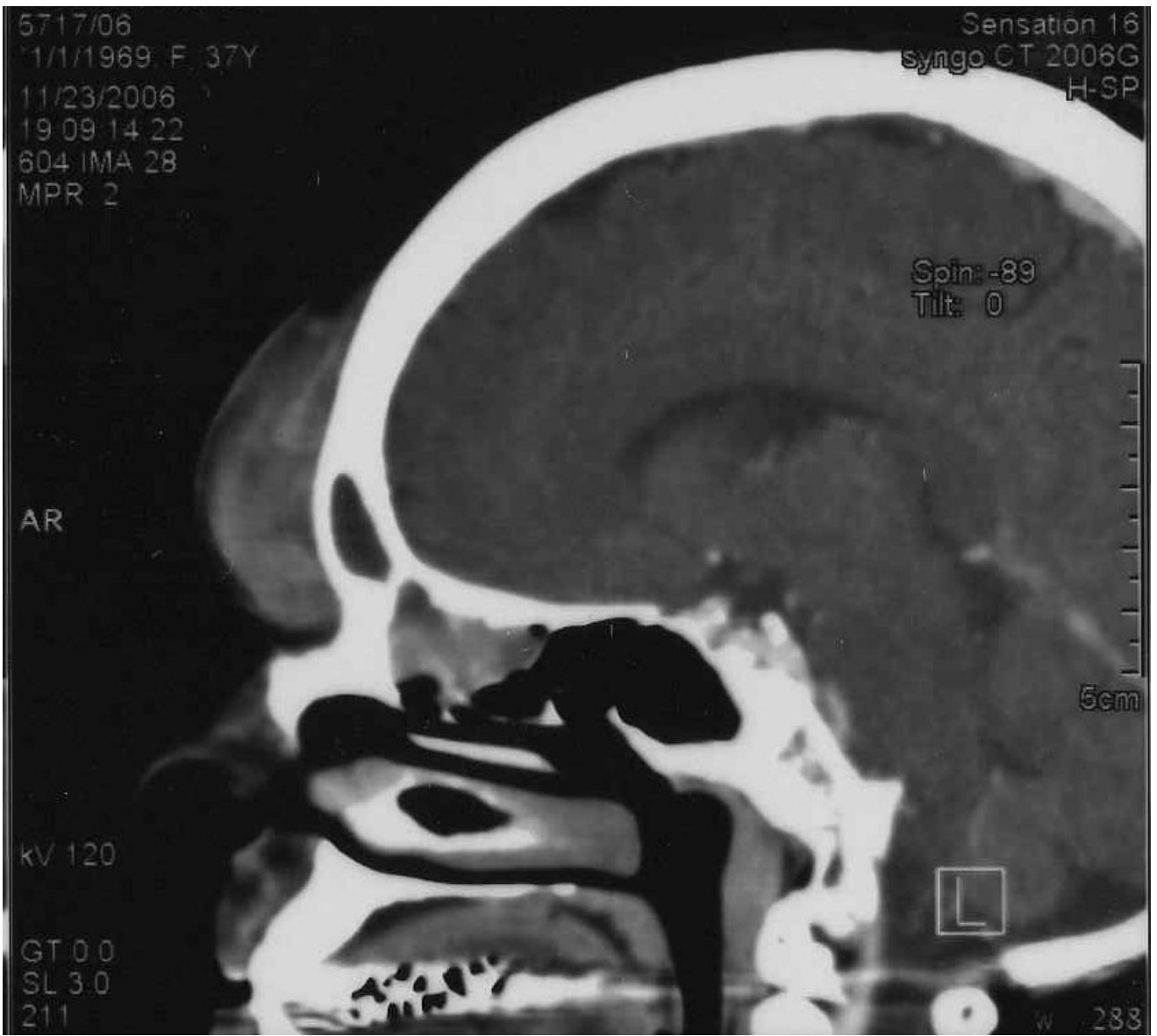
**Figure 1**

Diagnostic evaluation.

(a) Photograph of the patient's forehead. Purple solitary nodule is compressing the periorbital tissue producing swelling of the periorbital area.



(b) Computed tomography scan demonstrating the subcutaneous mass on the forehead that did not invade bones.





(c) Tumor biopsy finding. Dense infiltrate of atypical lymphoid cells positive for CD20, indicating B lymphocytes (immunoperoxidase stain, magnification x 40).

